

Surgery versus Balloon angioplasty for treating coarctation of aorta: A meta-analysis

Authors: -

1) Dr. Avichal Dani

Smt. NHLMMC, Ahmedabad, India

Email Address:- asdani98@gmail.com

2) Dr. Helly Thakkar

Smt. NHLMMC, Ahmedabad, India

Email Address:- hellythakkar1106@gmail.com

3) Dr. Dev Desai (Corresponding Author)

Smt. NHLMMC, Ahmedabad, India

Email Address:- devhdesai01@gmail.com

Mobile no.:- +91 9173655551

4) Dr. Jagdeepkaur S. Dani

Associate Professor, Department of Ocular Physiology, M & J Western Regional

Institute of Ophthalmology, Ahmedabad, India

Email Address:- dr.jagdeepdani@gmail.com

5) Dr. Sameer I. Dani

Chief, Department of Cardiology, Apollo CVHF Heart Institute, Ahmedabad, India

Email address:- drsameerdani@gmail.com

Abstract

Background: - In the past 50 years, therapeutic options for treating both children and adults with native aortic coarctation have significantly improved. In contrast to surgery, In 1982, balloon angioplasty (BA) was suggested as a potential alternative for the Primary treatment of CoA. Here, Surgery vs Angioplasty is compared to understand the rates of their complications like aneurysm and recoarctation.

Method:- A total of 13 RCTs with a total of 877 patients (Surgery-537, Angioplasty-340) of total patients were identified following PRISMA guidelines till November 2019 and were matched for inclusion and exclusion criteria. The following search strings and MESH terms were used: 'coarctation of aorta', 'surgery', 'balloon angioplasty, and 'aneurysm'. Following this, Surgery and Angioplasty were evaluated for complications and recoarctation. RevMan 5.3 was used for appropriate statistical tests. Fixed and Random Effect Model tests were used and $p < 0.05$ was considered statistically significant.

Result: - Angioplasty seems to be a Statistically better alternative with lesser complications (OR=1.993, CI95=1.126 to 3.527, $p=0.018$). It can be seen that Surgery is statistically far better in preventing the formation of an aneurysm (OR=0.291, CI95=0.141 to 0.602, $p=0.001$). Surgery as a treatment is statistically better than angioplasty to prevent a recoarctation (OR=0.375, CI95=0.268 to 0.524, $p < 0.001$).

Conclusion: - Surgery is found to be a better treatment option for preventing complications whereas angioplasty is better in preventing the formation of aneurysms and recoarctation.

Key words:- Coarctation of Aorta, Surgery, Balloon Angioplasty, Aneurysm

Introduction:-

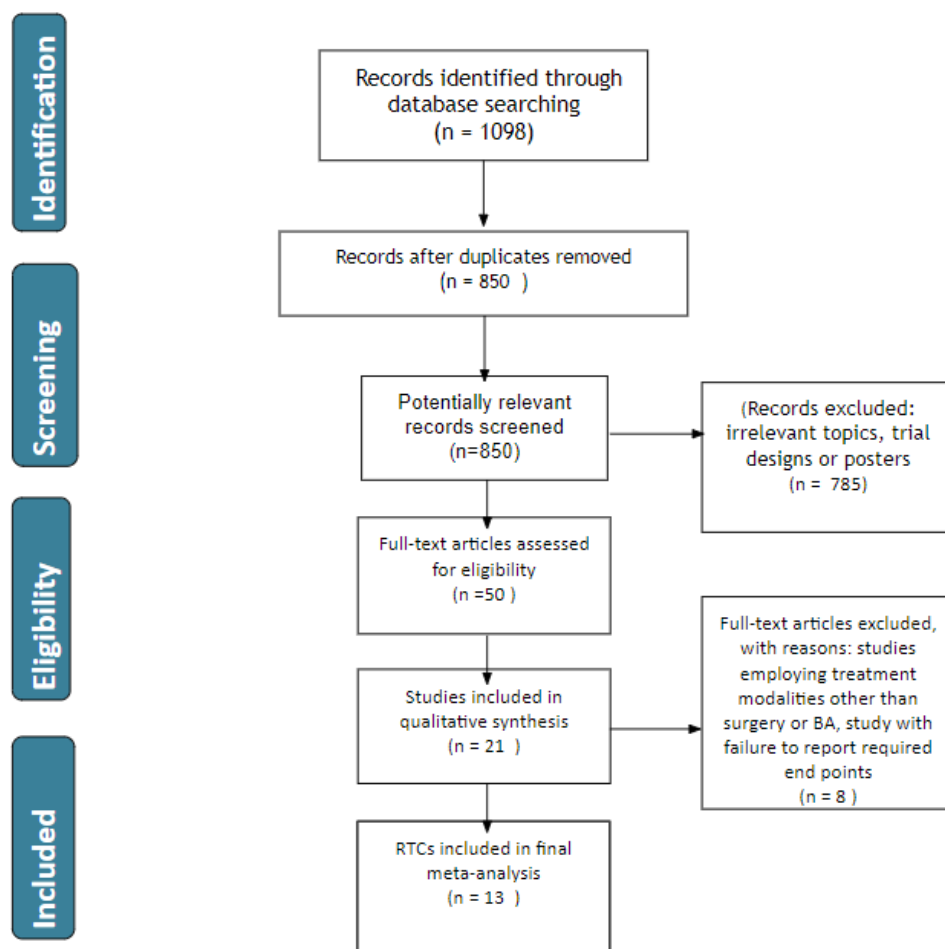
Johannes Baptista Morgani initially reported coarctation of the aorta (CoA), a malformation, in 1761. (1) In the past 50 years, therapeutic options for treating both children and adults with native aortic coarctation have significantly improved. Drs. Crawford and Nylin conducted the initial operation in 1944, and the surgical technique was improved throughout the subsequent four decades. (2) Despite the fact that surgical intervention's long-term results have been deemed adequate, in 1982, balloon angioplasty (BA) was suggested as a potential alternative to surgery for the primary treatment of CoA. (1)

In the 1990s, after the transcatheter balloon method, treating this lesion with intravascular stent therapy gained more recognition. Children and adults with native aortic coarctation are treated of choice at several hospitals using the transcatheter method. (2)

The indication for BA has become more clear as experience has grown, with patients who have long-segment coarctation and are younger than three months often being precluded from this kind of intervention. Surgery and BA both experience post-operative recoarctation and aneurysm development. It has not yet been determined if BA should be used as a first-choice treatment over surgical repair in a particular patient population. There are little data contrasting surgical treatment with balloon therapy. Actually, unfortunately, follow-up for all 3 types of treatment has been limited, making it difficult to draw any meaningful conclusions as to which treatment option is superior. (2)

The objective behind this meta-analysis is to find a better treatment modality with less complication for the treatment of Coarctation of the Aorta and to see the outcome results of each of these techniques. The two techniques to be compared here are surgery and angioplasty for rates of different complications with these procedures for example chances of producing an aneurysm, recoarctation, or other complications.

PRISMA Flowchart: - (Figure 1)



Methodology:-

SEARCH STRATEGY

A search was done using the databases- PubMed, Google Scholar, and Cochrane library for all relevant literature. Full - Text Articles written only in English were considered.

The medical subject headings (MeSH) and keywords 'coarctation of aorta', 'surgery', 'balloon angioplasty', and 'aneurysm' were used. References, reviews, and meta-analyses were scanned for additional articles.

STUDY SELECTION

Titles and abstracts were screened, and Duplicates and citations were removed. References of relevant papers were reviewed for possible additional papers. Papers with detailed patient information and statically supported results were selected.

we searched for papers that complications post procedures for coarctation, where the procedures considered were Surgery or Angioplasty.

The inclusion criteria were as follows: (1) studies that provided information about complications post procedures; (2) studies published in English; (3) Studies comparing Surgery and Angioplasty as a treatment modality for Coarctation

The exclusion criteria were as follows: (1) articles that were not full text ; (2) unpublished articles.

DATA EXTRACTION

Each qualifying paper was independently evaluated by two reviewers. Each article was analyzed for the number of patients, their age, procedure modality, and incidence of the predecided complications. Further discussion or consultation with the author and a third party was used to resolve conflicts. The study's quality was assessed using the modified Jadad score. In the end, a total of 13 RCTs with a total of 877 patients were selected according to PRISMA. Out of these 877 patients 537 had Surgery while 340 patients had Angioplasty.

STATISTICAL ANALYSIS

All of the data was obtained and entered into analytic software. Fixed- or random-effects models were used to estimate mean difference, standardized mean difference (SMD), odds ratios, and relative risk (RR) with 95 percent confidence intervals to examine critical clinical outcomes (CIs). Statistical heterogeneity was measured with the χ^2 ; $P < 0.100$ was considered as a representation of significant difference. I^2 greater than or equal to 50% indicated the presence of heterogeneity. Funnel plots were used to assess potential publication bias based on the prevalence of wound infection after surgery. A statistically significant difference was defined as $P < 0.05$.

RESULT

Figure 2 :- Complications

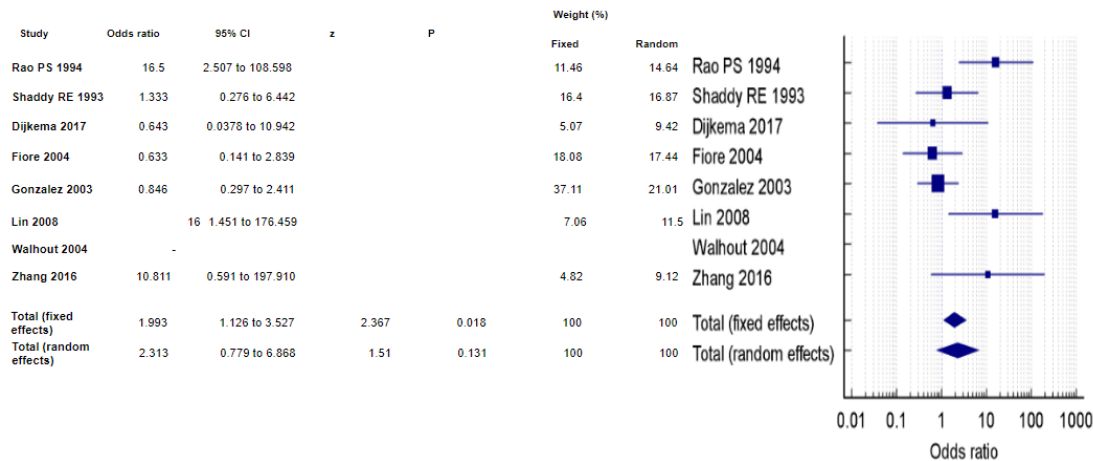


Figure 3 : Aneurysm

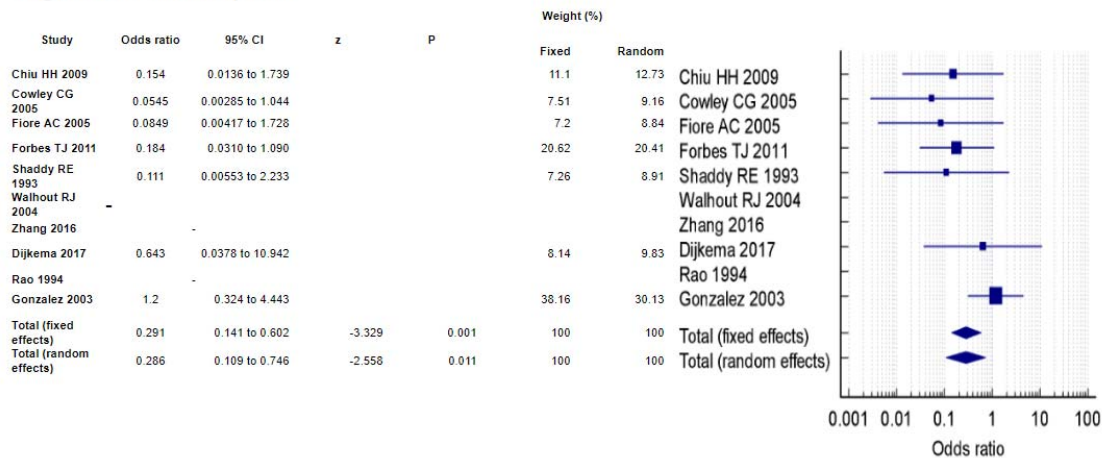
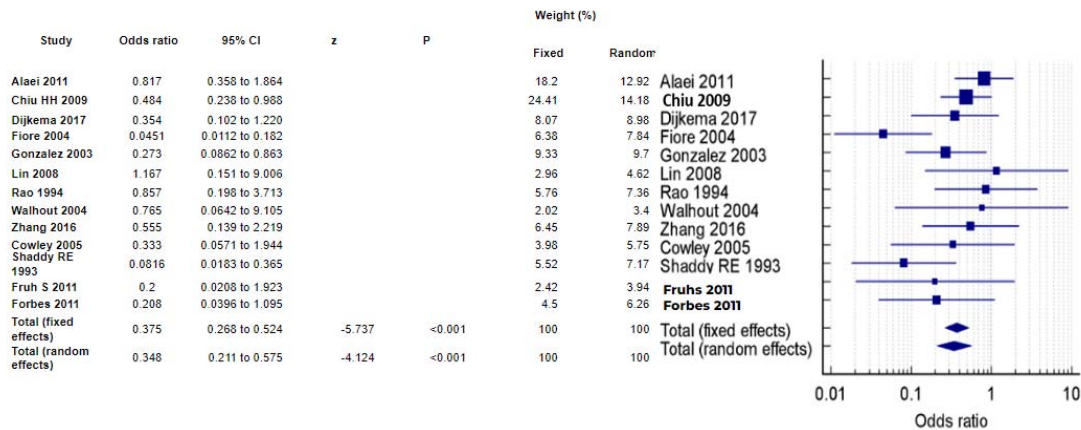


Figure 4 : Re-CoA



With the results presented above, it can be seen that when complications are compared between these two modalities of surgery and angioplasty, as per figure 2 Angioplasty seems to be a Statistically better alternative with lesser complications (OR=1.993, CI95=1.126 to 3.527, p=0.018). These results are supported by (3) (4) (5) but (6) says otherwise.

When the comparison of aneurysms is checked as depicted in figure 3, it can be seen that Surgery is statistically far better in preventing the formation of an aneurysm (OR=0.291, CI95=0.141 to 0.602, p=0.001) and it can be supported by (5) (6) (7) but (8) is the only paper we found saying otherwise and its results are statistically insignificant.

Figure 4 denotes the chances of formation of a coarctation again and it can be seen that surgery as a treatment is statistically better than angioplasty to prevent a recoarctation (OR=0.375, CI95=0.268 to 0.524, p=<0.001). These results are identical to all papers (6) (5) except in (9) .

Discussion:

This seems like a common pattern in almost all literature present anywhere is that out of all the modalities present to treat a coarctation, be it Surgery or Angioplasty with balloon or stent; no modality is full proof and each procedure has its own fallings when it comes to the complications it produces in the patients.

It is seen in almost all patients that surgery as a treatment modality beings the highest amount of post-operation complications which include (3) (4). In contrast to Surgery, we found that angioplasty produces very low incidences of these complications and these results are similar to many research papers present in the current literature available. There are some papers present that shows that angioplasty might carry higher chances of these complications but it can be seen that most of those papers have statistically insignificant results.

An aneurysm is one of the major complications produced in a treated coarctation as the wall is damaged and weak. The outpouching of this weak wall produces an aneurysm which can rupture and cause a big hemorrhage and hematoma. Failure to manage this patient almost results in the death of the patient. Aneurysm and rupture of these aneurysms in the brain can lead to stroke and sudden death. It is evident with the presented results that Angioplasty actually decreases the odds of producing an aneurysm in treated coarctation in contrast to surgery(6, 7); maybe because surgery opens the vessel wall so when stitched back, it is ought to bring some kind of weakness due to that not being the original tissue but being a healed tissue. Angioplasty is repeatedly found to be a better treatment modality in preventing an aneurysm formation.

One of the major issues with treating a coarctation is that the treated region might form a coarctation again. Also known as recoarctation, it is a major complication and needs the usage of treatment again. It was found in our results that angioplasty is far superior in preventing the formation of a recoarctation and this is similar to the pattern found in present literature and studies(5, 6). The reason behind a higher rate of recoarctation with surgery is that when the vessel is closed again, there is bound to become some type of stricture as the normally elastic tissue will be replaced with healing tissue.

Conclusion:-

All treatment modalities for the treatment of Coarctation have their own issues when it comes to complications but Surgery is found to be a better treatment option for preventing complications whereas angioplasty is better in preventing the formation of aneurysm and recoarctation.

No.	Author A	Year	Duration of follow up	Parameters given	Favourable towards	Location	Sample size	Mean age	Sample Characteristic	Quality
1	Forbes TJ et al. (2)	2011	1.9 years	Severe complication, Post-op aneurysm, Re-CoA	Angioplasty	USA	350	16.6 ± 10.9	Patient demographics such as age, weight, sex, and associated diagnosis were recorded. Baseline clinical information included upper and lower extremity systolic/diastolic blood pressures (BP), current antihypertensive medications, pre-operative CT, MRI, or catheterization measurements of the long axis of the aorta, coarctation type (discrete vs. long segment), and location.	Good
2	Rao PS et al. (3)	1994	4.5 years	Severe complication, Post-op aneurysm, Re-CoA	Angioplasty	Madison, Wisconsin	29	27 ± 35 Days	All infants 53 months old seen during the decade ending 1992 who underwent either surgical or balloon therapy for native aortic coarctation.	Good

									coarctation, imspeclive of the associated defects were included in our analysis	
3	Shaddy RE et al. (5)	1993	2-6 weeks	Severe complication, Post-op aneurysm, Re-CoA	Angio plasty	Salt Lake City, UT	36	6.3±2.0	all patients between the ages of 3 and 10 years who were seen at Primary Children's Medical Center with the clinical diagnosis of hemodynamical ly significant unoperated coarctation of the thoracic aorta were offered enrollment in a study comparing angioplasty and surgical treatment of coarctation of the aorta.	Good
4	Dijkema et al. (10)	2017	1–10 years	Severe complication, Post-op aneurysm, Re-CoA	Angio plasty	Leiden , Netherlands	48	NA	Only patients with coarctation of the localized membranous form were included	Good
5	Fiore et al. (6)	2005	37 months	Severe complication, Post-op aneurysm, Re-CoA	Surger y	Johnso n City, Tennessee	57	8.8 days	The intent of the study was to compare balloon angioplasty with surgery as initial treatment in neonates with hemodynamical	Good

									ly significant coarctation of the aorta. Patients excluded from the analysis included those with other complex anomalies such as univentricular heart, transposition of the great vessels, Taussig-Bing anomaly, and any patient suspected of having bacterial endocarditis or connective tissue disorder.	
6	Gonzalez et al. (8)	2003	6 months to 1 year	Severe complication, Post-op aneurysm, Re-CoA		Mexico	58	7.00 ±4.14	We studied male and female pediatric patients with congenital aortic coarctation, 1 to 16 years of age including patients with clinical diagnosis of aortic coarctation and trans-coarctation gradient 20 mmHg (determined by echocardiography or catheterization).	Good
7	Lin et al. (9)	2008	19 months	Severe complication	Angioplasty	Taipei	21	35 days	we encountered 34 cases of	Good

				on,Re-CoA		Taiwan			NAC in patients less than 120 days of age. We excluded patients with complex cardiac anomalies such as Taussig-Bing anomaly (2 patients), hypoplastic left heart syndrome (4 patients), double outlet right ventricle (2 patients), and tricuspid atresia (1 patient). Twenty-one patients were enrolled because 4 patients were lost to follow-up	
8	Walhout et al. (1)	2004	7.2 ±2.4 years	Severe complication, Post-op aneurysm, Re-CoA		Lausanne, Switzerland	46	5.8 years	This study includes 46 consecutive patients with coarctation of the localised membranous form. Neither isthmus hypoplasia, defined as isthmus diameter less than 40% of diameter of ascending aorta, nor arch hypoplasia, defined as proximal or distal transverse arch diameter	Good

									less than 60 or 50%, respectively, of the diameter of the ascending aorta, were present in any of the patients. All patients were older than 3 months of age.	
9	Zhang et al. (4)	2016	33 months	Severe complication, Post-op aneurysm, Re-CoA		Shanghai, China	92	59.6 Days	(I) the length of CoA was less than 5 mm; (II) the transverse aortic arch-to-ascending aorta diameter ratio was more than 0.3; and (III) the size of the patent ductus arteriosus (PDA) was less than 50% of the descending aorta diameter.	Good
10	Chiu HH et al. (11)	2009		Post-op aneurysm		Taipei, Taiwan	169		Patients diagnosed with simple CoA with or without a ventricular septal defect (VSD) were identified from the patient database of our institution from 1986 to 2004.	Good
11	Cowley CG et al. (7)	2005	1 year	Post-op aneurysm, Re-CoA	Surgery		36	3 to 10 years	all patients between the ages of 3 and 10 years seen at Primary Children's	Good

									Medical Center with a hemodynamically significant native CoA were invited to participate in an Institutional Review Board–approved study	
12	Alaei et al. (12)	2011	12 months	Re-CoA	Surgery		167	153.0±95.6 Days	All of these patients were younger than 1 year old with a diagnosis of coarctation of the aorta, with or without co-associated lesions.	Good
13	Fruh et al. (13)	2011	17.5 months	Re-CoA	Surgery		91	0.4 years	all consecutive patients treated for native CoA and Re-CoA between September 2001 and September 2006 with an age younger than or equal to 18 years were treated according to our age-related treatment using surgery by a majority for neonates and infants, and stent implantation for older children (>6 years) and adolescents for native and recurrent CoA.	Good

References:-

1. Ronald J Walkout JCL, Gordon H Oron, Ger B W E Bennink, Erik J Meijboom. Comparison of surgical repair with balloon angioplasty for native coarctation in patients from 3 months to 16 years of age 2004 [Available from: <https://pubmed.ncbi.nlm.nih.gov/15082273/>
2. Thomas J. Forbes DWK, Wei Du, Daniel R. Turner, Ralf Holzer, Zahid Amin, Ziyad Hijazi, Abdolrahim Ghasemi, Jonathan J. Rome, David Nykanen, Evan Zahn, Collin Cowley, Mark Hoyer, David Waight, Daniel Gruenstein, Alex Javois, Susan Foerster, Jacqueline Kreutzer, Nancy Sullivan, Asra Khan, Carl Owada, Donald Hagler, Scott Lim, Joshua Canter, Thomas Zellers,. Comparison of Surgical, Stent, and Balloon Angioplasty Treatment of Native Coarctation of the Aorta: An Observational Study by the CCISC (Congenital Cardiovascular Interventional Study Consortium) 2011 [Available from: <https://www.jacc.org/doi/abs/10.1016/j.jacc.2011.08.053>
3. P.Syamasundar Rao PSC, Rebecca Kosciak, Patricia A. Smith, Allen D. Wilson,. Surgical versus balloon therapy for aortic coarctation in infants \leq 3 months old 1994 [Available from: [https://www.jacc.org/doi/abs/10.1016/0735-1097\(94\)90395-6](https://www.jacc.org/doi/abs/10.1016/0735-1097(94)90395-6)
4. Huifeng Zhang MY, Gang Chen, Fang Liu, Lin Wu, Bing Jia. A comparison of balloon angioplasty of native coarctation versus surgical repair for short segment coarctation associated with ventricular septal defect-a single-center retrospective review of 92 cases 2016 [Available from: <https://pubmed.ncbi.nlm.nih.gov/27621858/>.
5. R E Shaddy MMB, J E Sturtevant, H D Ruttenberg, R B Jaffe, L Y Tani, V E Judd, L G Veasy, E C McGough and G S Orsmond. Comparison of angioplasty and surgery for unoperated coarctation of the aorta. 1993 [Available from: <https://www.ahajournals.org/doi/abs/10.1161/01.cir.87.3.793>
6. Andrew C Fiore LKF, Theresa Schwartz, Saadeh Jureidini, Ian Balfour, Dustin Carpenter, Daphne Demello, Katherine S Virgo, D Glenn Pennington, Robert G Johnson. Comparison of angioplasty and surgery for neonatal aortic coarctation 2004-2005 [Available from: <https://pubmed.ncbi.nlm.nih.gov/16242435/>
7. Collin G. Cowley GSO, Peter Feola, Lon McQuillan, Robert E. Shaddy. Long-Term, Randomized Comparison of Balloon Angioplasty and Surgery for Native Coarctation of the Aorta in Childhood 2005 [Available from: <https://www.ahajournals.org/doi/full/10.1161/CIRCULATIONAHA.104.510198>
8. Martha Hernández-González SS, Ignacio Conde-Carmona, Alberto Rangel-Abundis, Mariano Ledesma, Jaime Munayer, Felipe David, José Ortegón, Santiago Jiménez, Agustín Sánchez-Soberanis, Carlos Meléndez, Sergio Claire, Juan Gomez, Raúl Teniente-Valente, Carlos Alva. Intraluminal aortoplasty vs. surgical aortic resection in congenital aortic coarctation. A clinical random study in pediatric patients 2003 [Available from: <https://pubmed.ncbi.nlm.nih.gov/12957528/>
9. Shan-Miao Lin H-KH, Shye-Jao Wu and Ming-Ren Chen. Comparison Between Balloon Angioplasty and Surgery for Native Coarctation of the Aorta in Neonates and Young Infants 2008 [Available from: https://scholar.google.co.in/scholar?hl=en&as_sdt=0,5&as_vis=1&q=Lin+2008+coarctation+of+aorta.
10. Elles J Dijkema G-jTS, Tim Takken, Tim Leiner, Paul H Schoof, Felix Haas, Jan L M Strengers, Martijn G Slieker. Long-term results of balloon angioplasty for native coarctation of the aorta in childhood in comparison with surgery 2017 [Available from: <https://academic.oup.com/ejcts/article/53/1/262/4085761>

11. Hsin-Hui Chiu S-NC, Fu-Chang Hu, Chun-An Chen, Ming-Tai Lin, Jou-Kou Wang, Chung-I Chang, Yih-Shang Chen, Ing-Sh Chiu, Mei-Hwan Wu. Late cardiovascular complications after surgical or balloon angioplasty of coarctation of aorta in an Asian cohort 2009 [Available from: <https://pubmed.ncbi.nlm.nih.gov/19801038/>
12. Fariba Alaei MYAM, Hojat Mortaezaian, Mastaneh Alaei, Hooman Bakhshandeh. Comparison of angioplasty and surgery for neonatal aortic coarctation 2011 [Available from: <https://www.ncbi.nlm.nih.gov/pmc/articles/PMC3466896/>
13. Seraina Früh WK, Ali Dodge-Khatami, Hitendu Dave, René Prêtre, Oliver Kretschmar,. Comparison of surgical and interventional therapy of native and recurrent aortic coarctation regarding different age groups during childhood 2011 [Available from: <https://academic.oup.com/ejcts/article/39/6/898/377967>

Supplemental Table 2