

1 **Impact of Transjugular Intracardiac Echocardiography-Guided**
2 **Self-Expandable Transcatheter Aortic Valve Implantation**
3 **on Reduction of Conduction Disturbances**

4
5 Kenichi Ishizu, MD,^a Shinichi Shirai, MD,^a Norihisa Miyawaki, MD,^a Kenji Nakano, MD,^a
6 Tadatomo Fukushima, MD,^a Euihong Ko, MD,^a Yasuo Tsuru, MD,^a Hiroaki Tashiro, MD,^a
7 Hiroyuki Tabata, MD,^a Miho Nakamura, MD,^a Toru Morofuji, MD,^a Takashi Morinaga, MD,^a
8 Masaomi Hayashi, MD,^a Akihiro Isotani, MD,^a Nobuhisa Ohno, MD, PhD,^b Shinichi
9 Kakumoto, MD,^c Kenji Ando, MD^a

- 10 1. Department of Cardiology, Kokura Memorial Hospital, Kitakyushu, Japan
11 2. Department of Cardiovascular Surgery, Kokura Memorial Hospital, Kitakyushu, Japan
12 3. Department of Anesthesiology, Kokura Memorial Hospital, Kitakyushu, Japan

13
14 **Short running title:** ICE-guided self-expandable TAVI

15 **Total word count:** 4997 words

16
17 **Address for correspondence:**

18 Kenichi Ishizu, MD

19 Department of Cardiology, Kokura Memorial Hospital, 3-2-1 Asano, Kokurakita-ku,
20 Kitakyushu, Fukuoka, 802-8555, Japan

21 Tel.: +81-93-511-2000; Fax: +81-93-511-2029

22 E-mail: k.ishizu.04ri@gmail.com

1 **Abstract**

2 **Background:** A high permanent pacemaker implantation (PPI) risk remain a concern of
3 self-expandable transcatheter aortic valve implantation (TAVI), despite continued
4 improvements in implantation methodology. We aimed to assess the impact of real-time
5 direct visualization of the membranous septum using transjugular intracardiac
6 echocardiography (ICE) during TAVI on reducing the rates of conduction disturbances
7 including the need for PPI.

8 **Methods:** Consecutive patients treated with Evolut R and Evolut PRO/PRO+ from February
9 2017 to September 2022 were included in this study. We compared outcomes between the
10 conventional implantation method using the 3-cusps view (“3-cusps without ICE” group), the
11 recent method using cusp-overlap view (“cusp-overlap without ICE” group), and our novel
12 method using ICE (“cusp-overlap with ICE” group).

13 **Results:** Of the 446 patients eligible for analysis, 211 (47.3%) were categorized as the
14 “3-cusps without ICE” group, 129 (28.9%) were in the “cusp-overlap without ICE” group,
15 and 106 (23.8%) comprised the “cusp-overlap with ICE” group. Compared with the “3-cusps
16 without ICE” group, the “cusp-overlap without ICE” group had a smaller implantation depth
17 (2.2 [IQR 1.0–3.5] mm vs 4.3 [IQR: 3.3–5.4], $P < 0.001$) and lower 30-day PPI rates (7.0% vs
18 14.2%, $P = 0.035$). Compared with the “cusp-overlap without ICE” group, the “cusp-overlap
19 with ICE” group had lower 30-day PPI rates (1.0%, $P = 0.014$), albeit with comparable
20 implantation depths (1.9 [IQR 0.9–2.9] mm, $P = 0.150$). Multivariable analysis showed that
21 our novel method using ICE with the cusp-overlap view was independently associated with a
22 30-day PPI rate reduction. There were no group differences in 30-day all-cause mortality
23 (1.4% vs 1.6% vs 0%; $P = 0.254$).

24 **Conclusions:** Our novel implantation method using transjugular ICE, which enabled a
25 real-time direct visualization of the membranous septum, achieved a predictably high
26 position of prostheses, resulting in a substantial reduction of conduction disturbances
27 requiring PPI after TAVI.

1 **Key Words:**

2 Transcatheter aortic valve implantation, Permanent pacemaker implantation, Implantation

3 depth, Novel technique

4

1 **Introduction**

2 In the past decades, recommendations for transcatheter aortic valve implantation (TAVI),
3 which was established as a therapeutic alternative to surgical aortic valve replacement
4 (SAVR) for inoperable or high-risk patients with severe aortic stenosis (AS), have expanded
5 to include lower-risk patients.¹⁻³ However, a higher risk of conduction disturbances requiring
6 permanent pacemaker implantation (PPI) remain a serious concern of self-expandable TAVI.
7 Indeed, a large-scale randomized trial of low-surgical-risk patients demonstrated non-inferior
8 outcomes of self-expandable TAVI to SAVR, but the excess of new PPI for self-expandable
9 TAVI was noted albeit with its repositionable nature (17.4% vs 6.1%).⁴ Anatomically, the
10 conduction system is located at the lower end of the membranous septum (MS), and high
11 implantation is required to mitigate the risk of PPI in patients with a short MS. The recently
12 developed cusp-overlap method has been widely used in place of the conventional 3-cusps
13 method to achieve an accurate transcatheter heart valve (THV) implantation depth by
14 eliminating the parallax between the aortic annulus and the delivery catheter. However, the
15 Optimize PRO study interim analysis⁵, which examined the usefulness of the cusp-overlap
16 method, reported a still relatively high PPI rate of 8.8%. Therefore, we utilized transjugular
17 intracardiac echocardiography (ICE) to continuously monitor the MS during TAVI and
18 attempted to reduce the PPI rate by repositioning the device based on the ICE findings. The
19 aim of our study was to assess the impact of transjugular ICE-guided self-expandable TAVI
20 on reducing the rates of post-procedural conduction disturbances, compared to those resulting
21 from conventional implantation methods without ICE.

22

23 **Methods**

24 **Study Population and Design**

25 From February 2017 to September 2022, 1531 consecutive patients undergoing
26 TAVI at the Kokura Memorial Hospital were prospectively included in an institutional
27 database. All patients were considered as eligible candidates for TAVI rather than SAVR via

1 consensus of the heart team, and written informed consent was obtained from all patients
2 before the TAVI procedure. The study conformed to the principles outlined in the Declaration
3 of Helsinki and was approved by the Institutional Review Board of Kokura Memorial
4 Hospital. After excluding patients with balloon-expandable TAVI, previous cardiac electronic
5 device, and previous aortic bioprosthesis, a total of 446 patients treated with contemporary
6 repositionable self-expandable TAVI for symptomatic severe native AS were included in the
7 final analysis (**Figure 1**).

8

9 **Multidetector Computed Tomographic Image Acquisition and Analysis**

10 Computed tomographic examinations were performed as previously described.^{6,7} All
11 patients underwent pre-procedural electrocardiographically-gated multidetector computed
12 tomography (MDCT) using a 256-row system (Revolution CT, GE Healthcare, Waukesha,
13 WI) with a slice thickness of 0.625 mm and 25–70 mL of intravenously administered contrast
14 agent (Oypalomin 350, Fuji Pharma, Tokyo, Japan). Off-line measurements were performed
15 with 3mensio Valves software version 7.0 or 8.0 (Pie Medical Imaging, Maastricht,
16 Netherlands). The aortic annulus and left ventricular outflow tract (LVOT) area were
17 measured in mid-systole, and the other measurements were obtained in diastole. As
18 previously described, the MS length was measured by determining the thinnest part of the
19 interventricular septum on the perpendicular annular plane (axial) image, using the
20 perpendicular crosshairs to find the corresponding stretched vessel image and using the latter
21 to measure the perpendicular vertical distance from the annular plane to the vertex of the
22 muscular septum (**Figure S1**).⁸

23

24 **Procedure and Implantation Technique**

25 Evolut R and Evolut PRO/PRO+ (Medtronic, Minneapolis, MN) THVs were
26 implanted, and the sizing of which was determined on the basis of contrast-enhanced MDCT
27 findings. Before October 2019, 23-, 26-, and 29-mm THVs were used, and after its

1 commercial release in October 2019, 34-mm Evolut PRO+ were also included. The femoral
2 artery was the first-choice approach route; if femoral access was inappropriate, the iliac artery,
3 subclavian, or direct aortic routes were considered. The 3-cusps coplanar angle was
4 angiographically modified during the procedure based on the pre-procedural MDCT. The
5 conventional deployment method (earlier era) includes 4 elements: 1) advancing the delivery
6 catheter across the native valve in the 3-cusps coplanar view; 2) eliminating parallax of the
7 delivery catheter by moving the C-arm to more left anterior oblique and/or caudal from the
8 coplanar view; 3) deploying the THV to the point of no recapture; and 4) determining the
9 suitability for immediate device release or device repositioning by a pre-release coaxial root
10 angiogram. In July 2020, we introduced the systematic deployment method proposed by Tang
11 et al.⁹, including 5 elements: 1) advancing the delivery catheter across the native valve in the
12 cusp-overlap view, a coplanar projection achieved by overlapping the right coronary cusp and
13 left coronary cusp; 2) deploying the THV to the point of no recapture; 3) confirming the
14 target implantation depth from the bottom of the noncoronary cusp by a root angiogram in the
15 cusp-overlap view; 4) assessing the implantation depth from the bottom of the left coronary
16 cusp and the coaxiality of the delivery catheter with the aorta by a root angiogram in the
17 3-cusps coplanar view; and 5) determining the suitability for immediate device release or
18 device repositioning by these two root angiograms. Moreover, in addition to the cusp-overlap
19 technique, we have routinely used ICE during TAVI to continuously visualize the MS, the
20 bottom of which is known to be a risky landing zone for conduction disturbances. In all cases,
21 the AcuNav (Biosense Webster, Irvine, CA) ICE catheter was inserted from the right jugular
22 vein, enabling real-time evaluation for not only the relationship between the THV stent frame
23 and the MS but also the stiff wire in the left ventricle and paravalvular leakage. When the
24 bottom of the THV was located at a deeper position than MS at the point of no recapture, we
25 unexceptionally repositioned the THV to a higher position within the MS to prevent the stent
26 frame from damaging the conduction system (**Figure 2**). Therefore, the patients in our study
27 were divided into three chronological groups: 1) “3-cusps without ICE” group; 2)

1 “cusp-overlap without ICE” group; and 3) “cusp-overlap with ICE” group (**Figure 1**).

2

3 **Electrocardiography**

4 Following the procedure, patients had several twelve-lead electrocardiograms
5 (ECGs) to document serial changes in conduction. Those without significant changes in
6 cardiac conduction were routinely discharged on post-operative day five. Conduction
7 disturbances were determined as per standard definitions by the American Heart Association,
8 American College of Cardiology Foundation, and Heart Rhythm Society recommendations
9 for the standardization and interpretation of ECGs.¹⁰ A new-onset high-grade atrioventricular
10 block (AVB) was defined as the development of a second- or third- degree AVB on
11 post-procedural ECGs. A new-onset left bundle branch block (LBBB) was dichotomized into
12 persistent LBBB or transient LBBB. Persistent LBBB was defined as the development of
13 LBBB on post-procedural ECGs that persisted to discharge.

14

15 **Outcome Measures and Follow-up**

16 The primary outcome measure of the study was PPI within 30 days after the TAVI
17 procedure. As specific guidelines about the indications for post-TAVI PPI are lacking,¹¹ we
18 defined the indication for PPI as the presence of persistent high-grade AVB with the
19 agreement about the need for PPI in our electrophysiology team. We also assessed the other
20 new-onset conduction disturbances, including LBBB, THV implantation depth, and
21 procedural outcomes. All patients underwent up to 30 days of follow-up. Outcomes were
22 assessed according to the Valve Academic Research Consortium (VARC)-3 criteria.¹²

23

24 **Measurements of Prosthesis Implantation Depth**

25 Prosthesis implantation depth was measured from an off-line evaluation of
26 post-TAVI electrocardiographically-gated MDCT, which was routinely performed several
27 days after the procedure in our institute to assess the positional relation of the implanted

1 prosthesis and the surrounding structures. Off-line measurements were performed with
2 3mensio Valves software version 7.0 or 8.0 (Pie Medical Imaging, Maastricht, Netherlands)
3 as with the pre-TAVI MDCT. Implantation depth was defined as the vertical distance from the
4 native annulus to the most proximal edge to the stent frame on the same stretched vessel
5 plane used to measure the MS length in the pre-TAVI MDCT (**Figure S2**). To evaluate intra-
6 and inter-observer variabilities, we randomly selected a repeated measurement for a subset of
7 20 patients. Intra- and inter-observer agreements were almost perfect (intra-observer:
8 intraclass correlation coefficient [ICC]: 0.96; inter-observer: ICC 0.94).

10 **Statistical Analysis**

11 Categorical variables were described as number and percent and were compared
12 using the chi-square test. Continuous variables were described as the mean \pm standard
13 deviation or median (interquartile range, IQR) and were compared using the independent
14 Student's *t*-test or Kruskal–Wallis test depending on their distributions. To test the predictive
15 ability of our new implantation method using ICE for PPI, a multivariable logistic regression
16 model was constructed, which comprised variables known to be associated with PPI based on
17 clinical plausibility^{13,14} or with *P* values <0.10 in the univariate analysis. Associations were
18 expressed as odds ratios (OR) with 95% confidence interval (CI).

19 All statistical analyses were performed using JMP 14.2.0 (SAS Institute Inc., Cary,
20 NC) and R version 4.0.2 (R Foundation for Statistical Computing, Vienna, Austria). A
21 2-tailed *P* value of 0.05 was used for significance testing.

23 **Results**

24 **Baseline Patient Characteristics**

25 Of the 446 patients eligible for analysis, 211 (47.3%) were categorized as the
26 “3-cusps without ICE” group, 129 (28.9%) were included in the “cusp-overlap without ICE”
27 group, and 106 (23.8%) comprised the “cusp-overlap with ICE” group. The main baseline

1 clinical characteristics are presented in **Table 1**. The mean age of our study population was
2 85 (IQR: 82–89) years, 24% of patients were male, and the median Society of Thoracic
3 Surgeons (STS) risk score was 5.3 (IQR: 3.7–8.0). Patient demographics were comparable
4 between the three groups, except for the prevalence of male (19.0% vs 30.2% vs 27.4%; $P =$
5 0.042) and the Society of Thoracic Surgeons (STS) risk score (6.1 [IQR: 4.1–9.4] % vs 4.7
6 [IQR: 3.5–7.0] % vs 5.0 [IQR: 3.7–7.1] %; $P = 0.001$). The MS length was similar between
7 the three groups ($P = 0.824$).

8

9 **Procedural Characteristics**

10 Procedural characteristics are listed in **Table 2**. Almost all (92.2%) patients
11 underwent TAVI via the transfemoral approach. Overall, 59.9% received a 26-mm THV,
12 22.0% received a 29-mm THV, and 16.8% received a 23-mm THV. The degree of oversizing
13 and the rate of pre- and post-dilatation did not differ between the three groups. General
14 anesthesia was more frequently performed in the “3-cusps without ICE” group, compared
15 with the other two groups. The procedure time and contrast volume were also greater in the
16 “3-cusps without ICE” group.

17

18 **Outcomes**

19 Procedural clinical outcomes are shown in **Table 3**. Implantation depth was smaller
20 in the “cusp-overlap without ICE” group compared with the “3-cusps without ICE” group
21 (2.2 [IQR: 1.0–3.5] mm vs 4.3 [IQR: 3.3–5.4] mm; $P < 0.001$). Moreover, the difference
22 between the MS length and implantation depth (Δ MSID) was larger in the “cusp-overlap
23 without ICE” group compared with the “3-cusps without ICE” group (0.4 [IQR: -0.4–1.6]
24 mm vs -1.2 [IQR: -3.2–0.3] mm; $P < 0.001$). Although a comparable median Δ MSID was
25 observed between the “cusp-overlap without ICE” group and the “cusp-overlap with ICE”
26 group, the variation in the Δ MSID was obviously smaller in the “cusp-overlap with ICE”
27 group (**Figure 3**). Technical success and device success were achieved respectively in 437

1 (98.0%) and 414 (92.8%) patients, with significantly higher success rates across the three
2 groups. The rates of peri-procedural complications were low and comparable between the
3 three groups without Type 3 (life-threatening) or 4 (leading to death) bleeding (3.8% vs 2.3%
4 vs 0%; $P = 0.036$). All-cause 30-day mortality also did not differ between the three groups (P
5 = 0.254).

6 New-onset conduction disturbances after the TAVI procedure are detailed in **Table 4**.
7 Within 30 days, a total of 40 patients (9.0%) underwent PPI 5 (IQR: 3–6) days after TAVI.
8 The indication for PPI was a high-degree AVB in 3 patients and complete AVB in 37 patients.
9 As a whole, the rate of a 30-day PPI was substantially reduced with the temporal change in
10 implantation methods (“3-cusps without ICE” group vs “cusp-overlap without ICE” group vs
11 “cusp-overlap with ICE” group: 14.2% vs 7.0% vs 0.9%, respectively; $P < 0.001$). In addition,
12 significant differences were observed between adjacent groups (“3-cusps without ICE” group
13 vs “cusp-overlap without ICE” group: $P = 0.035$; “cusp-overlap without ICE” group vs
14 “cusp-overlap with ICE” group: $P = 0.014$) (**Figure 4A**). In the “cusp-overlap with ICE”
15 group, a THV bottom landing in the MS was achieved in all patients except for only one who
16 underwent a deep dive of the THV into the left ventricle and consequently required a PPI 4
17 days after TAVI. The incidence of new-onset persistent LBBB at discharge was also lower
18 across the groups (21.8% vs 12.4% vs 3.8%; $P < 0.001$). In the multivariable analysis,
19 compared with the “cusp-overlap without ICE” method, the “cusp-overlap with ICE” method
20 was independently associated with a lower 30-day PPI requirement (adjusted OR, 0.07 [95%
21 CI, 0.01–0.64]; $P = 0.018$). Baseline right bundle branch block (RBBB) (adjusted OR, 8.61
22 [95% CI, 3.49–21.24]; $P < 0.001$) and short MS length (adjusted OR per 1 mm decrease, 1.82
23 [95% CI, 1.30–2.54]; $P < 0.001$) also predicted a higher risk of 30-day PPI (**Table 5**). As post
24 hoc analyses, we assessed the impact of each implantation method on 30-day PPI in the
25 subgroups at high risk for conduction disturbances. The results showed a significantly lower
26 30-day PPI rate in the “cusp-overlap with ICE” group compared with the “cusp-overlap
27 without ICE” group also in patients with baseline RBBB (7.1% vs 44.4%; $P = 0.034$) (**Figure**

1 **4B)** or with an MS length < 2.5 mm (1.9% vs 12.7%; $P = 0.024$) (**Figure 4C**).

2 With regard to 30-day echocardiographic outcomes (**Table 6**), the “3-cusps without
3 ICE” group demonstrated a lower indexed effective orifice area (EOA) (1.77 [IQR: 1.50–
4 2.03] cm² vs 1.97 (IQR: 1.68–2.26) cm² vs 1.93 [IQR: 1.63–2.22] cm²; $P < 0.001$) and a
5 higher incidence of patient-prosthesis mismatch (PPM) (5.7% vs 1.6% vs 0.9%; $P = 0.027$).
6 In contrast, there were no differences in the rates of mild AR (56.9% vs 52.7% vs 54.7%; $P =$
7 0.703) or moderate to severe AR (0.5% vs 0.8% vs 0.9%; $P = 0.878$).

8

9 **Discussion**

10 In this study, we analyzed the impact of the novel implantation method using
11 transjugular ICE on reducing the occurrence of conduction disturbances and PPI after the
12 repositionable self-expandable TAVI. The main findings of our study are as follows: 1)
13 Compared with the 3-cusps view only, the combined use of cusp-overlap view led to a higher
14 THV position and a lower rate of conduction disturbances; 2) Most importantly, guidance
15 with a transjugular ICE, which enabled a real-time visualization of MS, provided a significant
16 reduction in conduction disturbances, albeit with a comparable THV implantation depth even
17 in patients who benefited from the cusp-overlap method; and 3) Multivariable analysis also
18 showed our novel technique, adding transjugular ICE to the cusp-overlap method, was
19 independently associated with a 30-day PPI rate reduction following TAVI.

20 Self-expandable TAVI generally carries high risks for post-procedural PPI (17.4%)
21 and new-onset LBBB (25.8%).^{4,8} As TAVI indications are expanding to include younger
22 patients with a low surgical risk, these conduction disturbances relevant to long-term adverse
23 outcomes have to be promptly addressed.^{15,16} The procedural steps of balloon-expandable
24 THVs have remained identical for several years, whereas the deployment methods for
25 self-expandable THV platforms continue to improve. Recently, two important modifications
26 to the self-expandable TAVI procedure have been proposed. The first is the cusp-overlap
27 technique advocated by Tang et al. in 2018, in which the C-arm is positioned to superimpose

1 the left coronary cusp over the right coronary cusp and isolate the non-coronary cusp. The
2 conventional 3-cusps view, although popular for the implantation of THVs, provides a high
3 degree of parallax between the aortic annulus and delivery catheter with a markedly
4 foreshortened LVOT, resulting in an inaccurate deeper position of the THV. In contrast, the
5 cusp-overlap view avoids the parallax of the delivery catheter and foreshortening of the
6 LVOT, and helps the operators achieve accurate THV deployment. Indeed, in our study,
7 compared with the 3-cusps view only, the combined use of cusp-overlap view allowed a
8 higher THV position with a lower rate of new-onset 30-day PPI (7.0% vs 14.2%). This result
9 dovetails with those from the Optimize PRO study interim analysis⁵; however, the
10 persistently high PPI rate as compared with that carried by SAVR remains a concern.¹⁷ The
11 second is the pre-procedural assessment of the MS length for a risk stratification of
12 conduction disturbances following TAVI. The use of MS length as an anatomic surrogate of
13 the distance between the aortic annulus and the bundle of His was first reported by Hamdan
14 et al. in 2015,¹⁸ and many studies since then have supported its importance.^{8,19,20} In particular,
15 Jilaihawi et al. demonstrated that the approach aiming for implantation depth in relation to
16 the non-coronary cusp less than MS length achieved very low and predictable PPI rates
17 (3.0%) after self-expandable TAVI. However, in fact, the MS length may approach the
18 minimum resolution of CT, particularly in cases with shorter MS lengths, which can
19 potentially lead to measurement errors. More importantly, fluoroscopic images at the point of
20 no recapture of the device may cause us misjudge the accurate implantation depth owing to
21 the parallax between the aortic annulus and delivery catheter. Furthermore, the MS is also
22 unable to be displayed by fluoroscopy.

23 Thereupon, we introduced a transjugular ICE in November 2021 to bring the PPI
24 rate as close to zero as possible. ICE enables real-time direct visualization of the MS during
25 THV implantation, and thus the operator can adjust the landing point at the MS with a
26 repositionable THV.²¹ Although some cases showing the feasibility of ICE were recently
27 reported from Japan,²¹ no comparative study is available on the impact of ICE-guided TAVI

1 on the reduction of subsequent conduction disturbances. Our study demonstrated that the
2 combination of cusp-overlap technique and transjugular ICE provided a predictable THV
3 bottom landing in the MS and an extremely low PPI rate (0.9%) without increasing adverse
4 outcomes, such as THV dislodgement and paravalvular leakage. Of note, the novel
5 implantation method using ICE also achieved a significant reduction of PPI rate in patients
6 with baseline RBBB or short MS length, which are known factors that carry a high PPI
7 risk.^{8,22} Meanwhile, it should be recognized that high implantation may compromise the
8 feasibility of coronary access or redo TAVI. However, in this regard, the direct visualization
9 of the MS by ICE may also help avoid unnecessarily high implantation while ensuring a low
10 PPI rate, because a longer MS would provide more freedom for a deeper THV implantation
11 without necessarily affecting the conduction system. Indeed, in our study, ICE-guided TAVI
12 provided a predictable Δ MSID with low variability (**Figure 3**).

13 Anecdotal reports have shown that a supra-annular prosthetic position may provide
14 better valve hemodynamics. This may be attributed to the higher risk for valve thrombosis
15 secondary to a constrained THV frame with deeper implantation and subsequent relative
16 immobility of the THV leaflets.²³⁻²⁵ As expected, we found that the cusp-overlap technique
17 provided a higher THV position, resulting in a larger EOA and lower mean gradient at 30
18 days, compared with the conventional implantation technique using the only the 3-cusps view.
19 PPM, which is defined by the value of the EOA, was also less frequently detected in the
20 cusp-overlap group.

21

22 **Limitations**

23 First, although we used our prospective institutional database, implantation depth
24 was retrospectively assessed from post-deployment aortic angiograms. Although the
25 measurement was performed by two independent cardiologists blinded to clinical outcomes
26 to mitigate bias, the implantation technique selected could be easily identified on the
27 angiograms. Second, a bias based on the learning curve of THV implantation should also be

1 considered because of the historical controlled nature of our study. Fortunately, baseline
2 characteristics reported to be predictive for PPI, such as the MS length, prosthesis oversizing,
3 and the prevalence of pre-existing RBBB and first-degree AVB, did not significantly differ
4 between groups, whereas the procedure time and contrast volume were actually greater in the
5 conventional “3-cusps view without ICE” group. Third, our data set only included
6 information up to 30 days, and the impact of ICE-guided TAVI on longer-term clinical
7 outcomes cannot yet be discussed. Fourth, MS length is an anatomic surrogate of the His
8 bundle location, but the exact location of the His bundle may slightly differ, as has been
9 reported.²⁶ Finally, our examinations focused solely on the Evolut THV series. Theoretically,
10 TAVI with other commercially available repositionable THV is expected to benefit from ICE
11 guidance; however, further studies are necessary before applying this method to other THVs.

12

13 **Conclusions**

14 A high risk for PPI remains a concern following self-expandable TAVI despite
15 continued improvement in device and implantation methodology. Our novel method
16 combining cusp-overlap view and ICE achieved a reliably higher THV position with
17 substantial reduction in the subsequent rates of PPI and conduction disturbances without
18 compromising procedural safety and THV hemodynamics. In particular, real-time direct
19 visualization of the MS using ICE should be recognized as an important technique to improve
20 patient outcomes.

21

1 **What Is Known?**

2 A high permanent pacemaker implantation (PPI) risk remains a concern of self-expandable
3 transcatheter aortic valve implantation (TAVI), despite continued improvement of
4 implantation methodology, including cusp-overlap technique.

5
6 **What the Study Adds?**

7 Transjugular intracardiac echocardiography (ICE) enables a real-time direct visualization of
8 membranous septum. Our novel method combining cusp-overlap technique and ICE achieved
9 a reliably higher transcatheter heart valve (THV) position with substantial reduction in the
10 rates of PPI and conduction disturbances after TAVI without compromising procedural safety
11 and THV hemodynamics.

12
13 **Acknowledgments**

14 None.

15
16 **Sources of Funding**

17 None.

18
19 **Disclosures**

20 Shinichi Shirai, MD, is the proctor of transfemoral-TAVI for Edwards Lifesciences,
21 Medtronic, and Abbott Medical. The other authors have nothing to disclose.

22
23 **Supplemental Material**

24 Figures S1-S2

25

References

- 1
- 2
- 3 1. Nishimura RA, Otto CM, Bonow RO, Carabello BA, Erwin JP, Fleisher LA, Jneid H,
4 Mack MJ, McLeod CJ, O’Gara PT, et al. 2017 AHA/ACC Focused Update of the
5 2014 AHA/ACC Guideline for the Management of Patients With Valvular Heart
6 Disease. *Journal of the American College of Cardiology*. 2017;70:252-289.
- 7 2. Baumgartner H, Falk V, Bax JJ, De Bonis M, Hamm C, Holm PJ, Iung B, Lancellotti
8 P, Lansac E, Rodriguez Muñoz D, et al. 2017 ESC/EACTS Guidelines for the
9 management of valvular heart disease. *European Heart Journal*. 2017;38:2739-2791.
- 10 3. Vandvik PO, Otto CM, Siemieniuk RA, Bagur R, Guyatt GH, Lytvyn L, Whitlock R,
11 Vartdal T, Brieger D, Aertgeerts B, et al. Transcatheter or surgical aortic valve
12 replacement for patients with severe, symptomatic, aortic stenosis at low to
13 intermediate surgical risk: a clinical practice guideline. *BMJ*. 2016:i5085.
- 14 4. Popma JJ, Deeb GM, Yakubov SJ, Mumtaz M, Gada H, O’Hair D, Bajwa T, Heiser
15 JC, Merhi W, Kleiman NS, et al. Transcatheter Aortic-Valve Replacement with a
16 Self-Expanding Valve in Low-Risk Patients. *New England Journal of Medicine*.
17 2019;380:1706-1715.
- 18 5. Grubb KJ. OPTIMIZE PRO Clinical Study Interim Analysis. *Paper presented at: TVT*
19 *2021; July 21, 2021; Miami, FL*.
- 20 6. Ishizu K, Shirai S, Kawaguchi T, Taniguchi T, Hayashi M, Isotani A, Arai Y, Soga Y,
21 Kakumoto S, Ando K. Effect of Radiolucent Line-Guided Balloon-Expandable
22 Transcatheter Aortic Valve Implantation on Subsequent Pacemaker Rate. *The*
23 *American Journal of Cardiology*. 2021.
- 24 7. Ishizu K, Shirai S, Tashiro H, Kitano K, Tabata H, Nakamura M, Morofuji T,
25 Murakami N, Morinaga T, Hayashi M, et al. Prevalence and Prognostic Significance
26 of Malnutrition in Older Japanese Adults at High Surgical Risk Undergoing
27 Transcatheter Aortic Valve Implantation. *Journal of the American Heart Association*.

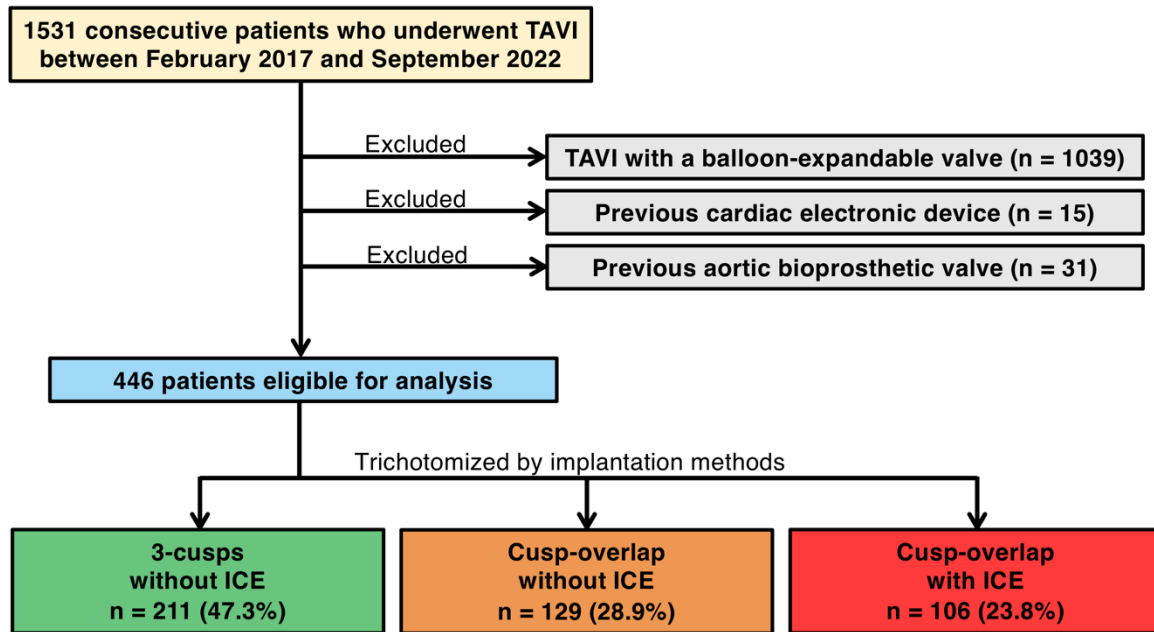
- 1 2022.
- 2 8. Jilaihawi H, Zhao Z, Du R, Staniloae C, Saric M, Neuburger PJ, Querijero M, Vainrib
3 A, Hisamoto K, Ibrahim H, et al. Minimizing Permanent Pacemaker Following
4 Repositionable Self-Expanding Transcatheter Aortic Valve Replacement. *JACC:
5 Cardiovascular Interventions*. 2019;12:1796-1807.
- 6 9. Tang GHL, Zaid S, Michev I, Ahmad H, Kaple R, Undemir C, Cohen M, Lansman SL.
7 "Cusp-Overlap" View Simplifies Fluoroscopy-Guided Implantation of
8 Self-Expanding Valve in Transcatheter Aortic Valve Replacement. *JACC Cardiovasc
9 Interv*. 2018;11:1663-1665.
- 10 10. Surawicz B, Childers R, Deal BJ, Gettes LS, Bailey JJ, Gorgels A, Hancock EW,
11 Josephson M, Kligfield P, Kors JA, et al. AHA/ACCF/HRS recommendations for the
12 standardization and interpretation of the electrocardiogram: part III: intraventricular
13 conduction disturbances: a scientific statement from the American Heart Association
14 Electrocardiography and Arrhythmias Committee, Council on Clinical Cardiology;
15 the American College of Cardiology Foundation; and the Heart Rhythm Society.
16 Endorsed by the International Society for Computerized Electrocardiology. *J Am Coll
17 Cardiol*. 2009;53:976-981.
- 18 11. Brignole M, Auricchio A, Baron-Esquivias G, Bordachar P, Boriani G, Breithardt OA,
19 Cleland J, Deharo JC, Delgado V, Elliott PM, et al. 2013 ESC Guidelines on cardiac
20 pacing and cardiac resynchronization therapy: The Task Force on cardiac pacing and
21 resynchronization therapy of the European Society of Cardiology (ESC). Developed
22 in collaboration with the European Heart Rhythm Association. *Europace*.
23 2013;15:1070-1118.
- 24 12. Généreux P, Piazza N, Alu MC, Nazif T, Hahn RT, Pibarot P, Bax JJ, Leipsic JA,
25 Blanke P, Blackstone EH, et al. Valve Academic Research Consortium 3: Updated
26 Endpoint Definitions for Aortic Valve Clinical Research. *Journal of the American
27 College of Cardiology*. 2021;77:2717-2746.

- 1 13. Ishizu K, Shirai S, Isotani A, Hayashi M, Kawaguchi T, Taniguchi T, Ando K,
2 Yashima F, Tada N, Yamawaki M, et al. Long-Term Prognostic Value of the Society of
3 Thoracic Surgery Risk Score in Patients Undergoing Transcatheter Aortic Valve
4 Implantation (From the OCEAN-TAVI Registry). *Am J Cardiol*. 2021.
- 5 14. Ludman PF, Moat N, De Belder MA, Blackman DJ, Duncan A, Banya W, Maccarthy
6 PA, Cunningham D, Wendler O, Marlee D, et al. Transcatheter Aortic Valve
7 Implantation in the United Kingdom. *Circulation*. 2015;131:1181-1190.
- 8 15. Chamandi C, Barbanti M, Munoz-Garcia A, Latib A, Nombela-Franco L,
9 Gutiérrez-Ibanez E, Veiga-Fernandez G, Cheema AN, Cruz-Gonzalez I, Serra V, et al.
10 Long-Term Outcomes in Patients With New Permanent Pacemaker Implantation
11 Following Transcatheter Aortic Valve Replacement. *JACC: Cardiovascular*
12 *Interventions*. 2018;11:301-310.
- 13 16. Nazif TM, Chen S, George I, Dizon JM, Hahn RT, Crowley A, Alu MC, Babaliaros V,
14 Thourani VH, Herrmann HC, et al. New-onset left bundle branch block after
15 transcatheter aortic valve replacement is associated with adverse long-term clinical
16 outcomes in intermediate-risk patients: an analysis from the PARTNER II trial.
17 *European Heart Journal*. 2019;40:2218-2227.
- 18 17. Mack MJ, Leon MB, Thourani VH, Makkar R, Kodali SK, Russo M, Kapadia SR,
19 Malaisrie SC, Cohen DJ, Pibarot P, et al. Transcatheter Aortic-Valve Replacement
20 with a Balloon-Expandable Valve in Low-Risk Patients. *N Engl J Med*.
21 2019;380:1695-1705.
- 22 18. Hamdan A, Guetta V, Klempfner R, Konen E, Raanani E, Glikson M, Goitein O,
23 Segev A, Barbash I, Fefer P, et al. Inverse Relationship Between Membranous Septal
24 Length and the Risk of Atrioventricular Block in Patients Undergoing Transcatheter
25 Aortic Valve Implantation. *JACC Cardiovasc Interv*. 2015;8:1218-1228.
- 26 19. Maeno Y, Abramowitz Y, Kawamori H, Kazuno Y, Kubo S, Takahashi N, Mangat G,
27 Okuyama K, Kashif M, Chakravarty T, et al. A Highly Predictive Risk Model for

- 1 Pacemaker Implantation After TAVR. *JACC Cardiovasc Imaging*.
2 2017;10:1139-1147.
- 3 20. Ishizu K, Murakami N, Morinaga T, Hayashi M, Isotani A, Arai Y, Ohno N,
4 Kakumoto S, Shirai S, Ando K. Impact of tapered-shape left ventricular outflow tract
5 on pacemaker rate after transcatheter aortic valve replacement. *Heart and Vessels*.
6 2022.
- 7 21. Miyamoto J, Ohno Y, Sakai K, Murakami T, Horinouchi H, Hasegawa M, Natsumeda
8 M, Torii S, Okada K, Cho Y, et al. Novel Strategy for Patients With Pre-Existing
9 Right Bundle Branch Block. *JACC: Cardiovascular Interventions*.
10 2020;13:2184-2185.
- 11 22. Kiani S, Kamioka N, Black GB, Lu MLR, Lisko JC, Rao B, Mengistu A, Gleason PT,
12 Stewart JP, Caughron H, et al. Development of a Risk Score to Predict New
13 Pacemaker Implantation After Transcatheter Aortic Valve Replacement. *JACC:
14 Cardiovascular Interventions*. 2019;12:2133-2142.
- 15 23. Philip F, Dinh H, Ko J, Chow MI, Huh J. Valve Thrombosis After Transcatheter
16 Aortic Valve Replacement. *J Am Coll Cardiol*. 2017;69:1649-1650.
- 17 24. Midha PA, Raghav V, Sharma R, Condado JF, Okafor IU, Rami T, Kumar G,
18 Thourani VH, Jilaihawi H, Babaliaros V, et al. The Fluid Mechanics of Transcatheter
19 Heart Valve Leaflet Thrombosis in the Neosinus. *Circulation*. 2017;136:1598-1609.
- 20 25. Makkar RR, Fontana G, Jilaihawi H, Chakravarty T, Kofoed KF, De Backer O, Asch
21 FM, Ruiz CE, Olsen NT, Trento A, et al. Possible Subclinical Leaflet Thrombosis in
22 Bioprosthetic Aortic Valves. *New England Journal of Medicine*. 2015;373:2015-2024.
- 23 26. Kawashima T, Sato F. Visualizing anatomical evidences on atrioventricular
24 conduction system for TAVI. *Int J Cardiol*. 2014;174:1-6.
25

1 Figure legends

2 Figure 1. Study Flowchart

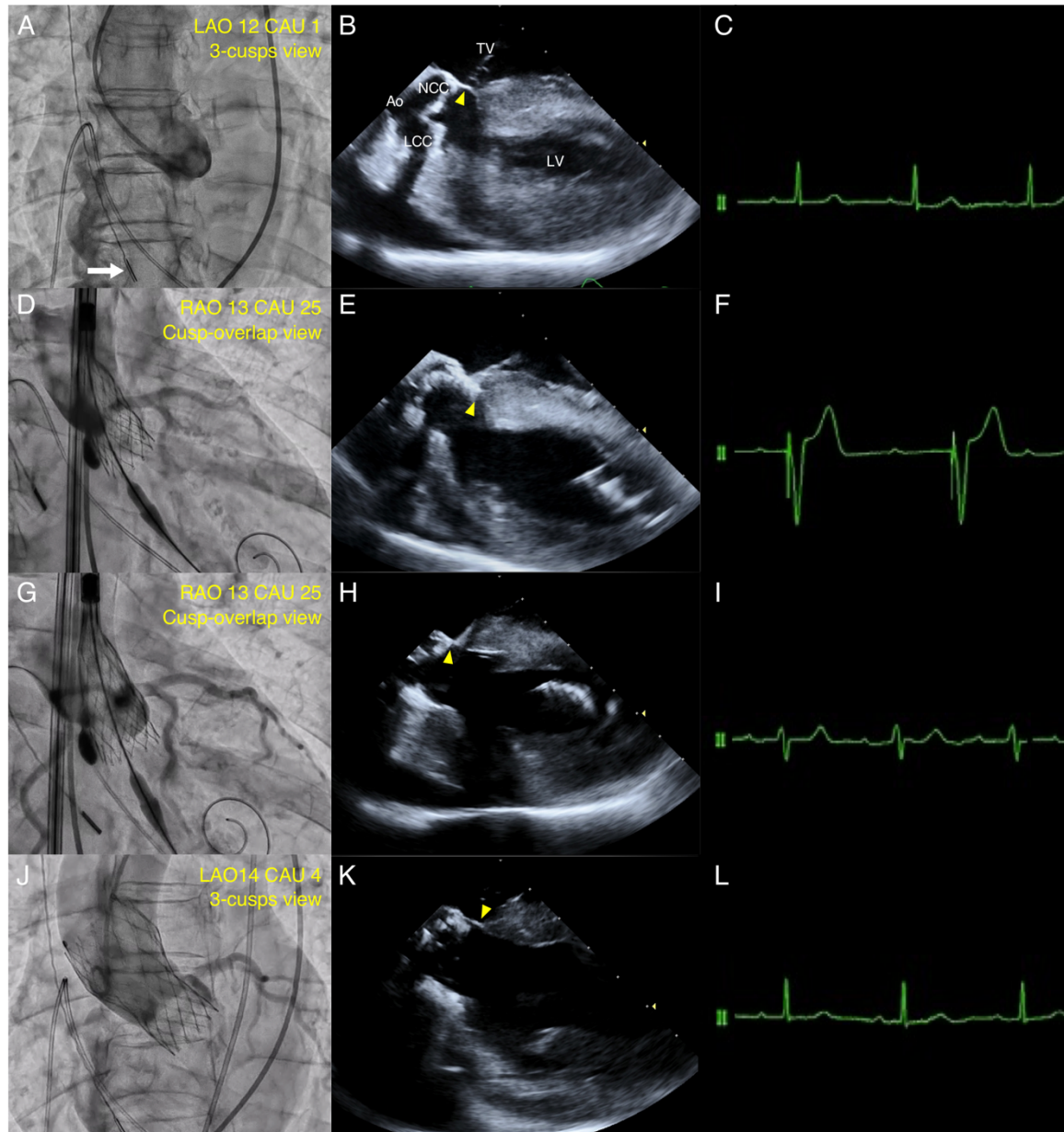


3 The flowchart provides information about the included and excluded patients.

4 ICE = intracardiac echocardiography; TAVI = transcatheter aortic valve implantation

5

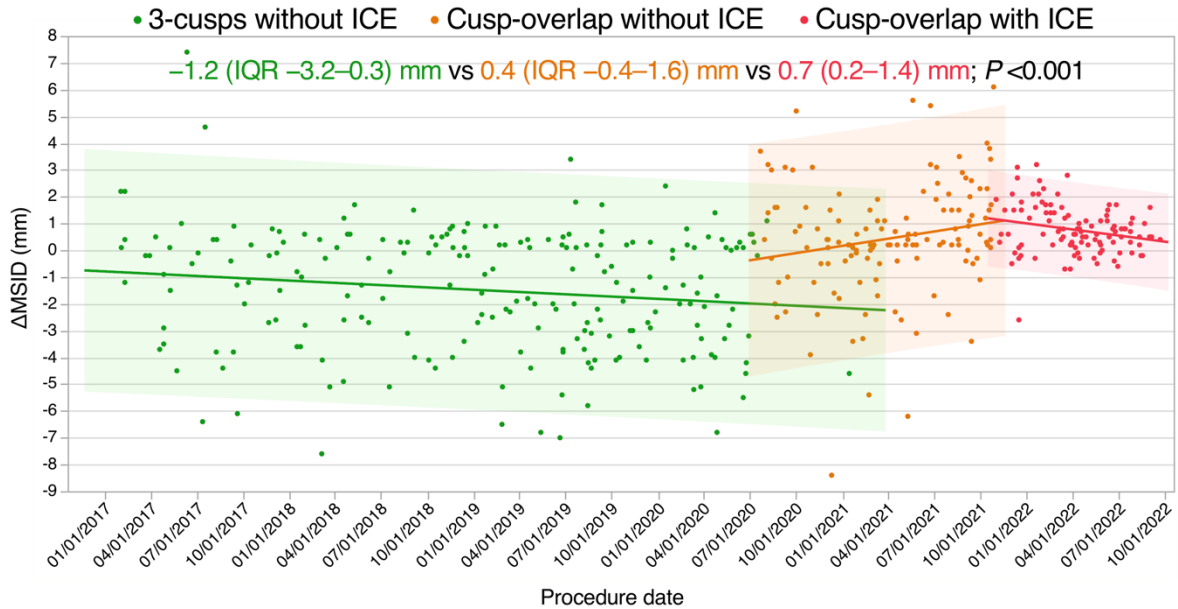
1 Figure 2. Real-Time Direct Visualization of Membranous Septum with Intracardiac 2 Echocardiography



- 3 (A) The 3-cusps coplanar angle was angiographically modified during the procedure. The
4 white arrow indicates the position of intracardiac echocardiography (ICE) catheter. (B)
5 Baseline ICE enabled direct visualization of membranous septum (MS) (yellow arrowhead).
6 (C) Baseline electrocardiogram showing sinus rhythm with narrow QRS. (D) At the first
7 attempt to deploy a 23-mm Evolut PRO+ to the point of no recapture in the cusp-overlap
8 view, (E) ICE showed the bottom of transcatheter heart valve (THV) located at a deeper

1 position than MS (yellow arrowhead), and (F) electrocardiogram showed complete
2 atrioventricular block. (G) At the second attempt to the point of no recapture, (H) ICE
3 showed the optimal THV landing in the MS (yellow arrowhead), and (I) electrocardiogram
4 showed recovery of sinus rhythm with left bundle branch block (LBBB). (J) Final
5 angiography showed trivial paravalvular leakage with the depth of 2 mm, and (K) ICE
6 showed the bottom of MS remained intact (yellow arrowhead). (L) By the end of the
7 procedure, electrocardiogram showed recovery from LBBB. Ao = aorta; LCC = left coronary
8 cusp; LV = left ventricle; NCC = non-coronary cusp; TV = tricuspid valve.
9

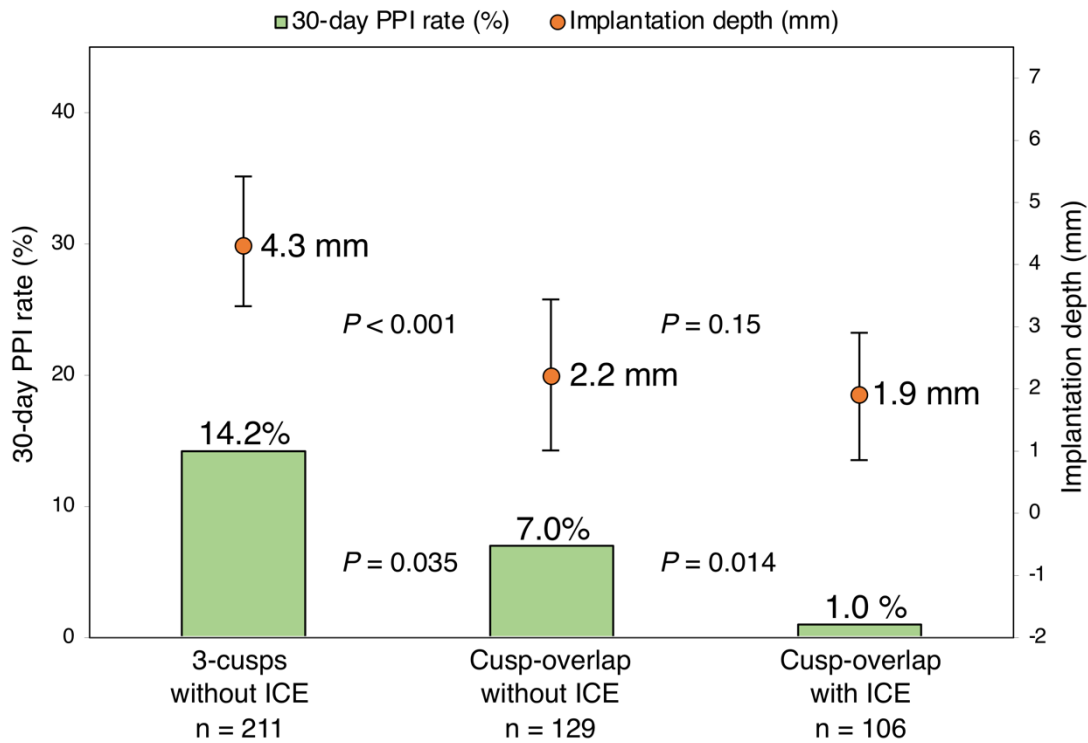
1 **Figure 3. Temporal Trends of the Difference Between Membranous Septum Length and**
2 **Implantation Depth (Δ MSID) with Each Technique**



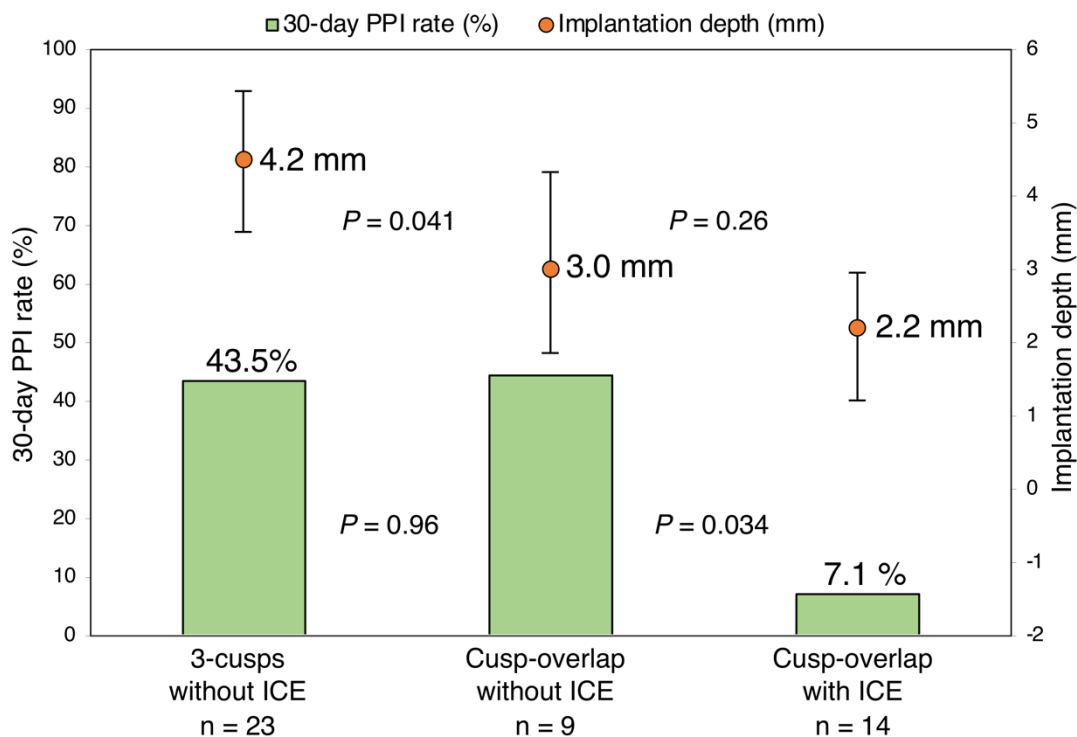
3 Filled circles indicate the final implantation depths in millimeters according to the timing of
4 procedure. Bold lines represent the regression lines of temporal trends of median
5 implantation depth. ICE = intracardiac echocardiography.
6

1 **Figure 4. Implantation Depths and New-Onset Permanent Pacemaker Implantation**
 2 **(PPI) Rates for Each Implantation Method**

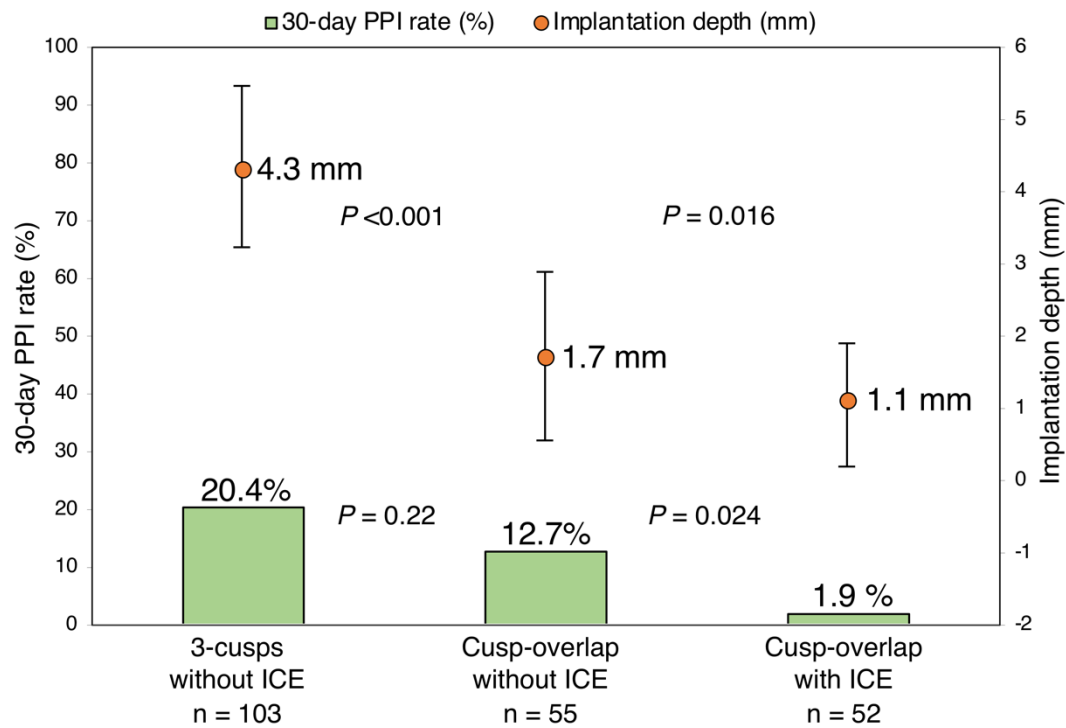
A. Entire cohort



B. Baseline RBBB



C. MS length < 2.5 mm



- 1 The orange dots show implantation depth. The green columns show the rates of new-onset
- 2 30-day PPI in the entire cohort (A), in those with right bundle branch block (RBBB) (B), and
- 3 in those with membranous septum (MS) length < 2.5 mm (C). The error bars indicate the
- 4 interquartile range. ICE = intracardiac echocardiography
- 5

1 **Tables**

2 **Table 1. Baseline Characteristics**

| | Implantation methods | | | <i>P</i> value |
|---------------------------------|-------------------------------------|--|---------------------------------------|-------------------|
| | 3-cusps without ICE (N = 211) | Cusp-overlap without ICE (N = 129) | Cusp-overlap with ICE (N = 106) | |
| Demographics | | | | |
| Age, years | 86 (82–89) | 85 (81–88) | 85 (81–89) | 0.540 |
| Male | 40 (19.0) | 39 (30.2) | 29 (27.4) | 0.042 |
| BMI, kg/m ² | 21.4 (19.6–23.7) | 22.1 (19.9–24.8) | 21.2 (18.9–24.4) | 0.187 |
| Clinical Frailty Scale \geq 4 | 90 (42.7) | 53 (41.1) | 52 (49.1) | 0.431 |
| NYHA functional class III/IV | 72 (34.1) | 35 (27.1) | 32 (30.2) | 0.387 |
| STS risk score, % | 6.1 (4.1–9.4) | 4.7 (3.5–7.0) | 5.0 (3.7–7.1) | 0.001 |
| Comorbidities | | | | |
| Hypertension | 174 (86.5) | 102 (79.1) | 87 (82.1) | 0.726 |
| Dyslipidemia | 102 (48.3) | 69 (53.5) | 52 (49.1) | 0.638 |
| Diabetes | 39 (18.5) | 33 (25.6) | 28 (26.4) | 0.164 |

| | | | | |
|----------------------------------|------------------|------------------|------------------|--------|
| Atrial fibrillation | 40 (19.0) | 31 (24.0) | 20 (18.9) | 0.488 |
| Coronary artery disease | 46 (21.8) | 65 (50.4) | 40 (37.7) | <0.001 |
| Previous coronary bypass | 4 (1.9) | 3 (2.3) | 1 (0.9) | 0.695 |
| Peripheral artery disease | 13 (6.2) | 11 (8.5) | 11 (10.4) | 0.401 |
| Chronic kidney disease | 133 (63.0) | 87 (67.4) | 73 (68.9) | 0.519 |
| Chronic pulmonary disease | 21 (10.0) | 13 (10.2) | 11 (10.4) | 0.993 |
| Cerebrovascular disease | 20 (89.5) | 10 (7.8) | 9 (8.5) | 0.855 |
| Active cancer | 10 (4.7) | 8 (6.2) | 4 (3.8) | 0.685 |
| Electrocardiographic data | | | | |
| Persistent AF | 20 (9.5) | 16 (12.4) | 12 (11.3) | 0.685 |
| PQ interval, ms * | 176 (158–198) | 174 (155–194) | 173 (158–196) | 0.920 |
| First-degree AVB * | 44 (23.0) | 22 (19.5) | 20 (21.3) | 0.761 |
| QRS duration, ms | 92 (86–102) | 92 (84–100) | 91 (86–105) | 0.564 |
| LBBB | 9 (4.3) | 2 (1.6) | 3 (2.8) | 0.343 |
| RBBB | 23 (10.9) | 9 (7.0) | 14 (13.2) | 0.259 |
| Echocardiographic data | | | | |
| AVA, cm ² | 0.62 (0.50–0.71) | 0.63 (0.52–0.73) | 0.60 (0.49–0.74) | 0.091 |

| | | | | |
|--|---------------------|---------------------|---------------------|-------|
| Indexed AVA, cm ² /m ² | 0.47 (0.40–0.50) | 0.44 (0.38–0.53) | 0.44 (0.32–0.52) | 0.448 |
| Mean aortic gradient, mmHg | 54.2 (41.0–69.9) | 51.1 (38.8–64.7) | 53.2 (41.5–70.3) | 0.083 |
| LVEF, % | 63.4 (59.9–66.0) | 63.1 (57.6–65.5) | 63.0 (56.7–66.4) | 0.319 |
| AR ≥ moderate | 6 (2.8) | 4 (3.1) | 9 (8.5) | 0.071 |
| MR ≥ moderate | 10 (4.7) | 8 (6.2) | 9 (8.5) | 0.431 |
| TR ≥ moderate | 4 (1.9) | 6 (4.7) | 8 (7.6) | 0.050 |
| SPAP, mmHg | 31.0 (26.0–37.5) | 31.0 (28.0–39.0) | 32.0 (26.6–38.1) | 0.436 |
| MDCT data | | | | |
| Annulus area, mm ² | 375.6 (340.2–425.0) | 386.9 (341.8–442.0) | 374.0 (329.2–427.2) | 0.094 |
| Annulus perimeter, mm | 69.6 (66.1–74.6) | 70.6 (67.3–75.9) | 70.7 (66.0–76.0) | 0.128 |
| LVOT area, mm ² | 353.3 (301.9–426.4) | 369.2 (319.6–428.3) | 356.0 (300.7–440.7) | 0.117 |
| STJ height, mm | 18.0 (16.1–19.6) | 18.1 (16.5–20.1) | 17.9 (16.3–20.0) | 0.717 |
| STJ diameter, mm | 24.1 (22.5–26.0) | 24.3 (22.7–27.0) | 24.3 (22.9–26.2) | 0.293 |
| Mean SOV diameter, mm | 28.5 (27.1–30.2) | 29.2 (27.2–31.3) | 28.5 (27.5–30.9) | 0.144 |
| LCA height, mm | 13.3 (11.9–14.6) | 13.4 (11.9–14.9) | 13.6 (12.1–14.7) | 0.222 |
| RCA height, mm | 14.5 (12.6–16.4) | 14.9 (12.8–17.3) | 13.9 (12.5–16.1) | 0.152 |
| LVOT calcification ≥ moderate | 21 (10.0) | 15 (11.6) | 10 (9.4) | 0.838 |

MS length, mm

2.5 (1.7–3.6)

2.7 (1.9–3.5)

2.5 (1.8–3.2)

0.824

- 1 Values are n (%) or median (interquartile range). * Patients with persistent atrial fibrillation were excluded.
- 2 AF = atrial fibrillation; AR = aortic regurgitation; AVA = aortic valve area; BMI = body mass index; LBBB = left bundle branch block; LCA =
- 3 left coronary artery; ICE = intracardiac echocardiography; LVEF = left ventricular ejection fraction; LVOT = left ventricular outflow tract;
- 4 MDCT = multidetector computed tomography; MR = mitral regurgitation; MS = membranous septum; NYHA = New York Heart Association;
- 5 RBBB = right bundle branch block; RCA = right coronary artery; SOV = sinus of Valsalva; SPAP = systolic pulmonary artery pressure; STJ =
- 6 sinotubular junction; STS = Society of Thoracic Surgeons; TR = tricuspid regurgitation.
- 7

1 **Table 2. Procedural Characteristics**

| | Implantation methods | | | <i>P</i> value |
|----------------------------|-------------------------------------|--|---------------------------------------|-------------------|
| | 3-cusps without ICE (N = 211) | Cusp-overlap without ICE (N = 129) | Cusp-overlap with ICE (N = 106) | |
| | Local anesthesia | 151 (71.6) | 113 (87.6) | |
| Access site | | | | |
| Transfemoral | 188 (89.1) | 123 (95.4) | 100 (94.3) | 0.070 |
| Alternative | 23 (10.9) | 6 (4.7) | 6 (5.7) | |
| Prosthesis size | | | | |
| 23 mm | 35 (16.6) | 21 (16.3) | 19 (17.9) | 0.167 |
| 26 mm | 124 (58.8) | 80 (62.0) | 63 (59.4) | |
| 29 mm | 52 (24.6) | 26 (20.2) | 20 (18.9) | |
| 34 mm | 0 (0) | 2 (1.6) | 4 (3.8) | |
| Oversizing by perimeter, % | 17.4 (13.0–20.3) | 16.8 (12.8–20.7) | 16.5 (12.5–20.6) | 0.283 |
| Pre-dilatation | 206 (97.6) | 128 (99.2) | 105 (99.1) | 0.434 |
| Post-dilatation | 41 (19.4) | 31 (24.0) | 20 (18.9) | 0.523 |

| | | | | |
|---------------------|---------------|------------|------------|--------|
| Procedure time, min | 60 (51–76) | 49 (43–61) | 49 (42–60) | <0.001 |
| Contrast volume, ml | 141 (110–174) | 80 (68–93) | 73 (60–88) | <0.001 |

- 1 Values are n (%) or median (interquartile range).
- 2 ICE = intracardiac echocardiography.

1 **Table 3. Clinical Outcomes**

| | Implantation methods | | | <i>P</i> value |
|---|--------------------------|--------------------------|-----------------------|-------------------|
| | 3-cusps | Cusp-overlap | Cusp-overlap | |
| | without ICE (N = 211) | without ICE (N = 129) | with ICE (N = 106) | |
| Implantation depth, mm | 4.3 (3.3–5.4) | 2.2 (1.0–3.5) | 1.9 (0.9–2.9) | <0.001 |
| ΔMSID, mm | -1.2 (-3.2–0.3) | 0.4 (-0.4–1.6) | 0.7 (0.2–1.4) | <0.001 |
| Technical success | 203 (96.2) | 128 (99.2) | 106 (100) | 0.016 |
| Device Success | 189 (89.6) | 122 (94.6) | 103 (97.2) | 0.024 |
| Conversion to open surgery | 3 (1.4) | 1 (0.8) | 0 (0) | 0.289 |
| Valve dislodgement | 3 (1.4) | 0 (0) | 0 (0) | 0.105 |
| Need for 2 nd valve implantation | 3 (1.4) | 1 (0.8) | 0 (0) | 0.289 |
| Coronary obstruction | 3 (1.4) | 0 (0) | 0 (0) | 0.105 |
| Stroke with disability | 4 (1.9) | 4 (3.1) | 0 (0) | 0.087 |
| Type 3 and Type 4 bleeding | 8 (3.8) | 3 (2.3) | 0 (0) | 0.036 |
| Major vascular and access-related complications | 12 (5.7) | 4 (3.1) | 3 (2.8) | 0.363 |
| Length of hospital stay after TAVI, day | 9 (6–13) | 8 (6–11) | 7 (5–11) | 0.042 |

| | | | | |
|------------------|---------|---------|-------|-------|
| 30-day mortality | 3 (1.4) | 2 (1.6) | 0 (0) | 0.254 |
|------------------|---------|---------|-------|-------|

- 1 Values are n (%) or median (interquartile range).
- 2 Δ MSID = difference between membranous septum length and implantation depth; ICE = intracardiac echocardiography; TAVI = transcatheter
- 3 aortic valve implantation.

1 **Table 4. New-Onset Conduction Abnormalities and Indications for Pacemaker Implantation**

| | Implantation methods | | | <i>P</i> value |
|--------------------------------|-------------------------------------|--|---------------------------------------|-------------------|
| | 3-cusps without ICE (N = 211) | Cusp-overlap without ICE (N = 129) | Cusp-overlap with ICE (N = 106) | |
| | 30-day PPI | 30 (14.2) | 9 (7.0) | |
| For advanced second-degree AVB | 2 (0.9) | 1 (0.8) | 0 (0) | 0.613 |
| For complete AVB | 28 (13.3) | 8 (6.2) | 1 (0.9) | <0.001 |
| New-onset LBBB | 83 (39.3) | 32 (24.8) | 26 (24.5) | 0.004 |
| Transient | 37 (17.5) | 16 (12.4) | 22 (20.8) | 0.209 |
| Persistent | 46 (21.8) | 16 (12.4) | 4 (3.8) | <0.001 |

2 Values are n (%).

3 AVB = atrioventricular block; ICE = intracardiac echocardiography; LBBB = left bundle branch block; PPI = permanent pacemaker
4 implantation.

5

1 **Table 5. Predictors of Permanent Pacemaker Requirement at 30 days**

| | Univariate Analysis | | | Multivariable Analysis | | |
|---|---------------------|------------|----------------|------------------------|------------|----------------|
| | HR | 95% CI | <i>P</i> value | HR | 95% CI | <i>P</i> value |
| Implantation methods | | | | | | |
| 3-cusps without ICE | 2.21 | 1.01–4.82 | 0.046 | 1.53 | 0.65–3.64 | 0.332 |
| Cusp-overlap without ICE | ... | ... | Reference | ... | ... | Reference |
| Cusp-overlap with ICE | 0.13 | 0.02–0.79 | 0.025 | 0.07 | 0.01–0.64 | 0.018 |
| Adjusting factors | | | | | | |
| Age (per 10 years increase) | 1.30 | 0.70–2.42 | 0.402 | ... | ... | ... |
| Male gender | 0.64 | 0.27–1.49 | 0.283 | ... | ... | ... |
| BMI (per 1 kg/m ² increase) | 0.97 | 0.89–1.07 | 0.567 | ... | ... | ... |
| STS score ≥ 8% | 1.72 | 0.86–3.42 | 0.125 | ... | ... | ... |
| Baseline RBBB | 7.26 | 3.47–15.17 | <0.001 | 8.61 | 3.49–21.24 | <0.001 |
| Baseline first-degree AVB | 1.86 | 0.89–3.88 | 0.097 | 1.77 | 0.75–4.17 | 0.190 |
| Oversizing by perimeter (per 10% increase) | 1.03 | 0.89–1.19 | 0.725 | ... | ... | ... |
| LVOT area (per 10 mm ² decrease) | 1.03 | 0.99–1.07 | 0.085 | 1.02 | 0.98–1.06 | 0.273 |
| MS length (per 1 mm decrease) | 1.98 | 1.44–2.71 | <0.001 | 1.82 | 1.30–2.54 | <0.001 |
| Pre-dilatation | 0.54 | 0.15–1.92 | 0.372 | ... | ... | ... |
| Post-dilatation | 2.49 | 0.90–6.88 | 0.101 | ... | ... | ... |

2 AVB = atrioventricular block; CI = confidence interval; BMI = body mass index; HR =
3 hazard ratio; ICE = intracardiac echocardiography; LVOT = left ventricular outflow tract; MS
4 = membranous septum; RBBB = right bundle branch block; STS = Society of Thoracic
5 Surgery.

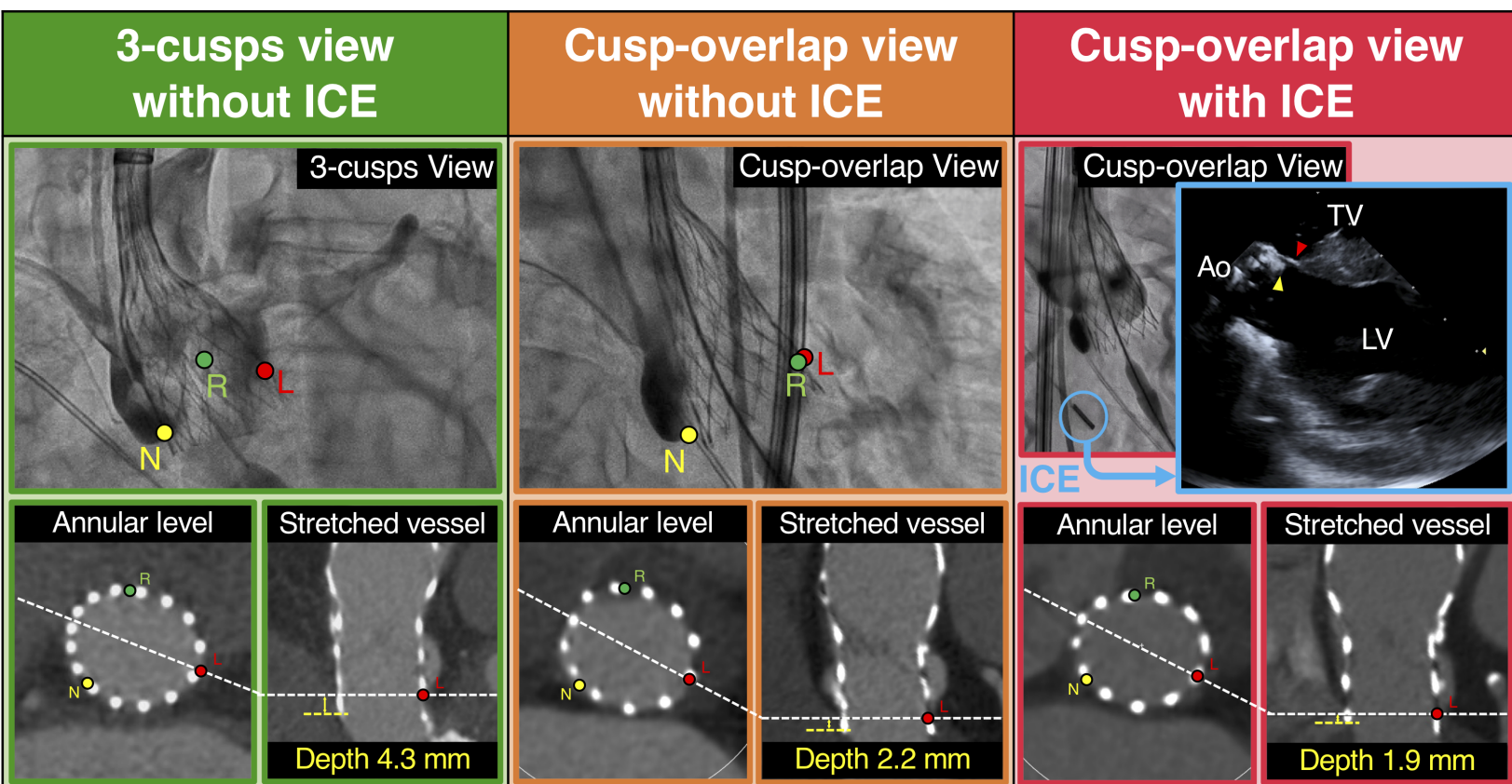
1 **Table 6. Echocardiographic Outcomes**

| | Implantation methods | | | <i>P</i> value |
|------------------------------|--------------------------|--------------------------|-----------------------|-------------------|
| | 3-cusps | Cusp-overlap | Cusp-overlap | |
| | without ICE (N = 211) | without ICE (N = 129) | with ICE (N = 106) | |
| EOA, cm ² | 1.77 (1.50-2.03) | 1.97 (1.68-2.26) | 1.93 (1.63-2.22) | <0.001 |
| Indexed EOA, cm ² | 1.29 (1.06-1.48) | 1.34 (1.18-1.56) | 1.33 (1.16-1.55) | 0.013 |
| PPM | 12 (5.7) | 2 (1.6) | 1 (0.9) | 0.027 |
| Moderate PPM | 11 (5.2) | 2 (1.6) | 1 (0.9) | 0.047 |
| Severe PPM | 1 (0.5) | 0 | 0 | 0.473 |
| Mean gradient, mmHg | 10.3 (8.1-12.7) | 9.3 (6.6-11.3) | 9.3 (7.4-12.4) | 0.015 |
| LVEF, % | 63.0 (59.6-65.7) | 62.9 (58.6-65.1) | 63.2 (57.1-66.5) | 0.482 |
| Mild AR | 120 (56.9) | 68 (52.7) | 58 (54.7) | 0.703 |
| Moderate to severe AR | 1 (0.5) | 1 (0.8) | 1 (0.9) | 0.878 |

2 Values are n (%) or median (interquartile range).

3 AR = aortic regurgitation; EOA = effective orifice area; ICE = intracardiac echocardiography; LVEF = left ventricular ejection fraction; PPM =

4 prosthesis-patient mismatch.



| Implantation Depth | | |
|---|--------------------------------------|--------------------------------------|
| 4.3 (IQR 3.3–5.4) mm | 2.2 (IQR 1.0–3.5) mm | 1.9 (IQR 0.9–2.9) mm |
| 30-day Permanent Pacemaker Implantation | | |
| 14.2% | 7.0% | 0.9% |
| New-onset Left Bundle Branch Block at Discharge | | |
| 21.8% | 12.4% | 3.8% |
| 30-day Aortic Regurgitation $\geq 2+$ | | |
| 0.5% | 0.8% | 0.9% |
| 30-day Effective Orifice Area | | |
| 1.77 (IQR 1.50–2.03) cm ² | 1.97 (IQR 1.68–2.26) cm ² | 1.93 (IQR 1.63–2.22) cm ² |

Ao = aorta; ICE = intracardiac echocardiography; LV = left ventricle; TV = tricuspid valve