

1 **Non-invasive identification of slow conducting anatomical isthmuses in**
2 **patients with tetralogy of Fallot by 3D late gadolinium enhancement**
3 **cardiovascular magnetic resonance imaging**

4

5 Yoshitaka Kimura, MD, PhD^{1,2}, Justin Wallet, MD^{1,2}, Monique R M Jongbloed, MD, PHD^{1,3}, Nico A.
6 Blom, MD, PhD⁴, Robin Bertels, MD⁴, Hildo J.Lamb, MD, PhD⁵, and Katja Zeppenfeld, MD, PhD^{1,2*}

7

8 ¹Department of Cardiology, Heart-Lung-Centre, Leiden University Medical Center, Leiden, The
9 Netherlands

10 ²Willem Einthoven Center of Arrhythmia Research and Management (WECAM), Leiden, The
11 Netherlands and Aarhus, Denmark

12 ³Department of Anatomy & Embryology, Leiden University Medical Centre, Leiden, The Netherlands

13 ⁴Department of Pediatric Cardiology, and ⁵Department of Radiology, Leiden University Medical
14 Center, Leiden, The Netherlands

15

16 **Word count:** 3958 words (main text)

17 **Short title:** Kimura et al., identification of SCAI in rTOF by 3D LGE-CMR

18

19 **E-mail: Address for correspondence:**

20 K. Zeppenfeld, MD, PhD

21 Leiden University Medical Center

22 Department of Cardiology (C-05-P)

23 P.O. Box 9600

24 2300 RC Leiden

25 Telephone: +31715262020

1 **Abstract**

2 Background:

3 Patients with repaired tetralogy of Fallot (rTOF) remain at risk of sustained monomorphic ventricular
4 tachycardia (SMVT) related to slow-conducting anatomical isthmuses (SCAI). Invasive
5 electroanatomical mapping (EAM) is the only available method to identify SCAI (SCAI_{EAM}). We aimed
6 to determine rTOF-specific high signal intensity threshold values (HSI_t) to identify abnormal
7 myocardium by 3D late gadolinium enhancement cardiac magnetic resonance (LGE-CMR) and assess
8 the performance of LGE-CMR to non-invasively identify SCAI_{EAM}.

9

10 Methods:

11 Consecutive rTOF patients who underwent right ventricular EAM (RV-EAM) and 3D LGE-CMR were
12 included (2012-2021). A SCAI_{EAM} was defined as an anatomical isthmus (AI) with conduction velocity
13 (CV) <0.5 m/s. LGE-CMR-derived 3D RV reconstructions were merged with 3D RV-EAM data. The HSI_t
14 was determined based on the comparison of local bipolar voltages (BV) and the corresponding local
15 SI using ROC analysis. An abnormal AI on LGE-CMR (Abnormal AI_{CMR}) was defined as AI showing
16 continuous high SI (>HSI_t) between anatomical boundaries.

17

18 Results

19 Forty-eight rTOF patients (34±16 years, 58% male) were included. Of 107 AIs on EAM (AI1 and 3 in all,
20 AI2 in 11), 78 were normal-conducting AI_{EAM} (NCAI_{EAM}), 22 were SCAI_{EAM} (SCAI_{EAM}2 in 2 and SCAI_{EAM}3
21 in 20), and 7 were blocked AI_{EAM}3. All 14 induced SMVTs were related to SCAI_{EAM}3. A total of 9240
22 EAM points were analyzed. HSI_t was 42% of the maximal SI (AUC 0.80; sensitivity, 74%; specificity,
23 78%). On 3D-CMR RV construction, all 29 SCAI_{EAM} or Blocked AI_{EAM} were identified as abnormal AI_{CMR}.
24 Among the 78 NCAI_{EAM}, 70 were normal AI_{CMR} and 8 were abnormal AI_{CMR}. The sensitivity and
25 specificity of 3D LGE-CMR for identifying SCAI_{EAM} or blocked AI_{EAM} were 100% and 90% (29/29 and

1 70/78), respectively. Among patients with $NCAI_{EAM3}$ (n=28), those with abnormal AI_{CMR3} (n=6) had
2 significantly lower BV and slower CV compared with those with normal AI_{CMR3} (n=22) (BV, 1.91 [1.62-
3 2.60] vs. 3.45 mV [2.22-5.67]; CV, 0.69 [0.62-0.81] vs, 0.95 m/s [0.82-1.09]; both $P < 0.01$).

4

5 Conclusion:

6 3D LGE-CMR can identify SCAI with excellent sensitivity and specificity and may identify diseased AI3
7 even before critical conduction delay occurs, which may enable non-invasive risk stratification of VT
8 and may refine patient selection for invasive EAM.

9

1 ***What is new?***

- 2 • rTOF-specific high signal intensity threshold (HSI_t) value on 3D LGE-CMR to identify abnormal
3 myocardium was determined by direct comparison between 9240 superimposed 3D EAM
4 points and corresponding local signal intensity on the 3D CMR-derived reconstruction.
- 5 • The newly proposed method of CMR image analysis using the obtained HSI_t showed an
6 excellent interobserver agreement and could identify SCAI or blocked AI with 100%
7 sensitivity and 90% specificity.
- 8 • Compared to patients with NCAI_{EAM} and normal AI_{CMR} (true negative CMR), those with
9 NCAI_{EAM} but abnormal AI_{CMR} (false positive CMR) had already significantly lower BV and CV
10 on EAM.

11

12 ***What are the clinical implications?***

- 13 • The newly proposed technique of 3D LGE-CMR image analysis may allow for non-invasive
14 and serial risk stratification of VT in patients with rTOF and can refine patient selection for
15 invasive EAM and concomitant ablation.

16

1 **Background**

2 Advances in surgical repair and medical treatment have improved survival in patients with tetralogy
3 of Fallot (TOF).^{1, 2} While fewer patients die from perioperative events and early heart failure, the risk
4 of sudden cardiac death (SCD) due to sustained monomorphic ventricular tachycardia (SMVT)
5 remains of concern. Identification of a repaired TOF (rTOF) patient at risk for ventricular tachycardia
6 (VT) and SCD is challenging.

7 The vast majority of documented ventricular arrhythmias in rTOF are SMVT due to reentry.
8 The critical component of the reentry circuits is typically located within anatomically defined
9 isthmuses (AI) bordered by unexcitable structures such as surgical scars, patches, and valve annuli.
10 While AI is present in almost all rTOF patients, only those with slow-conducting properties during
11 baseline rhythm (slow conducting AI (SCAI)) are arrhythmogenic and play a key role for re-entry
12 SMVT.³⁻⁶ SCAI is invasively defined by a reduced conduction velocity (CV) of <0.5m/s during SR or
13 pacing⁵ determined by electroanatomical mapping (EAM) and often shows reduced bipolar voltages
14 (BV) consistent with diseased myocardium.^{5, 7} Patients without SCAI or after successful transection of
15 SCAI by catheter ablation have excellent VT-free survival,⁸ while patients with a SCAI not successfully
16 ablated or not targeted are at high risk for VT. Currently, identification of SCAI requires invasive EAM.
17 As slow conduction may develop over time, repeated mapping studies may be required.

18 Compared to two-dimensional (2D) LGE-CMR, 3D LGE-CMR allows accurate visualization of
19 morphologically complex parts of the heart such as the RV outflow tract (RVOT) with high-spatial
20 resolution⁹ and has been compared with voltage mapping in a small series of rTOF patients.¹⁰
21 However, noninvasive identification of SCAI, as VT substrate in rTOF by LGE-CMR, has not been
22 achieved but may significantly contribute to individualized risk stratification and non-invasive follow-
23 up.

1 In the present study, we aimed to (1) determine rTOF-specific signal intensity threshold
2 values to identify abnormal myocardium by 3D registration of LGE-CMR and EAM and (2) assess the
3 performance of 3D LGE-CMR to non-invasively identify SCAI.

4

5 **Methods**

6 ***Patients selection and baseline evaluation***

7 Consecutive patients with rTOF who underwent detailed RV EAM and 3D LGE-CMR between
8 September 2012 and December 2021 at the Leiden University Medical Center (LUMC) were included.
9 EAM was performed before ablation in patients presenting with VT or out-of-hospital cardiac arrest
10 (OHCA), prior to planned surgical pulmonary valve replacement (PVR), or as part of risk stratification
11 according to our standard clinical protocol.⁵ All patients provided informed consent for the
12 procedure. The protocol applies to the Declaration of Helsinki and was approved by the internal
13 review board of the cardiology department in the LUMC. The medisch-ethische toetsingscommissie
14 (METC Leiden Den Haag Delft) waived the need for written informed consent, as all data were
15 acquired according to routine clinical care (G21.137).

16 A comprehensive clinical evaluation was performed before the EAM. Medical records were
17 reviewed for the details of prior surgeries and for the documentation of non-sustained and
18 sustained VA on 12-lead electrocardiograms (ECGs), Holter recordings, or stored electrograms from
19 intracardiac implantable devices. QRS duration, morphology, and fragmented QRS (FQRS) were
20 assessed by standard 12-lead ECG recorded at 25 mm/s in non-paced rhythm. FQRS was defined as
21 previously described¹¹ and analyzed by two observers blinded to patient characteristics and clinical
22 data. In cases of a discrepancy between the two observers, a consensus was established by a third
23 observer.

24 Biventricular systolic function and pulmonary valve insufficiency were measured by CMR.
25 The left and right ventricular functions were classified as severely reduced (<30%), moderately

1 reduced (30% to 39%), mildly reduced (40% to 54%), or good ($\geq 55\%$).⁸ LV diastolic dysfunction
2 (LVDD) was assessed by transthoracic echocardiography and defined as mitral lateral e' < 10 cm/s
3 and E/e' ratio ≥ 9 as previously described.^{12, 13} A previously suggested risk score to predict the
4 annualized rates of VT published in 2008 (hereafter, risk score 2008) was calculated for each
5 patient.¹⁴ Briefly, risk score 2008 consists of the following 6 parameters; prior palliative shunt (2
6 points), inducible sustained VT (2 points), QRS duration ≥ 180 ms (1 point), ventriculotomy incision (2
7 points), NSVT (2 points), and elevated LV end-diastolic pressure (LVEDP) (3 points). Patients were
8 categorized into 3 groups, low (0-2 points), intermediate (3-5 points), and high-risk (6-12 points).¹⁴
9 Because of the low availability of directly measured LVEDP, LVDD was considered as elevated
10 LVEDP.^{12, 13}

11

12 **3D LGE-CMR Acquisition and Processing**

13 All CMR examinations were performed in our institution on either a 1.5 T Gyroscan ACS-NT/Intera
14 MR system or on a 3.0 T Ingenia MR system (Philips Medical Systems, Best, The Netherlands) as
15 previously described.¹⁵ Following a standardized clinical protocol including cine MRI in long axis (2-
16 and 4-chamber views) and short axis, the gadolinium-based contrast agent (Dotarem, Guerbet,
17 Villepinte, France) was given intravenously (dosage, 0.15 mmol/kg). Ten minutes after contrast
18 administration, a 2D gradient-echo T1 weighted sequence was used to visually determine the
19 optimal inversion time (TI) of healthy myocardium. Approximately 10–15 min after administration of
20 contrast, a whole heart high spatial resolution 3D gradient echo (T1 fast field echo) phase sensitive
21 inversion recovery (PSIR) sequence was obtained during free breathing with diaphragmatic pencil-
22 beam navigation. Typical parameters were as follows: repetition time 4.15 ms; echo time 2.02 ms;
23 the optimal inversion time was set at the null point plus 50 ms and ranged from 250 to 400 ms; flip
24 angle 10°; field of view 350 × 350 mm; matrix size 208 × 208; acquired pixel size 1.68 × 1.68 mm;
25 reconstructed pixel size 0.91 × 0.91 mm; 71 transverse slices with 3.4 mm thickness and slice gap -

1 1.7 mm; sensitivity encoding factor 3. The 2D pencil beam respiratory navigator was planned on the
2 right hemidiaphragm. The acceptance window was set at 5mm with a constant correction of 0.6.
3 Saturation bands were planned on the navigator, vertebrae and thoracic subcutaneous adipose
4 tissue to suppress residual motion artifacts. Acquisition time was 3 min 4 s assuming 100 % navigator
5 efficiency and heart rate of 60 beats/min. Immediately after free-breathing LGE-CMR, breath hold
6 was obtained using a 3D gradient echo PSIR sequence in short-axis slice orientation in two equal
7 stacks during two breath-holds of 10–20 s duration.

8

9 ***Electrophysiology study and electroanatomical mapping***

10 Programmed electrical stimulation was performed from the RV apex and the RVOT, at or adjacent to
11 the infundibular septum (≥ 3 extrastimuli at ≥ 3 cycle lengths, including administration of
12 isoproterenol). SMVT was defined as a VT with a similar QRS configuration from beat to beat during
13 the VT episode lasting ≥ 30 s or causing hemodynamic compromise requiring termination. All
14 mapping and ablation procedures were continuously recorded for off-line analysis. The detailed
15 methods to obtain a 3D reconstruction of all AIs and targeting the VT-related isthmus by ablation
16 have been previously reported.³ AI1 is located between the tricuspid annulus (TA) and the RVOT
17 patch/RV incision. AI2 is bordered by an RV incision and the pulmonary valve (PV), and its presence
18 depends on the type of surgical approach. AI3 and 4 are located at the infundibular septum, with AI3
19 between PV and the VSD patch, and AI4 between the VSD patch and TA in case of muscular VSD.

20 Three-dimensional RV (and LV and aorta if necessary) electroanatomical bipolar voltage (BV)
21 mapping during baseline rhythm was performed using a 3.5mm irrigated-tip catheter (NaviStar
22 Thermocool, Smarttouch, Biosense Webster Inc., CA, USA) and long steerable sheaths. The aorta and
23 LV were approached by retrograde access, if necessary. Based on prior data, BV < 1.76 mV was
24 defined as low voltage.⁷ The locations of the TA and PV and unexcitable tissue (patch material) were
25 determined by the local electrograms, and/or non-capturing by pacing at 10 mA/2 ms. AI length,

1 width, and CV were measured as previously described.⁵ In cases with QRS duration <150ms and/or
2 collided activation wavefronts within an AI3 during non-paced rhythm, the RV was re-mapped during
3 pacing from the septal or lateral side of the isthmus just above sinus rhythm rate to allow correct
4 determination of the CV.¹⁶ If the CV across the AI was <0.5 m/s, the AI was considered SCAI_{EAM},⁵ and
5 an AI with CV ≥0.5 m/s was considered as normal conducting AI (NCAI_{EAM}). A blocked AI was defined
6 as AI with pre-existing conduction block.¹⁷

7

8 ***Ablation***

9 The 12-lead ECG was analyzed for each induced VT, and the AI related to the VT re-entry circuit was
10 determined by either pace-mapping within the isthmus (≥11/12 ECG-lead match between VT-QRS
11 and paced QRS) or by activation and entrainment mapping and/or termination of VT by
12 radiofrequency (RF) ablation if VT ablation was performed. Ablation was considered successful if
13 conduction through the corresponding AI was blocked after RF delivery, and any SMVTs were no
14 longer inducible. In selected patients in whom PVR was planned, intraoperative cryoablation of the
15 VT-related AI was performed, with intraoperative confirmation of bidirectional conduction block as
16 previously described.¹⁸

17

18 ***Follow-up***

19 Patients were followed according to institutional protocols. Follow-up started at electrophysiological
20 evaluation or (if performed) ablation. If multiple procedural attempts for arrhythmia control were
21 required, long-term outcome was assessed after the last procedure. All episodes of spontaneous
22 sustained VA and appropriate and inappropriate ICD therapy were recorded. VT was considered
23 sustained when ≥30 s or terminated by the ICD. Mortality was assessed from hospital records.

24

25 ***LGE-CMR-derived 3D scar reconstructions and evaluation of anatomical isthmuses***

1 LGE images in DICOM format were imported to the ADAS-3D image postprocessing software tool
2 (Galgo Medical, Barcelona, Spain). The RV wall was traced semiautomatically and then manually
3 corrected for a mid-myocardial layer (**Figure 1A**). The maximum and minimum voxel SIs (MaxSI and
4 MinSI) on the 3D RV shell were automatically detected and exported.

5 Next, the obtained 3D LGE-CMR-derived reconstruction of the RV was merged with the 3D-
6 RV CARTO mesh file. EAM points were superimposed on the CMR-derived reconstruction, which
7 allows for direct comparison of EAM data and local SI. EAM points >10mm away from the CMR-
8 derived reconstruction were removed from the analysis (**Figure 1B**).

9 The percentage of MaxSI (%MaxSI) at each EAM site was calculated for each EAM point by
10 the equation: $\%MaxSI = (Local\ SI - MinSI) / (MaxSI - MinSI) * 100$

11 Data on BV and %MaxSI for each EAM point were retrieved in all patients. The optimal
12 threshold of %MaxSI to detect abnormal low BV (<1.76mV), was determined by ROC analysis (**Figure**
13 **2**). The obtained high SI threshold (HSI_t) was applied to the CMR-derived 3D RV reconstruction,
14 color-coded for the local %MaxSI (**Figure 1C**).

15 All AI on the 3D LGE-CMR derived construction were analyzed. An abnormal AI_{CMR} was
16 defined as AI showing continuous high SI ($>HSI_t$) connecting the anatomical boundaries, otherwise
17 an AI was considered normal (normal AI_{CMR}). In cases with a normal AI_{CMR} on 3D CMR reconstruction,
18 the width of the normal SI area was measured using a tool deployed to the software (**Figure 1C**).
19 Total RV surface area and area above the HSI_t were automatically calculated.

20 All analyses were performed by an experienced operator blind to EAM data. To test
21 interobserver reproducibility, 20 cases were re-analyzed by a second operator, and the total RV
22 surface area, the area with $>HSI_t$, and positivity of abnormal AI_{CMR} were compared.

23

24 **Statistical analysis**

1 Continuous data are presented as mean \pm SD or median (interquartile range [IQR]) according to
2 distribution. Categorical data are reported as percentage and frequency. Continuous variables were
3 compared using the Student's t test or the Mann-Whitney U test where appropriate. Categorical
4 variables were compared using the chi-square test. Odds ratios of clinical parameters for the
5 presence of SCAI were calculated using univariable logistic regression analysis. The intraclass
6 correlation coefficient was used to determine interobserver variabilities in total RV surface area,
7 total scar area, and percentage of total scar area on CMR, and Kappa coefficient was calculated for
8 the positivity of abnormal AI_{CMR} . A p value <0.05 was considered significant. All analyses were
9 performed with SPSS 25.0 (IBM Corporation, Armonk, New York).

10

11 **Results**

12 ***Baseline data***

13 Forty-eight patients were included (34 ± 16 years, 58% men). Five patients (10%) had spontaneous,
14 clinical VT episodes, 19 patients (40%) underwent EAM before PVR, and the remaining 24 patients
15 (50%) for risk stratification. The median age at initial repair was 2.6 (IQR, 0.7-6.2) years, a
16 transannular patch was used in 30 (64%). The mean QRS duration was 155 ± 30 ms, and 19 patients
17 had a QRS duration <150 ms. Mean LVEF and RVEF were $55\pm 7\%$ and $48\pm 8\%$, respectively, and 42
18 patients (87%) had a good/mildly reduced RV systolic function. Baseline data are summarized in

19 **Table 1.**

20

21 ***Electrophysiological study and EAM data***

22 A total of 107 AIs were identified on EAM. AI1 and 3 were present in all patients, while AI2 was
23 identified in 11 patients (23%) and AI4 in none. All AI1 had normal CV. $SCAI_{EAM}2$ and 3 were observed
24 in 2 (4%) and 20 patients (42%), respectively. Seven patients (15%) had a blocked $AI_{EAM}3$ including 3
25 with previous ablation. The remaining 78 AIs were $NCAI_{EAM}$.

1 In 11 patients, 14 SMVTs (mean CL 250ms, IQR 231-278 ms) were induced, all related to
2 SCAI_{EAM}3.

3

4 ***Association between previously suggested non-invasive risk factors for VT and the presence of SCAI***

5 In univariable analysis, none of conventional non-invasive risk factors was significantly associated
6 with SCAI_{EAM}. The presence of SCAI_{EAM} was independent of risk score 2008 (Table 2).

7

8 ***Reversed registration of bipolar voltage mapping data and 3D LGE-CMR derived RV reconstruction***

9 A total of 10178 mapping points were superimposed onto the 3D-CMR RV reconstruction, and 9240
10 points within 10mm from the 3D-CMR RV reconstruction were used for the analysis. There was a
11 significant inverse relationship between local BV and %maxSI ($R^2=0.16$, $P<0.001$ Figure 2A). Based on
12 ROC curve analysis, the optimal SI cut-off value to identify abnormal low BV as surrogate for
13 diseased myocardium was 42% of the maximal SI with a sensitivity of 74% and specificity of 78%
14 (AUC 0.80, Figure 2B).

15

16 ***Identification of SCAI by 3D-CMR reconstruction using a disease-specific cut-off of SI for low BV***

17 Using the optimal HSI_t (42% of maxSI), 3D-CMR reconstructions of the RV were analyzed.
18 Representative 2 cases are illustrated in Figure 3. The total RV surface area and area above the HSI_t
19 were 238 ± 44 and 55 ± 25 cm², respectively. All unexcitable boundaries of AI as identified by EAM,
20 including patch materials, incision, and valve annuli had SI above the HSI_t.

21 All 107 AIs delineated by EAM were correctly identified on 3D CMR. Of the 107 AI_{EAM}, 37
22 AI_{EAM} in 33 patients were categorized as abnormal AI based on 3D LGE-CMR (Abnormal AI_{CMR}1, n=0;
23 abnormal AI_{CMR}2, n=4; abnormal AI_{CMR}3, n=33). Importantly, all 29 SCAI_{EAM} or blocked AI_{EAM} were
24 correctly classified as abnormal AI_{CMR}. Among the 78 NCAI_{EAM}, 70 were correctly categorized as
25 normal AI_{CMR} (normal AI_{CMR}1, n=48; normal AI_{CMR}2, n=7; normal AI_{CMR}3, n=15). The median width of

1 normal AI_{CMR3} was 15.5mm (range 6.3-27.4 mm). The remaining 8/78 (10%) NCA_{EAM} were
2 considered abnormal AI_{CMR} . Specifically, all 48 NCA_{EAM1} were also considered normal on CMR.
3 Among the 9 NCA_{EAM2} , 2/9 were classified as abnormal AI_{CMR2} . Among the 21 NCA_{EAM3} , 6/21 were
4 classified as abnormal AI_{CMR3} .

5 The sensitivity and specificity of 3D LGE-CMR for identifying SCA_{EAM} or blocked AI_{EAM} were
6 100% and 90% (29/29 and 70/78), respectively. For $AI3$, those values were 100% and 71%,
7 respectively.

8 CMR data are summarized in **Table 3**.

9

10 ***Interobserver variability***

11 Intraclass correlation coefficients were 0.97 (95%CI, 0.93-0.99) for the total RV surface area and 0.97
12 (0.93-0.99) for the area with $>HSL_t$. Kappa coefficient was 1.0.

13

14 ***Association between SMVT inducibility and SCAI on EAM and LGE-CMR***

15 SMVT was only inducible in patients with SCA_{EAM} or abnormal AI_{CMR} and was not inducible in any of
16 the patients with normal AI_{CMR} .

17

18 ***Association between bipolar voltage, conduction velocity, and CMR findings of AI3***

19 Patients were divided into 3 groups according to the EAM and CMR findings of $AI3$, considering EAM
20 as gold standard: (A) NCA_{EAM} and normal AI_{CMR} ("true negative CMR" n=15), (B) NCA_{EAM} and
21 abnormal AI_{CMR} ("false positive CMR" n=6), and (C) SCA_{EAM} and abnormal AI_{CMR} ("true positive CMR"
22 n=20).

23 The median BV and conduction velocity of $AI3$ were 1.68 (IQR 0.61-2.62) mV and 0.64 (0.36-
24 0.93) m/s, respectively. Of note, the median BV within $AI3$ was highest in group A, followed by
25 groups B and C, with statistically significant differences between each group (A, 3.45 mV [range,

1 2.22-5.67]; B, 1.91 mV [1.62-2.60]; C, 0.76 mV [0.25-2.59]; $P < 0.01$ (A vs. B and B vs. C, **Figure 4A**). In
2 addition, the median CV was highest in group A, followed by groups B and C, with statistical
3 significant differences among groups (A, 0.95 m/s [range, 0.82-1.09]; B, 0.69 m/s [0.62-0.81]; C, 0.36
4 m/s [0.29-0.44]; A vs. B, $P < 0.01$, B vs. C, $P < 0.001$, **Figure 4B**).

5

6 ***Acute ablation outcome***

7 Transection of AI3 was performed in all 20 patients with SCA_{EAM3} by radiofrequency (n=10) or
8 cryoablation (n=10). In the 2 patients with SCA_{EAM2} , the AI2 was successfully transected by catheter
9 ablation (n=1) or surgically transected during PVR (n=1). Acute procedural success was achieved in
10 17 of 20 patients (85%). In the remaining 3 patients, bidirectional block across the SCA_{EAM3} could
11 not be achieved (inaccessibility likely due to PVR/artificial material), and an ICD was implanted.

12

13 ***Follow-up***

14 During a median follow-up of 25 (IQR 11-45) months, 2 patients had VT, both with SCA_{EAM3} and
15 incomplete procedural success.

16 In one patient with a normal but narrow (6.3mm) AI_{CMR3} on a first CMR and corresponding
17 normal CV through the AI3 (0.81m/s) on EAM, a second 3D LGE-CMR was performed 4 years later
18 because of symptoms. The CMR was consistent with an abnormal AI_{CMR3} , and EAM confirmed a
19 SCA_{EAM3} , which was the critical substrate for an induced SMVT. AI3 was successfully transected by
20 catheter ablation (**Figure 5**).

21

22

23 **Discussion**

24 To the best of our knowledge, this is the first study to demonstrate that 3D LGE-CMR can non-
25 invasively identify SCAI as dominant substrate for VT in patients with rTOF. The newly proposed

1 method of CMR image analysis showed an excellent interobserver agreement and could identify
2 SCAI or blocked AI with 100% sensitivity and 90% specificity. Compared to patients with $NCAI_{EAM}$ and
3 normal AI_{CMR} (true negative CMR), those with $NCAI_{EAM}$ but abnormal AI_{CMR} (false positive CMR) had
4 already significantly lower BV and CV on EAM.

5 These results suggest that 3D LGE-CMR can diagnose SCAI with excellent accuracy and may
6 identify a diseased AI3 even before critical conduction delay occurs. This technique may allow for
7 non-invasive and serial risk stratification of VT and can refine patient selection for invasive EAM and
8 concomitant ablation.

9

10 ***SCAI as the dominant substrate for monomorphic VT***

11 The vast majority of VA in rTOF are reentrant VTs dependent on AIs. AIs are present in almost all
12 rTOF patients, but only SCAI are critical for monomorphic VT.⁵ Among 4 previously described AIs, AI3
13 is the most prevalent isthmus and more likely to show slow conduction in contemporary rTOF
14 patients.^{4, 5} In line with previous reports, in the present study, 20 out of all 22 $SCAI_{EAM}$ (91%) was
15 SCAI3, which was the substrate for all induced VTs.

16 Transection of SCAI by catheter or surgical ablation has been recognized as the most
17 effective, curative, and potentially preventive treatment of monomorphic VT in rTOF.⁸ rTOF patients
18 without SCAI during EAM and only mildly reduced or preserved cardiac function had no arrhythmic
19 event during long-term follow-up.⁸ As a consequence, identification of SCAI may allow for individual
20 risk stratification and preventive treatment of the VT substrate even before spontaneous and
21 potentially fatal VT occurs. To date, no single noninvasive parameter has been associated with the
22 presence of SCAI. In the present study, none of noninvasive parameters or risk scores was
23 significantly correlated with SCAI. Invasive EAM is currently the only diagnostic method to identify
24 SCAI.⁵ As slow conduction properties may develop over time, repeated invasive mapping studies may
25 be required.

1

2 ***Prior CMR studies in patients with rTOF***

3 The feasibility of semi-automated scar segmentation from 3D LGE-CMR has been reported in a small
4 series of rTOF patients.⁹ The 3D imaging technique is especially useful for morphologically complex
5 architectures, such as the RVOT, where the 2D technique cannot maintain continuously co-axial
6 slices to the imaging plane, increasing partial volume effects.⁹

7 Extensive myocardial scar detected by LGE-CMR has been associated with VT and SCD in
8 patients with rTOF.^{19, 20} However, before CMR becomes a decisive factor for risk stratification and VT
9 substrate delineation, important aspects need to be considered. First, LGE-CMR methods and SI
10 thresholds to delineate 3D scar geometry have not been validated for surgical scars and other
11 unexcitable boundaries of AI including endothelialized prosthetic patches. Second, previous reports
12 have focused on the entire RV with/without LV using a scoring system based on visual assessment of
13 2D LGE-CMR or manual segmentation of LGE from 3D LGE-CMR.^{21, 22} A RV LGE volume >10 cm³ has
14 been reported to be 100% sensitive and a RV-LGE volume >36 cm³ to be 100% specific for the
15 prediction of VA inducibility.²¹ Of note, the majority (approximately 80%) of the studied patients had
16 RV-LGE volumes between 10-36 cm³ and 30% of clinical sustained VT occurred in patients with the
17 inframedian RV LGE volume (<20cm³). These data emphasize the limitation of overall RV scar burden
18 for predicting VT in an individual patient.²¹

19 To date, no CMR study could identify SCAI as the most important VT substrate. A recent
20 study used 3D CMR reconstruction to visualize AI in 10 patients with rTOF.¹⁰ The best SI threshold
21 was defined by a site-by-site visual comparison of CMR reconstruction color-coded for different SI
22 thresholds, with the presence of AI on EAM (BV>1.5mV between boundaries), until the best match
23 was achieved. The CMR reconstruction using 60% of maxSI for isthmus boundaries showed a good
24 match with the number of AI on EAM in 9/10 patients, confirming that viable myocardium between
25 anatomical boundaries can be identified by LGE-CMR in rTOF. In this study, only one patient was

1 inducible for VT and no attempt was made to correlate CMR findings with SCAI. Of importance, AI is
2 present in almost all rTOF patients, and the anatomical location is often available from operation
3 reports. The presence of AI, as demonstrated in this study does not provide information on a
4 potential VT substrate.

5

6 ***Identification of SCAI by 3D CMR***

7 In contrast to the previous study, we performed reversed integration of CMR and EAM data allowing
8 the direct comparison of 9240 EAM points from 48 patients with local SI. We identified 42% of maxSI
9 as the best SI cut-off for abnormal myocardium, which, when continuously present between
10 anatomical boundaries was consistent with slow-conducting or blocked AI during invasive EAM.

11 The present study is the first to correctly identify not only AI but SCAI as VT substrate by
12 LGE-CMR. The excellent negative predictive value of the 3D LGE-CMR for SCAI impacts the need for
13 invasive EAM, currently performed for risk stratification and before re-valving. If SCAI are likely,
14 invasive EAM can be combined with concomitant catheter ablation or intraoperative cryoablation if
15 surgical PVR is indicated.

16 CMR cannot differentiate between SCAI and blocked AI and in these cases EAM is still necessary.

17 Human studies have demonstrated that critical conduction can occur through single myocardial
18 bundles of 200 μ m, which is beyond current resolution of in-vivo LGE-CMRs.²³

19

20 ***LGE-CMR for early detection of adverse remodeling***

21 There is a time dependent risk of VA in rTOF.²⁴ Adverse remodeling and slow conduction across AI
22 may develop over time. In the present study, one patient who underwent repeated EAM and CMR
23 showed a progressive conduction delay across AI3 over 4 years.

24 Three-dimensional LGE-CMR may identify AI3 that are more likely to remodel over time,
25 before critical conduction delay occurs. The six patients with $NCAI_{EAM}$ but abnormal AI_{CMR} ("false

1 positive CMR”) had already significantly lower BV and CV than those with $NCAI_{EAM}$ and normal AI_{CMR} .
2 Follow-up studies are required to evaluate if LGE-CMR can indeed detect AI that will develop slow
3 conduction over time, justifying preventive ablation in those who are scheduled for re-valving.

4

5 **Limitations**

6 This is a retrospective and single center study, and the sample size is limited. However, to our
7 knowledge, this is the largest cohort of rTOF patients with EAM and 3D LGE-CMR, including patients
8 with and without VT substrates. This study has been performed in a high-volume tertiary referral
9 center with expertise in electrophysiological evaluation of patients with congenital heart disease,
10 which likely influences the characteristics of the patient population. Prospective multi-center studies
11 are important to validate the proposed LGE-CMR method for non-invasive VT substrate
12 identification.

13

14 **Conclusion**

15 3D LGE-CMR can identify SCAI with 100% sensitivity and 90% specificity and may identify diseased
16 AI3 even before critical conduction delay occurs. This technique may allow for non-invasive risk
17 stratification of VT and can refine patient selection for invasive EAM.

18

19 **Funding**

20 We acknowledge the support from the Netherlands Cardiovascular Research Initiative: An initiative
21 with support of the Dutch Heart Foundation and Hartekind, CVON2019-002 OUTREACH.

22

23 **Disclosures**

24 No disclosures related to the manuscript. The department of Cardiology receives investigator
25 initiated research grants from Biosense Webster

1 **Figure legends**

2 **Figure 1. Processing of 3D LGE-CMR and integration with electroanatomical map**

3 **A:** (left panel) RV contour was semiautomatically traced and then manually corrected for a

4 midmyocardial layer. Noises by sternum wire were carefully removed from the contour.

5 (right panel) Tricuspid valve and pulmonary artery were removed from the 3D LGE-CMR

6 reconstruction. The imaging processing software automatically detects the maximum and minimum

7 SIs of the 3D LGE-CMR reconstruction.

8 **B:** (left panel) RV EAM was reviewed and exported.

9 (right panel) All mapping points were superimposed onto the 3D LGE-CMR reconstruction. EAM

10 points >10mm away from the CMR-derived reconstruction were removed from the analysis, and BV

11 of the remaining points were compared with corresponding local SIs. (see figure 2)

12 **C:** (left and mid panels) The obtained HSI_t (42% of the maximum SI) was applied to the 3D CMR RV

13 reconstruction, visualizing the RV shell color-coded by local %MaxSI and the scar lesion defined as an

14 area above the HSI_t . An additional threshold was put at 1.5 fold of the HSI_t but not used for analysis.

15 Abnormal myocardium ($>HSI_t$) was visualized as red, yellow, green, or blue, and normal myocardium

16 ($<HSI_t$) was as purple. AIs on the 3D LGE-CMR derived construction were visually inspected if it is

17 abnormal AI_{CMR} , defined as a continuous area above the HSI_t connecting anatomical boundaries.

18 (right panel) In cases with a normal AI_{CMR} , the lesion width of the healthy part of the AI was

19 measured using a tool deployed to the software.

20 AI = anatomical isthmus, BV = bipolar voltage, CMR = cardiac magnetic resonance imaging, EAM =

21 electroanatomical mapping, HSI_t = high signal intensity threshold, LGE = late gadolinium enhancement,

22 RV = right ventricle, SI = signal intensity

23

24 **Figure 2. Defining rTOF-specific SI threshold**

25 **A:** Correlation between BV and local SI

1 **B:** Receiver operating characteristic analysis for low BV correlating to local SI

2 AUC = area under the curve, BV = bipolar voltage, SI = signal intensity.

3

4 **Figure 3. Examples of normal and slow-conducting AIs**

5 **A:** Normal-conducting AI

6 **B:** Slow-conducting AI

7 AI = anatomical isthmus

8

9 **Figure 4. Bipolar voltage and conduction velocity on AI3 according to EAM and CMR findings**

10 **A: Bipolar voltage**

11 **B: Conduction velocity**

12 AI = anatomical isthmus, CMR = cardiac magnetic resonance imaging, CV = conduction velocity, EAM

13 = electroanatomical mapping.

14

15 **Figure 5. A patient with progression of conduction delay on AI3**

16 **A:** The first CMR showed narrow but normal AI3. The CV through the AI3 was normal (0.81m/s).

17 **B:** 3D LGE-CMR was repeated 4 years later, showing an abnormal AI3_{CMR}. EAM was also reperformed,

18 indicating SCAI_{EAM}3.

19 **C:** Fragmented local signals were observed at SCAI3. SMVT was induced and good pacemapping

20 morphology was obtained at SCAI3. SCAI3 was transected by catheter ablation.

21 AI = anatomical isthmus, CMR = cardiac magnetic resonance imaging, CV = conduction velocity, EAM

22 = electroanatomical mapping, LGE = late gadolinium enhancement, SCAI = slow-conducting

23 anatomical isthmus, SMVT = sustained monomorphic ventricular tachycardia.

Tables

Table 1. Baseline data

	ALL (n=48)
Age	34±16
Male	28 (58)
Age at total repair, year	2.6 (0.7-6.2)
Initial repair ≥5 years	17 (35)
Palliative shunt*	14 (30)
Transannular patch†	30 (64)
Right ventriculotomy**	18 (50)
PVR	23 (45)
Syncope	2 (4)
ECG	
QRS duration, ms	155±30
QRS duration ≥180 ms	9 (19)
CRBBB	42 (88)
FQRS	28 (58)
History of atrial arrhythmia	10 (21)
NSVT	17 (38)
Clinical SMVT	5 (10)
LVEF good/mildly reduced	48 (100)
RVEF good/mildly reduced	42 (87)
LV diastolic dysfunction††	5 (11)
PR moderate/severe	23 (48)
MRI	
MRI LVEF, %	55±7
MRI RVEF, %	48±8
MRI RVEDV, ml	227±61

Results are expressed as a number (%), mean ± SD, or median (IQR).

Data availability, *N=46, †N=47, **N=36, ††N=45.

AI indicates anatomical isthmus; CRBBB, complete right bundle branch block; ECG, electrocardiography; FQRS, fragmented QRS; LV, left ventricle; LVEF, left ventricular ejection fraction; MRI, magnetic resonance imaging; NCAI, normal-conducting anatomical isthmus; NSVT, non-sustained ventricular tachycardia; PR, pulmonary regurgitation; PVR, pulmonary valve replacement; RV, right ventricle; RVEDV, right ventricular end-diastolic volume; RVEF, right ventricular ejection fraction; SCAI, slow-conducting anatomical isthmus; SMVT, sustained monomorphic ventricular tachycardia.

Table 2. Univariable analysis for the association between clinical risk factors and risk score and

SCAI_{EAM}

	Odds ratio	95%CI	P
Age	1.01	0.97-1.05	0.69
Male	1.13	0.35-3.69	0.84
Age at total repair, year	1.01	0.89-1.15	0.86
Initial repair ≥5 years	0.97	0.29-3.22	0.96
Palliative shunt	3.60	0.97-13.4	0.06
Transannular patch	0.44	0.13-1.50	0.19
Right ventriculotomy	2.60	0.65-10.38	0.18
QRS duration, ms	0.99	0.97-1.01	0.48
FQRS	1.61	0.49-5.25	0.43
History of atrial arrhythmia	0.92	0.22-3.79	0.90
NSVT	0.35	0.09-1.36	0.12
RVEF moderate/severely reduced	0.67	0.11-4.05	0.66
LV diastolic dysfunction	0.38	0.04-3.67	0.40
PR moderate/severe	1.15	0.37-3.64	0.81
MRI LVEF, %	0.95	0.87-1.04	0.24
MRI RVEF, %	1.03	0.96-1.11	0.44
Risk score 2008 (per 1 point increase)	1.11	0.90-1.37	0.34
Intermediate risk (vs. Low)	0.85	0.20-3.56	0.82
High risk (vs. Low)	3.40	0.69-16.7	0.13

See Table 1 for abbreviations.

Table 3. CMR data

	ALL (n=48)
Total RV surface area (cm²)	238±43
Area above the HSI_t (cm²)	55±25
Area above the HSI_t (%)	24±10
Number of AI_{CMR} / abnormal AI_{CMR}	107 / 37
AI_{CMR}1 / abnormal AI_{CMR}1	48 (100) / 0
AI_{CMR}2 / abnormal AI_{CMR}2	11 (23) / 4 (8)
AI_{CMR}3 / abnormal AI_{CMR}3	48 (100) / 33 (69)
AI_{CMR}4 / abnormal AI_{CMR}4	0 / 0

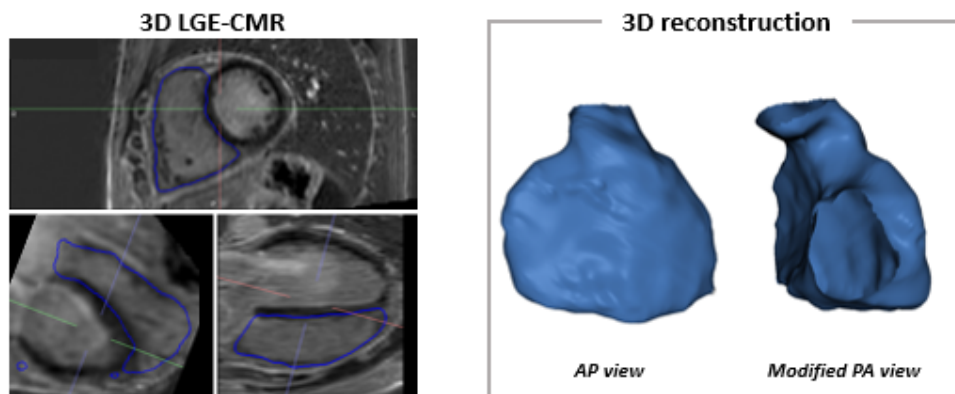
Results are expressed as a number (%) or mean ± SD.

See Table 1 for abbreviations.

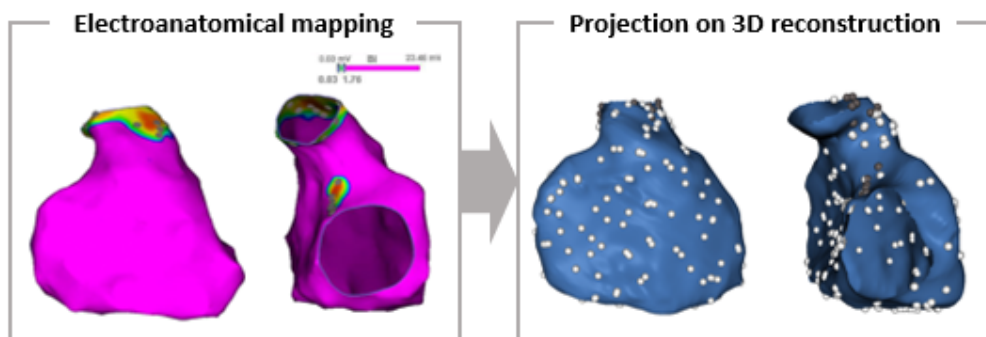
Figures

Figure 1.

A. Anatomical reconstruction



B. Mapping point projection on 3D LGE-CMR construction



C. Visualization of LGE using rTOF specific cut-off (HSI_t)

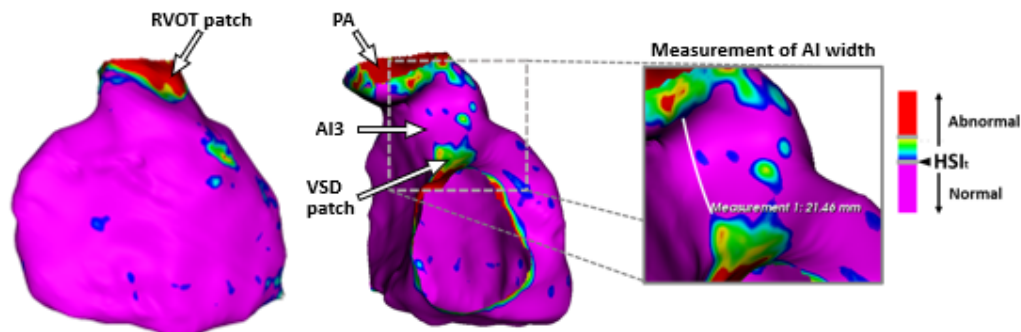


Figure 2.

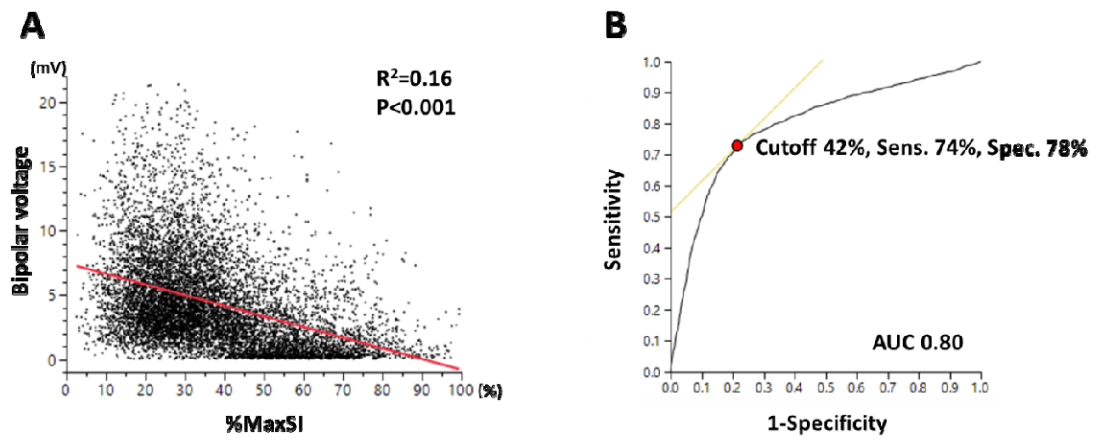
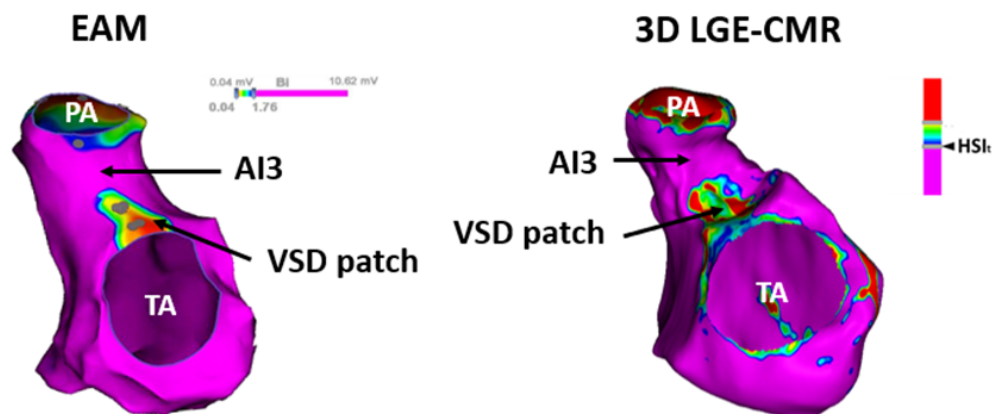


Figure 3.

A. Normal conducting AI



B. Slow conducting AI

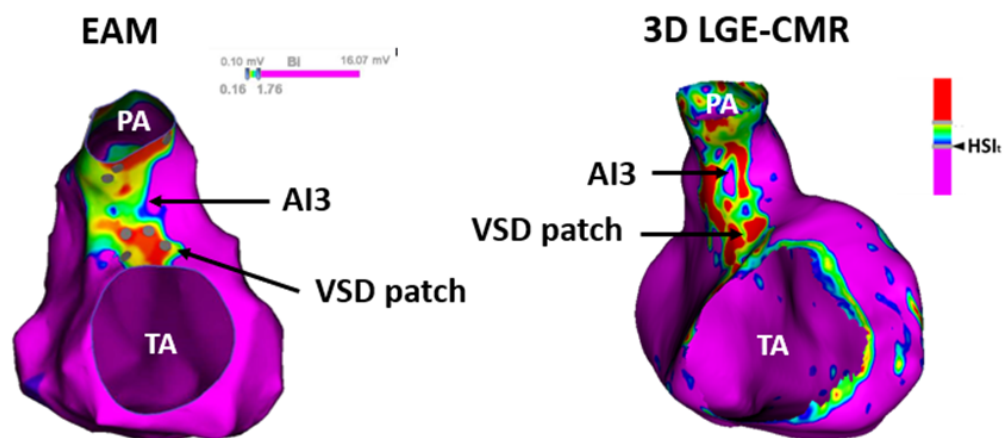


Figure 4

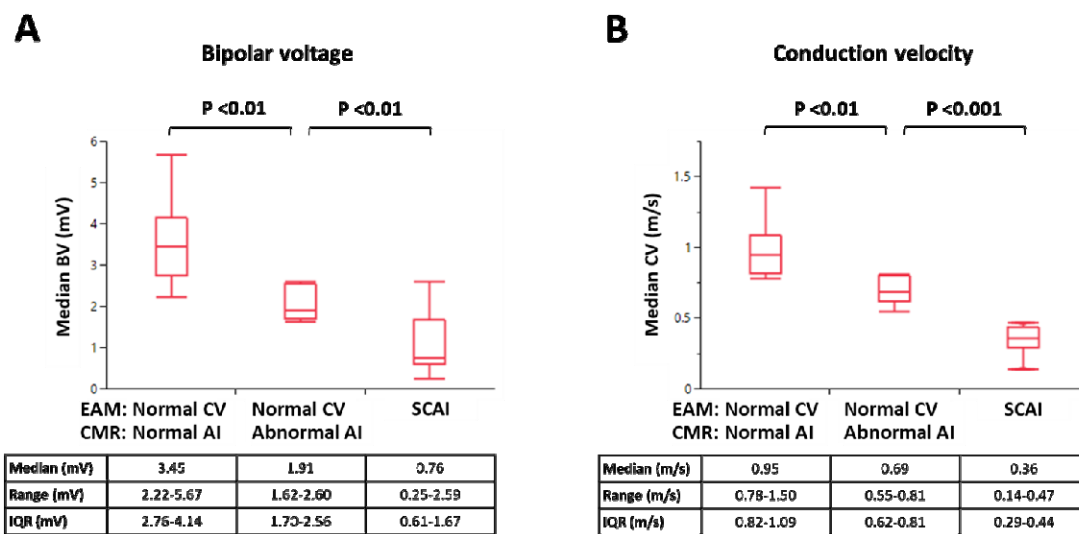
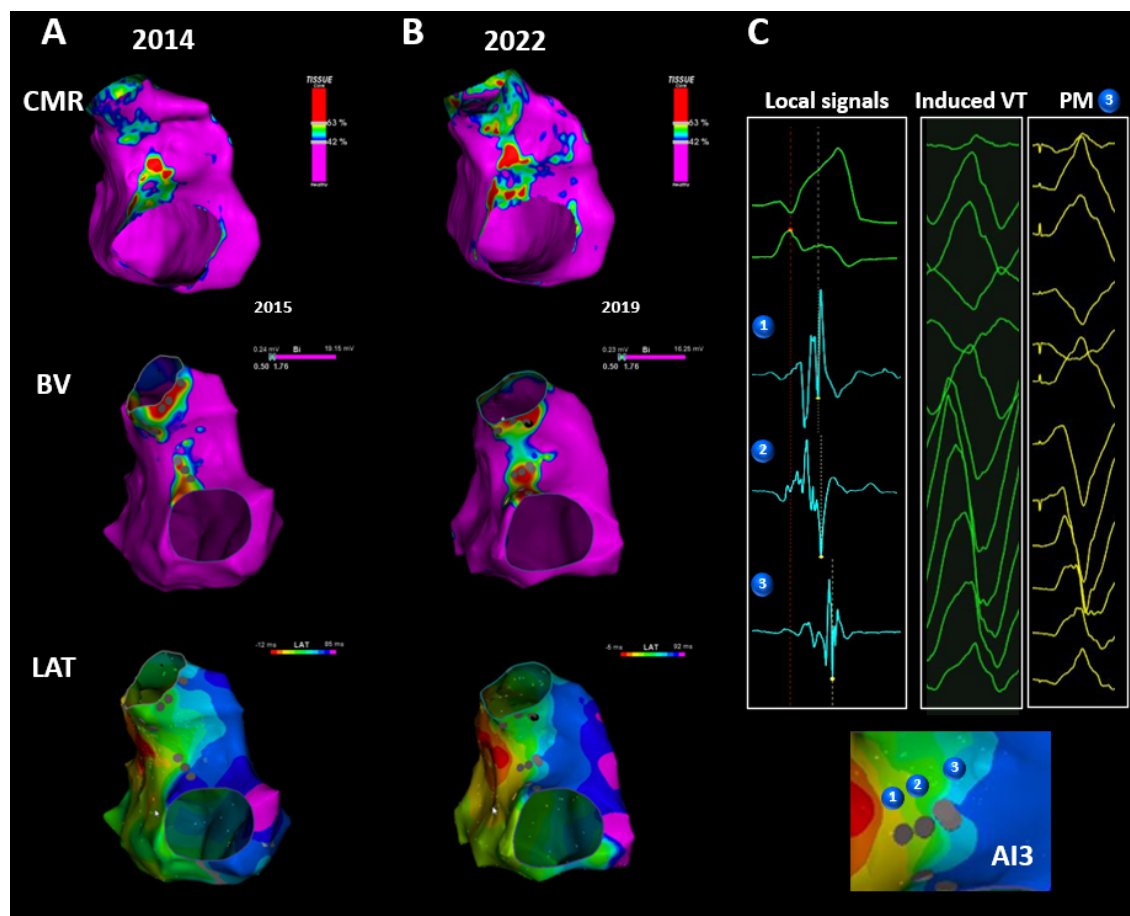


Figure 5.



References

1. Marelli AJ, Mackie AS, Ionescu-Iltu R, Rahme E and Pilote L. Congenital heart disease in the general population: changing prevalence and age distribution. *Circulation*. 2007;115:163-72.
2. Marelli AJ, Ionescu-Iltu R, Mackie AS, Guo L, Dendukuri N and Kaouache M. Lifetime prevalence of congenital heart disease in the general population from 2000 to 2010. *Circulation*. 2014;130:749-56.
3. Zeppenfeld K, Schalij MJ, Bartelings MM, Tedrow UB, Koplan BA, Soejima K and Stevenson WG. Catheter ablation of ventricular tachycardia after repair of congenital heart disease: electroanatomic identification of the critical right ventricular isthmus. *Circulation*. 2007;116:2241-52.
4. Moore JP, Seki A, Shannon KM, Mandapati R, Tung R and Fishbein MC. Characterization of anatomic ventricular tachycardia isthmus pathology after surgical repair of tetralogy of Fallot. *Circ Arrhythm Electrophysiol*. 2013;6:905-11.
5. Kapel GF, Sacher F, Dekkers OM, Watanabe M, Blom NA, Thambo JB, Derval N, Schalij MJ, Jalal Z, Wijnmaalen AP and Zeppenfeld K. Arrhythmogenic anatomical isthmuses identified by electroanatomical mapping are the substrate for ventricular tachycardia in repaired Tetralogy of Fallot. *Eur Heart J*. 2017;38:268-276.
6. Yang J, Brunnuell M, Liang JJ, Callans DJ, Garcia FC, Lin D, Frankel DS, Kay J, Marchlinski FE, Tzou W, et al. Long term follow-up after ventricular tachycardia ablation in patients with congenital heart disease. *J Cardiovasc Electrophysiol*. 2019;30:1560-1568.
7. Teijeira-Fernandez E, Cochet H, Bourier F, Takigawa M, Cheniti G, Thompson N, Frontera A, Camaioni C, Massouille G, Jalal Z, et al. Influence of contact force on voltage mapping: A combined magnetic resonance imaging and electroanatomic mapping study in patients with tetralogy of Fallot. *Heart Rhythm*. 2018;15:1198-1205.
8. Kapel GF, Reichlin T, Wijnmaalen AP, Piers SR, Holman ER, Tedrow UB, Schalij MJ, Stevenson WG and Zeppenfeld K. Re-entry using anatomically determined isthmuses: a curable ventricular tachycardia in repaired congenital heart disease. *Circ Arrhythm Electrophysiol*. 2015;8:102-9.
9. Stirrat J, Rajchl M, Bergin L, Patton DJ, Peters T and White JA. High-resolution 3-dimensional late gadolinium enhancement scar imaging in surgically corrected Tetralogy of Fallot: clinical feasibility of volumetric quantification and visualization. *J Cardiovasc Magn Reson*. 2014;16:76.

10. Rivas-Gandara N, Dos-Subira L, Francisco-Pascual J, Rodriguez-Garcia J, Pijuan-Domenech A, Benito B, Valente F, Pascual-Gonzalez G, Santos-Ortega A, Miranda B, et al. Substrate characterization of right ventricle in repaired tetralogy of Fallot using late enhancement cardiac magnetic resonance. *Heart Rhythm*. 2021;18:1868-1875.
11. Bokma JP, Winter MM, Vehmeijer JT, Vliegen HW, van Dijk AP, van Melle JP, Meijboom FJ, Post MC, Zwinderman AH, Mulder BJ and Bouma BJ. QRS fragmentation is superior to QRS duration in predicting mortality in adults with tetralogy of Fallot. *Heart*. 2017;103:666-671.
12. Nagueh SF, Appleton CP, Gillebert TC, Marino PN, Oh JK, Smiseth OA, Waggoner AD, Flachskampf FA, Pellikka PA and Evangelista A. Recommendations for the Evaluation of Left Ventricular Diastolic Function by Echocardiography. *Journal of the American Society of Echocardiography*. 2009;22:107-133.
13. Aboulhosn JA, Lluri G, Gurvitz MZ, Khairy P, Mongeon FP, Kay J, Valente AM, Earing MG, Opotowsky AR, Lui G, et al. Left and right ventricular diastolic function in adults with surgically repaired tetralogy of Fallot: a multi-institutional study. *Can J Cardiol*. 2013;29:866-72.
14. Khairy P, Harris L, Landzberg MJ, Viswanathan S, Barlow A, Gatzoulis MA, Fernandes SM, Beauchesne L, Therrien J, Chetaille P, et al. Implantable cardioverter-defibrillators in tetralogy of Fallot. *Circulation*. 2008;117:363-70.
15. Bizino MB, Tao Q, Amersfoort J, Siebelink HJ, van den Bogaard PJ, van der Geest RJ and Lamb HJ. High spatial resolution free-breathing 3D late gadolinium enhancement cardiac magnetic resonance imaging in ischaemic and non-ischaemic cardiomyopathy: quantitative assessment of scar mass and image quality. *Eur Radiol*. 2018;28:4027-4035.
16. Zeppenfeld K and Kimura Y. Catheter Ablation of Ventricular Tachycardia in Congenital Heart Disease *Catheter Ablation of Cardiac Arrhythmias in Children and Patients with Congenital Heart Disease*: CRC Press; 2021: 238-254.
17. Kapel GFL, Brouwer C, Jalal Z, Sacher F, Venlet J, Schaliij MJ, Thambo JB, Jongbloed MRM, Blom NA, de Riva M and Zeppenfeld K. Slow Conducting Electroanatomic Isthmuses: An Important Link Between QRS Duration and Ventricular Tachycardia in Tetralogy of Fallot. *JACC Clin Electrophysiol*. 2018;4:781-793.
18. Nevvazhay T, Zeppenfeld K, Brouwer C and Hazekamp M. Intraoperative cryoablation in late pulmonary valve replacement for tetralogy of Fallot. *Interact Cardiovasc Thorac Surg*. 2020;30:780-782.

19. Baumgartner H, De Backer J, Babu-Narayan SV, Budts W, Chessa M, Diller GP, Lung B, Kluin J, Lang IM, Meijboom F, et al. 2020 ESC Guidelines for the management of adult congenital heart disease. *Eur Heart J*. 2021;42:563-645.
20. Stout KK, Daniels CJ, Aboulhosn JA, Bozkurt B, Broberg CS, Colman JM, Crumb SR, Dearani JA, Fuller S, Gurvitz M, et al. 2018 AHA/ACC Guideline for the Management of Adults With Congenital Heart Disease: A Report of the American College of Cardiology/American Heart Association Task Force on Clinical Practice Guidelines. *Circulation*. 2019;139:e698-e800.
21. Ghonim S, Ernst S, Keegan J, Giannakidis A, Spadotto V, Voges I, Smith GC, Boutsikou M, Montanaro C, Wong T, et al. Three-Dimensional Late Gadolinium Enhancement Cardiovascular Magnetic Resonance Predicts Inducibility of Ventricular Tachycardia in Adults With Repaired Tetralogy of Fallot. *Circ Arrhythm Electrophysiol*. 2020;13:e008321.
22. Ghonim S, Gatzoulis MA, Ernst S, Li W, Moon JC, Smith GC, Heng EL, Keegan J, Ho SY, McCarthy KP, et al. Predicting Survival in Repaired Tetralogy of Fallot. *JACC: Cardiovascular Imaging*. 2021.
23. de Bakker JM, van Capelle FJ, Janse MJ, Tasseron S, Vermeulen JT, de Jonge N and Lahpor JR. Slow conduction in the infarcted human heart. 'Zigzag' course of activation. *Circulation*. 1993;88:915-26.
24. Khairy P, Aboulhosn J, Gurvitz MZ, Opatowsky AR, Mongeon FP, Kay J, Valente AM, Earing MG, Lui G, Gersony DR, et al. Arrhythmia burden in adults with surgically repaired tetralogy of Fallot: a multi-institutional study. *Circulation*. 2010;122:868-75.