

# **Clinical characteristic and imaging findings of post- infarction left ventricular pseudoaneurysm versus aneurysm: a pooled analysis of 21,472 patients**

Elmira Jafari Afshar, MD<sup>1</sup>, Amirhossein Tayebi, MD,<sup>1</sup> Parham Samimisedeh, MD,<sup>1</sup> Vahid Shahnavaaz, MD,<sup>1</sup> Aryan Madady, MD,<sup>2</sup> Hadith Rastad, PhD,<sup>3</sup> Neda Shafiabadi Hassani, MD<sup>4</sup>

Elmira Jafari Afshar and Amir Hossein Tayebi equally contributed as first authors.

Hadith Rastad and Neda Shafiabadi Hassani equally contributed as corresponding authors

<sup>1</sup>Cardiovascular Research Center, Alborz University of Medical Sciences, Karaj, Iran

<sup>2</sup>Cardiovascular surgery department, Shahid Rajaei hospital, Alborz University of Medical Sciences, Karaj, Iran

<sup>3</sup>Non-communicable Diseases Research Center, Alborz University of Medical Sciences, Karaj, Iran

<sup>4</sup>Herrington Heart and Vascular Institute, University Hospitals Cleveland Medical Center, Cleveland, Ohio, USA

[Elmirafshar72@gmail.com](mailto:Elmirafshar72@gmail.com)

[Amirhossein.tayebi.md@gmail.com](mailto:Amirhossein.tayebi.md@gmail.com)

[parhamsamimimd@gmail.com](mailto:parhamsamimimd@gmail.com)

[dr.vahid.shahnavaaz@gmail.com](mailto:dr.vahid.shahnavaaz@gmail.com)

[ariyan.madady.am@gmail.com](mailto:ariyan.madady.am@gmail.com)

[h.rastad91@gmail.com](mailto:h.rastad91@gmail.com)

[Neda.shafiabadiHassani@UHhospital.org](mailto:Neda.shafiabadiHassani@UHhospital.org)

## **Abstract**

### **Background**

Left ventricular pseudoaneurysm (LVPA) is a rare but life-threatening complication of myocardial infarction (MI). Given the similarities in the clinical presentations and the appearance of the cardiac imaging, differentiation of LVPA from left ventricular aneurysm (LVA) remains a challenge but is imperative for timely management. We summarized and compared clinical and imaging findings of post-MI LVPA and LVA.

### **Method**

We performed a comprehensive search of the literature in PubMed and Scopus databases using combinations of key terms covering LVPA / LVA and MI. In both LVA and LVPA, individual-level patient data (IPD) and aggregated-level data (AD) studies were combined through a two-stage analysis method.

### **Results**

We identified 379 eligible articles on LVPA (N= 504 patients) and 120 on LVA (n= 20,968). Based on our pooled analysis, cases were predominantly male in both groups (70.4% and 75.7 %, respectively), but LVPA patients were roughly older (Mean (95% Confidence interval (CI): (65.4 (62.4, 68.4) vs. 60.8 (58.9, 62.8) years, respectively) and had a shorter mean time interval from MI to diagnosis than LVA (5.1 vs. 27.8, months). At presentation, while 33.8 (95% CI: 22.1, 46.0) of patients with LVA had arrhythmia, only 1.0 % (95% CI: 0.0, 2.9) of LVPA patients presented with this symptom. LVPA compared to the LVA group, more frequently had ST-segment elevation (43.2% Vs. 28.6, respectively) but less frequently ECG signs of the old MI (42.2% Vs. 61.9, respectively). Echocardiography showed a lower diagnostic value in LVPA than LVA (Sensitivity: 81.4% Vs. 97.5%). Contrary to LVA, LVPA is mainly located on

posterior and inferior segments based on echocardiography evaluations. On Cardiac MRI, the majority of LVPA patients had pericardial LGE (84.0% (CI 95%: 63.9, 95.5)). A higher percentage of LVPA compared to the LVA group dead during hospitalization (13.8% vs. 4.7%, respectively) or after discharge (17.5% vs. 9.0%, respectively).

### **Conclusion**

Arrhythmia is likely common in LVA patients at presentation but not in LVPA. LVPA is mainly located on the posterior and inferior, and LVA is on the anterior and apical segments. On cardiac MRI, pericardial LGE may suggest the presence of LVPA rather than LVA in suspected patients.

**Keywords:** Left ventricular pseudoaneurysm, Left ventricular aneurysm, Myocardial infarction, imaging findings, clinical presentations

## Introduction

In patients with myocardial infarction (MI), during the acute phase or later, the left ventricular wall may become vulnerable to the formation of aneurysms. Most aneurysms, called true left ventricular aneurysm (LVA), are formed by an expansion of the thinned myocardium and contain residual elements of the myocardial wall. In rare cases, they are caused by the localized rupture of an infarcted area, known as false left ventricular aneurysm (LVPA).

As the wall of LVPA is made up of thrombus and/or pericardium without myocardial fibers (Figure.1), it is a more life-threatening entity, yet less known, than LVA (1–3). Still, differentiation between these outpouchings remains challenging and is of great importance for proper management; while LVA is often treated by elective surgery or medical treatment, LVPA mainly requires urgent surgical intervention (4,5).

While early diagnosis of LVPA and timely management are essential in reducing its mortality rate (6), our understanding of its clinical profile and imaging features is still limited and mainly comes from published case reports or case series. Also, up to our knowledge, no previous review study has compared clinical characteristics and imaging features between LVPA and LVA. In this comprehensive systematic review study, we have pooled data from post-MI cases reported since 1991 to provide better understanding of clinical and imaging features of LVPA. We have also compared these clinical and imaging findings between our pooled cohorts of LVPA and LVA cases to help physicians to distinguish these entities from each other.

## **Methods and materials**

Our study was conducted according to the Preferred Reporting Items for systematic reviews and Meta-analyses (PRISMA) guidelines (7). As a systematic review and meta-analysis of available literature, ethics committee approval was not required.

We included all eligible observational studies which reported imaging and clinical findings in patients with LVPA after myocardial infarction (MI). To compare these findings with those of the LVA, we also identify all studies with representative samples of patients with LVA following MI.

### **Search strategy**

We systematically searched online databases, including PubMed and Scopus, with additional manual search in google scholar on September 1st, 2022 using the combination of relevant keywords in two domains:

- 1) False [and True] Ventricular aneurysm
- 2) Myocardial infarction

Keywords from each domain were combined using the Boolean operator "OR", and domains were connected with the "AND" Boolean operator.

Furthermore, we also manually screened the reference list of included and similar articles for possible additional citations. All citations retrieved from databases were imported into EndNote X9 software (version EndNote X9.3.2, Captivate Analytics, California USA), then duplicates were removed.

We presented the detailed search string of each database in Supplementary Tables 1 & 2.

### **Study inclusion**

The title, abstract, and full text of imported studies were screened independently by two of our researchers [Ej& PS]. Eligible studies that met our inclusion criteria were included for review and meta-analysis. A third senior researcher [HR or NSH] resolved any disagreement between the researchers.

### **Selection Criteria**

Studies which met all of the following eligibility criteria were included in our review study:

- 1) Written in English.
- 2) Included patients with post-MI LVPA [or LVA for the comparison group].
- 3) Observational study design including case report, case series, or cohort studies

### **Data extraction**

Four researchers extracted the data from full-text articles into a data extraction form in Microsoft Excel. (Version 2016, Microsoft Corp., Redmond, WA, USA). We extracted the following data: First author's name, country, year, study design, sample size, age, sex, types of symptoms, time interval between last MI and diagnosis of the false [and true] aneurysm, cardiovascular disease risk factors and comorbidities, Electrocardiography (ECG), imaging findings [including chest X-ray, echocardiogram, CT-scan, and/or cardiac magnetic resonance imaging (CMR)], treatment strategies, follow-up duration and clinical outcomes, were also extracted from the included studies.

### **Risk of bias assessment**

The quality of included studies was assessed independently by two of our trained researchers. Any disagreements were resolved with discussion. We used the Joanna Briggs Institute (JBI) critical appraisal tool to appraise the quality of included studies. JBI's critical appraisal tool contained ten items and its total score ranges from 0 to 10 (8).

## Statistical analyses

Data extracted from case reports and case series with individual-level patient data (IPD) were combined into a single case series. Then this case series was pooled with other studies with aggregated level data (AD) using a standard meta-analysis method. We pooled the categorical variables, including gender, symptoms, risk factors, history of previous surgery, treatment strategy, in-hospital and follow-up death, infarction site, ECGs (electrocardiogram) results, and imaging results using meta-analysis of single proportions; continuous variables such as age, time from myocardial infarction to diagnosis, follow-up duration, and dimension size were combined using meta-analysis of mean and standard deviation. In all meta-analyses, a random-effect model was used to estimate the overall pooled proportion/mean and their 95% confidence intervals (CIs). Meta-analysis was conducted with R-studio version 4.2.2 software.

## Results

Detailed study selection process in detail for LVPA and LVA is presented in Supplementary figure 1 and 2, respectively. After removing duplicates and ineligible articles, we included 379 eligible articles on post-MI LVPA (N= 504 patients) (9–392) and 120 on post-MI LVA (n=20,968). (31,97,145,148,152,158,393–472)

Supplementary Table 3. shows the quality of the included case series; all studies scored eight or higher.

## Pseudoaneurysm

Characteristics of each included article are presented in Supplementary Table 4. Regarding the study type, 366 were case reports and 13 case series were published between 1991 to 2022. Cases were reported from 50 countries across the world; over 60% of them were reported from the USA (n=105), Turkey (n=63), and Italy (n=56). Echocardiography, mainly TTE (transthoracic echocardiography), was the most frequently utilized imaging modality for diagnosis. Over 90% (464/504) of reported cases underwent surgical treatment.

Table 1. shows the demographic and clinical characteristics of reported cases. Based on our pooled analysis, patients were predominantly male [70.4 % (95% CI: 65.8, 74.6)] with a mean age of 65.4 years (95% CI: 62.4, 68.4). They most frequently presented with CHF symptoms [45.5% (95% CI: 24.7, 67.1, available data: n=389), followed by dyspnea [43.3 % (95% CI: 24.4, 67.1, n=357), chest pain [39.2%, (95% CI:24.0, 55.4, n=409)]; with a less frequency, cardiogenic shock [10.0%, (95% CI: 0.4,58.8, n=352)], syncope [6.0%, (95% CI: 3.5, 8.9, n=340)], and arrhythmia [1.0% (95% CI:0.0, 2.9, n=241)] were also presented in these patients.



The time interval between the last MI and the diagnosis of LVPA varies from one day to 20 years (n=329); mean (95% CI) 5.1 (1.3, 8.9) months; according to this time interval, 29.0% of patients fell into the acute category (0, 14 days), 25.7% in subacute category (14, 90 days), and 45.5% into chronic category (more than 90 days) (Table 1).

Previous cardiac surgery was reported in 33.3% (95% CI:27.8, 39.2) of the cases (n=279), including CABG (21.1%) and valvular surgery (3.9%). History of smoking, hypertension, and diabetes mellitus was presented in 61.9% (24.2, 93.5), 52.2% (95% CI:21.8, 81.9), and 30.5% (CI 95%:16.9, 45.7) of patients, respectively. Previous cardiac surgery was reported in 33.3% (95% CI:27.8, 39.2) of the cases (n=279), including CABG (21.1%) and valvular surgery (3.9%). History of smoking, hypertension, and diabetes mellitus was presented in 61.9% (24.2 to 93.5), 52.2% (95% CI:21.8, 81.9), and 30.5% (CI 95%:16.9, 45.7) of patients, respectively (Table 1).

The ECG data on admission was available for 192 cases, of whom 185 (96.3%) had an abnormal finding(s), mainly ST-segment elevation (43.2% (95% CI:36.1, 50.1)), changes indicating old MI [42.7% (95% CI:35.6 to 50.0)], and/or tachycardia [9.4% (95% CI:5.6, 14.4)]. The location of infarction was, in order by frequency, inferior 37% (95% CI:21.8, 53.5), anterior 20.1 % (95% CI:11.6, 29.8), posterior 16.3% (95% CI:5.3, 31.0), and lateral in 9.0% (95% CI:5.9, 12.5).

The imaging findings are shown in table 3. Chest x-ray findings were reported in 92 patients; abnormalities cardiomegaly, cardiac mass, and cardiac silhouette sign were observed in [60.4% (95% CI: 50.2, 70.6), 35.1% (95% CI: 25.1, 45.1), and 25.2% (95% CI:16.1, 34.4)] of cases, respectively (Table 2).

Based on available data on Echocardiography evaluations (n=328), this imaging modality failed to diagnose LVPA in [18.6% (14.5, 23.2%)] of cases. The most frequent location of LVPA was posterior [34.5% (CI 95%:8.3, 66.3)], followed by inferior [21.2 (95% CI: 0.3, 47.2)], and

anterior 17.1% (CI 95%:3.7, 35.6). The mean (95% CI) LVEF was 36.5% (34.9, 38.0) (n=209). The mean (95% CI) of the two reported dimensions of the LVPA were 5.7 (95% CI: 5.2, 6.5, n=103) and 7.3 (CI 95%: 6.4, 8.2) centimeters (Table 2).

Data on Cardiac magnetic resonance was available in 85 patients. Common locations of the LVPA were inferior at 50.6% (CI 95%: 39.5, 61.6). The mean (95% CI), LVEF on MRI, reported in 18 patients, was 32.9% (CI 95%: 28.2, 37.6). Late gadolinium enhancement was reported in 25 patients which majority of them had pericardial LGE [84.0% (CI 95%: 63.9, 95.5)] (Table 2)..

A total of 114 cases underwent Computed tomography (CT) scan, mainly CT angiography (CTA) [49.5% (95% CI: 39.4, 59.6)]. The most prevalent location of LVPA in CT scans was inferior at 28.1% (95% CI: 20.1, 33.2), followed by apical at 24.5% (16.9, 33.5), posterior at 23.7% (95% CI: 16.2, 32.6). Hospital death and follow up death occur in 13.8% and 17.5% of LVPA cases, respectively (Table 2).

### **Comparisons between LVPA and LVA**

In both LVPA and LVA groups, over 70% of the cases were male (70.4% vs. 75.7 %, respectively), and their mean age fell in the seventh decade of life (65.4 vs. 60.8 years, respectively). Two groups were similar regarding the prevalence of cardiovascular disease risk factors, including; HTN, DM, hyperlipidemia, and smoking (Table 1).

On admission, while one out of three patients with LVA presented with arrhythmia, only one out of 100 LVPA patients showed this symptom; however, cardiogenic shock was more prevalent among LVPA than LVA group (10.0% vs. 6.1%, respectively). In addition, patients with LVPA less frequently had dyspnea (43.3% Vs. 63.9 %, respectively) chest pain (39.2% Vs. 56.9%,

respectively) and CHF symptoms (45.5% Vs. 59.7%, respectively) in comparison with those in LVA group (Table 1).

The mean time interval from MI to diagnosis was shorter in LVPA group than LVA (5.1 vs. 27.8, months, respectively). The most common previous cardiac surgery was CABG in both groups (Table 1).

On ECGs, LVPA group compared to LVA group more frequently showed ST-segment elevation (43.2% Vs. 28.6, respectively) but less frequently the changes indicating the old MI (42.2% Vs. 61.9, respectively). In addition, the most common location of infarction was inferior in the LVPA group [37% (95% CI:21.8, 53.5)] but the anterior segment in the LVA group [84.9% (95% CI: 66.8,97.0)] (Table 1).

On chest x-ray, a higher percentage of LVPA group had cardiac mass (35.1% vs. 20.8%) but a less percentage of them had evidence of cardiomegaly (60.4% vs. 66.7%) (Table 2).

Echocardiography had a lower sensitivity for diagnosis of LVPA compared to LVA group (81.4% vs. 97.5%). In contrast to LVPA that mainly located on posterior and inferior (34.5%,24.2%, respectively) segments, LVA involved apical and anterior segments (38.2%,35.2%, respectively). Patients with LVA had a higher mean (95% CI) LVEF than patients with LVPA [36.5% (34.9, 38.0) vs. 32.5% (29.7, 35.2)]. On cardiac MRI, approximately four out of five patients with LVPA (21/25) had a pericardial LGE, but none of five patients with LVA group had this pattern of LGE (Table 2).

The LVPA group compare to LVA group had a higher hospital mortality (13.8% vs. 4.7%, respectively) and follow up death (17.5% vs. 9.0%, respectively).

<b>Table 1. Clinical characteristics of LVPA and LVA patients</b>					
<b>Variable</b>		<b>Pseudoaneurysm</b>		<b>Aneurysm</b>	
		<b>Valid Sample size</b>	<b>Results</b>	<b>Valid Sample size</b>	<b>Results</b>
<b>Gender (male)</b>		504	70.4 (65.8-74.6)	20968	75.7 (69.3-81.6)
<b>Age (mean)</b>		503	65.4 (62.4-68.4)	20861	60.8 (58.9-62.8)
<b>Symptoms</b>	Dyspnea	357	43.3 (24.4-63.2)	736	63.9 (38.8-85.7)
	Chest pain	409	39.2 (24.0-55.4)	1857	56.9 (43.1-70.2)
	CHF	389	45.5 (24.7-67.1)	19514	59.7 (44.9-73.6)
	Shock	352	10.5 (0.4-58.8)	17714	6.1 (1.4-13.0)
	syncope	340	6.0 (3.5-8.9)	17711	6.3 (1.4-13.5)
	Arrhythmia	326	1.0 (0.0-2.9)	18978	33.8 (22.1-46.0)
	<b>Time from MI to diagnosis Mean</b>	Acute (day)		29.0 (23.4-35.2)	
Subacute (day)		241	25.7 (20.3-31.7)	29	55.2 (35.7-73.5)
Chronic (month)			45.2 (38.8-51.7)		24.1 (10.3-43.5)
Total (month)		329	5.1 (1.3-8.9)	18235	27.8 (17.4-37.2)
<b>Risk factor</b>	HTN	312	52.2 (21.8-81.9)	1649	58.8 (50.4-67.1)
	DM	349	30.5 (16.9-45.7)	1993	27.5 (22.3-33.0)
	Smoker	342	61.9(24.2-93.5)	373	50.7 (28.9-72.4)
	Hyperlipidemia	35	65.9 (229.6-94.9)	385	52.2 (19.4-84.0)
	<b>Previous surgery</b>	CABG		21.1 (16.5-26.4)	
Valvular		279	3.9 (1.9-6.9)	73	2.7 (0.3-9.5)
Without surgery			69.9 (64.1-75.2)		82.2 (71.4-90.1)
<b>Treatment</b>	Surgery	471	95.5 (84.2-100)		72.3 (60.9-82.0)
	Conservative		20.8 (16.3-25.5)	76	26.3 (16.8-37.7)
<b>Hospital death</b>	Intervention	341	6.5 (4.1-9.6)		1.3 (0.03-7.1)
		384	13.8 (9.9-18.1)	18204	4.7 (2.9-6.8)
<b>Follow up</b>	Follow up duration Mean (month)	88	22.1 (5.7-38.3)	647	47.3 (29.2-65.4)
	Follow up death	123	17.5 (10.4-25.7)	647	9.0 (4.8-14.1)
<b>ECG</b>	ST elevation		43.2 (36.1-50.5)		28.6 (17.8-41.3)
	Old MI		42.7 (35.6-50.0)		61.9 (48.8-73.9)
	Tachycardia	192	9.4 (5.6-14.4)	63	22.2 (12.7-34.5)
	Normal		3.6 (0.1-7.3)		6.3 (1.7-15.4)
<b>Infarction site</b>	Inferior		37.0 (21.8-53.5)	18063	11.9 (6.2-19.0)
	Anterior		20.1 (11.6-29.8)	18965	84.9 (66.8-97.0)
	Lateral	490	9.0 (5.9-12.5)	759	3.9 (0.3-10.3)
	Posterior		16.3 (5.3-31.0)	1091	4.2 (0.1-12.4)

Data presented as percentage (%) and 95% confidence intervals. CABG, coronary artery bypass graft; CHF, congestive heart failure; DM, diabetes mellitus; HTN, hypertension; LVPA, left ventricular pseudoaneurysm; MI, myocardial infarction; NA, not applicable; PA, pseudoaneurysm;

**Table 2.** imaging findings of LVPA and LVA patients

Diagnostic imaging			Pseudoaneurysm		Aneurysm	
			Valid sample size	Result	Valid sample size	Result
<b>Chest x-ray</b>	Cardiomegaly			60.4 (50.2-70.6)		66.7 (44.7-84.4)
	Cardiac mass		91	35.1 (25.1-45.1)	24	20.8 (7.1-42.1)
	Cardiac silhouette sign			25.2 (16.1-34.4)		12.5 (2.6-32.3)
	Normal			9.7 (3.6-15.9)		12.5 (2.6-32.3)
<b>Echocardiography</b>	Diagnosis on Echo		328	81.4 (76.8-85.5)	80	97.5 (91.2-99.7)
	Type	TTE:		81.7 (77.1-85.7)		87.3 (77.9-93.7)
		Doppler		13.1 (9.6-17.2)		1.2 (0.03-6.8)
		TEE	328	12.2 (8.8-16.2)	79	10.1 (4.4-18.9)
		Contrast echo		1.2 (0.3-3.1)		2.5 (0.03-8.8)
	Location of outpouching	Apical		13.8 (9.8-18.3)	1925	38.2 (11.9-71.1)
		Inferior		21.2 (3.0-47.2)	1925	1.1 (0.0-3.2)
		Anterior	329	17.1 (3.7-35.6)	1848	35.2 (8.7-67.9)
		Lateral		6.4 (1.5-13.5)	1807	0.7 (0.0-2.3)
		Posterior		34.5 (8.3-66.3)	1925	8.5 (3.6-14.9)
		PA dimension1	103	5.7 (5.2-6.5)	25	8.3 (6.0-10.6)
	Diameters Mean (cm)	PA dimension2	37	7.3 (6.4-8.2)	19	6.2 (4.5-7.9)
		Neck dimension1	12	4.1 (2.7-5.3)	9	4.4 (3.2-5.6)
		Neck dimension2	7	2.5 (0.4-4.7)	NA	
	Clot presentation		66	92.4 (83.2-97.5)	80	90.0 (81.2-95.6)
LVEF (mean)		209	36.5 (34.9-38.0)	2488	32.5 (29.7-35.2)	
<b>Cardiac magnetic resonance</b>	Location	Apical		24.7 (15.9-35.2)		45.4 (24.4-67.8)
		Inferior		50.6 (39.5-61.6)		45.4 (24.4-67.8)
		Anterior	85	2.4 (0.2-8.2)	22	0
		Lateral		15.3 (8.4-24.7)		9.2 (1.1-2.9)
		Posterior		15.3 (8.4-24.7)		0
		Basal		7.1 (2.6-14.7)		0
	Diameters Mean (cm)	PA dimension1	29	6.2 (3.9-8.2)	9	5.8 (2.3-9.5)
		PA dimension2	11	10.0 (7.0-11.0)	9	6.9 (4.8-9.1)
		Neck dimension1	4	3.0 (2.25-3.0)		NA
	Clot presentation	Neck dimension2	4	3.8 (1.9-5.4)		NA
			47	95.7 (85.4-99.5)	9	88.9 (51.7-99.7)
LVEF (mean)		18	32.9 (28.2-37.6)		NA	
<b>LGE</b>	Pericardial		25	84.0 (63.9-95.5)	5	0
	Myocardial			16.0 (4.5-36.1)		80.0 (28.3-99.5)
<b>CT scan</b>	Location	Apical	114	24.5 (16.9-33.5)	19	42.1 (20.2-66.5)

	Inferior		28.1 (20.1-37.2)		26.3 (9.1-51.2)
	Posterior		23.7 (16.2-32.6)		10.5 (1.3-33.1)
	Lateral		19.3 (12.5-27.7)		15.8 (3.3-39.6)
	Anterior		9.6 (4.9-16.6)		5.2 (0.1-26.0)
	Basal		6.1 (2.5-12.2)		0
	CT angiography		49.5 (39.4-59.6)		35.3 (14.2-61.7)
Type of the CT	Cardiac CT scan	101	36.6 (27.2-46.8)	17	52.9 (27.8-77.0)
	Chest CT scan		13.9 (7.7-22.1)		11.8 (1.4-36.4)
	PA dimension1	55	6.9 (5.6-8.1)	11	6.7 (4.9-8.4)
Diameters	PA dimension2	23	12.1 (3.7-20.6)	11	5.6 (4.4-6.8)
Mean (cm)	Neck dimension1	11	4.0 (2.1-6.1)		NA
	Neck dimension2	7	2.8 (0.6-4.9)		NA

Data presented as percentage (%) and 95% confidence intervals.; cm, centimeter; CT, computed tomography; LVA, left ventricular aneurysm; LVEF, left ventricular ejection fraction; LVPA, left ventricular pseudoaneurysm; MRI, magnetic resonance imaging; NA, not applicable; PA, pseudoaneurysm; TEE, trans esophageal echocardiography; TTE, trans thoracic echocardiography

## Discussion

This comprehensive pooled clinical and imaging data of all available studies describing LVPA after MI and compared the findings with those in a pooled cohort of LVA patients.

Since 1991, a total of 504 cases of LVPA following MI have been reported worldwide. The reported cases predominantly were male, and their age varied from 33 to 97 years old. In About half of the cases, LVPA was diagnosed 90 days or more (chronic LVPA) after the last MI. CHF symptoms were reported in nearly one out of three cases at the presentation; also, cardiogenic shock occurred in 10% of them on admission. A little more than 20% of the patients had a previous history of CABG. The most common abnormalities on ECG were STE and changes indicating old MI, and on CXR was cardiomegaly and cardiac mass, respectively. Approximately 80% of LVPA were diagnosed by echocardiography; the most common locations of PA were posterior, followed by inferior.

The LVPA patients were roughly older than LVA patients but gender was mainly male in both groups. Regarding clinical symptoms on admission, arrhythmia was common in the LVA group but not in LVPA. LVPA patients had a shorter mean time interval from the last MI to diagnosis compared to LVA patients. Contrary to LVPA, the most common location of LVA was apical and anterior. LVEF was a little higher in the LVPA group. ST-segment elevation was observed less frequently in LVA cases, and cardiomegaly was the most common finding on CXR in these patients. Contrary to LVA, pericardial LGE was a common finding in the LVPA patients on cardiac MRI. Hospital mortality was about three times higher in the LVPA group compared to the LVA group. About 95% and 73% of LVPA and LVA cases were treated surgically, respectively.

Gender pattern in LVPA and LVA was roughly the same and similar to MI; about 70% of MI cases are male. However, LVA patients were slightly older than the LVPA group (473,474).

Post-MI LVPA occurs when a pericardial adhesion restricts a true rupture of the ventricular wall, but LVA appears following cardiac remodeling that leads muscle fiber cells to change the geometry of the left ventricular cavity and form LVA (475). Aging is associated with the increased risk of impaired ventricular remodeling, a possible mechanism involved in LVA. In fact, elderly patients more frequently experience suppressed post-MI inflammation, which is vital to prevent ventricular remodeling (476).

A higher rate of arrhythmia observed in LVA than in LVPA could be justified by their different possible etiology; indeed, structural remodeling is associated with the development of areas of slow conduction and conduction block, resulting in the occurrence of arrhythmias (233,477).

Also, LVPA patients may more likely develop cardiogenic shock than LVA patients due to a higher risk of cardiac tamponade and ventricular rupture. As LVPA occurs more commonly in the acute phase of the infarction but LVA in the chronic phase, LVPA was mainly characterized by STE and LVA by signs of old MI on ECG.

LVPA is a life-threatening and emergency condition and more frequently results in worse outcomes compared to LVA; based on our pooled analysis, LVPA patients dead approximately 2 to 3 times more than their counterparts in the LVA group during the hospitalization and after discharge.

Still, early diagnosis can lead to timely management and improve the prognosis in the affected patients. In this way, the distinction between different outpouchings of the left ventricle, i.e., LVPA and LVA, is imperative for choosing a proper treatment strategy. While almost all



patients, with or without symptoms, in the LVPA group undergo cardiac surgery, management strategy in LVA is largely determined based on the presence of symptoms (478).

The availability, cost-effectiveness, and safety of echocardiography have made it the most utilized imaging modality in assessing structural heart diseases, including outpouchings of the left ventricle. Based on our pooled analysis, echocardiography has failed to detect the presence of LVAP in about 20% of cases but showed a better performance in diagnosing LVA (479). Some echocardiography features, such as the location of observed outpouchings and neck diameters, could also help to distinguish LVPA from LVA; contrary to LVA, LVPA is more frequently located on the posterior and inferior segments. Their different locations of infarction could explain this difference (480). However, another proposed explanation is that patients with anterior LVPA are at an increased risk of ventricular rupture leading to death before diagnosis (481).

Contrary to LVA, LVPA is usually characterized by a narrow neck on TTE echocardiography, which manifests as a turbulent flow on Doppler echocardiography (1,482); noteworthy, some chronic LVPA may have a wide base similar to LVA, causing misdiagnosis. However, most included studies failed to provide data on neck diameters in both groups.

MRI and CT scans, especially CT angiography, have higher accuracy than echocardiography for diagnosis of cardiac outpouchings, including LVPA; though, in practice, their utilization is limited by factors such as less availability, no portability, and high costs (483).

Available evidence suggests that pericardial LGE can be a helpful tool in differentiating LVPA from LVA [2]. Indeed, LGE presents in the wall of the aneurysm sac in both LVPA and LVA on cardiac MRI, but delayed enhancement of the pericardium is thought to be a characteristic feature of pseudoaneurysm. It indicates the presence of pericardial inflammation and fibrosis

induced by leakage of blood into the pericardial space subsequent to ventricular rupture (484,485).

### **Limitations and strengths**

As a review of published studies, our pooled data sets were incomplete for some variables, especially imaging features, likely due to the retrospective nature of the design of the included studies. Also, our review lacked confirmation of imaging findings by a core laboratory as we pooled data from published case series /reports. However, given the detailed protocols reported by most studies regarding the actual images, the validity of imaging findings can be considered acceptable.

using a comprehensive search of online databases, we included all relevant studies describing patients with post-MI LVPA; Given the small number of patients reported by each case series/case reports, this pooled cohort can promote the current understanding of the clinical and imaging findings in LVPA after MI. we also and compared the findings in LVPA with those in a pooled and large cohort of LVA patients to help physicians for differentiating these outpouchings.

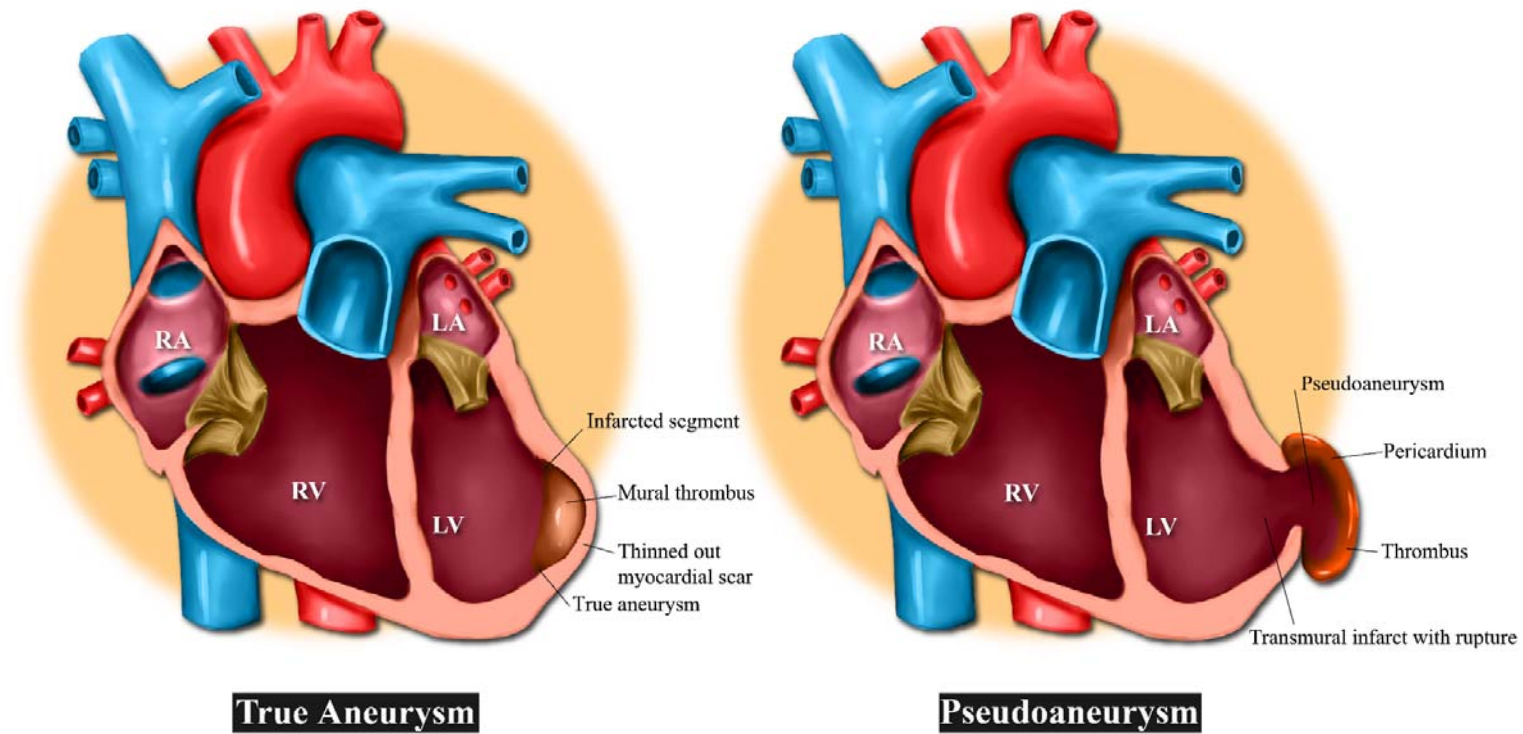
### **Conclusion**

Our pooled cohort suggests that LVPA is probably located on the posterior and inferior segments in most patients, contrary to the LVA that mainly involved the anterior and apical segments. Arrhythmia is likely a common clinical finding in LVA but not LVPA. Most ECG abnormalities might be ST-Elevation in LVAP and changes suggesting old MI in LVA. Cardiac mass on CXR may represent the presence of LVPA more than LVA. Echocardiography may fail to detect the

presence of LVPA in one out of five patients. On cardiac MRI, pericardial LGE may suggest the presence of LVPA than LVA in suspected patients.

### **Acknowledgment**

Researchers appreciated the Clinical Research Development Units of Kamali and Rajaei Hospitals in Alborz University of Medical Sciences.



**Figure1:** Pseudoaneurysm versus True aneurysm of the left ventricle



## References:

1. Kalisz K, Rajiah P. Radiological features of uncommon aneurysms of the cardiovascular system. *World J Radiol.* 2016;8(5):434.
2. Torchio F, Garatti A, Ronco D, Matteucci M, Massimi G, Lorusso R. Left ventricular pseudoaneurysm: the niche of post-infarction mechanical complications. *Ann Cardiothorac Surg.* 2022 May;11(3):290–8.
3. Friedman BM, Dunn MI. Postinfarction ventricular aneurysms. *Clin Cardiol.* 1995 Sep;18(9):505–11.
4. García-Lledó A, Moya-Mur JL, de Juan J, García-Pérez-Velasco J, Sanz A, Díaz-Caraballo E. Long-Term Survival of Chronic Left Ventricular Pseudoaneurysm in Elderly Adults. Is Surgery the Best Option? *J Am Geriatr Soc.* 2014 Nov;62(11):2224–5.
5. Solowjowa N, Nemchyna O, Hrytsyna Y, Meyer A, Hennig F, Falk V, et al. Surgical Restoration of Antero-Apical Left Ventricular Aneurysms: Cardiac Computed Tomography for Therapy Planning. *Front Cardiovasc Med.* 2022 Mar 28;9:763073.
6. Frances C, Romero A, Grady D. Left ventricular pseudoaneurysm. *J Am Coll Cardiol.* 1998 Sep;32(3):557–61.
7. Page MJ, McKenzie JE, Bossuyt PM, Boutron I, Hoffmann TC, Mulrow CD, et al. The PRISMA 2020 statement: An updated guideline for reporting systematic reviews. *PLOS Med.* 2021 Mar 29;18(3):e1003583.
8. Munn Z, Barker TH, Moola S, Tufanaru C, Stern C, McArthur A, et al. Methodological quality of case series studies: an introduction to the JBI critical appraisal tool. *JBI Database Syst Rev Implement Rep [Internet].* 2019 Sep 23 [cited 2023 Feb 21]; Publish Ahead of Print. Available from: <https://journals.lww.com/10.11124/JBISRIR-D-19-00099>
9. Abbood A, Al Salihi H, Olivier M, Khawaja F, Madruga M, Carlan SJ. Left Ventricular Pseudoaneurysm and Left Ventricular Thrombus in a Patient Presenting with an Acute ST-Elevation Myocardial Infarction. *Am J Case Rep [Internet].* 2021 Nov 22 [cited 2023 Feb 10];23. Available from: <https://www.amjcaserep.com/abstract/index/idArt/934272>
10. Abdelnaby M, Almaghraby A, Saleh Y, Hammad B, El-Amin A, El-Fawal S, et al. A Case of Left Ventricular Pseudoaneurysm. 2017;
11. Afonso Nogueira M, Fiarresga A, de Sousa L, Agapito A, Galrinho A, Cruz Ferreira R. Percutaneous closure of a giant left ventricular wall pseudoaneurysm: Anterograde approach with a double snare technique. *Rev Port Cardiol Engl Ed.* 2016 Jul 1;35(7):441.e1-441.e4.
12. Akcakoyun M. A giant posterolateral wall pseudoaneurysm presented with ventricular tachycardia. *Turk Kardiyol Dernegi Arsivi-Arch Turk Soc Cardiol [Internet].* 2016 [cited 2023 Feb 10]; Available from: <https://archivestsc.com/jvi.aspx?un=TKDA-47227>
13. Akgun S, Keser N, Yildirim T, Arsan S. Missed Diagnosis of Unruptured, Huge Left Ventricular Pseudoaneurysm. *Echocardiography.* 2003 Jan;20(1):75–6.
14. Akyuz AR. Unruptured left ventricular pseudoaneurysm presenting as mitral stenosis. *Turk Kardiyol Dernegi Arsivi-Arch Turk Soc Cardiol.* 2012;40(8):745–745.
15. Al Lawati A, Al-Hadhrami W, Al Hosni F, Al Lawati M, Elseragy E, Sirasanagandla S, et al. A Rare Case of a Left Ventricular Pseudoaneurysm With Lateral Wall Rupture. *Cureus [Internet].* 2022 Mar 7 [cited 2023 Feb 10];

Available from: <https://www.cureus.com/articles/88032-a-rare-case-of-a-left-ventricular-pseudoaneurysm-with-lateral-wall-rupture>

16. Al Saidi K, Malik SA, Albulushi A, Moulton M, Chatzizisis YS. Left Ventricular Pseudoaneurysm Complicated With Very Late Rupture 5 Years After Myocardial Infarction. *JACC Case Rep*. 2019 Dec;1(4):569–72.
17. Al-Mehisen R, Chan KL. Pulsatile Chest Wall Mass Complicating Myocardial Infarction: Assessment by Two-Dimensional, Three-Dimensional, and Contrast Echocardiography. *Can J Cardiol*. 2014 Jun;30(6):697.e3-697.e4.
18. Al-Naabi MJ, Maddali MM, Venkatachlam R. Mechanical Complication After a Myocardial Infarction. *J Cardiothorac Vasc Anesth*. 2021 Feb;35(2):670–2.
19. Alapati L. Left ventricular pseudoaneurysm: A case report and review of the literature. *World J Clin Cases*. 2014;2(4):90.
20. Alexanderson-Rosas E, Mondaca-Garcia O, Zambrano-Guatibonza H, Flores-Garcia A, Carvajal-Juarez I, Espinola-Zavaleta N. Multimodality assessment of ventricular pseudoaneurysm after non-reperused acute myocardial infarction. *J Nucl Cardiol*. 2019;26(4):1368–72.
21. Alexandrescu C, Civaia F, Dor V. Visualization of pseudoaneurysm of the left ventricle by magnetic resonance imaging. *Eur J Cardiothorac Surg*. 2007 Nov;32(5):798.
22. Aliyev N, Ibrahim M. Cardiac Magnetic Resonance Imaging of Massive Left Ventricular Pseudoaneurysm.
23. Alizadeh Sani Z, Salehi M, Ghadroost B, Jafarpour M, Behjati M. Recurrent Left Ventricular Apical Pseudoaneurysm at the Site of Previous Patch Repair; a Case Report. *Multidiscip Cardiovasc Ann [Internet]*. 2022 May 17 [cited 2023 Feb 10];13(1). Available from: <https://brieflands.com/articles/mca-119528.html>
24. Allende NG, Santos R, Sokn FJ, Merino SA, Accastello GM, Medina JC, et al. Unusual presentations of cardiac rupture during COVID-19 pandemic. *Echocardiography*. 2021 Mar;38(3):469–72.
25. Alshammari BS, Reardon MJ, Nabi F. Late Left Ventricular Pseudoaneurysm after Acute Myocardial Infarction. *Methodist DeBakey Cardiovasc J*. 2017 Jul 1;13(3):169.
26. Alshehri HZ, Momenah TS, AlBaradai A, Sallam A, Alassal MA, Lawand S. Successful percutaneous closure of post myocardial infarction left ventricular ruptured pseudoaneurysm after failed surgical repair. *J Cardiol Cases*. 2014 Apr;9(4):154–7.
27. Amin S, Hossain R, Jeudy J, Frazier AA, White C. A Sensible Approach to Diagnosing Cardiac Aneurysms, Pseudoaneurysms and Common Mimickers. *J Thorac Imaging*. 2018 Nov;33(6):W39–47.
28. Ancona MB, Visco E, Bellini B, Romano V, Vella C, Ferri L, et al. Percutaneous exclusion of left ventricular pseudoaneurysm. *J Cardiovasc Med*. 2021 Nov;22(11):864–5.
29. Ando S ichi, Kadokami T, Momii H, Hironaga K, Kawamura N, Fukuyama T, et al. Left Ventricular False-pseudo and Pseudo Aneurysm: Serial Observations by Cardiac Magnetic Resonance Imaging. *Intern Med*. 2007;46(4):181–5.
30. Andrade LC, Donato P, Ferreira MJ, Alves FC. LEFT VENTRICULAR FALSE ANEURYSM CHARACTERIZED BY CARDIOVASCULAR MAGNETIC RESONANCE AND LATE ENHANCEMENT TECHNIQUE.
31. Andrew Burger. Left Ventricular Pseudoaneurysm. 2001;

32. Anguita-Gámez M, Negreira-Caamaño M, Nuñez I, Marcos-Alberca P, Vidal M, Hernández P, et al. Apical left ventricular pseudoaneurysm: Diagnosis by multimodal cardiac imaging. *Cardiol J*. 2022 May 31;29(3):527–8.
33. Aoyagi S, Tayama K, Otsuka H, Okazaki T, Shintani Y, Wada K, et al. Sutureless Repair for Left Ventricular Free Wall Rupture After Acute Myocardial Infarction: SUTURELESS REPAIR FOR LVFWR. *J Card Surg*. 2014 Mar;29(2):178–80.
34. Arsanjani R, Lohrmann G, Allen S, Unzek S, Mookadam F. A Multi-Modality Approach to Left Ventricular Aneurysms: True vs False. *Am J Med*. 2016 Aug;129(8):e113–6.
35. Arslan S, Erkut B, Ates A, Kantarci M, Kalkan ME, Karakelleoglu S. Pseudoaneurysm of left ventricular following left ventricular apical venting. *Clin Res Cardiol*. 2009 Apr;98(4):280–2.
36. Arslantaş U, Kiliçgedik A, Çersit S, Acar RD, Pala S. A fifteen years old left ventricular pseudoaneurysm. *Int J Cardiol*. 2016 Jan;203:527–8.
37. Ashraf H, Sadatnaseri A, Aminorroaya A, Kuhi Z, Zandi N, Karbalai Saleh S. Left Ventricular Pseudoaneurysm as a Complication of Myocardial Infarction; A Case Series and Review of the Literature. *Front Emerg Med [Internet]*. 2021 Apr 4 [cited 2023 Feb 10]; Available from: <https://18.184.16.47/index.php/FEM/article/view/5892>
38. Asil S, Barış VÖ, Department of Cardiology, Dr. Ersin Arslan Training and Research Hospital, Gaziantep, Turkey, Görmel S, Department of Cardiology, Gülhane Training and Research Hospital, Ankara, Turkey, Çelik M, et al. Giant ventricular pseudoaneurysm and associated eccentric severe mitral regurgitation: Surgery or follow-up? *Turk Kardiyol Dernegi Arsivi-Arch Turk Soc Cardiol*. 2021 Dec 4;49(8):688–92.
39. Atik FA, Navia JL, Vega PR, Gonzalez-Stawinski GV, Alster JM, Gillinov AM, et al. Surgical Treatment of Postinfarction Left Ventricular Pseudoaneurysm. *Ann Thorac Surg*. 2007 Feb;83(2):526–31.
40. Avegliano G, Conde D, Ruiz MIG, Kuschner P, Sciancalepore A, Castro F, et al. Lateral Left Ventricular Wall Rupture Following Acute Myocardial Infarction: Pathophysiological Interpretation by Multimodality Imaging Approach. *Echocardiography*. 2014 Nov;31(10):E296–9.
41. Avsar S, Keskin M, Velibey Y, Kemaloglu Oz T, Guvenc TS, Guzelburc O, et al. Incremental Utility of Real Time Three-Dimensional Transthoracic Echocardiography for the Assessment of Left Ventricular Free Wall Rupture Location, Orifice Geometry, and Complex Intracardiac Flow. *Echocardiography*. 2015 Nov;32(11):1738–41.
42. Azraai M, Ajani AE. Late Post- Infarction Left Ventricular Pseudoaneurysm: A Case Report. *Cardiovasc Revasc Med*. 2020 Jan;21(1):145–6.
43. Bağrıtan B, Vural M, Tekümit H, Demirtafl M. A giant left ventricular pseudoaneurysm with severe mitral regurgitation after silent inferior myocardial infarction resulting in cardiogenic shock.
44. Bai W. Left ventricular pseudoaneurysm following acute myocardial infarction. *Anatol J Cardiol [Internet]*. 2018 [cited 2023 Feb 10]; Available from: <https://anatoljcardiol.com/jvi.aspx?un=AJC-39001>
45. Baker WB, Klein MS, Reardon MJ, Zoghbi WA. Left Ventricular Pseudoaneurysm Complicating Mitral Valve Replacement: Transesophageal Echocardiographic Diagnosis and Impact on Management. *J Am Soc Echocardiogr*. 1993 Sep;6(5):548–52.
46. Baks T, Cademartiri F, Spierenburg HAM, Feyter PJ de. Chronic pseudoaneurysm of the left ventricle. *Int J Cardiovasc Imaging*. 2006 Jun;22(3–4):497–9.



47. Banisauskaite A, Velavan P, Hasleton J, Mediratta N, Arzanauskaite M, Binukrishnan S. Myocardial rupture and left ventricular pseudoaneurysm due to late STEMI presentation during the COVID-19 pandemic lockdown: a classical case report. Potter TD, Henzel J, Karamisis G, Bernstein BS, Sunjaya AP, editors. *Eur Heart J - Case Rep.* 2021 Jul 1;5(7):ytab253.
48. Bansal RC, Pai G, Hauck J, Isaefl DM, Linda L. rupture and formation Unique flow and color flow. 1992;
49. Bard JW. Anesthetic implications of subacute left ventricular rupture following acute myocardial infarction: A case report.
50. Bekkers SCAM, Borghans RAP, Cheriex EC. Ventricular pseudoaneurysm after subacute myocardial infarction. *Int J Cardiovasc Imaging.* 2006 Nov 8;22(6):791–5.
51. Bettex DA, Vogt PR, Jenni R, Schmid ER. Unusual intraoperative impact of transesophageal echocardiography during the correction of a persistent pseudoaneurysm perfused from the left ventricular outflow tract. *J Cardiothorac Vasc Anesth.* 2002 Feb;16(1):80–2.
52. Bhardwaj R, Sondhi S, Mehta A. Unruptured giant left ventricular pseudoaneurysm after silent myocardial infarction. *BMJ Case Rep.* 2018 Jul 18;bcr-2018-225812.
53. Bhullar AS, Sandhu CS, Bhullar MS, Rathod A. Unusual presentation of left ventricular rupture. *BMJ Case Rep.* 2020 Jan;13(1):e231680.
54. Bildirici U, Agacdiken A, Ural E, Kahraman G, Komsuoglu B. Two Cases with Similar Pseudoaneurysms but Different Outcomes. *Clin Cardiol.* 2009 Jun;32(6):E59–61.
55. Bisoyi S, Dash A, Nayak D, Sahoo S, Mohapatra R. Left ventricular pseudoaneurysm versus aneurysm a diagnosis dilemma. *Ann Card Anaesth.* 2016;19(1):169.
56. Biswas A, Wilson J, Mukherjee D. An uncommon presentation of a cardiac pseudoaneurysm. *Indian Heart J.* 2010;62(4):361–2.
57. Bohdiewicz PJ. Single Photon Emission Computed Tomography Radionuclide Ventriculography in the Noninvasive Diagnosis and Evaluation of a False Left Ventricular Aneurysm (Pseudoaneurysm): *Clin Nucl Med.* 2003 Oct;28(10):821–6.
58. Bolognesi R, Cucchini F, Lettieri C, Manca C, Visioli O. Left ventricular false aneurysm: An unusually prolonged natural history. *Cathet Cardiovasc Diagn.* 1995 Sep;36(1):46–50.
59. Brennan S, Sulong S, Barrett M. Left ventricular pseudoaneurysm: an inadvertent consequence of COVID-19—a case report. Bouzas-Mosquera A, Henzel J, Mitsis A, Simovic S, Chakir M, editors. *Eur Heart J - Case Rep.* 2021 Jul 1;5(7):ytab203.
60. Bryniarski L, Kubinyi A, Ekiert-Kubinyi M, Kawecka-Jaszcz K. Postinfarction left ventricular pseudoaneurysm with left-to-right shunt: Case report and review of the literature. *Int J Cardiol.* 2010 Mar;139(2):199–201.
61. Burns CA, Paulsen W, Arrowood JA, Tolman DE, Rose B, Fabian JA, et al. Improved identification of posterior left ventricular pseudoaneurysms by transesophageal echocardiography. *Am Heart J.* 1992 Sep;124(3):796–9.
62. Butz T, Faber L, Langer C, Horstkotte D. Giant left ventricular pseudoaneurysm: a rare complication following left ventricular rupture caused by myocardial infarction. *Eur Heart J.* 2008 Jan;29(2):143–143.

63. Cacciapuoti F, Tirelli P, Cacciapuoti F. Left ventricular postinfarction pseudoaneurysm: diagnostic advantages of three-dimensional echocardiography. *J Cardiovasc Echography*. 2017;27(2):74.
64. Çakir H, Alizade E, Açar G, Bayram Z, Esen AM. A large left ventricular pseudoaneurysm evaluated with multimodality cardiac imaging. *J Cardiovasc Med [Internet]*. 2012 Jul 16 [cited 2023 Feb 10]; Publish Ahead of Print. Available from: <https://journals.lww.com/01244665-900000000-99264>
65. Caldeira A, Albuquerque D, Coelho M, Côrte-Real H. Left Ventricular Pseudoaneurysm: Imagiologic and Intraoperative Images. *Circ Cardiovasc Imaging*. 2019 Dec;12(12):e009500.
66. Cardinale L, Bosa M, Destefanis P, Giorcelli R. Left ventricular pseudoaneurysm diagnosed with multi-detector computer tomography. *Eur J Cardiothorac Surg*. 2008 Aug;34(2):450–450.
67. Carvalho D, Mimoso J, de Jesus I, Fragata J. One aneurysm and two pseudoaneurysms, same patient. *BMJ Case Rep*. 2019 Feb;12(2):bcr-2018-227566.
68. Casolo G, Rega L, Stefano P, Gensini G. False aneurysm of the left ventricle. Diagnosis by magnetic resonance imaging. *Int J Cardiol*. 2005 Feb;98(3):509–10.
69. Catena E, Sozzi F, Trunfio S, Montrasio E, Nonini S, Tarelli G. Left ventricular pseudoaneurysm associated with septal ventricular rupture following myocardial infarction. *J Cardiovasc Med*. 2010 Feb;11(2):140–2.
70. Çelebi AS, Çelebi ÖÖ, Diker E. A huge left ventricular pseudoaneurysm manifesting as acute dyspnea. *Int J Cardiovasc Acad*. 2015 Jun;1(1):29–30.
71. Chakraborty RN, Nicholson AA, Alamgir MF. Magnetic resonance images of left ventricular pseudoaneurysm. *Heart*. 1998 Jul 1;80(1):101–2.
72. Chang G, Lim RTC, Vu TD, Kofidis T, Ti LK. Three-Dimensional Transesophageal Echocardiography in the Excision of a Myocardial Pseudoaneurysm. *Anesth Analg*. 2015 Dec;121(6):1464–6.
73. Chatelain P, Didier D. Detection of myocardial rupture by cine-magnetic resonance imaging. *Am J Cardiol*. 1994 May 15;73(13):1033–5.
74. Chatterjee T, Meier B, Zanchin L, Streuli RA, Meyer BJ. Left ventricular pseudoaneurysm. *Clin Cardiol*. 1999 Nov 11;22(11):752–752.
75. Cho MN, Mehta SK, Matulevicius S, Weinstein D, Wait MA, McGuire DK. Differentiating True Versus Pseudo Left Ventricular Aneurysm: A Case Report and Review of Diagnostic Strategies. *Cardiol Rev*. 2006 Nov;14(6):e27–30.
76. Cicienia M, Fedele F, Petronilli V, De Carlo C, Moscucci F, Schina M, et al. Hidden in the heart: A peculiar type of left ventricular remodeling after acute myocardial infarction. *Echocardiography*. 2017 Nov;34(11):1738–9.
77. Coelho SG, Jorge CF, Carlos PB, Delgado A, Vicente L. Infarto do Miocárdio Inferior Evoluído com Pseudoaneurisma do Ventrículo Esquerdo: Um Dilema Diagnóstico. *Arq Bras Cardiol*. 2020 May 12;114(4):730–1.
78. Colletta M, Rubboli A, Di Pasquale G. Left ventricular pseudoaneurysm protruding outside the chest wall: *J Cardiovasc Med*. 2006 Oct;7(10):779.
79. Collier P, Phelan D, Soltesz E, Aljaroudi W. Left Ventricular Pseudoaneurysm: “To-and-Fro” Flow. *J Am Coll Cardiol*. 2013 Feb;61(8):896.

80. Coner A, Okyay K, Pirat B, Sezgin A, Muderrisoglu H. A Giant Left Ventricular Pseudoaneurysm Presenting with Severe Mitral Regurgitation.
81. Contuzzi R, Gatto L, Patti G, Goffredo C, D'Ambrosio A, Covino E, et al. Giant left ventricular pseudoaneurysm complicating an acute myocardial infarction in patient with previous cardiac surgery: a case report: *J Cardiovasc Med*. 2009 Jan;10(1):81–4.
82. Cortese F, Costantino MF, Ciccone MM, Calculli G. A perforated cardiac pseudoaneurysm complicating an acute myocardial infarction: *J Cardiovasc Med*. 2018 Dec;19(12):756–7.
83. Cruz I, Cotrim C, Lopes L, Fazendas P, Pereira H. A Very Complicated Inferior Myocardial Infarction: The Role of Multimodality Imaging Approach. *Arq Bras Cardiol [Internet]*. 2016 [cited 2023 Feb 10]; Available from: [https://www.scielo.br/scielo.php?script=sci\\_arttext&pid=S0066-782X2016000500450](https://www.scielo.br/scielo.php?script=sci_arttext&pid=S0066-782X2016000500450)
84. Csapo K, Voith L, Szuk T, Edes I, Kereiakes DJ. Postinfarction Left Ventricular Pseudoaneurysm. *Clin Cardiol*. 2009 Feb 3;20(10):898–903.
85. D'Antuono F, Stanzione A, Tucci AG, Pizza S, Venetucci P. An unusual cause of acute thoracic pain: left ventricular pseudoaneurysm. *Intern Emerg Med*. 2018 Dec;13(8):1329–31.
86. Daglar B, Celkan MA, Kazaz H, Ustunsoy H, Davutoglu V. Surgical Treatment of Postinfarction Left Ventricular Pseudoaneurysm. *J Card Surg*. 2004 Nov;19(6):544–6.
87. Davutoglu V, Soyduinc S, Sezen Y, Aksoy M. Unruptured giant left ventricular pseudoaneurysm complicating silent myocardial infarction in a diabetic young adult: Left ventricular giant pseudoaneurysm after silent myocardial infarction. *Int J Cardiovasc Imaging*. 2005 Apr;21(2–3):231–4.
88. De Castro S. Helping the surgeon: epicardial 3D echocardiography in aortic dissection. *Heart*. 2006 Jul 19;92(9):1237–1237.
89. DeCicco AE, Alaiti MA, Ali J, Cohen JN, Deo SV, Parikh SA, et al. A Thoracotomy Approach for the Surgical Repair of a Left Ventricular Free Wall Rupture. *Ann Thorac Surg*. 2016 Mar;101(3):e79–82.
90. Delgado C, Durán RM, Serra E, Barturen F. Left ventricular pseudoaneurysm with left atrium tamponade: A rare postinfarction complication. *J Am Soc Echocardiogr*. 1997 Jun;10(5):582–7.
91. Della Rocca DG, Forleo GB, Stazi CA, Franco G, Volpe GA, Romeo F. Massive Left Ventricular Pseudoaneurysm 20 Years After Acute Myocardial Infarction. *J Am Coll Cardiol*. 2013 Dec;62(23):e523.
92. Demir, Şahin, İltumur. A giant left ventricular pseudoaneurysm like an “ hourglass ” after silent myocardial infarction. In 2016.
93. Demirozu ZT, Akay MH, Frazier OH. Left Ventricular Pseudoaneurysm Arising Between Two Papillary Muscles: Repair Without Mitral Regurgitation. *J Card Surg*. 2010 Nov;25(6):668–70.
94. Depboylu BC, Hachulla AL, Testuz A, Cikirikcioglu M. Left ventricular free wall rupture contained by an apical pseudo-aneurysm. *Eur Heart J*. 2015 Nov 7;36(42):2898.1-2898.
95. Dewilde W, Muyltermans L, Delanote J, Bol A. An acute posterior myocardial infarction complicated with late pseudoaneurysm of the posterior wall. *Int J Cardiol*. 2006 Aug 10;111(2):336–7.
96. Di Bella I, Minzioni G, Maselli D, Pasquino S, Viganò M. Septal dissection and rupture evolved as an inferobasal pseudoaneurysm. *Ann Thorac Surg*. 2001 Apr;71(4):1358–60.

97. Di Saverio M, Massacesi C, Rolando M, Iadanza Lanzaro B, Marrangoni A, Gregori G, et al. P130 A RARE CASE OF LARGE POST INFARCTION LEFT VENTRICULAR PSEUDOANEURYSM UNDERGOING CONSERVATIVE MANAGEMENT. *Eur Heart J Suppl.* 2022 May 18;24(Supplement\_C):suac012.126.
98. Diago JL. Left Ventricular Pseudoaneurysm in Cardiac Magnetic Resonance Imaging.
99. Díaz-Navarro R, Nihoyannopoulos P. Post-myocardial infarction left ventricular pseudoaneurysm diagnosed incidentally by echocardiography. *Echo Res Pract.* 2017 Dec;4(4):K37–40.
100. Dichtl W, Müller S, Bonatti J, Pachinger O, Bartel T. Left ventricular pseudoaneurysm. *Wien Klin Wochenschr.* 2006 Apr;118(5–6):151–151.
101. Doğan A. Giant pseudoaneurysm caused by left ventricle free-wall rupture leading left to right shunting: a rare case. *Turk Kardiyol Dernegi Arsivi-Arch Turk Soc Cardiol.* 2013;41(2):177–177.
102. Dokainish H, Tontiplaphol A, Flamm SD. My heart is popping out of my chest: left ventricular pseudoaneurysm with systemic arterial embolism. *BMJ Case Rep.* 2009;2009:bcr2006096404.
103. Douedi S, Alfraji N, Upadhyaya VD, Odak M, Meleka M, Raza MR. Pseudoaneurysm Development after Free Wall Rupture Post Myocardial Infarction. *J Cardiovasc Dev Dis.* 2020 Sep 7;7(3):34.
104. Driessen R, Sardari Nia P, Roekaerts P, Delnoij T. Cardiac rupture with giant left ventricular pseudoaneurysm following inferior wall myocardial infarction: A rare complication. *Acute Card Care.* 2015 Apr 3;17(2):33–33.
105. Dubey L, Timala R, Adhikari R, Sharma S, Gautam M, Gautam S. Unruptured left ventricular pseudoaneurysm following inferior wall myocardial infarction. *Cardiol J.* 2012 Oct 6;19(5):539–42.
106. Dubreuil D, Gosselin G, Hébert Y, Perrault LP. Contained rupture of left ventricular false aneurysm after acute myocardial infarction secondary to left anterior descending artery embolism. *Can J Cardiol.* 2008 Dec;24(12):S94–5.
107. Dutta R, Kahn AM, Rathod A, Greenberg B. Utility of Cardiac Magnetic Resonance Imaging in Evaluating Left Ventricular Pseudoaneurysm. *Congest Heart Fail.* 2008 Mar;14(2):91–4.
108. Duvernoy O, Wikström G, Mannting F, Larsson SG, Andrén B, Dubiel T. Pre- and postoperative CT and MR in pseudoaneurysms of the heart. *J Comput Assist Tomogr.* 1992;16(3):401–9.
109. Elgharably H, Halbreiner MS, Shoenhagen P, Navia JL. Repair of left ventricular pseudoaneurysm with the triple patch technique (Empanada Patch). *Interact Cardiovasc Thorac Surg.* 2016 Jan;22(1):116–7.
110. Elsayed H, Obafemi T, Chew PG, Khand A. Circumferential Calcified Thrombus in a Basal Lateral Wall Pseudoaneurysm. *Heart Lung Circ.* 2015 Jun;24(6):e79–80.
111. Encarnacion-Martinez U, Ruan LAJ, Gopar-Nieto R, Vieyra G. THE RELEVANCE OF MULTIMODALITY CARDIAC IMAGING IN THE DIFFERENTIAL DIAGNOSIS OF LEFT VENTRICULAR ANEURYSM VS PSEUDOANEURYSM AFTER AN ACUTE MYOCARDIAL INFARCTION. *J Am Coll Cardiol.* 2022 Mar;79(9):2984.
112. Eng MH, Garcia JA, Hansgen A, Krantz MJ. Impending Left Ventricular Rupture. *Clin Cardiol.* 2008 Mar;31(3):137–8.
113. Erdim R, Yildirimturk O, Polat B, Aytakin S, Demiroglu C, Aytakin V. Left Ventricular Pseudoaneurysm Complicating Inferior Myocardial Infarction: A Case Report. *Int J Angiol.* 2011 Jun;20(02):107–10.

114. Eren E, Bozbuga N, Toker ME, Keles C, Rabus MB, Yildirim O, et al. Surgical Treatment of Post-Infarction Left Ventricular Pseudoaneurysm. *Tex Heart Inst J*. 2007;34(1):47–51.
115. Espinola-Zavaleta N, Vargas-Barrón J, Romero-Cardenas A, Gonzalez-Sanchez S, Lopez-Soriano F, Rijlaarsdam M, et al. Three Different Coexisting Mechanical Complications of Myocardial Infarction Detected by Transthoracic and Transesophageal Echocardiography. *Echocardiography*. 1997 Jan;14(1):51–5.
116. Essandoh M, Otey AJ, Crestanello J. Severe Mitral Regurgitation After Left Ventricular Pseudoaneurysm Repair. *J Cardiothorac Vasc Anesth*. 2015 Oct;29(5):1295–300.
117. Evangelou D, Letsas KP, Gavrielatos G, Alexanian IP, Pappas LK, Sioras E, et al. Giant Left-Ventricular Pseudoaneurysm following Silent Myocardial Infarction. *Cardiology*. 2006;105(3):137–8.
118. Ezzat MA, Abdelmeguid I, Leclerc D, Nguyen A, Piwnica A. Left ventricular pseudoaneurysm associated with mitral regurgitation. *Ann Thorac Surg*. 1992 Mar;53(3):504–6.
119. Falcão JL de AA, Falcão SNRS, Garcia MFMA, Arruda ALM, Hueb AC, Jatene FB, et al. [Left ventricular pseudoaneurysm associated to severe mitral insufficiency, complicating inferolaterodorsal acute myocardial infarction]. *Arq Bras Cardiol*. 2005 Jun;84(6):488–91.
120. Falcetta G, Pratali S, De Martino A, Celiento M, Bortolotti U. Repair of a giant left ventricular pseudoaneurysm with rupture of the interventricular septum. *Gen Thorac Cardiovasc Surg*. 2019 Sep;67(9):800–2.
121. Faludi R, Tóth L, Komócsi A, Varga-Szemes Á, Papp L, Simor T. Chronic postinfarction pseudoaneurysm diagnosed by cardiac MRI. *J Magn Reson Imaging*. 2007 Dec;26(6):1656–8.
122. Fang L, Xue C, Zhao Y, Wen Z, Henein M. Left ventricular pseudoaneurysm complicating a ruptured isolated congenital diverticulum. *Echocardiography*. 2020 Jun;37(6):926–7.
123. Faustino M, Ranchordás S, Abecasis J, Freitas A, Ferreira M, Gil V, et al. Pseudoaneurisma ventricular esquerdo – um desafio diagnóstico. *Rev Port Cardiol*. 2016 Jun;35(6):373.e1-373.e6.
124. Fearon WF, Stertz S, Lo S. Giant left ventricular pseudoaneurysm. *Clin Cardiol*. 2001 Apr;24(4):345–345.
125. Fehske W, Kranidis A, Kirchhoff PG, Omran H, Lauck G, Lüderitz B. Diagnosis of a posterior left ventricular pseudoaneurysm by multiplane transesophageal echocardiography. *J Clin Ultrasound*. 1995 Jan;23(1):59–62.
126. Fernandes RM, Mota T, Azevedo P, Cunha S, Bento D, Marques N, et al. Giant Left Ventricular (Pseudo?) Aneurysm Complicating Anterior Myocardial Infarction. *JACC Case Rep*. 2021 Feb;3(2):334–8.
127. Fernandez-Valls M. Isolated left ventricular apical hypoplasia: a new congenital anomaly described with cardiac tomography. *Heart*. 2004 May 1;90(5):552–5.
128. Figueras J, Cortadellas J, Domingo E, Soler-Soler J. Survival following self-limited left ventricular free wall rupture during myocardial infarction. Management differences between patients with or without pseudoaneurysm formation. *Int J Cardiol*. 2001;
129. Filizcan U, Cetemen S, Soylu O, Bicer M, Aydogan H, Eren E. Left ventricular giant pseudoaneurysm. *Innov Phila Pa*. 2010;5(4):303–5.
130. Firstenberg MS, Blais D, Crestanello J, Sai-Sudhakar C, Sirak J, Louis LB, et al. Long-term Mechanical Support for Complex Left Ventricular Postinfarct Pseudoaneurysms. *Heart Surg Forum*. 2009 Oct 1;12(5):E291–3.

131. Fisicaro A, Albertini A, Laricchia A, Mangieri A, Giannini F, Colombo A. Post-ischemic Ventricular Septal Pseudoaneurysm Contained Inside Right Ventricular Cavity: A Novel Entity. *Circ Cardiovasc Imaging*. 2020 Nov;13(11):e010561.
132. Fok M, Bashir M, Hammoud I, Harrington D, Kuduvali M, Field M, et al. An apical left ventricular aneurysm rupture presenting as left breast mass 11 years after surgical repair. *Ann R Coll Surg Engl*. 2014 Oct;96(7):e6–7.
133. Frances CD, Shlipak MG, Grady D. Left Ventricular Pseudoaneurysm: Diagnosis by Cine Magnetic Resonance Imaging. *Cardiology*. 1999;92(3):217–9.
134. Freixa X. Left ventricular pseudoaneurysm complicating acute myocardial infarction: improved diagnosis by real time three dimensional echocardiography. *Heart*. 2006 Feb 1;92(2):154–154.
135. Fukunaga N, Rao V. A Huge Postinfarction Left-Ventricular Pseudoaneurysm: A Life-Threatening Complication of an Inferior Infarct. *CJC Open*. 2020 Nov;2(6):748–9.
136. Fuster RG, Estornell J, Hornero F, Montero JA. True Versus False Ventricular Aneurysm: Accurate Diagnosis With Gadolinium Magnetic Resonance. *Ann Thorac Surg*. 2005 Oct;80(4):1528.
137. Gan H li, Zhang J qun. Diagnosis and surgical treatment of post-infarction left ventricular pseudoaneurysm. *Chin Med J (Engl)*. 2009 Jan 20;122(2):232–5.
138. Garcia-Guimaraes M, Velasco-Garcia-de-Sierra C, Estevez-Cid F, Perez-Cebey L, Bouzas-Mosquera A, Mendez-Eirin E, et al. Current role of cardiac imaging to guide surgical correction of a giant left ventricular pseudoaneurysm. *Int J Cardiol*. 2015 Nov;198:152–3.
139. Garg V, Arora D, Mishra M. Left Ventricle Pseudoaneurysm-Recurrence following Surgical Repair.
140. Ghatak A, Farrer M. Pseudoaneurysm of the left ventricle after repairing a ventricular septal defect complicating acute myocardial infarction. *Heart*. 2007 Jul;93(7):782–782.
141. Ghersin E, Kerner A, Gruberg L, Bar-El Y, Abadi S, Engel A. Left ventricular pseudoaneurysm or diverticulum: differential diagnosis and dynamic evaluation by catheter left ventriculography and ECG-gated multidetector CT. *Br J Radiol*. 2007 Sep;80(957):e209–11.
142. Gill S, Rakhit DJ, Ohri SK, Harden SP. Left ventricular true and false aneurysms identified by cardiovascular magnetic resonance. *Br J Radiol*. 2011 Feb;84(998):e35–7.
143. Gollol-Raju N, Olearczyk B, Johnson R, Menzies DJ. Pseudo-pseudoaneurysm: A Rare and Unexplored Mechanical Complication of Myocardial Infarction. *J Am Soc Echocardiogr*. 2007 Nov;20(11):1317.e1–1317.e3.
144. Gomes R, Andrade MJ, Santos M, Lima S, Gouveia RA, Ferreira MM, et al. “Mushroom cloud”: a giant left ventricular pseudoaneurysm after a myocardial infarction due to myocardial bridging – a case report. *Cardiovasc Ultrasound*. 2009 Dec;7(1):36.
145. Gopal A, Pal R, Karlsberg RP, Budoff MJ. Left ventricular pseudoaneurysm by cardiac CT angiography. *J Invasive Cardiol*. 2008 Jul;20(7):370–1.
146. Gopalakrishnan M, Aruni B, Silva-Palacios F, Eryazici P, Stecy P, Danciu S. Unmasking a Giant Ventricular Pseudoaneurysm. *J Am Coll Cardiol*. 2012 Sep;60(11):1026.

147. Goto T, Ono M, Yagi T, Kitaura K. Left Ventricular Pseudo-False Aneurysm Communicating With the Right Ventricle. *Ann Thorac Surg*. 2010 Oct;90(4):e63.
148. Grant EN, Huang N, Joshi GP, Aguirre MA. Dual presentation of a giant left ventricular pseudoaneurysm and true aneurysm. *Proc Bayl Univ Med Cent*. 2012 Jan;25(1):28–30.
149. Guerreiro RA, Congo K, Carvalho J, Pais J, Brás D, Piçarra B, et al. Left ventricular basal inferior pseudoaneurysm and left atrial dissection after myocardial infarction: Case report. *Echocardiography*. 2017 Jun;34(6):939–41.
150. Gultekin N. Left ventricular posterior wall rupture contained by posterolateral pseudo-aneurysm with calcified thrombus. *Turk Kardiyol Dernegi Arsivi-Arch Turk Soc Cardiol [Internet]*. 2016 [cited 2023 Feb 10]; Available from: <https://archivestsc.com/jvi.aspx?un=TKDA-94020>
151. Hamamoto M, Morifuji K. Surgery for left ventricular pseudoaneurysm: thoracotomy or sternotomy. *Asian Cardiovasc Thorac Ann*. 2013 Oct;21(5):602–4.
152. Harrity P, Subramanian R, Patel A, Blanco J. Improved diagnosis and characterization of postinfarction left ventricular pseudoaneurysm by cardiac magnetic resonance imaging. *Clin Cardiol*. 1991 Jul;14(7):603–6.
153. Hassan M, Ricci M, Gologorsky E, Salerno TA. Simultaneous Left Ventricular Pseudo-Aneurysm and Ruptured Ventricular Septal Defect Following an Acute Myocardial Infarction. *J Card Surg*. 2010 Sep;25(5):529–529.
154. Hinton J, Hunter G, Dissanayake M, Hatrick R. Acute respiratory distress secondary to a huge chronic left ventricular pseudo-aneurysm. *Echo Res Pract*. 2019 Dec;6(4):K19–22.
155. Hirt LS. Chronic left ventricular pseudo-aneurysm after posterior myocardial infarction. *Case Rep*. 2012 Jul 19;2012(jul19 1):bcr2012006533–bcr2012006533.
156. Ho HH, Sinaga DA, Lee E, Watson TJ, Hon JKF. Left ventricular pseudoaneurysm. *J Geriatr Cardiol JGC*. 2017 Jan;14(1):78–80.
157. Holtackers RJ, ter Bekke RMA, Bijvoet GP, Gommers S, Chiribiri A, Lorusso R. A Boolean Dilemma. *JACC Case Rep*. 2021 Jan;3(1):112–6.
158. Hui-li G, Jian-qun Z. Diagnosis and surgical treatment of post-infarction left ventricular pseudoaneurysm. *Chin Med J (Engl)*.
159. Hulten EA, Blankstein R. Pseudoaneurysms of the Heart. *Circulation*. 2012 Apr 17;125(15):1920–5.
160. Hung MJ, Cherng WJ, Kuo L i T, Wang CH. Echocardiographic characteristics of patients surviving nonsurgically treated left ventricular pseudoaneurysm after acute myocardial infarction. *Am J Cardiol*. 2003 Feb;91(3):328–31.
161. Ibrahim M, Gumm DC. Left ventricular pseudoaneurysm following undiagnosed myocardial infarction: the curious case of the woman with three ventricles. *BMJ Case Rep*. 2015 Jul 8;bcr2015211597.
162. Inayat F, Ghani AR, Riaz I, Ali NS, Sarwar U, Bonita R, et al. Left Ventricular Pseudoaneurysm: An Overview of Diagnosis and Management. *J Investig Med High Impact Case Rep*. 2018 Jan;6:232470961879202.
163. Inoue T, Hashimoto K, Bando K, Yoshitake M. Left ventricular pseudo-false aneurysm perforating into the right ventricle. *Interact Cardiovasc Thorac Surg*. 2015 Jul;21(1):137–9.



164. Irazusta FJ, Ramirez U, Caro-Codon J, Refoyo E, Garrido D, Pinilla I, et al. Extensive Chest Wall Destruction Secondary to a Large Ventricle Pseudoaneurysm: A Surgical Challenge. *Ann Thorac Surg*. 2017 Mar;103(3):e227–9.
165. Jacob JLB, Buzelli G, Machado NCS, Garzon PGA, Garzon SAC. Pseudoaneurysm of Left Ventricle.
166. Jahangiri M, Sarkar D, Quinton P, Ward DE. Submitral Left Ventricular Pseudoaneurysm. *Ann Thorac Surg*. 2005 Mar;79(3):1031–2.
167. Jallal H, Belabes S, Khatouri A. Uncommon post-infarction pseudoaneurysms: A case report. *World J Cardiol*. 2022 Apr 26;14(4):260–5.
168. Jáuregui B, Sobrino JM, Lage E, López-Haldón JE, Martínez Á. Giant unruptured left ventricular pseudoaneurysm as a rare cause of heart failure after an unnoticed coronary ischaemic event. *Eur Heart J - Cardiovasc Imaging*. 2013 Jul;14(7):720–720.
169. Jebelli M, Kernstine K, Mandegar MH, Chitsaz S, Rayatzadeh H. Left Ventricular Pseudoaneurysm Demonstrated by 64- Multislice Computed Tomography.
170. Jiang C, Zhao R, Yang X. Six-year follow-up of a left ventricular pseudoaneurysm without surgical repair. *Can J Cardiol*. 2007 Jul;23(9):739–41.
171. Jolly N, Faxon DP, Lang RM. Coronary Artery Compression Caused by a Large Pseudoaneurysm Complicating an Acute Myocardial Infarction. *Echocardiography*. 2004 Jan;21(1):85–6.
172. Kadavath S, Ayan M, Al-Hawwas M. Dynamic Systolic Compression of the Left Anterior Descending Coronary Artery as the First Clue of Postinfarction Left Ventricular Pseudoaneurysm. *Can J Cardiol*. 2019 Oct;35(10):1419.e9-1419.e11.
173. Kang YR, Jeong YH, Koh JS, Choi HC, Kim JW, Park SR, et al. Asymptomatic Left Ventricular Pseudoaneurysm Evaluated With Multimodality Cardiac Imaging. *Korean Circ J*. 2011;41(4):224.
174. Kansiz E, Hatemi AC, Tongut A, Cohcen S, Yildiz A, Kilickesmez K, et al. Surgical Treatment of a Giant Postero-Inferior Left Ventricular Pseudoaneurysm Causing Severe Mitral Insufficiency and Congestive Heart Failure. *Ann Thorac Cardiovasc Surg*. 2012;18(2):151–5.
175. Kar B, Gholkar G, Gregoric ID, Jain SK, Loyalka P. Percutaneous Closure of a Left Ventricular Pseudoaneurysm in a High-Risk Surgical Candidate. *Tex Heart Inst J*. 2012;39(5):680–2.
176. Kara İ, Ay Y, Anasız H, Yıldırım T, Arsan S. Kronik sol ventrikül psödoanevrizmasının başarılı cerrahi tedavisi.
177. Karaca O, Gunes HM, Cakal B, Turkoglu H. Giant left ventricular pseudoaneurysm concomitant with severe mitral regurgitation: multimodality imaging and successful surgical repair. *Eur J Cardiothorac Surg*. 2015 Apr 1;47(4):e162–3.
178. Karaji I, Bleie Ø, Skromme K, Davidsen C. Coexisting left ventricular aneurysm and pseudoaneurysm after inferior wall myocardial infarction. *Eur Heart J - Cardiovasc Imaging*. 2020 Oct 1;21(10):1089–1089.
179. Karamitsos TD, Ferreira V, Banerjee R, Moore NR, Forfar C, Neubauer S. Contained Left Ventricular Rupture After Acute Myocardial Infarction Revealed by Cardiovascular Magnetic Resonance Imaging. *Circulation*. 2012 May 8;125(18):2278–80.



180. Kaur N, Panda P, Choudhary AK, Sharma YP. Left ventricular pseudoaneurysm: imaging. *BMJ Case Rep*. 2021 Jun;14(6):e243913.
181. Kawasuji M, Sawa S, Tsubota M, Arano Y, Iwa T. Diagnosis and treatment of left ventricular false aneurysm. *Jpn Circ J*. 1991 Dec;55(12):1224–7.
182. Kerkhoff GO, Höfs C, Roer N, Albes G, Lehner A, Koslowski B, et al. Left Ventricular Pseudoaneurysm: Clinical Role of Cardiovascular Magnetic Resonance Imaging. *Circulation [Internet]*. 2004 May 25 [cited 2023 Feb 10];109(20). Available from: <https://www.ahajournals.org/doi/10.1161/01.CIR.0000130756.52908.B2>
183. Keskin M. A giant left ventricular pseudoaneurysm presenting with transient ischemic attack 7 years after acute myocardial infarction: A deep investigation via multiple imaging modalities. *Anatol J Cardiol [Internet]*. 2016 [cited 2023 Feb 10]; Available from: <https://anatoljcardiol.com/jvi.aspx?un=AJC-58295>
184. Kim MN, Park SM, Kim SW, Lee KN, Kim JS, Kang EJ, et al. Progression of Left Ventricular Pseudoaneurysm after an Acute Myocardial Infarction. *J Cardiovasc Ultrasound*. 2010;18(4):161.
185. Kocabaş U, Özyurtlu F. Giant left ventricular pseudoaneurysm presenting with ventricular tachycardia. *Turk J Emerg Med*. 2018 Jun;18(2):88–9.
186. Koito H, Nakamura C, Suzuki J, Kamihata H, Takayama Y, Iwasaka T, et al. Pseudoaneurysm of the Left Ventricle Progressing From a Subepicardial Aneurysm. *Jpn Circ J*. 1999;63(7):559–63.
187. Koizumi K, Misumi T, Kudo M, Matsubara T. Giant left ventricular pseudo-false aneurysm following myocardial infarction. *Jpn J Thorac Cardiovasc Surg*. 2005 Feb;53(2):120–3.
188. Kojury J, Shahrzad S, Taban S, Shafa M, Hashemi A, Hashemi A. Left Ventricular Pseudo-Aneurysm: Do Not Make the Same Mistake.
189. Koklu E, Arslan S, Yuksel IO, Bayar N, Yilmaz GM, Kucukseymen S. Management of Left Ventricular Free Wall Rupture Associated with Acute Myocardial Infarction.
190. Kollar A, Byrd BF, Lui HK, Drinkwater DC. Mitral valve replacement and endocavitary patch repair for a giant left ventricular pseudoaneurysm. *Ann Thorac Surg*. 2001 Jun;71(6):2020–2.
191. Komeda M, David TE. Surgical treatment of postinfarction false aneurysm of the left ventricle. *J Thorac Cardiovasc Surg*. 1993 Dec;106(6):1189–91.
192. Konen E, Merchant N, Gutierrez C, Provost Y, Mickleborough L, Paul NS, et al. True versus False Left Ventricular Aneurysm: Differentiation with MR Imaging—Initial Experience. *Radiology*. 2005 Jul;236(1):65–75.
193. Konishi T, Funayama N, Tsukahara T, Yamamoto T, Nishihara H. Multimodality assessment of spontaneous haemostasis of left ventricular free wall rupture after myocardial infarction. *Eur Heart J – Cardiovasc Imaging*. 2016 Apr;17(4):467–467.
194. Korkmaz K, Lafci G, Gedik HS, Budak AB, Yener AU, Ecevit AN, et al. Surgical treatment of post-infarct left ventricular pseudo-aneurysm with on-pump beating heart technique : online article - case report. *Cardiovasc J Afr*. 2014 Nov 4;25(5):e1–4.
195. Koutsampasopoulos K, Grigoriadis S, Vogiatzis I. Exertional dyspnea after myocardial infarction: thinking beyond the diagnosis of heart failure. *J Int Med Res*. 2018 Nov;46(11):4769–74.

196. Koçak H, Becit N, Ceviz M, İnçel Y. Left ventricular pseudoaneurysm after myocardial infarction. *Heart Vessels*. 2003 Jul 1;18(3):160–2.
197. Krasner H, Tighe D. A complex echocardiographic diagnosis. *J Cardiothorac Vasc Anesth*. 1999 Oct;13(5):635–7.
198. Kronzon I, Ruiz CE, Perk G. Guidance of Post Myocardial Infarction Ventricular Septal Defect and Pseudoaneurysm Closure. *Curr Cardiol Rep*. 2014 Mar;16(3):456.
199. Krysztofiak H, Migaj J, Buczkowski P, Stefaniak S, Straburzyńska-Migaj E, Kałużna-Oleksy M. Ventricular pseudoaneurysm rupture – a potentially fatal complication of myocardial infarction. *Adv Interv Cardiol*. 2020;16(4):512–3.
200. Kumar S, Kapoor A, Moorthy N, Sinha N. Post Myocardial Infarction Left Ventricular Giant Pseudoaneurysm. *Heart Views*. 2011;12(3):118.
201. Kusadokoro S, Hori D, Fujii K, Yamaguchi A. Left thoracotomy approach for left ventricular pseudoaneurysm due to myocardial infarction after mitral valve replacement for papillary muscle rupture. *J Card Surg*. 2020 Aug;35(8):2103–5.
202. Lafci B, Özsöyler I, Emreçan B, Göktogan T, Bozok S, Yasa H, et al. Surgical Treatment of Postinfarction Left Ventricular Pseudoaneurysms. *Heart Surg Forum*. 2006 Dec 1;9(6):E876–9.
203. Lakkireddy DR, Khan IA, Nair CK, Korlakunta HL, Sugimoto JT. Pseudo-pseudoaneurysm of the Left Ventricle: A Rare Complication of Acute Myocardial Infarction A Case Report and Literature Review. 2005;56(1).
204. Landi A, Andres AL, Napodano M. Late recurrence of a giant left ventricular pseudoaneurysm: the importance of multimodality imaging approach. *Monaldi Arch Chest Dis [Internet]*. 2020 Mar 12 [cited 2023 Feb 10];90(1). Available from: <https://www.monaldi-archives.org/index.php/macd/article/view/1232>
205. Lasorda DM, Dianzumba SB, Casaday FM, Joyner CR. Diagnosis of recurrent left ventricular pseudoaneurysm by echocardiography with color flow imaging. *Clin Cardiol*. 1991 May;14(5):431–4.
206. Lee JH, Song JH, Kim H, Yeol Lee D, Oh J, Sin YH, et al. Unstable pseudoaneurysm treatment with stent graft. *J Vasc Access*. 2019 Mar;20(2):224–5.
207. Lee SY, Farid A, Dharawat R, Jung SM, Aman E, Amsterdam E, et al. Culprit of Unstable Angina: A Large Left Ventricular Outflow Tract Pseudoaneurysm. *Circ Cardiovasc Imaging*. 2021 Mar;14(3):e011238.
208. Lee WC, Fu M. Subacute giant left ventricular pseudoaneurysm mimicking pneumonia. *J Echocardiogr*. 2015 Jun;13(2):72–3.
209. Lee YH, Hou CJY, Hung CL, Tsai CH. Silent and Huge Left Ventricular Pseudoaneurysm with Left Atrial Compression: Dedicated Spatial Resolution and Geometry by 3-Dimensional Echocardiography. *J Am Soc Echocardiogr*. 2007 Jun;20(6):772.e5-772.e9.
210. Leitman M, Shmueli R, Stamler A, Krakover R, Hendler A, Vered Z. An Unusual Presentation of a Large Left Ventricular Pseudoaneurysm. *Echocardiography*. 2006 May;23(5):403–4.
211. Leontiadis E, Bairaktaris A, Korfer R. Left Ventricular Pseudoaneurysm Following Surgical Revascularization. *Clin Cardiol*. 2009 Jun;32(6):E103–E103.

212. Li X, Wang Y, Wang D, Lai C, Wang C. The evolution of left ventricular pseudoaneurysm from the rupture of left ventricular free wall following acute myocardial infarction: a case report. *BMC Cardiovasc Disord*. 2020 Dec;20(1):5.
213. Liao CY, Ho SY, Hsia CH, Yang WY, Yang AD, Lee KW. Left Ventricular Pseudoaneurysm Following Myocardial Infarction Demonstrated By 64 Multidetector Computed Tomography.
214. Lipiec P, Chrzanowski L, Kasprzak JD. Post-myocardial infarction biventricular pseudoaneurysm with bidirectional shunt. *Heart*. 2010 Mar 1;96(6):483–4.
215. Liu H, Xie J, Zhang X. A giant left ventricular pseudo-pseudoaneurysm following myocardial infarction. *Gen Thorac Cardiovasc Surg*. 2022 May;70(5):495–7.
216. Loperfido F, Mazzari M, Vigna C, Manzoli U, Rome MD. Diagnosis of left ventricular pseudoaneurysm by pulsed Doppler echocardiography.
217. Ludmir J, Kapoor K, George P, Khural J, Barr B. Left Ventricular Pseudoaneurysm Following Inferior Myocardial Infarction: A Case for Conservative Management. *Cardiol Res*. 2016;7(1):32–5.
218. MacDonald ST, Mitchell ARJ, Timperley J, Forfar JC. Left Ventricular Pseudoaneurysm and Rupture After Limited Myocardial Infarction. *J Am Soc Echocardiogr*. 2005 Sep;18(9):980.e1-980.e4.
219. Mackenzie JW, Lemole GM. Pseudoaneurysm of the left ventricle. *Tex Heart Inst J*. 1994;21(4):296–301.
220. Madan T, Juneja M, Raval A, Thakkar B. Transcatheter device closure of pseudoaneurysms of the left ventricular wall: An emerging therapeutic option. *Rev Port Cardiol*. 2016 Feb;35(2):115.e1-115.e5.
221. Maeba H, Miyasaka Y, Kotaka A, Tsujimoto S, Yuasa F, Iwasaka T. Pseudoaneurysm with left-to-right shunt in a patient with myocardial infarction: evaluation by three-dimensional echocardiography. *J Med Ultrason*. 2012 Jul;39(3):169–72.
222. Maffe' S, Zenone F, Paffoni P, Pardo NF, Dellavesa P, Perucca A, et al. Left ventricular pseudoaneurysm: an atypical case associated with a small ventricular septal defect: *J Cardiovasc Med*. 2008 Feb;9(2):195–200.
223. Mahesh B, Ong P, Kutty R, Abu-Omar Y. Tamponade by an expanding left ventricular pseudoaneurysm: A unique presentation. *Asian Cardiovasc Thorac Ann*. 2015 Oct;23(8):976–8.
224. Mahilmaran A, Nayar PG, Abraham KA. Left Ventricular Pseudoaneurysm.
225. Mallat J. Positive end-expiratory pressure-induced increase in central venous pressure to predict fluid responsiveness: don't forget the peripheral venous circulation! *Br J Anaesth*. 2016 Sep;117(3):397–9.
226. Mallidi HR, Latter DA. Ventricular pseudoaneurysm associated with severe mitral regurgitation. *Nat Clin Pract Cardiovasc Med*. 2006 May;3(5):283–7.
227. Mangia M, Madeo A, Conti B, Galea N. Giant left ventricular pseudoaneurysm following coronary artery bypass graft surgery. *Eur J Cardiothorac Surg*. 2012 Mar 1;41(3):e21–e21.
228. Mani A, Harikrishnan S, Valaparambil AK. A curious case of stent fracture and left ventricular pseudoaneurysm – A rare association in the background of cardiac tuberculosis. *Trop Doct*. 2021 Oct;51(4):594–5.

229. Mao CT, Li MF, Kao YC, Cherng WJ, Hung MJ. Long-term Survival of A Patient with Asymptomatic Left Ventricular Pseudoaneurysm after Acute Myocardial Infarction.
230. Marchandot B, Crimizade U, El Ghannudi S, Morel O. Giant ventricular pseudoaneurysm following inferior myocardial infarction: insights from multimodal imaging approach. *Eur Heart J - Case Rep* [Internet]. 2018 Mar 1 [cited 2023 Feb 10];2(1). Available from: <https://academic.oup.com/ehjcr/article/doi/10.1093/ehjcr/ty019/4922886>
231. Marnelos PG, Georghiou GP, Mitselos LE, Michaelides TY, Christou CP, Soteriou MC. Sixty-Four Slice Computed Tomography as an Alternative Modality for the Non-Invasive Diagnosis of Left Ventricular Pseudoaneurysm.
232. Marques JS, Jorge C, Martins SR, Feijão A, Diogo AN. Acute myocardial infarction complication diagnosed by three-dimensional echocardiography. *Eur Heart J - Cardiovasc Imaging*. 2011 Apr;12(4):E29–E29.
233. Martin R, Tegtmeier T, Smith AS, Ognibene A, Ognibene A. Left Ventricular Pseudoaneurysm Presenting Twenty-eight Months After Myocardial Infarction: A Case Report. *Angiology*. 1997 Feb;48(2):177–81.
234. May BV, Reeves ST. Contained Rupture of a Left Ventricular Pseudoaneurysm. *Anesth Analg*. 2007 Jul;105(1):38–9.
235. Melman YF, Levy MS, Laham RJ. Intracardiac echocardiography and fluoroscopy guided percutaneous left ventricular pseudoaneurysm closure: Percutaneous LV Pseudoaneurysm Closure. *Catheter Cardiovasc Interv*. 2013 Dec 1;82(7):E915–8.
236. Meng X, Yang YK, Yang KQ, Zhang Y, Lu PP, Fan P, et al. Clinical characteristics and outcomes of left ventricular pseudoaneurysm: A retrospective study in a single-center of China. *Medicine (Baltimore)*. 2017 May;96(18):e6793.
237. Milojevic P, Neskovic V, Vukovic M, Nezic D, Djukanovic B. Surgical repair of a leaking double postinfarction left ventricular pseudoaneurysm. *J Thorac Cardiovasc Surg*. 2004 Nov;128(5):765–7.
238. Miltner B, Dulgheru R, Nchimi A, Pierard LA, Davin L. Left ventricular aneurysm: true, false or both? *Acta Cardiol*. 2016 Oct;71(5):616–7.
239. Miranda G, Gonçalves MI, Perestrelo P, Rodrigues AS, Rodrigues B, Ballesteros R. Left ventricular pseudoaneurysm as a complication of myocardial infarction. *Med Clínica Práctica*. 2021 Oct;4(4):100245.
240. Mittal S. Left Ventricular Pseudoaneurysm.
241. Mittle S, Makaryus AN, Mangion J. Role of Contrast Echocardiography in the Assessment of Myocardial Rupture. *Echocardiography*. 2003 Jan;20(1):77–81.
242. Miyagawa A, Okamura H, Kitada Y, Arakawa M, Adachi H. Double-patch and glue repair of a postinfarction left ventricular pseudoaneurysm. *Asian Cardiovasc Thorac Ann*. 2021 Feb;29(2):116–8.
243. Mohamed A. Left ventricular apex rupture in STEMI. *Clin Case Rep* [Internet]. 2021 Jul [cited 2023 Feb 10];9(7). Available from: <https://onlinelibrary.wiley.com/doi/10.1002/ccr3.4332>
244. Moreno R. Usefulness of Contrast Agents in the Diagnosis of Left Ventricular Pseudoaneurysm after Acute Myocardial Infarction. *Eur J Echocardiogr*. 2002 Jun;3(2):111–6.

245. Moriarty J, Harris TJ, Vorobiof G, Kwon M, Aboulhosn J. Direct Percutaneous Repair of Left Ventricular Pseudoaneurysm via Transthoracic Deployment of a Ventricular Septal Defect Closure Device. *Tex Heart Inst J*. 2015 Aug 1;42(4):362–6.
246. Moss AJ, Lim KH, Japp AG. A 49-year-old with chest pain and collapse. *Heart*. 2017 Jun;103(12):968–968.
247. Mourabiti AY, Alami BE, Bouanani Z, Sqalli Houssaini M, El Bouardi N, Haloua M, et al. A case of a giant left ventricular pseudoaneurysm. *Radiol Case Rep*. 2021 Oct;16(10):2920–3.
248. Mousavi N, Buksak R, Walker JR, Hussain F, Pascoe E, Kirkpatrick IDC, et al. Left ventricular pseudoaneurysm: The role of multimodality cardiac imaging. *Can J Cardiol*. 2009 Nov;25(11):e389.
249. Mujanovic E, Bergsland J, Avdic S, StanimirovicMujanovic S, KovacevicPreradovic T, Kabil E. Surgical Treatment of Left Ventricular Pseudoaneurysm. *Med Arch*. 2014;68(3):215.
250. Mukherjee D, Datta G, Majhi B, Agrawal BK, Singh R. Ventricular Pseudo-aneurysm with Coronary Ectasias. 2011;59.
251. Müller U, Nitzsche S, Eitel I, Gutberlet M, Schuler G, Thiele H. Covered rupture of the free left ventricular wall or “only” thrombus in a true aneurysm? *Clin Res Cardiol*. 2008 Nov;97(11):843–5.
252. Mullins CE. Vessel restenosis versus “streamlining.” *Heart*. 2002 Dec 1;88(5):445–6.
253. Nakashima R, Yamaguchi K, Yoshitomi H, Okada T, Endo A, Tanabe K. A case of myocardial infarction and left ventricular pseudo-false aneurysm perforating the right ventricle. *J Echocardiogr*. 2017 Jun;15(2):91–2.
254. Narayan RL, Vaishnav P, Goldman ME, Stelzer P, Clark L, Kini AS, et al. Percutaneous Closure of Left Ventricular Pseudoaneurysm. *Ann Thorac Surg*. 2012 Nov;94(5):e123–5.
255. Narin C, Ege E, Ozkara A, Tanyeli O, Sarkilar G, Soylu A, et al. Surgical Treatment of Postinfarction Pseudoaneurysms of the Left Ventricle. *J Card Surg*. 2008 Jul;23(4):294–8.
256. Narvaez Muñoz AF, Gonzalez Cambeiro C, Duran Muñoz D, Rosario Ortiz A. Giant left ventricular pseudoaneurysm manifested with a persistent cough. *J Card Surg*. 2017 May;32(5):285–7.
257. Naseerullah FS, Baig M, Wool KJ, Murthy A. Left ventricle pseudoaneurysm: Diagnosis by a new murmur. *J Cardiol Cases*. 2018 Jul;18(1):20–4.
258. Negi P, Bhardwaj R, Asotra S, Mahajan K. Inferior wall STEMI presenting with a ruptured intraseptal pseudoaneurysm.
259. Nekkanti R, Nanda NC, Ansingkar KG, McGiffin DC. Transesophageal Three-Dimensional Echocardiographic Assessment of Left Ventricular Pseudoaneurysm. *Echocardiography*. 2002 Feb;19(2):169–72.
260. Neven KGEJ, Crijns HJGM, Cheriex EC. Late left ventricular pseudoaneurysm formation following subacute myocardial infarction. *Int J Cardiol*. 2005 Jan;98(1):165–7.
261. Niemann M, Hermann M, Jacobs S, Gotschy A, Gordic S, Tanner FC, et al. The third ventricle — A case of a giant post infarct pseudoaneurysm. *Int J Cardiol*. 2014 Dec;177(3):e93–6.
262. Niimura H, Mito T, Matsunaga A, Koga S, Akasu K, Morishige N, et al. Left Ventricular Pseudoaneurysm Following Acute Myocardial Infarction. *Intern Med*. 2006;45(21):1221–3.

263. Nishimura Y, Okamura Y, Noguchi Y, Yamamoto S, Hatada A, Hisaoka T. Successful Repair of a Large Pseudoaneurysm of the Left Ventricle Late after Mitral Valve Replacement Due to Rupture of the Papillary Muscle Following Acute Myocardial Infarction. 2004;10(6).
264. Noorani A, Burt C, Nashef SAM. Post-infarction biventricular free wall rupture with extracardiac shunt presenting as ventricular septal rupture. *Interact Cardiovasc Thorac Surg*. 2013 Aug;17(2):419–20.
265. Novo G, Midiri M, Fazio G, Alaimo V, Evola S, Rotolo A, et al. Unusual Case of Left Ventricular Pseudoaneurysm. *Circ J*. 2009;73(5):974–5.
266. Nurozler F, Kutlu T, Küçük G. False aneurysm of the left ventricle following myocardial infarction : an unusual location. 2007;18(6).
267. O'Flynn E, Purkayastha S, Athanasiou T, Casula R. Repair of a Giant Left Ventricular Pseudoaneurysm in a Jehovah's Witness. *Asian Cardiovasc Thorac Ann*. 2006 Aug;14(4):328–30.
268. O'Sullivan CJ, Groza D, Eberli FR. Left ventricular pseudoaneurysm formation in a patient presenting with a subacute myocardial infarction. *BMJ Case Rep*. 2017 Dec 14;bcr-2017-222481.
269. Ohtani H, Katoh H, Saitoh T, Shiraki K, Saotome M, Urushida T, et al. Left Ventricular Pseudo-False Aneurysm Detected With ECG-Gated Multidetector Computed Tomography and Cardiac Magnetic Resonance Imaging. *Circ J*. 2010;74(9):1986–8.
270. Okada M, Watanuki H, Sugiyama K, Futamura Y, Matsuyama K. Unusual rupture of left ventricular pseudo-false aneurysm secondary to subacute anterolateral myocardial infarction: a case report. *J Cardiothorac Surg*. 2019 Dec;14(1):93.
271. Oliveira SM, Dias P, Pinho T, Gavina C, Almeida PB, Madureira AJ, et al. Giant left ventricular pseudoaneurysm: The diagnostic contribution of different non-invasive imaging modalities. *Rev Port Cardiol Engl Ed*. 2012 Jun;31(6):439–44.
272. Oncel CR, Ucar M, Basarici I. Left ventricular lateral wall pseudoaneurysm presented with decompensated heart failure. *Case Rep*. 2014 Oct 8;2014(oct08 2):bcr2014206389–bcr2014206389.
273. Orsborne C, Schmitt M. Left ventricular pseudoaneurysm after myocardial infarction detected by cardiac MRI. *Case Rep*. 2014 Nov 25;2014(nov25 2):bcr2014207277–bcr2014207277.
274. Otahbachi M, Cevik C, Meyerrose G, Malki Q. Left ventricular free wall rupture and large pseudoaneurysm after percutaneous coronary intervention. *Cardiovasc Revasc Med*. 2009 Apr;10(2):140–1.
275. Ousaka D, Obara N, Fujiwara M, Nakagawa K, Teraoka A, Kasahara S, et al. A case of conservative management for left ventricular giant pseudoaneurysm without ST segment changes. *J Cardiol Cases*. 2018 May;17(5):167–70.
276. Oxorn D. Coexistent true and false left ventricular aneurysms. *Eur J Cardiothorac Surg*. 2000 Aug 1;18(2):251.
277. Ozeke O, Golbasi Z, Cagli K, Tufekcioglu O. Left Ventricular Pseudoaneurysm Developing as a Late Complication of Coronary Artery Bypass Grafting with Apicoseptal Plication: LEFT VENTRICULAR PSEUDOANEURYSM. *Echocardiography*. 2005 Sep 2;22(8):679–81.
278. Ozer N, Aksoy H, Hazırolan T, Tulumen E, Devenci OS, Okutucu S, et al. An Unusual Case of a Giant Pseudoaneurysm Formation after Myocardial Infarction: Unusual Case of a Giant Pseudoaneurysm Formation. *Echocardiography*. 2010 May 10;27(8):E83–6.

279. Ozerkan F, Gurgun C, Zoghi M. Images in Cardiovascular Medicine.
280. Panos A, Kalangos A. Dyspnea and late left ventricular pseudoaneurysm formation.
281. Parikh RV, Ahmadi-Kashani M, Fleischmann D, Woo YJ, McConnell MV. A Crack in the Wall: Evolution of a Left Ventricular Apical Pseudoaneurysm. *Can J Cardiol*. 2016 Jun;32(6):830.e7-830.e8.
282. Park WK, Kim DH, Cho SH. Large Chronic Pseudoaneurysm of Left Ventricle Complicating Anterior Myocardial Infarction. *Korean Circ J*. 2018;48(8):760.
283. Pasala S, Pak K, Genovese L, Emaminia A. Left ventricular pseudoaneurysm in a young adult after non-ST elevation myocardial infarction. *BMJ Case Rep*. 2022 Mar;15(3):e244880.
284. Patel P, Siegenthaler M, Bandettini WP, Arai AE, Fujikura K. Left Ventricular Pseudoaneurysm in a Patient With an Apical Aneurysm. *JACC Case Rep*. 2021 Jan;3(1):91–3.
285. Patra S, Dhadake SM, Agrawal N, Cn M. Giant left ventricular pseudoaneurysm following acute inferior wall myocardial infarction presenting with acute left ventricular failure: a rare complication. *Case Rep*. 2013 Aug 2;2013(aug02 1):bcr2013200270–bcr2013200270.
286. Patted DrS, Halkati DrP, Modi DrR. Lv Pseudoaneurysm- An Unprecedented Condition. *IOSR J Dent Med Sci IOSR-JDMS*. 2015 Sep;
287. Paul JF, Macé L, Caussin C, Fsihi A, Berthaux X, Brenot P, et al. Multirow Detector Computed Tomography Assessment of Intraseptal Dissection and Ventricular Pseudoaneurysm in Postinfarction Ventricular Septal Defect. *Circulation*. 2001 Jul 24;104(4):497–8.
288. Pavani M, Scrocca I, Meliga E, De Benedictis M. Percutaneous Closure of a Left Ventricular Pseudoaneurysm Causing Recurrent Embolization, With Cerebral Protection and Extracorporeal Membrane Oxygenation Support. *JACC Cardiovasc Interv*. 2018 Jan;11(2):e7–10.
289. Perek B, Jemielity M, Dyszkiewicz W. Clinical Profile and Outcome of Patients with Chronic Postinfarction Left Ventricular False Aneurysm Treated Surgically. *Heart Surg Forum*. 2004 Apr 1;7(2):106–9.
290. Perrotta S, Lepore V, Flinck A, Berglin E, Rådberg G. Left thoracotomy for recurrent left ventricular pseudoaneurysm: *J Cardiovasc Med*. 2013 Jun;14(6):474–6.
291. Petrou E. Left ventricular pseudoaneurysm formation: Two cases and review of the literature. *World J Clin Cases*. 2014;2(10):581.
292. Pilato E, Pinna GB, Parisi V, Manzo R, Comentale G. Mechanical complications of myocardial infarction during COVID-19 pandemic: An Italian single-centre experience. *Heart Lung*. 2020 Nov;49(6):779–82.
293. Pineda-De Paz DO, Hernández-del Rio JE, González-Padilla C, Esturau-Santaló RM, Romero-Palafox J, Grover-Paez F, et al. Left ventricular free-wall rupture, a potentially lethal mechanical complication of acute myocardial infarction: an unusual and illustrative case report. *BMC Cardiovasc Disord*. 2019 Dec;19(1):80.
294. Pizzuto A, Santoro G, Baldi C, Celi S, Cuman M, Anees AJ, et al. 3D model-guided transcatheter closure of left ventricular pseudoaneurysm: a case series. *J Cardiovasc Med [Internet]*. 2020 Sep 15 [cited 2023 Feb 10];Publish Ahead of Print. Available from: <https://journals.lww.com/10.2459/JCM.0000000000001114>



295. Pontone G, Andreini D, Ballerini G, Pompilio G, Alamanni F, Nobili E, et al. An unusual case of large left ventricular aneurysm: Complementary role of echocardiography and multidetector computed tomography in surgical planning. *Eur J Radiol Extra*. 2005 May;54(2):51–4.
296. Prêtre R, Linka A, Jenni R, Turina MI. Surgical treatment of acquired left ventricular pseudoaneurysms. *Ann Thorac Surg*. 2000 Aug;70(2):553–7.
297. Prifti E, Bonacchi M, Baboci A, Giunti G, Veshti A, Demiraj A, et al. Surgical treatment of post-infarction left ventricular pseudoaneurysm: Case series highlighting various surgical strategies. *Ann Med Surg*. 2017 Apr;16:44–51.
298. Purcaro A, Costantini C, Ciampani N, Mazzanti M, Silenzi C, Gili A, et al. Diagnostic Criteria and Management of Subacute Ventricular Free Wall Rupture Complicating Acute Myocardial Infarction. *Am J Cardiol*. 1997 Aug;80(4):397–405.
299. Qian H, Li Y, Qin Y, Huang H. An unusual left ventricle pseudo-aneurysm with progressive mitral regurgitation. *Eur Heart J*. 2021 Feb 21;42(8):873–873.
300. Radhakrishnan BK, Kumar CJA, Philipose S, Karunakaran J. A large left ventricular pseudoaneurysm. *Eur J Cardiothorac Surg*. 2016 Apr;49(4):1291–2.
301. Rahman A, Gupta R, Birnbaum Y. Magnetic resonance imaging of left ventricular lateral wall pseudoaneurysm. *Clin Cardiol*. 2005 Nov;28(11):545–545.
302. Rao A, Garimella S, Nanda NC, Chung SM. Transesophageal Color Doppler Echocardiographic Diagnosis of Cardiac Rupture Following Acute Myocardial Infarction. *Echocardiography*. 1996 May;13(3):309–12.
303. Rao MS, Vaijyanath P, Taneja K, Dubey B, Manchanda SC, Venugopal P. Recurrent pseudoaneurysm of the left ventricle with subcutaneous herniation into the chest wall. A case report. *Tex Heart Inst J*. 1998;25(4):309–11.
304. Rasouly N, Stanekzai R, Hamidi H, Ahamdzai R. Computed Tomography Features of Left Ventricular Pseudoaneurysm: A Case Report. *Iran J Radiol* [Internet]. 2016 Dec 28 [cited 2023 Feb 10];In press(In press). Available from: <https://brieflands.com/articles/iranjradiol-56268.html>
305. Reinecke H, Wichter T, Weyand M. Left ventricular pseudoaneurysm in a patient with Dressler’s syndrome after myocardial infarction. *Heart*. 1998 Jul 1;80(1):98–100.
306. Rentoukas EI, Lazaros GA, Kaoukis AP, Matsakas EP. Double rupture of interventricular septum and free wall of the left ventricle, as a mechanical complication of acute myocardial infarction: a case report. *J Med Case Reports*. 2008 Dec;2(1):85.
307. Reyaldean R, Jeffries C, Hardman D, Challa P, Dahiya A. Multimodality Imaging in a Case of Chronic Massive Left Ventricular Pseudoaneurysm. *CASE*. 2018 Jun;2(3):95–8.
308. Riesenhuber M, Schneider M, Maier A, Rohla M, Gyöngyösi M. Chronic rupture of the left ventricular wall with a giant pseudoaneurysm. *Eur Heart J - Cardiovasc Imaging*. 2019 Feb 1;20(2):242–242.
309. Rimac G, Marzouk M, Dumont É, Paradis JM. When a delayed cardiology consultation leads to a massive left ventricle pseudoaneurysm: collateral effects of the COVID-19 pandemic. *Eur Heart J*. 2020 Aug 21;41(32):3102–3102.



310. Robles P, Jiménez JJ, Monedero I. Left ventricular pseudoaneurysm with a fistula to right ventricle. *Eur Heart J*. 2006 Aug 1;27(16):1946–1946.
311. Roosens B, Argacha JF, Soens L, Ilsen B, Cosyns B. Left ventricular pseudo-aneurysm as a source of recurrent septicaemia. *Eur Heart J – Cardiovasc Imaging*. 2017 Jan;18(1):94–94.
312. Sadeghpour A, Pourafkari L, Khesali H, Nader ND. Chronic large pseudoaneurysm of the left ventricle. *Intern Emerg Med*. 2020 Jan;15(1):145–6.
313. Saito T, Solowjowa N, Hetzer R, Knosalla C. Giant pseudoaneurysm on left ventricular posterolateral wall with an orifice between papillary muscles. *Interact Cardiovasc Thorac Surg*. 2014 Nov;19(5):869–71.
314. Sakakibara K, Matsumoto M, Kaga S, Suzuki S. Giant Left Ventricular Pseudoaneurysm after Myocardial Infarction. *Intern Med*. 2012;51(4):445–6.
315. Sansone F, Ceresa F, Patane F. Left Ventricular Pseudoaneurysm After Left Ventricular Remodeling.
316. Sato M, Endo M, Tomizawa Y, Nishida H. Left ventricular true aneurysm with pseudo-aneurysm detected five years and nine months following repair for oozing type free wall rupture. *Jpn J Thorac Cardiovasc Surg*. 2005 Mar;53(3):147–9.
317. Schalla S, Bar F, Mochtar B, Snoep G. Left ventricular pseudoaneurysm.
318. Schillaci G, Gemelli F, Marchesi S, Mannarino E. Left Ventricular Pseudoaneurysm Complicating an Asymptomatic Myocardial Infarction. *Echocardiography*. 2004 Oct;21(7):663–4.
319. Schreurs M, Herregods MC, Bogaert J, Troost E, Budts W. Pseudoaneurysm of the left ventricle with moderate left-to-right shunt. *Int J Cardiol*. 2008 Oct;130(1):11–3.
320. Seabra D, Moreno N, Pissarra D, Amorim M. Recurrent left ventricular pseudoaneurysm with an ominous presentation. *Interact Cardiovasc Thorac Surg*. 2020 Sep 1;31(3):405–7.
321. Seabra D, Neto A, Oliveira I, Santos RP dos, Azevedo J, Pinto P. Dor Abdominal: uma Apresentação Incomum de Ruptura Miocárdica: Ruptura do miocárdio incomum. *Arq Bras Cardiol [Internet]*. 2020 Feb [cited 2023 Feb 10]; Available from: [https://www.scielo.br/scielo.php?script=sci\\_arttext&pid=S0066-782X2020000200319](https://www.scielo.br/scielo.php?script=sci_arttext&pid=S0066-782X2020000200319)
322. Serra Valério R, Sayuri Oshiro F, DASA, São Paulo, SP, Brazil, Eyer Rodrigues AA, DASA, São Paulo, SP, Brazil, Federal University of São Paulo, São Paulo, SP, Brazil, et al. Left Ventricular Free-Wall Rupture (Pseudoaneurysm) after Acute Myocardial Infarction in an Asymptomatic Patient. *ABC Imagem Cardiovasc [Internet]*. 2021 Mar 1 [cited 2023 Feb 10];34(1). Available from: <https://www.abcimaging.org/article/left-ventricular-free-wall-rupture-pseudoaneurysm-after-acute-myocardial-infarction-in-an-asymptomatic-patient/>
323. Shijo T, Toda K, Taniguchi K. Repair of Huge Left Ventricular Pseudoaneurysm after Sutureless Repair. *Thorac Cardiovasc Surg*. 2010 Apr;58(03):177–9.
324. Shimono H, Kajiya T, Atsuchi Y, Atsuchi N, Ohishi M. Giant left ventricular pseudo-aneurysm after posterior myocardial infarction. *Eur Heart J*. 2018 Oct 1;39(37):3479–3479.
325. Shimono H, Kajiya T, Inoue H, Ueno M, Takaoka J, Atsuchi Y, et al. Left Ventricular Pseudo-aneurysm with Ventricular Septal Rupture Due to Anterior ST-segment Elevation Myocardial Infarction. *Intern Med*. 2019 Jul 1;58(13):1901–5.

326. Shiozaki AA, Filho RA de F, Dallan LAO, de Oliveira SA, Nicolau JC, Rochitte CE. Left Ventricular Free-Wall Rupture After Acute Myocardial Infarction Imaged by Cardiovascular Magnetic Resonance. *J Cardiovasc Magn Reson*. 2007 Jul;9(4):719–21.
327. Shreetal RN, Sajeer K, Sandeep R, Rajesh GN, Haridasan V, Sadanadan R, et al. Double ventricular rupture after acute myocardial infarction: A rare case report. *Indian Heart J*. 2015 Dec;67:S21–3.
328. Si D, Shi K, Gao D, Yang P. Ruptured left ventricular pseudoaneurysm in the mediastinum following acute myocardial infarction: a case report. *Eur J Med Res*. 2013 Dec;18(1):2.
329. Silveira I, Rodrigues P, Gomes C, Torres S. Giant Left Ventricular Pseudoaneurysm as a Late Complication of Myocardial Infarction.
330. Singh AS, Sivakumar K. Case report: pericardial adhesions from a previous coronary artery bypass surgery contain a left ventricular free wall rupture after an acute myocardial infarction to form a pseudoaneurysm. *Eur Heart J - Case Rep [Internet]*. 2018 Sep 1 [cited 2023 Feb 10];2(3). Available from: <https://academic.oup.com/ehjcr/article/doi/10.1093/ehjcr/tyt081/5062277>
331. Singh A, Kliger C, Ruiz CE. Novel approach for the percutaneous treatment of left ventricular pseudoaneurysms: Percutaneous Treatment of LVPA. *Catheter Cardiovasc Interv*. 2015 May;85(6):1092–6.
332. Singh BK, Greene AL, Ritchie ME. Pseudo-Pseudoaneurysm of the Left Ventricle. *Cardiology*. 1998;89(2):159–61.
333. Smolka G, Peszek-Przybyla E, Sosnowski M, Ochala A. Complete Percutaneous Obliteration of a Post-Infarction Left Ventricular Inferior Wall Pseudoaneurysm. *JACC Cardiovasc Interv*. 2012 Aug;5(8):886–7.
334. Sokolskaya N, Kopylova N, Slivneva I, Kolesnikov Y, Alshibaya M, Zakharkina M. CASE REPORTS Echocardiographic diagnosis of a massive left ventricular pseudoaneurysm: a case report. *Pol J Cardio-Thorac Surg*. 2015;2:181–3.
335. Sørensen MB, Moat NE, Mohiaddin RH. False Left Ventricular Aneurysm Documented by Magnetic Resonance Imaging. *Circulation*. 2002 Apr 9;105(14):1734–1734.
336. Sorrell VL, Callaway MJ, Zwischenberger JB, Schmedtje JFJ. Left Ventricular Pseudoaneurysm. *J Thorac Imaging*. 1994 Fall;9(4):258.
337. Soud M, Moussa Pacha H, Hritani R, Alraies MC. Post myocardial infarction left ventricular pseudoaneurysm. *Cardiovasc Revasc Med*. 2018 Mar;19(2):199–200.
338. Sousa P, Santos W, Cordeiro P, Pereira S, Ferrinha R, Brandão V, et al. Pseudoaneurysm inside of a true aneurysm. *J Cardiothorac Surg*. 2013 Dec;8(1):97.
339. Stanton MW, Douthit MB, Jenkins RD, Holland MR, Martin SL, Albrecht MA. Recurrent left ventricular false aneurysm. *Ann Thorac Surg*. 1997 May;63(5):1472–3.
340. Subban V, Sethuratnam R, Ajit MS. Asymptomatic large unruptured left ventricular pseudoaneurysm. *Heart*. 2009 Jul 15;95(14):1139–1139.
341. Subban V, Kurian VM, Ajit MS, Kumar RS. Hybrid Trans-apical Device Closure of Left Ventricular Pseudoaneurysm Under Trans-oesophageal Echocardiographic Guidance. *Heart Lung Circ*. 2012 Nov;21(11):734–6.

342. Sulman D, Darmon A, Ducrocq G. A giant left ventricular calcified pseudoaneurysm 24 years following acute myocardial infarction: a case report. Hatipoglu S, Bawaskar P, Henze J, editors. *Eur Heart J - Case Rep.* 2021 Sep 4;5(9):ytab329.
343. Suzuki A, Ishikawa J, Nemoto Y, Tanaka J, Nishimura T, Kyo S, et al. Acute left ventricular free wall rupture treated by percutaneous intra-pericardial fibrin-glue infusion. *J Echocardiogr.* 2019 Jun;17(2):106–8.
344. Takahashi T, Okayama H, Hiasa G, Kazatani Y, Sasaki H. Giant left ventricular pseudoaneurysm: a rare complication of surgical patch repair for left ventricular free wall rupture. *Eur Heart J – Cardiovasc Imaging.* 2016 Feb;17(2):176–176.
345. Tallarico D, Chiavari PA, Mollo P, Campolongo G. Left Ventricular Pseudoaneurysm: Echocardiographic and Intraoperative Images. *Circulation [Internet].* 2005 Feb [cited 2023 Feb 10];111(4). Available from: <https://www.ahajournals.org/doi/10.1161/01.CIR.0000153815.87329.1D>
346. Tang L, Tang J jun, Hu X qun, Fang Z fei, Zhu Z wei, Chen Y qin, et al. Transcatheter Closure of Complex Post-Myocardial Infarction Left Ventricular Pseudoaneurysm and Unique Post-Traumatic Right Ventricular Pseudoaneurysm. *Int Heart J.* 2019 Jul 30;60(4):998–1002.
347. Tarrio RF, Martinell MJ, Moya GJ, Calderon RP. Endocavitary Patch Repair for a Left Ventricular Pseudoaneurysm: An Alternative Approach. *J Card Surg.* 2005 May;20(3):278–80.
348. Thavendiranathan P, Verhaert D, Hasan A, Sun BC, Sai-Sudhakar C, Rajagopalan S, et al. Contained Left Ventricular Free Wall Rupture After Myocardial Infarction. *J Am Coll Cardiol.* 2010 Jun;56(1):e1.
349. Tiwari P, Patel T, Shah S, Dev M. Left Ventricular Apical Pseudoaneurysm with Cardiac Tamponade. *J Cardiovasc Imaging.* 2020;28(1):74.
350. Tomescu M, Rusinaru D, Mut-Vitcu B, Cocora M, Mavrea A, Citu I, et al. Unusual Cause of Heart Failure in a 65-Year-Old Woman. *Echocardiography [Internet].* 2008 Sep [cited 2023 Feb 10]; Available from: <https://onlinelibrary.wiley.com/doi/10.1111/j.1540-8175.2008.00759.x>
351. Torchio F, Garatti A, Ronco D, Matteucci M, Massimi G, Lorusso R. Left ventricular pseudoaneurysm: the niche of post-infarction mechanical complications. *Ann Cardiothorac Surg.* 2022 May;11(3):290–8.
352. Tran T, Ross B, Colletti P, Ching R. Gd-Enhanced Cardiovascular MR Imaging to Identify Left Ventricular Pseudoaneurysm. *J Cardiovasc Magn Reson.* 2005 Jul 1;7(4):717–21.
353. Tsai IC, Lin MC, Jan SL, Fu YC. Multidetector Row Computed Tomography for Percutaneous Closure of a Left Ventricular Free Wall Rupture After Myocardial Infarction. *JACC Cardiovasc Interv.* 2015 Sep;8(11):e175–6.
354. Tsukagoshi J, Miura S, Yamada A. Challenges in management of a giant left ventricular pseudoaneurysm complicated by intracerebral hemorrhage. *J Card Surg.* 2020 Jul;35(7):1636–7.
355. Tuan J, Kaivani F, Fewins H. Left ventricular pseudoaneurysm. *Eur J Echocardiogr.* 2007 Jun 21;S152521670700131X.
356. Tutar E. Familial Mediterranean fever gene (MEFV) mutations in patients with rheumatic heart disease. *Heart.* 2002 Jun 1;87(6):568–9.
357. Unai S, Ohno T, Miyairi T. Left Ventricular Pseudoaneurysm Following Myocardial Infarction: Images in Cardiac Surgery. *J Card Surg.* 2013 Jan;28(1):47–47.

358. Varghese A. Cardiovascular magnetic resonance of left ventricular pseudoaneurysm. *Heart*. 2005 Apr 1;91(4):477–477.
359. Varvarigos N, Koletsis E, Zafiropoulos A, Papaioannou H, Migdalis I. A case of left ventricular pseudoaneurysm with long survival and congestive heart failure as first presentation. Case report and review of the literature. *Med Sci Monit Int Med J Exp Clin Res*. 2005 Nov;11(11):CS69-73.
360. Vijayvergiya R. Giant left ventricular pseudoaneurysm presenting with hemoptysis. *World J Cardiol*. 2012;4(6):218.
361. Vijayvergiya R, Hasan A, Singhal M. Spontaneous closure of a large left ventricular pseudoaneurysm. *Indian Heart J*. 2016 Sep;68:S81–2.
362. Villanueva C, Milder D, Manganas C. Ruptured Left Ventricular False Aneurysm Following Acute Myocardial Infarction: Case Report and Review of the Literature. *Heart Lung Circ*. 2014 Dec;23(12):e261–3.
363. Virmani R. Drug eluting stents: are human and animal studies comparable? *Heart*. 2003 Feb 1;89(2):133–8.
364. Walters MI, Caplin JL. Atrioventricular fistula: an unusual complication of a ventricular pseudoaneurysm after myocardial infarction. *Heart*. 1998 May 1;79(5):523–4.
365. Watanabe T, Iwai-Takano M, Ohto Y, Abe H, Saitoh H, Ujiie M, et al. A case of left ventricular aneurysm caused by localized myocardial infarction. *J Echocardiogr*. 2013 Sep;11(3):106–8.
366. Webb J, Gemmell M, Al-Fakih K, Chiribiri A. Medical treatment of left ventricular pseudoaneurysms. *QJM*. 2016 Mar;109(3):213–4.
367. Weber DJ, Sheikh AY, Cain BS, LaBourene JI, Melikian V. Repair of Enlarging Left Ventricular Pseudoaneurysm Two Months After Coronary Artery Bypass Grafting. *Ann Thorac Surg*. 2019 Jan;107(1):e37–9.
368. Weston MW, Mckinnon E, Donald T, Vijayanagar R, Canedo M. Unknown Extra Cardiac Echo-Free Space: Diagnosis of a Left Ventricular Pseudoaneurysm by Color Flow Echocardiography. *Clin Cardiol*. 1991 Jun;14(6):526–8.
369. White JM, Lowe BS, Ruygrok PN. A Man With 3 Lives. *JACC Cardiovasc Interv*. 2015 Apr;8(5):e77–9.
370. Wieczorek J, Mizia-Stec K, Rybicka-Musialik A, Janusiewicz P, Malinowski M, Deja MA. A large pseudoaneurysm of the left cardiac ventricle in a 57-year-old patient after urgent coronary artery bypass grafting and surgical mitral valve replacement due to acute myocardial infarction. *Pol J Cardio-Thorac Surg*. 2014;4:432–6.
371. Witalka T, Smith M, Lee S. Anterior wall ventricular pseudoaneurysm presenting as dizziness and syncope. *Am J Emerg Med*. 2019 Jan;37(1):175.e3-175.e5.
372. Wolf M, Vermeersch P, Reet BV, Branden FLJVD. Early surgical repair of an acute post-infarction left ventricular pseudoaneurysm complicated by second pseudoaneurysm formation. *Acta Cardiol*. 2012 Dec;67(6):723–6.
373. Woods T, Grist T, Rahko P. Leaking Left Ventricular Pseudoaneurysm. *Circulation*. 1999 Jul 20;100(3):329–329.
374. Yalonetsky S, Abikeeva L, Suigenbayev D, Lessick J, Aronson D. Post-infarction biventricular free wall rupture with an extracardiac left to right shunt thorough a pseudoaneurysm. *Int J Cardiol*. 2015 May;186:264–5.

375. Yamada H, Sakurai A, Higurashi A, Takeda K. Cardiac CT for intraseptal pseudoaneurysm: impending double rupture of ventricular septum and left ventricular free wall. *Case Rep.* 2015 Jan 27;2015(jan27 2):bcr2014207352–bcr2014207352.
376. Yamada S, Kainuma S, Toda K, Sawa Y. Giant Left Ventricular Pseudoaneurysm 10 Years After Post-Infarct Ventricular Septal Defect Repair. *Circ J.* 2022 Apr 25;86(5):877.
377. Yavari A, Sriskandan N, Khawaja MZ, Walker DM, Giles JA, McWilliams ET. Computed tomography of a broken heart: Chronic left ventricular pseudoaneurysm. *J Cardiovasc Comput Tomogr.* 2008 Mar;2(2):120–2.
378. Yaymaci B, Bozbuğa N, Balkanay M. Unruptured left ventricular pseudoaneurysm. *Int J Cardiol.* 2001 Jan;77(1):99–101.
379. Yeo TC. Clinical Profile and Outcome in 52 Patients with Cardiac Pseudoaneurysm. *Ann Intern Med.* 1998 Feb 15;128(4):299.
380. Yıldız İ. Left ventricular pseudoaneurysm as a silent complication of non-ST segment elevation myocardial infarction. *Turk Kardiyol Dernegi Arsivi-Arch Turk Soc Cardiol [Internet].* 2017 [cited 2023 Feb 10]; Available from: <https://archivestsc.com/jvi.aspx?un=TKDA-22934>
381. Yilmaztepe MA. Left ventricle pseudoaneurysm detected eight months after myocardial infarction. *Turk Kardiyol Dernegi Arsivi-Arch Turk Soc Cardiol [Internet].* 2018 [cited 2023 Feb 10]; Available from: <https://archivestsc.com/jvi.aspx?un=TKDA-59607>
382. Yoda M, Hata M, Sezai A, Niino T, Unosawa S, Wakui S, et al. A Surgical Case of Left Ventricular Pseudoaneurysm Complicating Myocardial Infarction in a Diabetic Patient on Dialysis. 2007;13(3).
383. Yoshida R, Takagi K, Morita Y, Morishima I. Incidentally discovered left ventricular pseudoaneurysm after silent myocardial infarction occurred in a young woman with peritoneal dialysis. *Eur Heart J.* 2019 May 7;40(18):1474–1474.
384. Yu TH, Hung WC, Chiu CA, Wang CP. Medical Treatment of a Salmonella-infected Left Ventricular Pseudoaneurysm: A Case Report. *Kaohsiung J Med Sci.* 2010 Jan;26(1):35–9.
385. Yucel G, Steinberg E, O'Reilly M, Kronzon I. Giant Left Ventricular Pseudoaneurysm. *Circulation.* 1996 Aug 15;94(4):848–848.
386. Zhang Y, Li Y, Yang Y, Lv Q. Usefulness of contrast echocardiography in the diagnosis of left ventricular pseudoaneurysm. *QJM Int J Med.* 2020 Oct 1;113(10):741–2.
387. Zhang Y, Yang Y, Sun HS, Tang Y. Surgical Treatment of Left Ventricular Pseudoaneurysm. *Chin Med J (Engl).* 2018 Jun 20;131(12):1496–7.
388. Zhang ZP, Su X, Liu CW, Song D, Peng J, Wu MX, et al. Use of intra-aortic balloon pump support for oozing-type cardiac rupture after acute myocardial infarction. *Am J Emerg Med.* 2016 Jan;34(1):120.e1-120.e3.
389. Zheng Y, Zhu W, Huang X, Lin Y. Rapidly Progressing Fatal Left Ventricular Pseudoaneurysm After Acute Myocardial Infarction - A Case Report of Delayed Diagnosis: Ventricular Pseudoaneurysm - A Case Report. *Heart Surg Forum.* 2021 Apr 29;24(2):E414–7.
390. Zhong W, Liu Z, Fan W, Ou B, Zhong M, Zeng Z, et al. Transcatheter closure for the treatment of pseudoventricular aneurysm after acute myocardial infarction: a case report. *Ann Transl Med.* 2020 Nov;8(22):1528–1528.

391. Zoffoli G, Mangino D, Venturini A, Terrini A, Asta A, Zanchettin C, et al. Diagnosing left ventricular aneurysm from pseudo-aneurysm: a case report and a review in literature. *J Cardiothorac Surg*. 2009 Dec;4(1):11.
392. Zouari F, Tlili R, Azaiez F, Zayed S, Ben Romdhane R, Ziadi J, et al. Thrombosed left ventricular pseudoaneurysm following myocardial infarction: a case report. *J Med Case Reports*. 2021 Dec;15(1):258.
393. Abbood A, Al Salihi H, Olivier M, Khawaja F, Madruga M, Carlan SJ. Left Ventricular Pseudoaneurysm and Left Ventricular Thrombus in a Patient Presenting with an Acute ST-Elevation Myocardial Infarction. *Am J Case Rep [Internet]*. 2021 Nov 22 [cited 2023 Feb 11];23. Available from: <https://www.amjcaserep.com/abstract/index/idArt/934272>
394. Abdelnaby M, Almaghraby A, Saleh Y, Hammad B, El-Amin A, El-Fawal S, et al. A Case of Left Ventricular Pseudoaneurysm. 2017;
395. Al Lawati A, Al-Hadhrami W, Al Hosni F, Al Lawati M, Elseragy E, Sirasanagandla S, et al. A Rare Case of a Left Ventricular Pseudoaneurysm With Lateral Wall Rupture. *Cureus [Internet]*. 2022 Mar 7 [cited 2023 Feb 11]; Available from: <https://www.cureus.com/articles/88032-a-rare-case-of-a-left-ventricular-pseudoaneurysm-with-lateral-wall-rupture>
396. Al Saidi K, Malik SA, Albulushi A, Moulton M, Chatzizisis YS. Left Ventricular Pseudoaneurysm Complicated With Very Late Rupture 5 Years After Myocardial Infarction. *JACC Case Rep*. 2019 Dec;1(4):569–72.
397. Alapati L. Left ventricular pseudoaneurysm: A case report and review of the literature. *World J Clin Cases*. 2014;2(4):90.
398. Aliyev N, Ibrahim M. Cardiac Magnetic Resonance Imaging of Massive Left Ventricular Pseudoaneurysm.
399. Ashraf H, Sadatnaseri A, Aminorroaya A, Kuhl Z, Zandi N, Karbalai Saleh S. Left Ventricular Pseudoaneurysm as a Complication of Myocardial Infarction; A Case Series and Review of the Literature. *Front Emerg Med [Internet]*. 2021 Apr 4 [cited 2023 Feb 11]; Available from: <https://18.184.16.47/index.php/FEM/article/view/5892>
400. Azraai M, Ajani AE. Late Post- Infarction Left Ventricular Pseudoaneurysm: A Case Report. *Cardiovasc Revasc Med*. 2020 Jan;21(1):145–6.
401. Bai W. Left ventricular pseudoaneurysm following acute myocardial infarction. *Anatol J Cardiol [Internet]*. 2018 [cited 2023 Feb 11]; Available from: <https://anatoljcardiol.com/jvi.aspx?un=AJC-39001>
402. Baks T, Cademartiri F, Spierenburg HAM, Feyter PJ de. Chronic pseudoaneurysm of the left ventricle. *Int J Cardiovasc Imaging*. 2006 Jun;22(3–4):497–9.
403. Banisaukaite A, Velavan P, Hasleton J, Mediratta N, Arzanauskaite M, Binukrishnan S. Myocardial rupture and left ventricular pseudoaneurysm due to late STEMI presentation during the COVID-19 pandemic lockdown: a classical case report. Potter TD, Henzel J, Karamisis G, Bernstein BS, Sunjaya AP, editors. *Eur Heart J - Case Rep*. 2021 Jul 1;5(7):ytab253.
404. Bisoyi S, Dash A, Nayak D, Sahoo S, Mohapatra R. Left ventricular pseudoaneurysm versus aneurysm a diagnosis dilemma. *Ann Card Anaesth*. 2016;19(1):169.
405. Bryniarski L, Kubinyi A, Ekiert-Kubinyi M, Kawecka-Jaszcz K. Postinfarction left ventricular pseudoaneurysm with left-to-right shunt: Case report and review of the literature. *Int J Cardiol*. 2010 Mar;139(2):199–201.



406. Butz T, Faber L, Langer C, Horstkotte D. Giant left ventricular pseudoaneurysm: a rare complication following left ventricular rupture caused by myocardial infarction. *Eur Heart J*. 2008 Jan;29(2):143–143.
407. Cacciapuoti F, Tirelli P, Cacciapuoti F. Left ventricular postinfarction pseudoaneurysm: diagnostic advantages of three-dimensional echocardiography. *J Cardiovasc Echography*. 2017;27(2):74.
408. Caldeira A, Albuquerque D, Coelho M, Côrte-Real H. Left Ventricular Pseudoaneurysm: Imagiologic and Intraoperative Images. *Circ Cardiovasc Imaging*. 2019 Dec;12(12):e009500.
409. Chakraborty RN, Nicholson AA, Alamgir MF. Magnetic resonance images of left ventricular pseudoaneurysm. *Heart*. 1998 Jul 1;80(1):101–2.
410. Cho MN, Mehta SK, Matulevicius S, Weinstein D, Wait MA, McGuire DK. Differentiating True Versus Pseudo Left Ventricular Aneurysm: A Case Report and Review of Diagnostic Strategies. *Cardiol Rev*. 2006 Nov;14(6):e27–30.
411. Contuzzi R, Gatto L, Patti G, Goffredo C, D'Ambrosio A, Covino E, et al. Giant left ventricular pseudoaneurysm complicating an acute myocardial infarction in patient with previous cardiac surgery: a case report: *J Cardiovasc Med*. 2009 Jan;10(1):81–4.
412. Csapo K, Voith L, Szuk T, Edes I, Kereiakes DJ. Postinfarction Left Ventricular Pseudoaneurysm. *Clin Cardiol*. 1997 Oct;20(10):898–903.
413. Davutoglu V, Soyduinc S, Sezen Y, Aksoy M. Unruptured giant left ventricular pseudoaneurysm complicating silent myocardial infarction in a diabetic young adult: Left ventricular giant pseudoaneurysm after silent myocardial infarction. *Int J Cardiovasc Imaging*. 2005 Apr;21(2–3):231–4.
414. Della Rocca DG, Forleo GB, Stazi CA, Franco G, Volpe GA, Romeo F. Massive Left Ventricular Pseudoaneurysm 20 Years After Acute Myocardial Infarction. *J Am Coll Cardiol*. 2013 Dec;62(23):e523.
415. Diago JL. Left Ventricular Pseudoaneurysm in Cardiac Magnetic Resonance Imaging.
416. Díaz-Navarro R, Nihoyannopoulos P. Post-myocardial infarction left ventricular pseudoaneurysm diagnosed incidentally by echocardiography. *Echo Res Pract*. 2017 Dec;4(4):K37–40.
417. Erdim R, Yildirimturk O, Polat B, Aytekin S, Demiroglu C, Aytekin V. Left Ventricular Pseudoaneurysm Complicating Inferior Myocardial Infarction: A Case Report. *Int J Angiol*. 2011 Jun;20(02):107–10.
418. Falcão JL de AA, Falcão SNRS, Garcia MFMA, Arruda ALM, Hueb AC, Jatene FB, et al. Pseudoaneurisma de ventrículo esquerdo associado a insuficiência mitral grave complicando infarto agudo do miocárdio ínfero-látero-dorsal. *Arq Bras Cardiol*. 2005 Jun;84(6):488–91.
419. Faustino M, Ranchordás S, Abecasis J, Freitas A, Ferreira M, Gil V, et al. Pseudoaneurisma ventricular esquerdo – um desafio diagnóstico. *Rev Port Cardiol*. 2016 Jun;35(6):373.e1-373.e6.
420. Frances CD, Shlipak MG, Grady D. Left Ventricular Pseudoaneurysm: Diagnosis by Cine Magnetic Resonance Imaging. *Cardiology*. 1999;92(3):217–9.
421. Garg P, Rajashekar P, Airan B. Giant left ventricular pseudoaneurysm following inferior wall myocardial infarction—A case report. *Indian J Thorac Cardiovasc Surg*. 2013 Jun;29(2):131–3.

422. Ghersin E, Kerner A, Gruberg L, Bar-El Y, Abadi S, Engel A. Left ventricular pseudoaneurysm or diverticulum: differential diagnosis and dynamic evaluation by catheter left ventriculography and ECG-gated multidetector CT. *Br J Radiol.* 2007 Sep;80(957):e209–11.
423. Gill S, Rakhit DJ, Ohri SK, Harden SP. Left ventricular true and false aneurysms identified by cardiovascular magnetic resonance. *Br J Radiol.* 2011 Feb;84(998):e35–7.
424. Gomes R, Andrade MJ, Santos M, Lima S, Gouveia RA, Ferreira MM, et al. “Mushroom cloud”: a giant left ventricular pseudoaneurysm after a myocardial infarction due to myocardial bridging – a case report. *Cardiovasc Ultrasound.* 2009 Dec;7(1):36.
425. Ho HH, Sinaga DA, Hon JKF. Left ventricular pseudoaneurysm.
426. Hung MJ, Wang CH, Cherng WJ. Unruptured left ventricular pseudoaneurysm following myocardial infarction. *Heart.* 1998 Jul 1;80(1):94–7.
427. Hung MJ, Cherng WJ, Kuo L i T, Wang CH. Echocardiographic characteristics of patients surviving nonsurgically treated left ventricular pseudoaneurysm after acute myocardial infarction. *Am J Cardiol.* 2003 Feb;91(3):328–31.
428. Ivert T, Almdahl SM, Lunde P, Lindblom D. Postinfarction left ventricular pseudoaneurysm--echocardiographic diagnosis and surgical repair. *Cardiovasc Surg Lond Engl.* 1994 Aug;2(4):463–6.
429. Jacob JLB, Buzelli G, Machado NCS, Garzon PGA, Garzon SAC. Pseudoaneurysm of Left Ventricle.
430. Kaur N, Panda P, Choudhary AK, Sharma YP. Left ventricular pseudoaneurysm: imaging. *BMJ Case Rep.* 2021 Jun;14(6):e243913.
431. Kerkhoff GO, Höfs C, Roer N, Albes G, Lehner A, Koslowski B, et al. Left Ventricular Pseudoaneurysm: Clinical Role of Cardiovascular Magnetic Resonance Imaging. *Circulation [Internet].* 2004 May 25 [cited 2023 Feb 11];109(20). Available from: <https://www.ahajournals.org/doi/10.1161/01.CIR.0000130756.52908.B2>
432. Kim KH, Yoon JH, Kim JY, Lee HH, Ko JY, Lee BK, et al. A Case of Asymptomatic Left Ventricular Pseudoaneurysm after Myocardial Infarction. *Korean Circ J.* 1999;29(12):1357.
433. Kim MN, Park SM, Kim SW, Lee KN, Kim JS, Kang EJ, et al. Progression of Left Ventricular Pseudoaneurysm after an Acute Myocardial Infarction. *J Cardiovasc Ultrasound.* 2010;18(4):161.
434. Konen E, Merchant N, Gutierrez C, Provost Y, Mickleborough L, Paul NS, et al. True versus False Left Ventricular Aneurysm: Differentiation with MR Imaging—Initial Experience. *Radiology.* 2005 Jul;236(1):65–75.
435. Koak H, Becit N, Ceviz M, n Y. Left ventricular pseudoaneurysm after myocardial infarction. *Heart Vessels.* 2003 Jul 1;18(3):160–2.
436. Leitman M, Shmueli R, Stamler A, Krakover R, Hendler A, Vered Z. An Unusual Presentation of a Large Left Ventricular Pseudoaneurysm. *Echocardiography.* 2006 May;23(5):403–4.
437. Li X, Wang Y, Wang D, Lai C, Wang C. The evolution of left ventricular pseudoaneurysm from the rupture of left ventricular free wall following acute myocardial infarction: a case report. *BMC Cardiovasc Disord.* 2020 Dec;20(1):5.



438. Ludmir J, Kapoor K, George P, Khural J, Barr B. Left Ventricular Pseudoaneurysm Following Inferior Myocardial Infarction: A Case for Conservative Management. *Cardiol Res.* 2016;7(1):32–5.
439. MacDonald ST, Mitchell ARJ, Timperley J, Forfar JC. Left Ventricular Pseudoaneurysm and Rupture After Limited Myocardial Infarction. *J Am Soc Echocardiogr.* 2005 Sep;18(9):980.e1-980.e4.
440. Mahilmaran A, Nayar PG, Abraham KA. Left Ventricular Pseudoaneurysm.
441. Mao CT, Li MF, Kao YC, Cherng WJ, Hung MJ. Long-term Survival of A Patient with Asymptomatic Left Ventricular Pseudoaneurysm after Acute Myocardial Infarction.
442. Marchandot B, Crimzade U, El Ghannudi S, Morel O. Giant ventricular pseudoaneurysm following inferior myocardial infarction: insights from multimodal imaging approach. *Eur Heart J - Case Rep [Internet].* 2018 Mar 1 [cited 2023 Feb 11];2(1). Available from: <https://academic.oup.com/ehjcr/article/doi/10.1093/ehjcr/tyt019/4922886>
443. Martin R, Tegtmeier T, Smith AS, Ognibene A, Ognibene A. Left Ventricular Pseudoaneurysm Presenting Twenty-eight Months After Myocardial Infarction: A Case Report. *Angiology.* 1997 Feb;48(2):177–81.
444. Meng X, Yang YK, Yang KQ, Zhang Y, Lu PP, Fan P, et al. Clinical characteristics and outcomes of left ventricular pseudoaneurysm: A retrospective study in a single-center of China. *Medicine (Baltimore).* 2017 May;96(18):e6793.
445. Mittal S. Left Ventricular Pseudoaneurysm.
446. Moreno R. Usefulness of Contrast Agents in the Diagnosis of Left Ventricular Pseudoaneurysm after Acute Myocardial Infarction. *Eur J Echocardiogr.* 2002 Jun;3(2):111–6.
447. Mousavi N, Buksak R, Walker JR, Hussain F, Pascoe E, Kirkpatrick IDC, et al. Left ventricular pseudoaneurysm: The role of multimodality cardiac imaging. *Can J Cardiol.* 2009 Nov;25(11):e389.
448. Narayan RL, Vaishnav P, Goldman ME, Stelzer P, Clark L, Kini AS, et al. Percutaneous Closure of Left Ventricular Pseudoaneurysm. *Ann Thorac Surg.* 2012 Nov;94(5):e123–5.
449. Nekkanti R, Nanda NC, Ansingkar KG, McGiffin DC. Transesophageal Three-Dimensional Echocardiographic Assessment of Left Ventricular Pseudoaneurysm. *Echocardiography.* 2002 Feb;19(2):169–72.
450. Neven KGEJ, Crijns HJGM, Cheriex EC. Late left ventricular pseudoaneurysm formation following subacute myocardial infarction. *Int J Cardiol.* 2005 Jan;98(1):165–7.
451. Niimura H, Mito T, Matsunaga A, Koga S, Akasu K, Morishige N, et al. Left Ventricular Pseudoaneurysm Following Acute Myocardial Infarction. *Intern Med.* 2006;45(21):1221–3.
452. Oliveira SM, Dias P, Pinho T, Gavina C, Almeida PB, Madureira AJ, et al. Giant left ventricular pseudoaneurysm: The diagnostic contribution of different non-invasive imaging modalities. *Rev Port Cardiol Engl Ed.* 2012 Jun;31(6):439–44.
453. Orsborne C, Schmitt M. Left ventricular pseudoaneurysm after myocardial infarction detected by cardiac MRI. *Case Rep.* 2014 Nov 25;2014(nov25 2):bcr2014207277–bcr2014207277.
454. Patra S, Dhadake SM, Agrawal N, Cn M. Giant left ventricular pseudoaneurysm following acute inferior wall myocardial infarction presenting with acute left ventricular failure: a rare complication. *Case Rep.* 2013 Aug 2;2013(aug02 1):bcr2013200270–bcr2013200270.

455. Petrou E. Left ventricular pseudoaneurysm formation: Two cases and review of the literature. *World J Clin Cases*. 2014;2(10):581.
456. Pineda-De Paz DO, Hernández-del Rio JE, González-Padilla C, Esturau-Santaló RM, Romero-Palafox J, Grover-Paez F, et al. Left ventricular free-wall rupture, a potentially lethal mechanical complication of acute myocardial infarction: an unusual and illustrative case report. *BMC Cardiovasc Disord*. 2019 Dec;19(1):80.
457. Rasouly N, Stanekzai R, Hamidi H, Ahamdzai R. Computed Tomography Features of Left Ventricular Pseudoaneurysm: A Case Report. *Iran J Radiol [Internet]*. 2016 Dec 28 [cited 2023 Feb 11];In press(In press). Available from: <https://brieflands.com/articles/iranradiol-56268.html>
458. Reyaldeen R, Jeffries C, Hardman D, Challa P, Dahiya A. Multimodality Imaging in a Case of Chronic Massive Left Ventricular Pseudoaneurysm. *CASE*. 2018 Jun;2(3):95–8.
459. Schalla S, Bar F, Mochtar B, Snoep G. Left ventricular pseudoaneurysm.
460. Shimono H, Kajiyama T, Inoue H, Ueno M, Takaoka J, Atsuchi Y, et al. Left Ventricular Pseudo-aneurysm with Ventricular Septal Rupture Due to Anterior ST-segment Elevation Myocardial Infarction. *Intern Med*. 2019 Jul 1;58(13):1901–5.
461. Shiozaki AA, Filho RA de F, Dallan LAO, de Oliveira SA, Nicolau JC, Rochitte CE. Left Ventricular Free-Wall Rupture After Acute Myocardial Infarction Imaged by Cardiovascular Magnetic Resonance. *J Cardiovasc Magn Reson*. 2007 Jul;9(4):719–21.
462. Si D, Shi K, Gao D, Yang P. Ruptured left ventricular pseudoaneurysm in the mediastinum following acute myocardial infarction: a case report. *Eur J Med Res*. 2013 Dec;18(1):2.
463. Sokolskaya N, Kopylova N, Slivneva I, Kolesnikov Y, Alshibaya M, Zakharkina M. CASE REPORTS Echocardiographic diagnosis of a massive left ventricular pseudoaneurysm: a case report. *Pol J Cardio-Thorac Surg*. 2015;2:181–3.
464. Soud M, Moussa Pacha H, Hritani R, Alraies MC. Post myocardial infarction left ventricular pseudoaneurysm. *Cardiovasc Revasc Med*. 2018 Mar;19(2):199–200.
465. Tallarico D, Chiavari PA, Mollo P, Campolongo G. Left Ventricular Pseudoaneurysm: Echocardiographic and Intraoperative Images. *Circulation [Internet]*. 2005 Feb [cited 2023 Feb 11];111(4). Available from: <https://www.ahajournals.org/doi/10.1161/01.CIR.0000153815.87329.1D>
466. Tuan J, Kaivani F, Fewins H. Left ventricular pseudoaneurysm. *Eur J Echocardiogr*. 2007 Jun 21;S152521670700131X.
467. Varghese A. Cardiovascular magnetic resonance of left ventricular pseudoaneurysm. *Heart*. 2005 Apr 1;91(4):477–477.
468. Vijayvergiya R. Giant left ventricular pseudoaneurysm presenting with hemoptysis. *World J Cardiol*. 2012;4(6):218.
469. Yaymaci B, Bozbuğa N, Balkanay M. Unruptured left ventricular pseudoaneurysm. *Int J Cardiol*. 2001 Jan;77(1):99–101.
470. Yoda M, Hata M, Sezai A, Niino T, Unosawa S, Wakui S, et al. A Surgical Case of Left Ventricular Pseudoaneurysm Complicating Myocardial Infarction in a Diabetic Patient on Dialysis. 2007;13(3).

471. Zoffoli G, Mangino D, Venturini A, Terrini A, Asta A, Zanchettin C, et al. Diagnosing left ventricular aneurysm from pseudo-aneurysm: a case report and a review in literature. *J Cardiothorac Surg*. 2009 Dec;4(1):11.
472. Zouari F, Tlili R, Azaiez F, Zayed S, Ben Romdhane R, Ziadi J, et al. Thrombosed left ventricular pseudoaneurysm following myocardial infarction: a case report. *J Med Case Reports*. 2021 Dec;15(1):258.
473. Biernacka A, Frangogiannis NG. Aging and Cardiac Fibrosis. *Aging Dis*. 2011;2(2).
474. Albrektsen G, Heuch I, Løchen ML, Thelle DS, Wilsgaard T, Njølstad I, et al. Lifelong Gender Gap in Risk of Incident Myocardial Infarction: The Tromsø Study. *JAMA Intern Med*. 2016 Nov 1;176(11):1673.
475. Ruzza A, Czer LSC, Arabia F, Vespignani R, Esmailian F, Cheng W, et al. Left Ventricular Reconstruction for Postinfarction Left Ventricular Aneurysm: Review of Surgical Techniques. *Tex Heart Inst J*. 2017 Oct 1;44(5):326–35.
476. Bromage DI, Trevelin S, Huntington J, Yang VX, Mackie SJ, Sawyer G, et al. Nrf2 attenuates the innate immune response after experimental myocardial infarction.
477. Goette A. Tachycardia-induced remodeling: atria and ventricles take a different route. *Cardiovasc Res*. 2004 Aug;63(2):194–5.
478. Subban V, Kurian VM, Ajit MS, Kumar RS. Hybrid Trans-apical Device Closure of Left Ventricular Pseudoaneurysm Under Trans-oesophageal Echocardiographic Guidance. *Heart Lung Circ*. 2012 Nov;21(11):734–6.
479. Ousaka D, Obara N, Fujiwara M, Nakagawa K, Teraoka A, Kasahara S, et al. A case of conservative management for left ventricular giant pseudoaneurysm without ST segment changes. *J Cardiol Cases*. 2018 May;17(5):167–70.
480. Høyland K, Mohamed Ali A, Vegsundvåg J, Chambers JB, Saeed S. Echocardiographic features of left ventricular recess, cleft, diverticulum, and aneurysm: A systematic review. *J Clin Ultrasound*. 2022 Mar;50(3):339–46.
481. Bisoyi S, Dash A, Nayak D, Sahoo S, Mohapatra R. Left ventricular pseudoaneurysm versus aneurysm a diagnosis dilemma. *Ann Card Anaesth*. 2016;19(1):169.
482. Tuan J, Kaivani F, Fewins H. Left ventricular pseudoaneurysm. *Eur J Echocardiogr*. 2007 Jun 21;S152521670700131X.
483. Gaddipati VC, Martin AI, Valenzuela MO, Mahmud A, Patel AA. An Incidentally Detected Right Ventricular Pseudoaneurysm. *Case Rep Cardiol*. 2017;2017:1–4.
484. Gill S, Rakhit DJ, Ohri SK, Harden SP. Left ventricular true and false aneurysms identified by cardiovascular magnetic resonance. *Br J Radiol*. 2011 Feb;84(998):e35–7.
485. Patel P, Siegenthaler M, Bandettini WP, Arai AE, Fujikura K. Left Ventricular Pseudoaneurysm in a Patient With an Apical Aneurysm. *JACC Case Rep*. 2021 Jan;3(1):91–3.