

1 **Listract test: a Standardized Assessment Method for Isolated Lisfranc Instability in**  
2 **Cadaver Models**

3 Vasundhara Mathur<sup>1</sup>, David O. Osei-Hwedie<sup>1,2</sup>, Sayyed Hadi Sayyed Hosseinian<sup>1</sup>, Fernando  
4 Raduan<sup>1,3</sup>, Philip Kaiser<sup>1,3</sup>, Hamid Ghaednia<sup>1,2</sup>, Gregory Waryasz<sup>1,3</sup>, Lorena Bejarano-  
5 Pineda<sup>1,3</sup>, John Kwon<sup>1,3</sup>, Soheil Ashkani-Esfahani<sup>1,2,3</sup>

6

7 **Affiliations**

8 1- Foot & Ankle Research and Innovation Lab (FARIL), Department of Orthopaedic Surgery,  
9 Massachusetts General Hospital, Harvard Medical School, Boston, MA

10 2- FARIL-SORG Collaborative, Department of Orthopaedic Surgery, Massachusetts General  
11 Hospital, Boston, MA

12 3- Foot and Ankle Center, Massachusetts General Hospital, Newton-Wellesley Hospital,  
13 Harvard Medical School, Boston, MA

14

15 **Corresponding Author:**

16 Vasundhara Mathur

17 **Address:** Foot & Ankle Research and Innovation Lab (FARIL), Department of Orthopaedic  
18 Surgery, Massachusetts General Hospital, Harvard Medical School, Boston, MA

19 **Email:** [vmathur1@mgh.harvard.edu](mailto:vmathur1@mgh.harvard.edu)

20

21 **Abstract**

22 **Background:** The gold standard for diagnosis of Lisfranc instability is direct visualization in  
23 the operation room while the examination techniques is still unstandardized and non-  
24 reproducible. We aimed to introduce a novel reproducible intraoperative mechanical testing  
25 method (Listract test) for intraoperative isolated Lisfranc instability assessment.

26 **Methods:** The Lisfranc ligament between the first cuneiform (C1) and second metatarsus  
27 (M2) in eight lower leg cadaveric specimens were dissected to replicate C1-M2 Lisfranc  
28 instability by eight foot and ankle surgeons. The 50N distraction force was applied in the  
29 direction of the C1-M2 ligament. Three methods of fixation - flexible fixation, metal screw,  
30 and bio-absorbable screw- were used to fix the injury, and Listract test was applied again  
31 after fixation. Besides intraoperative assessment, C1-M2 diastasis and area were measured  
32 using radiographs for assessment of Lisfranc instability.

33 **Results:** The sensitivity and specificity of the Listract test for detection of C1-M2 instability  
34 were 100% and 100% intraoperatively, 33.3% and 95.2% using radiographic diastasis  
35 measurement, and 63.2% and 38% using area measurement, respectively. The Listract test  
36 had a specificity and sensitivity of 100% and 96% for intraoperative assessment, 87.5% and  
37 64.3 for radiographic C1-M2 diastasis, and 48% and 50% for radiographic area.

38 **Conclusion:** The Listract test is a simple, reproducible, and replicable intraoperative method  
39 for evaluating the Lisfranc joint for instability. Developing a device with this mechanism can  
40 help clinicians confirm the diagnosis and provide appropriate treatment particularly for  
41 equivocal diagnoses.

42 **Keywords:** Lisfranc instability; biointegrative screws; tarsometatarsal injury, Lisfranc  
43 ligament

45 Authors' contributions:

46 SAE: Conception, design, and conducting the study, analysis, drafting the manuscript; VM,

47 DOH, SHSH, FR: conducting the study, analysis, preparing the manuscript draft; LBP, JK,

48 GW, PK: conducting the study, manuscript preparation, discussion.

49

50

51

## 52 **Introduction**

53 Injuries to the Lisfranc joint represent 0.2% of all fractures and have an annual incidence of  
54 1/55,000 individuals.<sup>1,2</sup> Ligamentous type of Lisfranc injuries is difficult to detect, with 20-  
55 40% of them remaining undetected or misdiagnosed at initial presentation.<sup>3</sup> In such cases,  
56 debilitating sequelae like midfoot instability, arch collapse, and traumatic arthritis are more  
57 likely to follow, thereby underlying the importance of timely diagnosis and treatment.<sup>4</sup>  
58 Surgical intervention is key to the preservation of the joint and to achieving anatomic  
59 reduction.<sup>5,6</sup> A high portion of instabilities caused by joint widening is observed between the  
60 first cuneiform and second metatarsal bones (C1-M2), and between the first and second  
61 cuneiform bones (C1-C2). Various types of metal and flexible fixations are used as fixation  
62 methods for Lisfranc instabilities.<sup>7,8</sup> While magnetic resonance imaging (MRI) and weight-  
63 bearing CT (WBCT) have shown high sensitivity and specificity for the detection of Lisfranc  
64 instability, radiographs, especially in weight-bearing status, are still the mainstay for primary  
65 assessment. Despite various imaging methods, intraoperative examination is the gold  
66 standard for confirmation of the diagnosis.<sup>9,10</sup> However, the intraoperative stress examination  
67 of the Lisfranc joint by applying a distraction force is not standardized and not a reproducible  
68 method.<sup>11</sup> Surgeons apply various amounts of force on the joint to confirm the diagnosis. This  
69 can lead to over or under-diagnosis of the instability. Aiming to introduce a more  
70 standardized and dynamic assessment method, a study suggested using Freer to apply stress  
71 on the joint. Authors in this study suggested that when the Freer elevator on the thin side  
72 could be twisted >90 degrees on the wide side, the Lisfranc joint could be considered  
73 unstable.<sup>12</sup> It is also assumed that the distracting forces applied to the joint should be in the  
74 direction of the forces that the actual ligaments bear in physiologic weight-bearing  
75 condition.<sup>13</sup>

76 In this study we aimed to introduce a standardized and reproducible intraoperative  
77 mechanical test for Lisfranc instability, particularly in isolated Lisfranc ligament injuries. Our  
78 hypothesis is that resembling a standard distracting force applied on the Lisfranc ligament in  
79 the physiologic weight-bearing position can result in a reproducible and more accurate  
80 evaluation method.

81

## 82 **Materials and Methods**

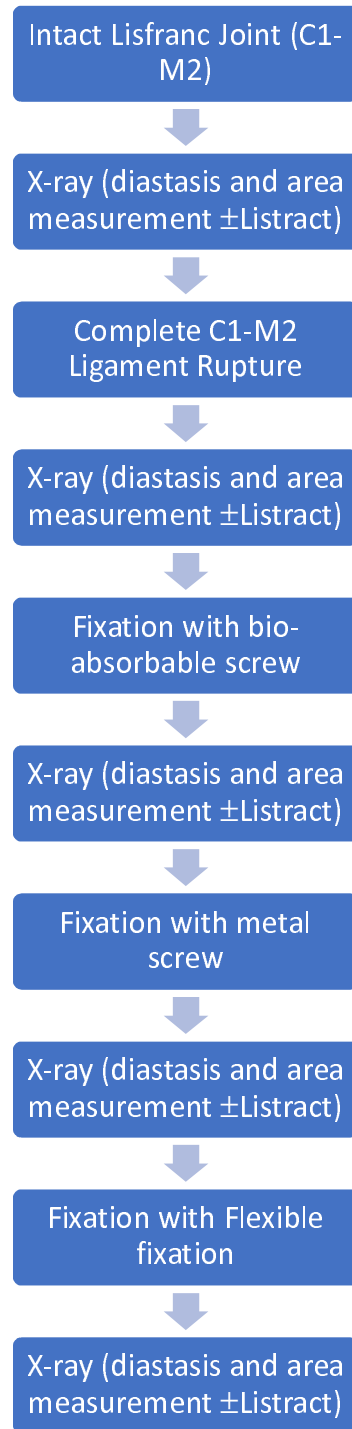
83 All experiments in this study were approved by the Institutional Research Board protocol  
84 (IRB #2016P001295). Fresh-frozen lower-leg cadaveric specimens amputated from the  
85 proximal tibia were completely thawed passively prior to conducting the experiment.  
86 Radiographic images were obtained in various stages including before injury (stable Lisfranc  
87 joint), after injury (unstable Lisfranc after C1-M2 ligament dissection), and after each  
88 fixation (Stabilized Lisfranc joint) with and without Listract test. The C1-M2 diastasis and  
89 area were measured on these images at each stage. **Figure 1** shows the stepwise process of the  
90 experiment. For induction of the instability, a complete dissection of the C1-M2 ligament was  
91 made from the dorsal to the plantar surface of the foot.

92 To apply the “Listract test” in the direction of the C1-M2 ligament, a K-wire was drilled  
93 through C1 from the dorsal to the plantar aspects of the foot at a 90° angle to the bone.  
94 Another K-wire was drilled through the base of M2 dorsal to plantar at a 90° angle to the  
95 bone. The positions of the K-wires were confirmed via radiographic images. These K-wires  
96 served as opposite pivot points to apply the distraction force between C1 and M2. Using a  
97 radiolucent wire that could tolerate a force of ~15 kg (33.1 lbs), the K-wires were pulled with  
98 a 50N (5 kg or 11.02 lbs). **Figure 2** shows the construction of the test using K-wires,  
99 radiolucent wires (fish wire), and pulleys to direct the forces from both opposite directions.

100 To select the amount of force needed to conduct the test, in a pilot study on 4 cadaver  
101 specimens prior to the main experiment, we used different distraction forces, including 25N  
102 (2.5 kg), 50N (5 kg), and 100N (10 kg). We considered 2 mm C1-M2 diastasis as the  
103 threshold for instability. The 25N forces from two directions were not sufficient to render 2  
104 mm diastasis in unstable Lisfranc joints while the 100N force, though led to >2 mm widening  
105 in all four specimens, were too heavy, making the test hard to use in practice and to keep the

106 feet steady while applying the forces. Thus, we selected 50N forces for the main experiment  
107 since it led to >2 mm widening in all the specimens and was also feasible to apply in practice.  
108 We applied the Listract test on the specimens in five stages (Figure 1), including 1) Intact  
109 Lisfranc ligament, 2) full resection of Lisfranc ligament leading to instability of the joint, and  
110 3) fixation with bioabsorbable radiolucent screws (OSSIO Inc., MA, USA), 4) fixation with  
111 single cortical metal screws (DePuy-Synthes, West Chester, PA), 5) fixation with single  
112 flexible fixation method (mini-Tightrope, Arthrex, Naples, FL, US). Radiographic images  
113 were obtained in ten stages, including a) intact Lisfranc ligament with and without applying  
114 the Listract test, b) dissected Lisfranc C1-M2 ligament  $\pm$  Listract test, c) bio-absorbable  
115 screw fixation  $\pm$  Listract test, d) metal screw fixation  $\pm$  Listract test, e) flexible fixation  $\pm$   
116 Listract test. Eight orthopaedic foot and ankle surgeons performed the experiment on separate  
117 cadavers. We could not perform direct measurement of the C1-M2 diastasis due to the  
118 presence of K-wires that barred the C1-M2 region. Three independent observers performed  
119 measurements on all radiographs. These three observers were unaware of the procedures and  
120 differences in the forces applied on the joint in each imaging stage. The measurements  
121 included C1-M2 diastasis and C1-M2 area on dorsiplantar radiographic images.

122

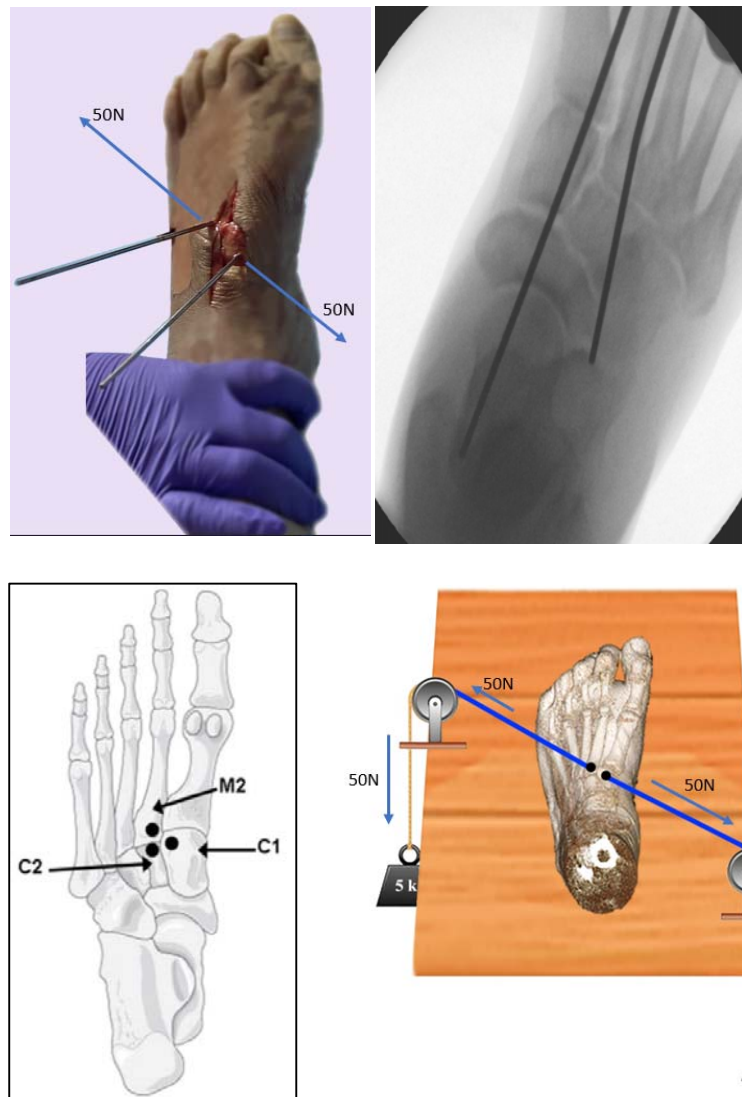


123

124 Figure 1. The stepwise process of the experiment assessing the use of the Lisfranc distraction  
125 test (Listract test) for detection of isolated Lisfranc ligament rupture leading to instability.



126



127 Figure 2. The Listract test; a mechanical distraction test exerted in alignment with the  
128 direction of the C1-M2 ligament to assess the stability of the joint. A schematic view of a  
129 cadaveric left foot subjected to the distraction forces applied using a pulley system.

130

### 131 *Statistical Analysis and Interobserver Reliability*

132 C1-M2 diastasis and area measurements were performed in each stage by three expert  
133 observers and reported as the mean and standard deviation (SD). Comparisons of the  
134 measurements in each stage on the radiographic images were performed using Mann-  
135 Whitney U test. Comparison of the measurements after the three fixation methods and the

136 measurements performed at the dissected ligament stage were compared using the Kruskal-  
137 Wallis test. P-value <0.05 was considered statistically significant. For these analyses, SPSS  
138 software (version 26.0, Armonk, NY, USA) was used for data analysis in this study. The three  
139 observers were asked to assess the joint instability intraoperatively before and after dissecting  
140 the C1-M2 ligament while they were blinded to the condition of the ligament. Their answers  
141 were recorded. Additionally, the sensitivity and specificity values for each intraoperative  
142 diagnosis and each measurement, diastasis, and area, in detecting Lisfranc instability with  
143 and without Listract test were calculated. The cut-off value for diastasis was considered  
144 3mm, and for area was 30mm<sup>2</sup>.<sup>14,15</sup> For diastasis and area measurements among the observers  
145 with and without the Listract test, we used the intraclass correlation coefficient (ICC). Values  
146 less than 50%, between 50% and 75%, between 75% and 90%, and greater than 90% were  
147 considered poor, moderate, good, and excellent , respectively.

148 **Results**

149 The mean and SD for all stages of measurements have been tabulated (Table 1). Applying  
150 Listract test to the unstable C1-M2, led to a significant difference between area with Listract  
151 compared to the area sans Listract test. Applying Listract test to C1-M2 after flexible fixation  
152 led to a significant difference in the diastasis before and after the test (Table 1). The  
153 measurements between the unstable C1-M2 and the measurements after all fixation methods  
154 were significantly different with and without the Listract test ( $P < 0.05$ ).

155 The ICC for C1-M2 instability diagnosis intraoperatively with Listract test was 0.97  
156 (95%CI=0.94-0.99). For the C1-M2 diastasis (0.64, 95%CI=0.53-0.73) and area (0.80,  
157 95%CI=0.72-0.86) measurements were moderate and good, respectively. The sensitivity and  
158 specificity for intraoperative Listract test were 0.96 and 1.00. The specificity and specificity  
159 for radiographic diastasis were 0.15 and 1.00 without Listract and 0.33 and 0.95 with Listract  
160 test, respectively. The specificity and specificity for area measurement were 0.63 and 0.38  
161 without Listract and 0.67 and 0.76 with Listract test, respectively.

162

163

**Table 1.** Diastases and areas of C1-M2 in cadaver specimens after each stage, including intact and dissected Lisfranc ligament, and after fixation with flexible, metal screw, and bio-absorbable fixations. Each measurement was conducted without and with the Listract test. Data are shown as mean (SD).

<i>Stage</i>	<i>Diastasis (mm)</i>	<i>Diastasis + Listract test</i>	<i>P-value<sup>†</sup></i>	<i>Area(mm<sup>2</sup>)</i>	<i>Area + Listract test</i>	<i>P-value<sup>†</sup></i>
<i>Stable C1-M2</i>	1.61 (0.27)	1.82 (0.57)	0.11	26.8 (6.21)	31.3 (11.06)	<b>&lt;0.001</b>
<i>Unstable C1-M2</i>	2.47 (0.51)	2.75 (0.52)	0.13	32.7 (13.08)	41.8 (14.32)	<b>0.002</b>
<i>P-value*</i>	<b>&lt;0.001*</b>	<b>&lt;0.001*</b>		<b>0.001*</b>	<b>0.001*</b>	
<i>Flexible fixation</i>	2.02 (0.50)	2.22 (0.24)	<b>0.03</b>	30.75 (7.42)	29.9 (6.8)	0.09
<i>P-value</i>	<b>0.01**</b>	<b>0.04**</b>		<b>0.03**</b>	<b>&lt;0.001**</b>	
<i>Metal Screw fixation</i>	1.72 (0.63)	1.61 (1.31)	0.40	30.75 (17.13)	31.8 (19.19)	0.08
<i>P-value</i>	<b>&lt;0.001**</b>	<b>&lt;0.001**</b>		<b>0.01**</b>	<b>0.01**</b>	
<i>Bio-absorbable screw fixation</i>	1.67 (0.77)	1.69 (0.64)	0.50	29.53 (9.15)	31.13 (9.75)	0.06
	<b>&lt;0.001**</b>	<b>&lt;0.001**</b>		<b>0.01**</b>	<b>0.003**</b>	

<sup>†</sup> Measurement with vs. without Listract test, Mann-Whitney U test; p-value<0.05 considered significant.

\* Measurements in intact vs. dissected Lisfranc ligament; Mann-Whitney U test.

\*\* Measurements in the fixation method vs. dissected Lisfranc ligament stage; Mann-Whitney U test.

164

165

166

167 **Discussion**

168 The purpose of this study was to introduce a standardized, reproducible, and reliable  
169 examination method for Lisfranc instability diagnosis. Despite various radiological methods  
170 introduced to detect Lisfranc instability, particularly for C1-M2 and C1-C2 instabilities, the  
171 intraoperative diagnosis remained the gold-standard method for confirmation. However, the  
172 methods used by most of the surgeons were not standardized, not based on a specific amount  
173 of force, and thus, not reproducible. Given diastasis and area measurement as two  
174 radiographic methods for the detection of C1-M2 instability, we found that Listract test can  
175 increase the specificity and sensitivity of these tests using pre-defined cut-off values. Listract  
176 test applies a specific amount of force (50N) on the joint in the direction of the ligaments.  
177 This helps the surgeon mimic the physiologic load on the joint intraoperatively and assess the  
178 joint in a condition closer to real-life conditions. Moreover, Listract test has led to greater  
179 values both for diastasis and area; however, only the area showed a significant difference  
180 when comparing measurements with versus without Listract measurements. Future studies  
181 can also focus on introducing an intraoperative cut-off value for the diastasis to increase.

182 All the fixation groups showed significant differences with the unstable group and values  
183 similar to the stable groups. This can indicate similar efficacy of all the fixation methods for  
184 Lisfranc instability including the novel bio-absorbable screws. While the Listract test  
185 produced a nearly perfect ICC (97%) and it showed to increase in the sensitivity and  
186 specificity of both radiographic diastasis and area measurements, the need to reassess the cut-  
187 off values for both of these radiographic measurements seems inevitable. The interobserver  
188 agreement was moderate and good for diastasis and area measurement, respectively;  
189 however, previous reports using 3D weight-bearing CT scans have shown an ICC of >0.96  
190 using 3D volume measurement for this non-invasive imaging method<sup>10,16-18</sup>. Bhimani et al.  
191 have shown that weight-bearing CT scan can detect Lisfranc instability in C1-M2 joint with a

192 sensitivity and specificity of 0.79 and 96.5 for diastasis and area, respectively.<sup>10</sup> They have  
193 also shown that 3D volume measurement can have a specificity and sensitivity of 0.98 and  
194 0.92, respectively. However, performing weight-bearing CT scan in patients who cannot  
195 tolerate the pain or in the operative room is not feasible. Kitsukawa et al. reported that  
196 diagnoses of Lisfranc injury on MRI in oblique plane parallel to the ligament with isotropic  
197 3D MRI reliably matched with direct intraoperative observations.<sup>9</sup> However, MRO is not a  
198 dynamic and weight-bearing imaging modality to show functional instability. Another study  
199 by Naguib et al, concluded that the accuracy of surgeons' eye tracking assessment of  
200 intraoperative fluoroscopic imaging during stress examination of the tarsometatarsal joint  
201 complex in the diagnosis of Lisfranc injuries was reliable.<sup>11</sup> The Freer elevator test developed  
202 by Young et al. has shown promise as a reliable method of intra-operative evaluation of the  
203 injured Lisfranc ligament but is limited by possible iatrogenic injury due to the twisting  
204 motion and lack of data on its accuracy.<sup>12</sup> None of these intraoperative methods were either  
205 standardized or made reproducible. Our study demonstrated a standardized method using a  
206 specific amount of force in a specific direction that can be fundamental in developing devices  
207 for intraoperative assessment of the Lisfranc joint, particularly C1-M2 and even C1-C2 as the  
208 next step.

209 A limitation of our study was that we only assessed C1-M2 joint and did not include C1-C2  
210 and other tarsometatarsal joints. Moreover, we did not conduct intraoperative measurement and  
211 the C1-M2 diastasis to compare with the radiographic measurement. Lastly, the number of  
212 our cadavers, though it was based previous studies, was limited, which can lead to reducing  
213 the validity and reliability of our measurements while will not affect the purpose of the study.  
214 A strong point of our study was the use of different fixation methods that are available in  
215 practice, as a means to test our method in different fixation techniques.

## 216 **Conclusion**

217 The Listract test is a standardized and reproducible intraoperative examination technique that  
218 applies 50N distraction forces in the direction of the C1-M2 ligament. This can help the  
219 surgeon assess the joint in a simulated real-life situation under a specific force for distaction  
220 and, thus, instability. Future studies with larger cadaver populations to establish cut-off  
221 values for both radiographic measurement and intraoperative measurement under Listract test  
222 are necessary. In order to use this method intraoperatively, we aimed to design a device that  
223 can measure the amount of distraction force, apply 50N, and also measure the amount of  
224 diastasis by the surgeon efficiently.

#### 225 **Acknowledgement**

226 This study was logistically and financially sponsored by FARIL-MGH Center, Ossio Inc.,  
227 and Depuy Synthes, who helped us provide the instruments and conduct the experiment.

#### 228 **Conflict of Interest**

229 None of the sponsoring companies have participated, interfered, or were aware of the  
230 outcomes of the study until the manuscript was publicly published. None of the authors has  
231 any conflict of interest with the sponsoring companies.

232

233 **References**

- 234 1. English TA. DISLOCATIONS OF THE METATARSAL BONE AND ADJACENT  
235 TOE. *J Bone Joint Surg Br.* 1964;46:700-704.
- 236 2. Alberta FG, Aronow MS, Barrero M, Diaz-Doran V, Sullivan RJ, Adams DJ.  
237 Ligamentous Lisfranc joint injuries: a biomechanical comparison of dorsal plate and  
238 transarticular screw fixation. *Foot Ankle Int.* 2005;26(6):462-473.  
239 doi:10.1177/107110070502600607
- 240 3. Renninger CH, Cochran G, Tompane T, Bellamy J, Kuhn K. Injury Characteristics of  
241 Low-Energy Lisfranc Injuries Compared With High-Energy Injuries. *Foot Ankle Int.*  
242 2017;38(9):964-969. doi:10.1177/1071100717709575
- 243 4. Philbin T, Rosenberg G, Sferra JJ. Complications of missed or untreated Lisfranc  
244 injuries. *Foot Ankle Clin.* 2003;8(1):61-71. doi:10.1016/s1083-7515(03)00003-2
- 245 5. Cassebaum WH. Lisfranc fracture-dislocations. *Clin Orthop.* 1963;30:116-129.
- 246 6. Desmond EA, Chou LB. Current concepts review: Lisfranc injuries. *Foot Ankle Int.*  
247 2006;27(8):653-660. doi:10.1177/107110070602700819
- 248 7. Moracia-Ochagavía I, Rodríguez-Merchán EC. Lisfranc fracture-dislocations: current  
249 management. *EFORT Open Rev.* 2019;4(7):430-444. doi:10.1302/2058-5241.4.180076
- 250 8. Raikin SM, Elias I, Dheer S, Besser MP, Morrison WB, Zoga AC. Prediction of midfoot  
251 instability in the subtle Lisfranc injury. Comparison of magnetic resonance imaging with  
252 intraoperative findings. *J Bone Joint Surg Am.* 2009;91(4):892-899.  
253 doi:10.2106/JBJS.H.01075
- 254 9. Kitsukawa K, Hirano T, Niki H, Tachizawa N, Mimura H. The Diagnostic Accuracy of  
255 MRI to Evaluate Acute Lisfranc Joint Injuries: Comparison With Direct Operative  
256 Observations. *Foot Ankle Orthop.* 2022;7(1):24730114211069080.  
257 doi:10.1177/24730114211069080
- 258 10. Bhimani R, Sornsakrin P, Ashkani-Esfahani S, et al. Using area and volume measurement  
259 via weightbearing CT to detect Lisfranc instability. *J Orthop Res Off Publ Orthop Res*  
260 *Soc.* 2021;39(11):2497-2505. doi:10.1002/jor.24970
- 261 11. Naguib S, Meyr AJ. Reliability, Surgeon Preferences, and Eye-Tracking Assessment of  
262 the Stress Examination of the Tarsometatarsal (Lisfranc) Joint Complex. *J Foot Ankle*  
263 *Surg Off Publ Am Coll Foot Ankle Surg.* 2019;58(1):93-96.  
264 doi:10.1053/j.jfas.2018.08.015
- 265 12. Young K, Lee H. Freer Test for an Intraoperative Evaluation of a Lisfranc Joint Injury: A  
266 Technical Report. *J Korean Foot Ankle Soc.* 2020;24(4):165-167.
- 267 13. Mascio A, Greco T, Maccauro G, Perisano C. Lisfranc complex injuries management and  
268 treatment: current knowledge. *Int J Physiol Pathophysiol Pharmacol.* 2022;14(3):161-  
269 170.



- 270 14. Sripanich Y, Weinberg MW, Krähenbühl N, et al. Imaging in Lisfranc injury: a  
271 systematic literature review. *Skeletal Radiol.* 2020;49(1):31-53. doi:10.1007/s00256-019-  
272 03282-1
- 273 15. Rikken QGH, Hagemeyer NC, De Bruijn J, et al. Novel values in the radiographic  
274 diagnosis of ligamentous Lisfranc injuries. *Injury.* 2022;53(6):2326-2332.  
275 doi:10.1016/j.injury.2022.02.044
- 276 16. Macmahon PJ, Dheer S, Raikin SM, et al. MRI of injuries to the first interosseous  
277 cuneometatarsal (Lisfranc) ligament. *Skeletal Radiol.* 2009;38(3):255-260.  
278 doi:10.1007/s00256-008-0613-6
- 279 17. Potter HG, Deland JT, Gusmer PB, Carson E, Warren RF. Magnetic Resonance Imaging  
280 of the Lisfranc Ligament of the Foot. *Foot Ankle Int.* 1998;19(7):438-446.  
281 doi:10.1177/107110079801900704
- 282 18. Lu J, Ebraheim NA, Skie M, Porshinsky B, Yeasting RA. Radiographic and computed  
283 tomographic evaluation of Lisfranc dislocation: a cadaver study. *Foot Ankle Int.*  
284 1997;18(6):351-355. doi:10.1177/107110079701800608
- 285