

Targeting of Th17-related cytokines in patients with Darier Disease

Monika Ettinger¹, Teresa Burner², Isabella Pospischil¹, Judith Traxler¹, Gerald Wahl¹, Sabine Altrichter^{1,2}, Angelika Lackner², Iris K. Gratz³, Susanne Kimeswenger^{2*}, Emmanuella Guenova^{4,5*}, Wolfram Hoetzenecker^{1,2*}

Affiliations:

¹ Department of Dermatology and Venerology, Kepler University Hospital Linz, Linz, Austria

² Department of Dermatology and Venerology, Medical Faculty, Johannes Kepler University Linz, Linz, Austria

³ Department of Biosciences and Molecular Biology, University of Salzburg, Salzburg, Austria

⁴ Department of Dermatology, University of Lausanne and Faculty of Biology and Medicine, University of Lausanne, Lausanne, Switzerland

⁵ Department of Dermatology, Hospital 12 de octubre, Medical school, University Complutense, Madrid, Spain

*authors contributed equally

Corresponding author: Wolfram Hoetzenecker MD, PhD, Krankenhausstr. 9, 4020 Linz, Austria, phone +43 (0)5 7680 83 – 4101;

wolfram.hoetzenecker@kepleruniklinikum.at

Abstract

Darier disease (DD) is a rare, inherited multi-organ disorder associated with mutations in the ATP2A2 gene. In DD patients, the skin is frequently affected, characterized by malodorous, inflamed skin and recurrent, severe infections. Therapeutic options are limited and inadequate for the long-term management of this chronic disease. Using immunoprofiling with NanoString technology, qPCR and immunohistochemistry, we demonstrate enhanced expression of Th-17-related genes and cytokines in six DD patients. We prove that targeting the IL-23/17 axis in DD with monoclonal antibodies is an effective and safe therapy in DD patients, leading to significant clinical improvement. As DD is a chronic, relapsing disease, our findings provide new options for the long-term management of skin inflammation in patients with DD.

NOTE: This preprint reports new research that has not been certified by peer review and should not be used to guide clinical practice.

Introduction

Darier Disease (DD) or dyskeratosis follicularis is a rare autosomal dominant inherited disorder (prevalence: 1-3:100.000) defined by heterozygous mutations in the ATP2A2 gene encoding the sarcoendoplasmic reticulum Ca²⁺ ATPase isoform 2 (SERCA2). (Sakuntabhai et al. 1999) In addition to an increased risk of neuropsychiatric disorders, type 1 diabetes, and heart failure, the skin is the most commonly affected organ in DD patients. (Bachar-Wikstrom et al. 2020; Bachar-Wikström and Wikström 2021; Cederlöf et al. 2015, 2019; Curman et al. 2021; Dodiuk-Gad et al. 2013, 2016) DD manifests as cutaneous keratotic papules and malodorous plaques, often affecting large areas of the body and significantly affecting patients' quality of life. (Rogner et al. 2021) The disease has a late onset, often around puberty, and a chronic course with exacerbations triggered by sun exposure, heat, friction, or infection, often requiring hospitalization with intravenous treatment. (Bachar-Wikström and Wikström 2021) Therapeutic options are limited and inadequate for the long-term management of this chronic disease with recurrent severe bacterial and viral infections of the skin². (Hanna et al. 2022; Rogner et al. 2021) Conventional treatment still relies on the short-term use of topical corticosteroids, antiseptics and systemic antibiotics. Currently, the most effective treatment is systemic retinoids, but their use is limited by side effects. (Dicken et al. 1982; Hanna et al. 2022) Despite the identification of the underlying genetic mutation in ATP2A2 (Sakuntabhai et al. 1999), the exact molecular mechanism of the characteristic cutaneous phenotype is poorly understood. (Savignac et al. 2011) Interestingly, a recent report has linked mutations in the ATP2A2 gene to impaired V(D)J recombination and B cell maturation. (Chen et al. 2021) Because chronic inflammation of the skin is common and deleterious in DD, we hypothesized that the involvement of the skin's immune system is critical in the pathogenesis of DD and aimed to characterize the cellular and molecular composition of the cutaneous immune infiltrate in DD skin lesions.

Results

We included six patients with DD in our cohort. DD was verified by histology of skin biopsies and genetic analyses. The characteristics and previous therapies of the patients (3 males, 3 females; age range 21-58 years) are summarized in Table 1. The patients had skin manifestations since adulthood, ranging from moderate (PAT4) to severe (PAT1, 2, 5, 7, 9) forms of disease with recurrent bacterial and viral cutaneous infections, some of which required hospitalization (Suppl Fig. 1). All patients had been previously treated with various drugs that provided no or only short-term clinical benefit (Table 1).

Table 1: Darier Disease patient characteristics and treatments

Patient age*/sex	Heterogenous ATP2A2 mutation	Phenotype/ disease severity**	Complications	Prior therapies	Increased cytokine***	Current therapy
PAT1/26-30/f	c.215 C > A, (p.Ser72Tyr)	Suppl. severe Fig 1/	recurrent bacterial cutaneous superinfections	topical steroids, antiseptics, systemic therapy with isotretinoin 06/18-02/19 (no beneficial effect)	IL23A	systemic therapy with guselkumab for 13 months
PAT2/41-45/m	c.1184T>G, (p.Val395Gly)	Suppl. severe Fig 1/	recurrent bacterial cutaneous superinfections	topical steroids, antiseptics, systemic therapy with acitretin 08-09/2017, 04/21-09/21 (no benefit), CO ₂ laser on legs (temporary benefit)	IL17A	systemic therapy with secukinumab for twelve months
PAT4/46-50/m	c.2305G> A (p.Gly769Arg)	Suppl. moderate Fig 1/	recurrent HSV infections and bacterial cutaneous infections	topical steroids, antiseptics, systemic therapy with acitretin 12/18-07/19 (no benefit), CO ₂ laser on legs (temporary benefit)	IL17A	topical steroids, antiseptics
PAT5/21-25/f	c.392G>A p.(Arg131Gln)	Suppl. severe Fig 1/	recurrent bacterial cutaneous superinfections	no topical or systemic therapy	IL17A	loss of follow up
PAT7/56-60/m	c.224delT p.(Leu75Trpfs*15)	Suppl. severe Fig 1/	recurrent bacterial cutaneous superinfections	topical steroids, antiseptics	IL17A	systemic therapy with acitretin since for four months
PAT9/45-50/f	c.1287+1delG splice mutation	Suppl. severe Fig 1/	recurrent bacterial cutaneous superinfections depression	topical steroids, antiseptics, systemic therapy with isotretinoin 2008-09/22 (temporary benefit)	IL17A	systemic therapy with secukinumab for two months

* age in 5-year ranges

** No standardized assessment scale has been validated to date for DD. The disease was considered severe if the patient had a body surface area (BSA) > 35%, moderate if BSA was 10%-35%.

*** Cytokine that has been shown to be increased in the patient's lesional skin.

Using NanoString technology, we performed high-throughput immunoprofiling (Fig. 1A) of the genes expressed in lesional skin of the six DD patients. Gene set enrichment analysis (GSEA) of the gene expression data revealed that IL-17-signaling was enhanced in the skin of DD patients compared with the skin of healthy controls (HC) (Fig. 1B, Suppl Table 1). Interestingly, the expression profile resembled that of patients with psoriasis, which is known to be a Th17 driven disease (Fig. 1A, Suppl Table 2). (Lowes et al. 2008) Based on these results, we examined Th17-, Th1-, and Th2-related cytokines in DD patients by qRT-PCR and found significantly increased IL17A expression compared to HC skin (Fig. 1C, Suppl Fig. 2). Specifically, five of six DD patients showed increased expression of IL17A and one patient displayed increased expression of IL23A (Suppl Fig. 2, Table 1). Overexpression of Th17-related cytokines was confirmed at the protein level in immunofluorescence staining of skin sections (Fig. 1D and Suppl Fig. 3).

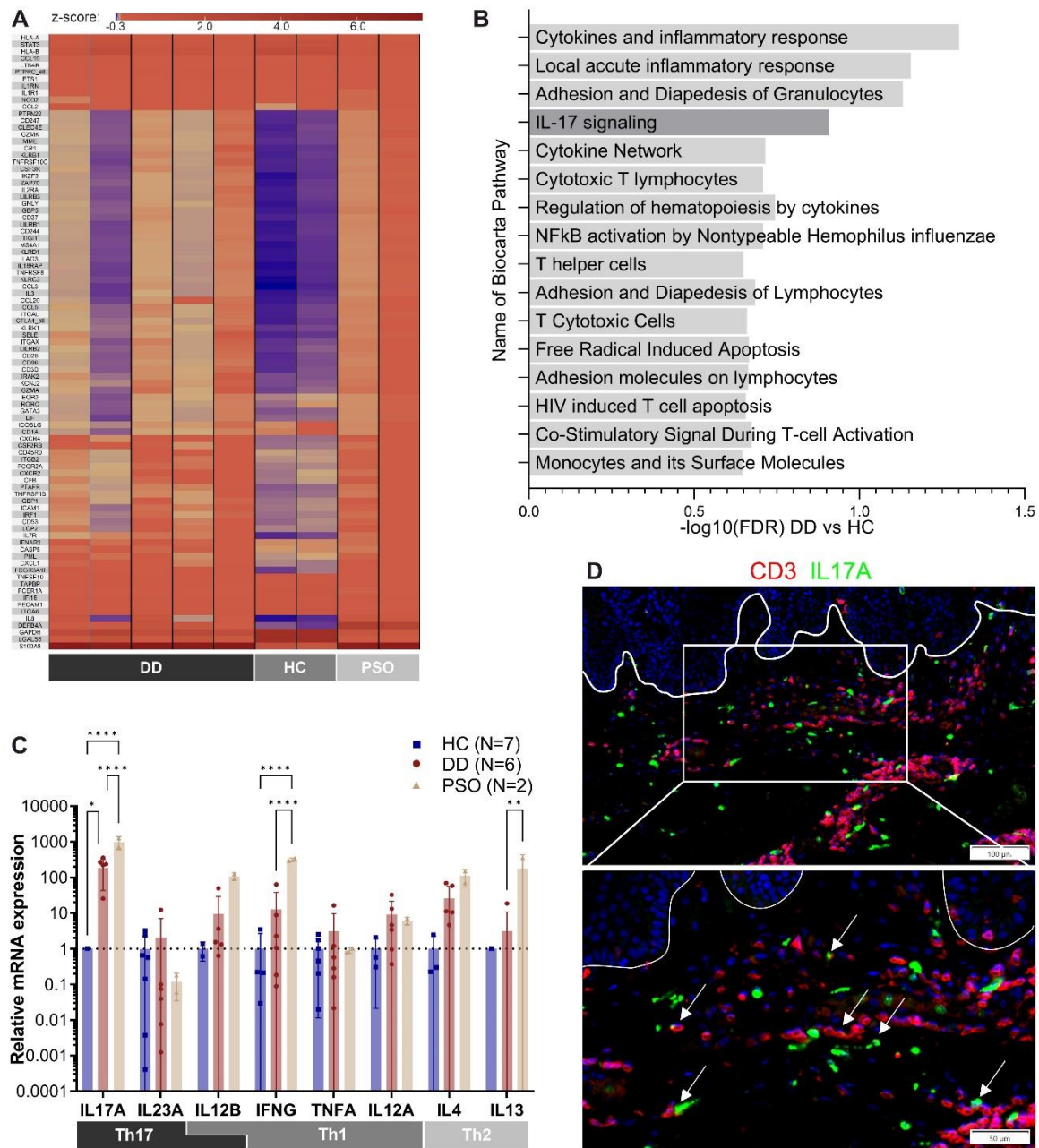


Fig 1: Enhanced expression of Th-17-related genes and cytokines in the skin of patients with Darier disease (DD)

A: Heat map of differentially expressed (DE) genes expressed as Z-score (DD vs HC, fold change > 1.5, p-value (t-test) < 0.05) as determined by NanoString nCounter analysis using the Immunology_V2 panel in skin of untreated DD patients (DD, N=5), healthy controls (HC, N=2) and Psoriasis patients (PSO, N=2).

B: Biocarta pathways enriched in DD patients as compared to HC, as determined by NanoString nCounter and Gene Set Enrichment Analysis. Pathways are ordered according to their normalized enrichment scores. Bars represent $-\log_{10}$ of False Discovery Rates (FDR) (See Suppl Table 2 for complete table).

C: Relative mRNA expression (qRT-PCR) of Th1, Th2 and Th17-associated cytokines normalized to housekeeping gene ACTB and relative to HC. Bars represent means, error bars represent standard deviations. * p<0.05, ** p<0.005, **** p<0.00005 (2-way ANOVA with Turkey's post hoc test).

D: Representative immunofluorescence images of IL17A and CD3 staining in DD patient skin (PAT9). CD3 positive T cells are marked in red, IL17A positive cells are marked in green, DAPI-stained nuclei are marked in blue. The upper panel shows 10x magnification of the double staining. The lower panel shows the double staining of inset (20x magnification). White arrows indicate double positive cells in the 20x magnified image.

Because our results indicated an enhanced IL-23/-17 axis in inflamed DD skin, we took a precision medicine approach and administered monoclonal antibodies targeting the overexpressed cytokine to the treatment-refractory patients. Specifically, we treated PAT1 with an IL23A blocking antibody (guselkumab) and PAT2 with an IL17A blocking antibody (secukinumab). In both patients, we observed a rapid decrease in skin inflammation, followed by a reduction and flattening of hyperkeratotic papules and plaques, especially in the most severely affected areas of the body (i.e., the thorax; Fig. 2A, Suppl Fig. 4). Most importantly, the reduction in skin inflammation resulted in a marked decrease in odor and bacterial and viral superinfections of the skin. The treatment is well tolerated and has been used in both patients (PAT1, 2) for almost a year. Interestingly, three months after treatment initiation in PAT1 and PAT2, improvement in clinical symptoms was accompanied by normalization of the inflammatory gene expression profile (NanoString and qRT-PCR; Fig. 2B-C) in the patients' skin. In detail, antibody therapy specifically suppressed Th17 associated cytokines (IL23A in PAT1, IL17A in PAT2) in skin samples, which correlated with a normalization and/or increased expression of Th1 and Th2 cytokines compared to HC (Fig. 2C). Based on our observation in PAT1 and PAT 2 we recently introduced treatment with secukinumab (targeting IL17A) in a third DD patient (PAT9). One month after therapy initiation, we already observed less skin inflammation and flattened plaques on thorax and legs suggesting early clinical improvement (Suppl Fig. 5).

Discussion

In our patient cohort, we demonstrated for the first-time increased expression of Th-17-related genes in the skin of DD patients. Based on our observation, we targeted the IL-23/-17 axis in patients, resulting in an effective and safe therapy.

Treatment of genodermatoses in general is challenging. (Morren et al. 2022) Because of the small patient population, it is almost impossible to conduct clinical trials and thus get drugs approved. There is a very limited number of effective treatments for DD, and there are no randomized, placebo-controlled trials. (Rogner et al. 2021) Recent studies have shown that mutations in the ATP2A2 gene lead to impaired calcium homeostasis in keratinocytes and decreased cell-cell adhesion in the epidermis. (Bachar-Wikström and Wikström 2021) This mechanism is thought to lead to the characteristic skin phenotype of DD with hyperkeratotic papules and plaques and provides further rationale for the use of keratolytic retinoids in the long-term management of patients. Indeed, systemic retinoids (e.g. isotretinoin) are effective in DD patients but are often discontinued due to side effects and the persistence of skin inflammation with recurrent infections. (Dicken et al. 1982)

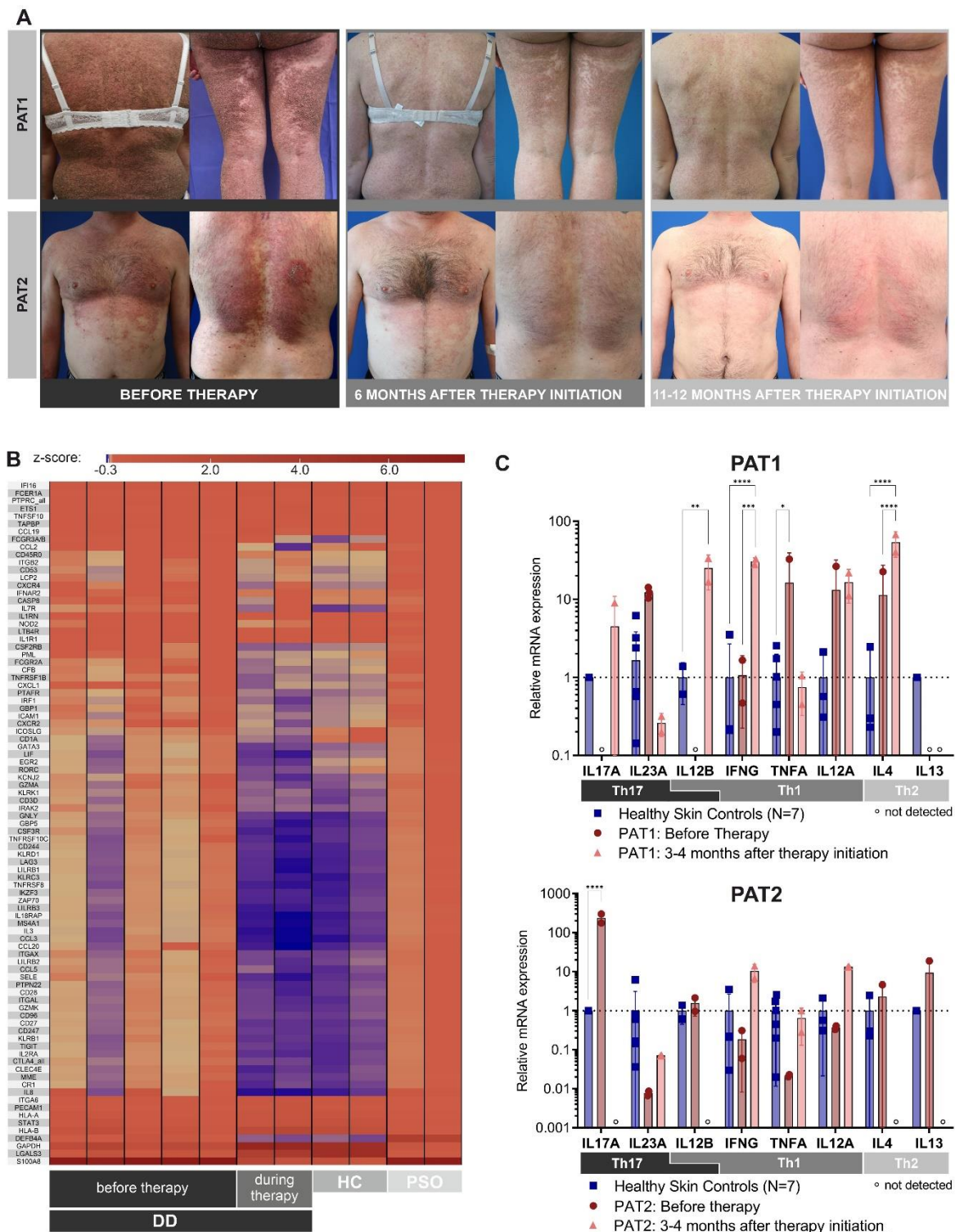


Fig 2: Targeting the IL-23/IL-17 axis with monoclonal antibodies is effective in patients with Darier disease

A: Cutaneous improvement after personalized targeted antibody therapy. Clinical images of guselkumab (upper, PAT1) and secukinumab (lower, PAT2) treated patients before, 6 and 11-12 months after initiation of antibody therapy.

B: Normalization of gene expression during therapy of differentially regulated genes (DD vs HC) in DD patients, as determined by NanoString® nCounter analysis using the Immunology_V2 panel.

C: Relative mRNA expression (qRT-PCR) of Th1, Th2 and Th17-associated cytokines normalized to housekeeping gene ACTB and relative to HC for PAT1 (upper panel) and PAT2 (lower panel). Bars represent means, error bars represent standard deviations. * $p < 0.05$, ** $p < 0.005$, *** $p < 0.0001$, **** $p < 0.00005$ (2-way ANOVA with Turkey's post hoc test).

A hallmark of DD is chronic inflammation of the skin, which is common and deleterious in most patients. Interestingly, reports on the role of the immune system in the pathogenesis and progression of DD are rare. To date, skin inflammation in DD patients has mainly been considered an indirect, secondary effect of impaired epidermal barrier function and/or dysbiosis of the cutaneous microbiome in DD patients. In a recent report by Chen et al., mutations in the ATP2A2 gene were for the first time directly associated with impaired immune system function, particularly the B-cell compartment. (Chen et al. 2021) The authors showed that SERCA2, encoded by the ATP2A2 gene, is required for V(D)J recombination and subsequent B cell maturation. Interestingly, some DD patients have reduced numbers of mature B cells in the blood. (Chen et al. 2021) In our study, we observed increased expression of Th-17-related genes in the skin of DD patients. On the one hand, Th17 dominance in the skin of patients could be a direct effect of ATP2A2 gene mutations in immune cells that drives Th17 skewing of naïve T cells. Interestingly, in preliminary experiments, we observed altered Ca²⁺ signaling in T cells from DD patients compared with healthy controls (data not shown). On the other hand, impaired epidermal homeostasis and an altered microbiome might be indirectly responsible for increased expression of Th17-related genes in the skin of DD patients.

In summary, we demonstrated for the first time increased expression of Th-17-related genes in DD. We prove that targeting the IL-23/-17 axis in DD is an effective and safe therapy in three DD patients. Because DD is a chronic, relapsing disease complicated by recurrent bacterial and viral skin infections, our results provide new options for the long-term management of skin inflammation in patients with DD. Further studies are needed to evaluate the long-term benefits and side effects of this treatment modality and to clarify the mechanism of IL-17 signaling in DD patients.

Methods

Patients

Skin samples (3 to 6 mm biopsy specimens) and blood samples for collection of PBMCs were obtained from patients with Darier Disease (DD) (before initiation of therapy and at specific time points during therapy), healthy controls (undergoing cosmetic surgery), and psoriasis patients (PSO) as positive controls. Written informed consent was obtained from patients and controls. The study was approved by the ethics committee of the Medical Faculty of Johannes Kepler Universität Linz (EK Nr: 1327/2021, 1036/2020 and 1071 /2021). The study was registered at ClinicalTrials.gov, Identifier: NCT05680974. The patient identifiers (PAT1-PAT9) cannot be traced back to individual patients and are not known by anybody outside the research group.

Three patients (PAT1, PAT2 and PAT9) were treated with secukinumab (targeting IL17A, PAT2 and PAT9) or guselkumab (targeting IL23A, PAT1). PAT1 received guselkumab 100 mg subcutaneously at weeks 0 and 4, followed by injections every 8 weeks, and PAT2 received secukinumab 300 mg subcutaneously once a week for 5 weeks, followed by monthly administrations. PAT9 received secukinumab 300 mg subcutaneously once a week for 5 weeks, so far.

Molecular genetic analysis

Exome Sequencing. Using Twist comprehensive Exome and Mitochondrial Panel (Twist Bioscience) sequencing on NextSeq2000 (Illumina) as “paired and end reads”.

Gene expression profiling

RNA extraction. 3-mm biopsies of patients’ lesional skin and controls’ normal skin were kept at -80 °C in RNAlater® (Invitrogen). After thawing, biopsies were mechanically disrupted using a TissueLyser II and 5-mm Stainless Steel Beads (Qiagen). RNA was isolated using Monarch Total Miniprep Kit (New England Biolabs) according to the manufacturer’s protocol.

Nanostring. For multiplex gene expression profiling of the mRNA, the Nanostring® nCounter System was used together with their immunology panel NS_Immunology_v2_C2328 and the nCounter SPRINT Profiler was used. Positive control was mRNA from skin lesions of two psoriasis patients. Data was analyzed using nSolver 4.0, R and Gene Set Enrichment Analysis (GSEA). (R_Core_Team 2022; Subramanian, Tamayo, Vamsi K. Mootha, et al. 2005) Unfortunately, quality control for PAT2 failed and this patient was excluded from the analysis. Data was normalized by using all housekeeping genes from the panel with an average count higher than 100 and with less than 35 % coefficient of variance. The list of differentially regulated genes was generated by comparing the expression of all genes between DD and HC samples. Cut-off for fold change was 1.5 and for p-value 0.05 (Student’s t test). Heatmaps were created with the R superheat package. (Barter et al. 2018; R_Core_Team 2022) Data from each gene was scaled to mean 0 and standard deviation 1 (z-score).

GSEA analysis. The enrichment score (weighted Kolmogorov-Smirnov-like statistic) tells the degree to which a gene set is overrepresented at the extremes of the ranked list of compared groups (i.e. DD vs HC in Suppl Table 2 and PSO vs HC in Suppl Table 3), normalized enrichment score (NES) accounts for different gene set sizes and correlations between the expression data set and the gene sets. We analyzed the list of gene set ‘Biocarta Pathways’ (c2.cp.biocarta.v2022.1.Hs.symbols.gmt [Curated]). We took a closer look at all gene sets with false discovery rates (FDR) lower than 0.25. (Subramanian, Tamayo, Vamsi K Mootha, et al. 2005)

Reverse Transcriptase qPCR. cDNA Synthesis Kit (Biozym) was used for cDNA synthesis according to the manufacturer’s instructions. qRT-PCR was conducted on a LightCycler® 450,

using DNA Master Fast Star HybProbe (Roche) and Taqman® Gene Expression Assay (FAM) for IL4 (Hs00174122_m1), IL12A (Hs01073447_m1), IL12B (Hs01011518_m1), IL13 (Hs00174379_m1), IL17A (Hs00174383_m1), IL23A (Hs00372324_m1), TNFA (Hs00174128_m1) und INFG (Hs00989291_m1) (Thermo Fisher Scientific).

Protein expression profiling

Immunofluorescence. Immunofluorescence was performed on formalin-fixed, paraffin-embedded lesional patient skin and normal control skin. After deparaffinization of the slides, Antigen Retrieval was performed in boiling hot citrate buffer (pH 6.0) for ten minutes. Slides were blocked, followed by overnight incubation of the 1:500 diluted IL-23 p19 Rabbit anti-Human Antibody (PA520239, Invitrogen), 1:200 diluted IL-17 Polyclonal Antibody (bs-2140R, Bioss) and 1:50 diluted Anti-Human CD3 Monoclonal Antibody (MA5-12577, Invitrogen). Antibodies Goat anti-Rabbit IgG (H+L) Cross-Adsorbed Secondary Antibody, AF 488 (A-11070, Thermo Fisher Scientific) and Donkey anti-Mouse IgG (H+L) Highly Cross-Adsorbed Secondary Antibody, AF 647 (A-31571, Invitrogen) were utilized as secondary antibodies. Slides were covered using Antifade/DAPI covering media and scanned with Histo Scanner VS200 v4 (Olympus).

References

- Bachar-Wikstrom, Etty, Philip Curman, Tara Ahanian, Ivone U. S. Leong, Henrik Larsson, Martin Cederlöf, and Jakob D. Wikstrom. 2020. "Darier Disease Is Associated with Heart Failure: A Cross-Sectional Case-Control and Population Based Study." *Scientific Reports* 10(1):1–8. doi: 10.1038/s41598-020-63832-9.
- Bachar-Wikström, Etty, and Jakob D. Wikström. 2021. "Darier Disease – a Multi-Organ Condition?" *Acta Dermato-Venereologica* 101(4). doi: 10.2340/00015555-3770.
- Barter, Rebecca L., Bin Yu, Rebecca L. Barter, and Bin Yu. 2018. "Superheat : An R Package for Creating Beautiful and Extendable Heatmaps for Visualizing Complex Data Superheat : An R Package for Creating Beautiful and Extendable Heatmaps for Visualizing Complex Data." 8600. doi: 10.1080/10618600.2018.1473780.
- Cederlöf, M., R. Karlsson, H. Larsson, C. Almqvist, P. K. E. Magnusson, K. Nordlind, M. Landén, and P. Lichtenstein. 2015. "Intellectual Disability and Cognitive Ability in Darier Disease: Swedish Nation-Wide Study." *British Journal of Dermatology* 173(1):155–58. doi: 10.1111/bjd.13740.
- Cederlöf, Martin, Philip Curman, Tara Ahanian, Ivone U. S. Leong, Kerstin Brismar, Etty Bachar-Wikstrom, and Jakob D. Wikstrom. 2019. "Darier Disease Is Associated with Type 1 Diabetes: Findings from a Population-Based Cohort Study." *Journal of the American Academy of Dermatology* 81(6):1425–26. doi: 10.1016/j.jaad.2019.05.087.

- Chen, Chun-chin, Bo-ruei Chen, Yinan Wang, Philip Curman, Helen A. Beilinson, Ryan M. Brecht, Catherine C. Liu, Ryan J. Farrell, Jaime De Juan-sanz, Louis-marie Charbonnier, Shingo Kajimura, Timothy A. Ryan, and David G. Schatz. 2021. "Sarco/Endoplasmic Reticulum Ca²⁺-ATPase (SERCA) Activity Is Required for V(D)J Recombination." 218(8).
- Curman, Philip, Johanna Bern, Linnea Sand, Martin Cederlöf, Ety Bachar-Wikström, and Jakob D. Wikström. 2021. "Patients with Darier Disease Exhibit Cognitive Impairment While Patients with Hailey-Hailey Disease Do Not: An Experimental, Matched Case-Control Study." *Acta Dermato-Venereologica* 101(6):1–6. doi: 10.2340/00015555-3818.
- Dicken, Charles H., Eugene A. Bauer, Paul G. Hazen, Gerald G. Krueger, James G. Marks, Joseph S. McGuire, and Lawrence A. Schachner. 1982. "Isotretinoin Treatment of Darier's Disease." *Journal of the American Academy of Dermatology* 6(4):721–26. doi: 10.1016/S0190-9622(82)80052-2.
- Dodiuk-Gad, R., E. Cohen-Barak, M. Ziv, A. Shani-Adir, S. Shalev, B. Chazan, R. Raz, R. Colodner, B. Amichai, A. Zlotogorski, Y. Keness, and D. Rozenman. 2013. "Bacteriological Aspects of Darier's Disease." *Journal of the European Academy of Dermatology and Venereology* 27(11):1405–9. doi: 10.1111/jdv.12025.
- Dodiuk-Gad, R. P., E. Cohen-Barak, M. Khayat, H. Milo, L. Amariglio-Diskin, N. Danial-Faran, M. Sah, M. Ziv, A. Shani-Adir, B. Amichai, A. Zlotogorski, Z. Borochowitz, D. Rozenman, and Stavit Shalev. 2016. "Darier Disease in Israel: Combined Evaluation of Genetic and Neuropsychiatric Aspects." *British Journal of Dermatology* 174(3):562–68. doi: 10.1111/bjd.14220.
- Hanna, Nardin, Megan Lam, Patrick Fleming, and Charles W. Lynde. 2022. "Therapeutic Options for the Treatment of Darier's Disease: A Comprehensive Review of the Literature." *Journal of Cutaneous Medicine and Surgery* 26(3):280–90. doi: 10.1177/12034754211058405.
- Lowes, Michelle A., Toyoko Kikuchi, Judilyn Fuentes-duculan, Irma Cardinale, Lisa C. Zaba, Asifa S. Haider, Edward P. Bowman, and James G. Krueger. 2008. "Psoriasis Vulgaris Lesions Contain Discrete Populations of Th1 and Th17 T Cells." *Journal of Investigative Dermatology* 128(5):1207–11. doi: 10.1038/sj.jid.5701213.
- Morren, Marie Anne, Eric Legius, Fabienne Giuliano, Smail Hadj-Rabia, Daniel Hohl, and Christine Bodemer. 2022. "Challenges in Treating Genodermatoses: New Therapies at the Horizon." *Frontiers in Pharmacology* 12(January):1–25. doi: 10.3389/fphar.2021.746664.
- R_Core_Team. 2022. "R: A Language and Environment for Statistical Computing."
- Rogner, Danielle Franziska, Judith Lammer, Alexander Zink, and Henning Hamm. 2021.

“Darier and Hailey-Hailey Disease: Update 2021.” *JDDG - Journal of the German Society of Dermatology* 19(10):1478–1501. doi: 10.1111/ddg.14619.

Sakuntabhai, Anavaj, Victor Ruiz-perez, Simon Carter, Nick Jacobsen, Susan Burge, Sarah Monk, Melanie Smith, Colin S. Munro, Michael O. Donovan, Nick Craddock, Raju Kucherlapati, Jonathan L. Rees, Mike Owen, G. Mark Lathrop, Tom Strachan, and Alain Hovnanian. 1999. “Mutations in ATP2A2, Encoding a Ca²⁺ Pump, Cause Darier Disease.” *Nat Genet* 21(march):271–77. doi: 10.1038/6784.

Savignac, Magali, Anissa Edir, Marina Simon, and Alain Hovnanian. 2011. “Darier Disease: A Disease Model of Impaired Calcium Homeostasis in the Skin.” *Biochimica et Biophysica Acta - Molecular Cell Research* 1813(5):1111–17. doi: 10.1016/j.bbamcr.2010.12.006.

Subramanian, Aravind, Pablo Tamayo, Vamsi K Mootha, Sayan Mukherjee, Benjamin L. Ebert, Michael A. Gillette, Amanda Paulovich, Scott L. Pomeroy, Todd R. Golub, Eric S. Lander, and Jill P. Mesirov. 2005. “Gene Set Enrichment Analysis: A Knowledge-Based Approach for Interpreting Genome-Wide Expression Profiles.” *Proceedings of the National Academy of Sciences of the United States of America* 102(43):15545–50. doi: 10.1073/pnas.0506580102.

Subramanian, Aravind, Pablo Tamayo, Vamsi K. Mootha, Sayan Mukherjee, Benjamin L. Ebert, Michael A. Gillette, Amanda Paulovich, Scott L. Pomeroy, Todd R. Golub, Eric S. Lander, and Jill P. Mesirov. 2005. “Gene Set Enrichment Analysis: A Knowledge-Based Approach for Interpreting Genome-Wide Expression Profiles.” *Proceedings of the National Academy of Sciences of the United States of America* 102(43):15545–50. doi: 10.1073/pnas.0506580102.

Acknowledgements

We would like to thank the patients who supported this research project. We would also like to thank all the physicians and nurses who cared for the patients. We thank Dr. Antonia Currie for proofreading the manuscript. This work was supported by grants of the Medical Faculty of the Johannes Kepler University (Linz, Austria), the Swiss National Science Foundation (IZLIZ3_200253/1), the University of Lausanne (SKINTEGRITY.CH collaborative research program), and the Forschungskredit of the University of Zurich (FK-15-040 to WH).

Author contributions

ME, SK and WH planned the study, revised the data and wrote the manuscript. TB, IP, JT, GW, AL, IG and SK performed experiments. ME, IG, SA, EG and WH revised the data and manuscript. ME, IP, JT and GW provided samples of patients and controls and clinical data.

Competing interests

The authors declare no competing interests.