

1 **Fat infiltration in the vastus medialis implicates joint structural abnormalities in**
2 **early-stage symptomatic knee osteoarthritis**

3

4 Atsushi Hoki, PT¹, Ella D'Amico, MD², Fabrisia Ambrosio, PhD, MPT^{3,4},
5 Tsubasa Iwasaki, PT, MSc¹, Yoshikazu Matsuda, MD^{5,6}, *Hiroataka Iijima, PT, PhD^{7,8}

6

7 ¹Department of Physical Therapy, Matsuda Orthopedic Clinic, Saitama, Japan

8 ²Department of Physical Medicine and Rehabilitation, University of Pittsburgh, Pittsburgh,
9 PA

10 ³Department of Physical Medicine and Rehabilitation, Spaulding Rehabilitation Hospital and
11 Harvard Medical School, Boston, MA

12 ⁴Discovery Center for Musculoskeletal Recovery, Schoen Adams Research Institute at
13 Spaulding, Boston, MA

14 ⁵Department of Orthopedic Surgery, Matsuda Orthopedic Clinic, Saitama, Japan

15 ⁶Department of Pharmacy, Josai University, Saitama, Japan

16 ⁷Institute for Advanced Research, Nagoya University, Nagoya, Japan

17 ⁸Biomedical and Health Informatics Unit, Department of Integrated Health Science, Graduate
18 School of Medicine, Nagoya University, Nagoya, Japan

19

20 ***Corresponding author:**

21 Hiroataka Iijima, PT, PhD

22 Institute for Advanced Research, Nagoya University, Furo-Cho, Chikusa-ku, Nagoya, Aichi,
23 464-8601, Japan

24 Email address: ijijima@met.nagoya-u.ac.jp

25 **ABSTRACT**

26 **Objective:** Early knee osteoarthritis (KOA) presents as minor structural abnormalities in joint
27 tissues, such as cartilage and subchondral bone, that cannot be assessed radiographically.
28 Identification of a sensitive and convenient marker for early disease has the potential to
29 enhance patient outcomes. This study determined 1) whether fat infiltration in muscle (i.e.,
30 muscle quality), as measured by ultrasound, is associated with structural abnormalities seen in
31 early KOA and 2) which quadriceps muscles are appropriate as a novel marker for early KOA.

32 **Methods:** Participants with early symptomatic KOA (Kellgren Lawrence grade 1-2)
33 underwent ultrasound assessment to measure the echo intensity of the vastus medialis and
34 rectus femoris. The echo intensity corrected for ultrasound wave attenuation caused by
35 subcutaneous fat was then calculated (i.e., corrected echo intensity). Structural abnormalities
36 were assessed using the whole-organ magnetic resonance score (WORMS). A generalized
37 linear mixed model was used to assess the relationship between the corrected echo intensity
38 and WORMS score.

39 **Results:** Forty-nine participants (ages: 44-78 years, 65.3% women) with 52 knees were
40 included. After adjustment for covariates, increased corrected echo intensity (i.e., poor muscle
41 quality) in the vastus medialis muscle was significantly associated with greater structural
42 abnormalities, including disrupted cartilage integrity in the medial tibiofemoral joint. The
43 association was not significant in the rectus femoris muscle.

44 **Conclusion:** Individuals with poor muscle quality in the vastus medialis displayed
45 compromised joint integrity. This study suggests that fat infiltration in vastus medialis assessed
46 by ultrasound is an indicator of early symptomatic KOA.

47 INTRODUCTION

48 Knee osteoarthritis (KOA) is a progressively painful and debilitating condition that can limit
49 activities of daily living(1). Due to a lack of effective disease modifying treatments for KOA,
50 increased clinical interest has been directed towards early detection so as to minimize disease
51 progression(2). While radiography is the current gold standard for assessment of KOA, by the
52 time radiography detects narrowing of the joint space, more than 10% of the cartilage has
53 already been lost, and the subchondral bone area has increased by 15%(3). More recent studies
54 have shown that in patients with early KOA, inflammation of the synovium precedes
55 radiographic signs(4). The identification of sensitive and convenient early-stage markers of
56 whole joint structural abnormalities would expand opportunities for effective disease
57 management.

58 One promising candidate for identification of early disease is skeletal muscle fatty
59 infiltration (i.e., myosteatosi s). It is well established that myosteatosi s causes muscle
60 weakness(5), a major risk factor for incident of KOA(6). In addition, myosteatosi s elicits
61 endocrine effects via the secretion of adipokines implicated in the pathogenesis of KOA(7). A
62 meta-analysis showed that myosteatosi s in the quadriceps muscle is increased in individuals
63 with mild-to-moderate KOA when compared to healthy older adults(8). Further implicating the
64 contribution to disease progression, a longitudinal study reported that myosteatosi s in the
65 quadriceps muscle, particularly vastus medialis (VM) muscle, was associated with greater
66 cartilage loss and bone marrow lesions in patients with mild to moderate KOA(9). These
67 previous studies used magnetic resonance imaging (MRI) to assess myosteatosi s in quadriceps

68 muscle. However, MRI is both costly and requires long procedure times. Given these barriers,
69 ultrasound represents an attractive alternative to assess myosteatorsis in quadriceps. Echo
70 intensity (EI), measured using ultrasound, has previously been established as an accurate and
71 reliable indicator for myosteatorsis in comparison to similar measurements using MRI and
72 computed tomography (CT) (10, 11). However, whether increased EI (i.e., poorer muscle
73 quality) of quadriceps muscle can be an indicator of structural abnormalities in earlier stage of
74 KOA has not been assessed.

75 This cross-sectional study tested the hypothesis that poorer quadriceps muscle quality
76 assessed by ultrasound is associated with greater structural abnormalities of the knee in
77 individuals with earlier stage of symptomatic KOA. Specifically, we posited that EI of the VM
78 muscle is associated with increased structural abnormalities (e.g., cartilage loss, bone marrow
79 lesion), as identified by MRI. This study primarily focused on the VM muscle given that poor
80 muscle quality in people with KOA has predominantly been confirmed only in this muscle(12).
81 Given that some studies have also targeted the rectus femoris muscle (RF) for the muscle
82 quality assessment(8), this study also determined whether structural abnormalities of the knee
83 are associated with poor muscle quality in the RF. Ultimately, we aimed to identify the most
84 appropriate target muscle for the prediction of earlier stage of KOA. The findings of this study
85 support ultrasound-based assessment of VM quality as an indicator of early stage of KOA and
86 represent a promising first step in the development of an effective intervention for KOA.

87

88 **METHODS**

89 *Subjects*

90 Individuals with KOA were recruited at the outpatient department of the Matsuda
91 Orthopedic Clinic in Saitama, Japan, from June 2021 to October 2021. All recruited
92 participants were previously seen in the orthopedic clinic for pain in one or both knees and had
93 a diagnosis of KOA within up to 3 months. The presence of KOA was confirmed by an
94 experienced orthopedic surgeon using the radiographically defined Kellgren and Lawrence
95 grading scale (KL grade)(13). Participants also underwent MRI of their symptomatic knee(s).
96 The eligibility criteria were as follows: (1) mild KOA with KL grade 1-2; (2) absence of
97 osteonecrosis of the medial femoral condyle; (3) no history of surgery to the extremities
98 (except intraarticular knee injections); (4) ability to walk without an assistive device; (5) no
99 cognitive dysfunction; (6) no neuromuscular disease; and (7) no trauma to bilateral lower
100 extremities. All these criteria were assessed based on information in the medical records. Given
101 that radiographically defined KL grade 1, but not grade 0, predicts development of KOA to a
102 grade 2 or higher within 3–5 years(14, 15), this study included individuals with KL grades 1
103 but excluded grade 0. This study was approved by the Ethics Committee of the Medical
104 Corporation Nagomi (No. 20210427). All participants provided signed informed consent.

105

106 *Measurements*

107 Muscle quality of the RF and VM was quantified by ultrasound. Structural abnormalities
108 were identified using MRI. These assessments were limited to the symptomatic knee(s), as

109 defined by the presence of knee pain and/or functional limitations from medical examination
110 by physician. Demographic characteristics, body mass index (BMI), ultrasound-based muscle
111 thickness, and self-reported measures of knee pain and disability were also assessed as
112 participant characteristics and/or covariates.

113

114 *Ultrasound imaging of RF and VM muscles*

115 Ultrasound images of the symptomatic knee(s) were acquired using a B-mode imaging
116 device that was equipped with an 8-MHz linear-array probe (SNI BLE, Konica Minolta Ltd.,
117 Japan). Owing to the lack of evidence for specific ultrasound parameters in the assessment of
118 muscle quality in the RF and VM muscles, ultrasound settings were optimized to visually
119 discriminate the fascia of the RF and VM from the muscle fibers and other surrounding tissues
120 (frequency: 9 MHz, gain: 25 dB, dynamic range: 60), in accordance with a previous study(12).
121 These ultrasound settings were kept consistent across all participants, and images were taken in
122 a relaxed supine position with the arms and legs extended. The RF was evaluated on the
123 transverse line halfway between the anterior superior iliac spine and proximal end of patella
124 while the VM was evaluated at the 5cm medial side from the 20% distal point of anterior
125 superior iliac spine and proximal end of patella(12) (**Figure 1A**). The head of the probe was
126 maintained perpendicular to the muscles examined. A water-soluble transmission gel
127 (PROJELLY, Jex Inc., Japan) was applied to the skin to enhance acoustic coupling. EI of the
128 captured ultrasound images was then assessed using ImageJ software (version 1.53, National
129 Institutes of Health, USA)(16). Regions of interest were selected at depths of 1.0-4.0 cm from
130 the surface of skin on the screen display. The EI of the analysis region was calculated using

131 grayscale values from 0 (black) to 255 (white), with a higher mean pixel intensity value
132 indicating fatty infiltration and/or fibrosis tissue(11, 17) (i.e., poor muscle quality). All
133 ultrasound imaging and ImageJ analyses were performed by a trained investigator (AH). To
134 assess the reliability of the imaging procedure, the same investigator performed another
135 assessment more than six months after the first assessment, revealing an excellent intraclass
136 correlation coefficient ($ICC_{1,1}$: 0.948, 95% confidence interval [CI]: 0.912–0.970)(18). To
137 account for the effect of subcutaneous fat thickness on echo measurements, a correction factor
138 was applied to echo measurements (Equation 1)(11), as recommended in several studies(19,
139 20). The formula for the corrected EI was as follows:

$$140 \quad y_2 = y_1 + (x * cf) \quad (1)$$

141 with y_2 = corrected echo intensity; y_1 = raw echo intensity; x = subcutaneous fat thickness; and
142 cf = correction factor of 40.5278.

143 Subcutaneous fat thickness was measured from the superior border of the superficial
144 aponeurosis to the inferior border of the dermis layer, per the established protocol validated by
145 MRI and computed tomography(11, 21). In addition, as a covariate, muscle thickness (cm) was
146 measured from the cortex of the femur to the superior border of the superficial aponeurosis of
147 the RF and VM muscles(22). The image analysis procedure for EI, subcutaneous fat thickness,
148 and muscle thickness is illustrated in **Figure 1B**.

149

150 *Assessment of structural abnormalities in the knee joint by MRI*

151 Structural abnormalities in the knee joint were identified using MRI (1.5 Tesla
152 whole-body MR system, Canon Medical Systems, Japan). Images were obtained as sagittal

153 proton-density-weighted images (3600 msec TR (Repetition Time), 30 msec TE (Echo Time),
154 256×384 matrix, 3.5 mm slice thickness, 0.3 mm inter-slice gap, 180 mm×180 mm field of
155 view, TSE fact (Turbo Spin Echo fact): 15, scan time: 3 min, frequency encoding:
156 anterior-posterior). We used a semi-quantitative scoring method of the whole-organ magnetic
157 resonance imaging score (WORMS)(23), which has been used previously for individuals with
158 early KOA(24). WORMS includes the following categories: (1) cartilage signal and
159 morphology, (2) subarticular bone marrow abnormality, (3) subarticular cysts, (4) subarticular
160 bone attrition, (5) marginal osteophytes, (6) medial and lateral meniscal integrity, (7) anterior
161 and posterior cruciate ligament integrity, (8) medial and lateral collateral ligament integrity, (9)
162 synovitis, loose bodies, and (10) periarticular cysts/bursae. The whole knee joint was divided
163 into the medial tibiofemoral joint, lateral tibiofemoral joint, and patellofemoral joint. The
164 femoral articular surface, medial tibial plateau and lateral tibial plateau were divided into
165 three sub-regions (anterior, central, posterior). The tibia has an additional subspinous
166 sub-region comprised of the non-articulating portion of the tibial plateau beneath the tibial
167 spines. The assessment was performed by the same investigator (AH) who had undergone
168 three weeks of formal training by an experienced orthopedic surgeon and radiologist prior to
169 the start of the study. The investigator read MRI images in a random order with a blinded
170 subject ID. At the second evaluation of WORMS by the same investigator, more than six
171 months after the initial evaluation, the intraclass correlation coefficient was good ($ICC_{1,1}$:
172 0.849, 95%CI: 0.752, 0.910).

173

174 *Participant characteristics and covariates*

175 Data on participant age, sex, and height were self-reported in the electronic medical
176 records. Body mass was measured on a digital scale with the participants dressed but not
177 wearing shoes. BMI was calculated by dividing body mass (kg) by height (m²). A knee

178 radiograph of the symptomatic knee in the anteroposterior view in the weight-bearing position
179 was obtained for all subjects. Using this image, we assessed the femur-tibia angle (FTA) as a
180 measure of the anatomical axis (higher values indicate more varus alignment). The center of
181 the FTA was defined from three points: a point at the base of the tibial spines, at bisecting the
182 femur and tibia, originating 10 cm from the knee joint surface(25). FTA was then corrected to
183 account for sex differences in knee alignment, which was calculated by the addition of 3.5° for
184 women and 6.4° for men, respectively(26). This corrected FTA was used for the subsequent
185 statistical analyses as an alternative measure of full-limb radiograph in weight-bearing
186 position(27).

187 To quantify knee symptoms, all subjects completed the Knee Injury and Osteoarthritis
188 Outcome Score (KOOS)(28). The KOOS has the following subcategories: pain, symptoms,
189 activities of daily living (ADL), sport and recreation function, and knee-related quality of life,
190 with higher scores (0-100) representing better function. This study used the KOOS pain and
191 ADL subscales for descriptive analysis.

192

193 *Statistical analysis*

194 The minimum sample size required to detect significance was calculated from pilot data of
195 individuals with KOA (n = 20) using Power and Sample Size Program, version 3.1.6
196 (Vanderbilt University Medical Center, USA)(29). Preliminary data indicated that the standard
197 deviations of the WOMBS and EI were 9.415 and 17.575, respectively, with a slope estimate of
198 0.209 obtained when WOMBS was regressed against EI. As such, 46 subjects were needed to
199 reject the null hypothesis that this slope equals zero with a probability (power) of 0.8. The Type
200 I error probability associated with this test of null hypothesis was 0.05. The same approach
201 identified that 38 subjects would be needed to detect a significant relationship between the

202 WORMS and corrected EI. After considering the potential 10% dropout rate due to the
203 exclusion criteria and missing data, the required sample size of this study was 51 participants.

204 To account for the similarity between the right and left knees, a generalized linear mixed
205 model, with WORMS total score as fixed effects and patient ID as random-effect intercept and
206 slope, was used to assess the relationship between the WORMS (continuous variable) and EI of
207 VM (continuous variable) or corrected EI of VM (continuous variable). Age (continuous
208 variable), muscle thickness (continuous variable), and sex were included as covariates. These
209 covariates were chosen based on their potential correlation with joint structural abnormalities
210 and muscle quality(30, 31). BMI was not considered as a covariate because of a possible strong
211 correlation with muscle thickness(32). To address the possibility that structural abnormalities
212 might be associated with changes in tissue quality in muscles other than the VM, we repeated
213 the generalized linear mixed model including EI or corrected EI of RF muscle. Since the
214 WORMS total score includes structural abnormalities of whole knee joint tissues (i.e., cartilage,
215 subchondral bone, ligaments, menisci, and synovium), we performed a sensitivity analysis
216 focusing on the WORMS sub-score of cartilage at medial tibiofemoral joint. In the sensitivity
217 analysis, we repeated the generalized linear mixed model described above.

218 All statistical analyses were performed using EZR, version 1.54 (Saitama Medical Center,
219 Jichi Medical University, Japan), which is a graphical user interface for R, version 4.0.3 (The R
220 Foundation for Statistical Computing, Austria), a modified version of R commander designed
221 to add statistical functions frequently used in biostatistics. Statistical significance was set at p
222 <0.05 .

223

224

225

226 RESULTS

227 A total of 51 participants (54 knees) were recruited. Two participants displayed severe
228 KOA with KL grade 3 and were therefore excluded. Therefore, 49 participants (age: 44-78
229 years, 65.3% women) with a total of 52 symptomatic knees were ultimately included. **Table 1**
230 summarizes the participants' characteristics. Of the 49 participants with mild KOA, 30 (61%)
231 had a normal BMI (BMI 18.5 to 24.9 kg/m²), 14 (29%) were pre-obese (BMI 25.0 to 29.9
232 kg/m²), and 5 (10%) were obese (BMI >30 kg/m²). Of the 52 knees, 39 (75%) had varus
233 alignment (corrected FTA >181°), 12 (23%) had neutral alignment (178° < corrected FTA
234 <181°), and 1 (2%) had valgus alignment (corrected FTA <178°)(26).

235 *Individuals with poorer VM muscle quality display higher disruption in cartilage integrity*

236 Consistent with the findings seen with early-stage symptomatic KOA(24), 52 knees
237 (100%) had cartilage defects, 51 (98%) had meniscal tears, and 21 (40%) had bone marrow
238 lesions in the WOMBS subcategories. Among these subcategories, the cartilage sub-score in
239 the medial compartment of the tibiofemoral joint showed the highest median score (**Figure 2**),
240 where was most likely to have relations to KOA(33). Ultrasound and MRI assessments
241 revealed inter-subject variability in quadriceps muscle quality, as identified by ultrasound
242 assessment, as well as structural abnormalities of the cartilage, as identified on MRI
243 assessment among individuals with mild KOA (**Figure 3**). Since all included participants
244 displayed mild KOA with KL grade 1-2, the identification of inter-subject variability in
245 structural abnormalities highlights the ability of MRI to assess structural abnormalities in the
246 earlier stages of KOA. The generalized linear mixed model revealed that the poor muscle
247 quality of the VM, as assessed by corrected EI, was significantly associated with higher joint
248 structural abnormalities after adjusting for muscle thickness, age, and sex. Decreased muscle
249 quality of the RF was also associated with increased joint abnormalities, though the trend was

250 blunted as compared to VM (**Table 2**). The corrected EI of the VM had higher predictive
251 ability for joint structural abnormalities ($r^2=0.44$, $p=0.003$) compared to uncorrected EI of VM
252 ($r^2=0.39$, $p=0.02$) (**Figure 4A-B**).

253 Because joint structural abnormalities were most frequently identified in the articular
254 cartilage in the medial tibiofemoral joint (**Figure 2**), we performed a sensitivity analysis
255 focusing on the WORMS cartilage score in the medial tibiofemoral joint as an outcome
256 variable. The results revealed that poor muscle quality of the VM was significantly associated
257 with more cartilage abnormalities in the medial tibiofemoral joint (**Table S1**). When we added
258 the lower limb alignment (i.e., corrected FTA) or BMI as a covariate to the generalized linear
259 mixed model, poor muscle quality of VM still displayed a significant association with cartilage
260 in medial tibiofemoral joint (**Table S2, S3**). Collectively, these findings indicate that
261 individuals with poor VM muscle quality demonstrate disrupted cartilage integrity in the
262 medial compartment of the knee, regardless of the degree of static knee alignment or obesity.
263 Our results identified by ultrasound reinforce those previously identified by MRI
264 demonstrating that increased cartilage damage is associated with increased fat infiltration in
265 the quadriceps, particularly VM muscle(9, 34-36) (**Figure 4C**).

266

267 **DISCUSSION**

268 Establishment of ultrasound-based prognostic disease marker at the early stages of KOA
269 represents a critical need in the field to better manage the progression of OA. As a first step to
270 address this need, this study tested the hypothesis that poor quadriceps muscle quality, as
271 assessed by ultrasound, is associated with greater structural abnormalities in participants with
272 early stages of KOA. We found that individuals with poor VM muscle quality demonstrated
273 significantly greater structural abnormalities in the knee, even after adjustment for muscle

274 thickness, age, and sex. A subsequent sensitivity analysis identified the same relationship when
275 we focused on structural abnormalities in the articular cartilage at the medial tibiofemoral joint,
276 a finding consistent with medial KOA(33). Notably, these relationships were not significant in
277 the RF muscle, suggesting that the identified relationship between poor quadriceps muscle
278 quality and structural abnormalities occurs in a muscle-specific manner. Importantly, in these
279 analyses, EI corrected for subcutaneous fat improved the predictive ability for structural
280 integrity. Taken together, poor muscle quality in the VM assessed by ultrasound may be a
281 sensitive marker for disrupted cartilage integrity and development of KOA.

282 Analytical ultrasound imaging is increasingly recognized as a cost-efficient and reliable
283 tool to assess fat content in skeletal muscle with many benefits over the two gold standard
284 methods, MRI and CT. Ultrasound-based assessment is also attractive over other measures of
285 muscle dysfunction, such as manual muscle strength testing, given it is less influenced by pain
286 evoked by the measurement procedure (37, 38). Here, we evaluated muscle quality by
287 ultrasound using a previously validated scale, EI. We found that quadriceps EI was an effective
288 predictor of individuals with compromised cartilage integrity. Our results are in line with
289 longitudinal studies demonstrating that VM fat content as evaluated by MRI predicted greater
290 cartilage loss and bone marrow lesions(9, 35, 36). The similarities between the different
291 devices supports the use of ultrasound as a promising tool to predict disrupted cartilage
292 integrity. The utility of ultrasound-based assessment is further enhanced by its capacity to
293 identify individuals at an earlier stage of KOA when compared to conventional radiography,
294 which does not adequately capture the onset or progression of cartilage damage.

295 Early KOA represents a critical window of opportunity to restore joint integrity before
296 the onset of debilitating pain and functional limitations, which often require invasive
297 interventions(2). The findings of this study suggest that implementing ultrasound in clinical

298 practice may help to identify people with minimal cartilage damage who are at risk of
299 developing more severe KOA.

300 Through ultrasound assessments of individual quadriceps muscles, this study also found
301 that the VM displayed a greater predictive ability for compromised cartilage integrity than RF.
302 This was also consistent with previous longitudinal studies using MRI assessments, which
303 revealed the significant relationship between cartilage loss and increased fat infiltration in the
304 VM, but not other quadriceps muscles (i.e., RF, vastus lateralis or vastus intermedius
305 muscles)(36). While the underlying role of the VM in cartilage damage is unclear, these
306 observations may reflect the unique biomechanical role of the VM muscle. The VM primarily
307 acts to stabilize the patellofemoral joint by maintaining medial tracking of the patella during
308 loading(39, 40). The VM therefore contributes to joint stability and load distribution of the
309 knee in the medial-lateral plane with the potential to affect the integrity of articular cartilage
310 at medial tibiofemoral joint(41). Another possible explanation for muscle-specific association
311 with cartilage loss is metabolic link between adipose tissue in VM and cartilage homeostasis.
312 Fat is an endocrine organ that releases inflammatory cytokines such as tumor necrosis factor
313 alpha and interleukin-6(42), which have been implicated in the pathophysiology of KOA(43).
314 The role of adipose-cartilage molecular crosstalk was clearly presented by the recent animal
315 study demonstrating that fat deficiency protected knee joints from spontaneous or
316 post-traumatic murine KOA(44). While no study has addressed the differential role of fat in
317 the VM versus RF muscles, the close anatomic proximity of VM and medial tibiofemoral
318 joint might explain, at least in part, the observed relationship between fat infiltration in VM
319 and cartilage integrity. The current study further supports the need for studies investigating the
320 crosstalk between adipose in quadriceps muscle, particularly in the VM, and cartilage.

321 Although this study provides a new perspective on a sensitive marker for early stage of
322 KOA, it has limitations. First, this study did not consider physical activity levels as a potential

323 confounder(45, 46). Reduced physical activity in daily life, commonly seen in people with
324 KOA, increases accumulation of inter and intramuscular adipose tissue(47). Also, the
325 cross-sectional nature of the study design limited determination of the causal relationship
326 between poor VM muscle quality and compromised structural integrity.

327 Nevertheless, this study has several strengths. First, we applied subcutaneous fat
328 correction to ultrasound-based muscle quality assessment, as recommended in previous
329 reports(19, 20). This method was used to adjust for ultrasound wave attenuation due to
330 subcutaneous fat(48). The corrected EI improved the predictive ability of ultrasound-based
331 signal intensity for structural integrity, and, therefore, this metric should be considered for use
332 in clinical practice over EI. Second, this study used MRI to assess multiple tissues involved in
333 OA pathology. This allowed for the assessment of the relationship between quadriceps muscle
334 quality and structural integrity as stratified according to tissue type, such as cartilage,
335 subchondral bone, and synovium. All of these are considered to influence each other via
336 molecular crosstalk, which contributes to the pathophysiology of early KOA(49). Finally, this
337 study analyzed patients with symptomatic mild KOA who are generally considered to be at
338 high risk of disease progression. Targeting this population provides an enhanced identification
339 of patients who might benefit from treatment for KOA to prevent disease progression.

340 Overall, this study addressed an existing knowledge gap by demonstrating that poor
341 muscle quality in the VM muscle in early-stage KOA is related to structural abnormalities.
342 Further, findings of the current study support the use of ultrasound as a reliable tool for
343 assessing VM muscle quality as a sensitive marker of earlier stage of KOA. As such, our study
344 has the potential to represent an important first step in the development of future longitudinal
345 studies designed to clarify the role of muscle quality, and, ultimately, refine clinical practice to
346 target disease progression at an earlier stage.

347

348 **Contributors**

349 (1) AH and HI were the main contributors to the conception and design of the study; AH, TI,
350 and YM were the main contributors to the acquisition of data; AH, ED, FA, and HI
351 contributed to the analysis and interpretation of data.

352 (2) AH, ED, FA, and HI drafted the manuscript, and AH, ED, FA, and HI critically revised
353 the manuscript.

354 (3) All authors have provided final approval for the version to be submitted.

355

356 **Competing interests**

357 The authors have no conflicts of interest to declare.

358

359 **Acknowledgments**

360 We thank the members of the Physical Therapy and Radiology Department of Matsuda
361 Orthopedic Clinic for extending support in data collection.

362

363 **References**

- 364 1. Guccione AA, Felson DT, Anderson JJ, Anthony JM, Zhang Y, Wilson PW, et al. The effects of
365 specific medical conditions on the functional limitations of elders in the Framingham Study.
366 American journal of public health. 1994;84(3):351-8.
- 367 2. Mahmoudian A, Lohmander LS, Mobasher A, Englund M, Luyten FP. Early-stage symptomatic
368 osteoarthritis of the knee - time for action. Nat Rev Rheumatol. 2021;17(10):621-32.
- 369 3. Jones G, Ding C, Scott F, Glisson M, Cicuttini F. Early radiographic osteoarthritis is associated
370 with substantial changes in cartilage volume and tibial bone surface area in both males and females.
371 Osteoarthritis Cartilage. 2004;12(2):169-74.
- 372 4. Ishibashi K, Sasaki E, Ota S, Chiba D, Yamamoto Y, Tsuda E, et al. Detection of synovitis in
373 early knee osteoarthritis by MRI and serum biomarkers in Japanese general population. Sci Rep.
374 2020;10(1):12310.
- 375 5. Biltz NK, Collins KH, Shen KC, Schwartz K, Harris CA, Meyer GA. Infiltration of
376 intramuscular adipose tissue impairs skeletal muscle contraction. J Physiol. 2020;598(13):2669-83.

- 377 6. Øiestad BE, Juhl CB, Culvenor AG, Berg B, Thorlund JB. Knee extensor muscle weakness is a
378 risk factor for the development of knee osteoarthritis: an updated systematic review and meta-analysis
379 including 46 819 men and women. *Br J Sports Med.* 2022;56(6):349-55.
- 380 7. Chang J, Liao Z, Lu M, Meng T, Han W, Ding C. Systemic and local adipose tissue in knee
381 osteoarthritis. *Osteoarthritis Cartilage.* 2018;26(7):864-71.
- 382 8. Pedroso MG, de Almeida AC, Aily JB, de Noronha M, Mattiello SM. Fatty infiltration in the
383 thigh muscles in knee osteoarthritis: a systematic review and meta-analysis. *Rheumatology*
384 *international.* 2019;39(4):627-35.
- 385 9. Raynauld JP, Pelletier JP, Roubille C, Dorais M, Abram F, Li W, et al. Magnetic Resonance
386 Imaging-Assessed Vastus Medialis Muscle Fat Content and Risk for Knee Osteoarthritis Progression:
387 Relevance From a Clinical Trial. *Arthritis Care Res (Hoboken).* 2015;67(10):1406-15.
- 388 10. Valera-Calero JA, Ojedo-Martín C, Fernández-de-Las-Peñas C, Cleland JA, Arias-Buría JL,
389 Hervás-Pérez JP. Reliability and Validity of Panoramic Ultrasound Imaging for Evaluating Muscular
390 Quality and Morphology: A Systematic Review. *Ultrasound Med Biol.* 2021;47(2):185-200.
- 391 11. Young HJ, Jenkins NT, Zhao Q, McCully KK. Measurement of intramuscular fat by muscle echo
392 intensity. *Muscle Nerve.* 2015;52(6):963-71.
- 393 12. Taniguchi M, Fukumoto Y, Kobayashi M, Kawasaki T, Maegawa S, Ibuki S, et al. Quantity and
394 Quality of the Lower Extremity Muscles in Women with Knee Osteoarthritis. *Ultrasound Med Biol.*
395 2015;41(10):2567-74.
- 396 13. Kellgren JH, Lawrence J. Radiological assessment of osteo-arthrosis. *Annals of the rheumatic*
397 *diseases.* 1957;16(4):494.
- 398 14. Hart DJ, Spector TD. Kellgren & Lawrence grade 1 osteophytes in the knee--doubtful or
399 definite? *Osteoarthritis Cartilage.* 2003;11(2):149-50.
- 400 15. Cibere J, Sayre E, Guermazi A, Nicolaou S, Kopec J, Esdaile J, et al. Natural history of cartilage
401 damage and osteoarthritis progression on magnetic resonance imaging in a population-based cohort
402 with knee pain. *Osteoarthritis and cartilage.* 2011;19(6):683-8.
- 403 16. Schindelin J, Arganda-Carreras I, Frise E, Kaynig V, Longair M, Pietzsch T, et al. Fiji: an
404 open-source platform for biological-image analysis. *Nat Methods.* 2012;9(7):676-82.
- 405 17. Pillen S, Tak RO, Zwarts MJ, Lammens MM, Verrijp KN, Arts IM, et al. Skeletal muscle
406 ultrasound: correlation between fibrous tissue and echo intensity. *Ultrasound Med Biol.*
407 2009;35(3):443-6.
- 408 18. Koo TK, Li MY. A Guideline of Selecting and Reporting Intraclass Correlation Coefficients for
409 Reliability Research. *J Chiropr Med.* 2016;15(2):155-63.
- 410 19. Oranchuk DJ, Stock MS, Nelson AR, Storey AG, Cronin JB. Variability of regional quadriceps
411 echo intensity in active young men with and without subcutaneous fat correction. *Appl Physiol Nutr*
412 *Metab.* 2020;45(7):745-52.
- 413 20. Stock MS, Whitson M, Burton AM, Dawson NT, Sobolewski EJ, Thompson BJ. Echo Intensity
414 Versus Muscle Function Correlations in Older Adults are Influenced by Subcutaneous Fat Thickness.
415 *Ultrasound Med Biol.* 2018;44(8):1597-605.
- 416 21. Watanabe Y, Ikenaga M, Yoshimura E, Yamada Y, Kimura M. Association between echo
417 intensity and attenuation of skeletal muscle in young and older adults: a comparison between
418 ultrasonography and computed tomography. *Clin Interv Aging.* 2018;13:1871-8.

- 419 22. Pardo E, El Behi H, Boizeau P, Verdonk F, Alberti C, Lescot T. Reliability of ultrasound
420 measurements of quadriceps muscle thickness in critically ill patients. *BMC Anesthesiol.*
421 2018;18(1):205.
- 422 23. Peterfy CG, Guermazi A, Zaim S, Tirman PF, Miaux Y, White D, et al. Whole-Organ Magnetic
423 Resonance Imaging Score (WORMS) of the knee in osteoarthritis. *Osteoarthritis Cartilage.*
424 2004;12(3):177-90.
- 425 24. Hada S, Kaneko H, Sadatsuki R, Liu L, Futami I, Kinoshita M, et al. The degeneration and
426 destruction of femoral articular cartilage shows a greater degree of deterioration than that of the tibial
427 and patellar articular cartilage in early stage knee osteoarthritis: a cross-sectional study. *Osteoarthritis*
428 *Cartilage.* 2014;22(10):1583-9.
- 429 25. McDaniel G, Mitchell KL, Charles C, Kraus VB. A comparison of five approaches to
430 measurement of anatomic knee alignment from radiographs. *Osteoarthritis Cartilage.*
431 2010;18(2):273-7.
- 432 26. Ohi H, Iijima H, Aoyama T, Kaneda E, Ohi K, Abe K. Association of frontal plane knee
433 alignment with foot posture in patients with medial knee osteoarthritis. *BMC Musculoskelet Disord.*
434 2017;18(1):246.
- 435 27. Kraus VB, Vail TP, Worrell T, McDaniel G. A comparative assessment of alignment angle of
436 the knee by radiographic and physical examination methods. *Arthritis Rheum.* 2005;52(6):1730-5.
- 437 28. Roos EM, Lohmander LS. The Knee injury and Osteoarthritis Outcome Score (KOOS): from
438 joint injury to osteoarthritis. *Health Qual Life Outcomes.* 2003;1:64.
- 439 29. Dupont WD, Plummer WD, Jr. Power and sample size calculations for studies involving linear
440 regression. *Control Clin Trials.* 1998;19(6):589-601.
- 441 30. Hudelmaier M, Glaser C, Hohe J, Englmeier KH, Reiser M, Putz R, et al. Age-related changes in
442 the morphology and deformational behavior of knee joint cartilage. *Arthritis Rheum.*
443 2001;44(11):2556-61.
- 444 31. Liikavainio T, Lyytinen T, Tyrväinen E, Sipilä S, Arokoski JP. Physical function and properties
445 of quadriceps femoris muscle in men with knee osteoarthritis. *Arch Phys Med Rehabil.*
446 2008;89(11):2185-94.
- 447 32. Sung ES, Han A, Hinrichs T, Vorgerd M, Platen P. Impact of Body Mass Index on Muscle
448 Strength, Thicknesses, and Fiber Composition in Young Women. *Int J Environ Res Public Health.*
449 2022;19(16).
- 450 33. Stoddart JC, Dandridge O, Garner A, Cobb J, van Arkel RJ. The compartmental distribution of
451 knee osteoarthritis - a systematic review and meta-analysis. *Osteoarthritis Cartilage.*
452 2021;29(4):445-55.
- 453 34. Kumar D, Karampinos DC, MacLeod TD, Lin W, Nardo L, Li X, et al. Quadriceps intramuscular
454 fat fraction rather than muscle size is associated with knee osteoarthritis. *Osteoarthritis Cartilage.*
455 2014;22(2):226-34.
- 456 35. Teichtahl AJ, Wluka AE, Wang Y, Wijethilake PN, Strauss BJ, Proietto J, et al. Vastus medialis
457 fat infiltration - a modifiable determinant of knee cartilage loss. *Osteoarthritis Cartilage.*
458 2015;23(12):2150-7.

- 459 36. Kumar D, Link TM, Jafarzadeh SR, LaValley MP, Majumdar S, Souza RB. Association of
460 Quadriceps Adiposity With an Increase in Knee Cartilage, Meniscus, or Bone Marrow Lesions Over
461 Three Years. *Arthritis Care Res (Hoboken)*. 2021;73(8):1134-9.
- 462 37. Henriksen M, Rosager S, Aaboe J, Graven-Nielsen T, Bliddal H. Experimental knee pain reduces
463 muscle strength. *J Pain*. 2011;12(4):460-7.
- 464 38. Shakoor N, Furmanov S, Nelson DE, Li Y, Block JA. Pain and its relationship with muscle
465 strength and proprioception in knee OA: results of an 8-week home exercise pilot study. *J*
466 *Musculoskelet Neuronal Interact*. 2008;8(1):35-42.
- 467 39. Panagiotopoulos E, Strzelczyk P, Herrmann M, Scuderi G. Cadaveric study on static medial
468 patellar stabilizers: the dynamizing role of the vastus medialis obliquus on medial patellofemoral
469 ligament. *Knee Surgery, Sports Traumatology, Arthroscopy*. 2006;14(1):7-12.
- 470 40. Sakai N, Luo Z-P, Rand JA, An K-N. The influence of weakness in the vastus medialis oblique
471 muscle on the patellofemoral joint: an in vitro biomechanical study. *Clinical Biomechanics*.
472 2000;15(5):335-9.
- 473 41. Wang Y, Wluka AE, Berry PA, Siew T, Teichtahl AJ, Urquhart DM, et al. Increase in vastus
474 medialis cross-sectional area is associated with reduced pain, cartilage loss, and joint replacement
475 risk in knee osteoarthritis. *Arthritis & Rheumatism*. 2012;64(12):3917-25.
- 476 42. Trayhurn P, Beattie JH. Physiological role of adipose tissue: white adipose tissue as an endocrine
477 and secretory organ. *Proceedings of the Nutrition Society*. 2001;60(3):329-39.
- 478 43. Berenbaum F. Osteoarthritis as an inflammatory disease (osteoarthritis is not osteoarthrosis!).
479 *Osteoarthritis and cartilage*. 2013;21(1):16-21.
- 480 44. Collins KH, Lenz KL, Pollitt EN, Ferguson D, Hutson I, Springer LE, et al. Adipose tissue is a
481 critical regulator of osteoarthritis. *Proc Natl Acad Sci U S A*. 2021;118(1).
- 482 45. Fukumoto Y, Yamada Y, Ikezoe T, Watanabe Y, Taniguchi M, Sawano S, et al. Association of
483 physical activity with age-related changes in muscle echo intensity in older adults: a 4-year
484 longitudinal study. *J Appl Physiol (1985)*. 2018;125(5):1468-74.
- 485 46. Lin W, Alizai H, Joseph GB, Srikkum W, Nevitt MC, Lynch JA, et al. Physical activity in
486 relation to knee cartilage T2 progression measured with 3 T MRI over a period of 4 years: data from
487 the Osteoarthritis Initiative. *Osteoarthritis Cartilage*. 2013;21(10):1558-66.
- 488 47. Manini TM, Clark BC, Nalls MA, Goodpaster BH, Ploutz-Snyder LL, Harris TB. Reduced
489 physical activity increases intermuscular adipose tissue in healthy young adults. *Am J Clin Nutr*.
490 2007;85(2):377-84.
- 491 48. Pillen S. Skeletal muscle ultrasound. *European Journal of Translational Myology*.
492 2010;20(4):145-56.
- 493 49. Sellam J, Berenbaum F. The role of synovitis in pathophysiology and clinical symptoms of
494 osteoarthritis. *Nature Reviews Rheumatology*. 2010;6(11):625-35.

496 **Table 1.** Characteristics of the study subjects (49 participants with 52 symptomatic knees)

Age, years	64.1±8.9
Sex (female/male), no.	32/17
Height, cm	159.8±9.3
Weight, kg	63.2±11.5
BMI, kg/m ²	24.7±3.7
Analgesic medication, no. (%)	21 (43%)
FTA, degree	178.2±1.9
Alignment (varus/neutral/valgus), no. (%)	39 (75%)/12 (23%)/1 (1%)
KL grade (grade 1/grade 2), no.	13/39
KOOS pain, points	39.2±21.8
KOOS ADL, points	32.2±27.9
Corr. EI of VM	139.3±29.2
Corr. EI of RF	140.6±26.7

497 Except where indicated otherwise, values are presented as mean (SD). Score of KOOS pain
498 and KOOS ADL are percentage scores from 0 to 100. For KOOS pain, a score of 100
499 represents no pain, and pain increases as scores approach 0. KOOS ADL with 100 representing
500 no disability and 0 representing maximum disability.

501 *Abbreviations: ADL, activities of daily living; BMI, body mass index; Corr. EI, corrected echo*
502 *intensity; FTA, femur-tibia angle; KL grade, Kellgren, and Lawrence grading scale; KOOS,*
503 *Knee Injury and Osteoarthritis Outcome Score; RF, rectus femoris; SD, standard deviation;*
504 *VM, vastus medialis.*

505 **Table 2.** Association between WORMS total score and VM and RF muscle quality

VM (corr.EI) vs WORMS (total score)					
Variables	Coefficient	95% CI	Df	t value	p value
(Intercept)	-17.477	-37.552, 2.644	45.807	-1.660	0.104
Corr. EI (VM)	0.146	0.06, 0.231	46.523	3.269	0.002
Muscle thickness (VM)	-2.45	-7.118, 2.225	45.199	-1.008	0.319
Age	0.34	0.096, 0.583	43.782	2.644	0.011
Sex	-1.074	-6.288, 4.127	45.466	-0.392	0.697
RF (corr.EI) vs WORMS (total score)					
(Intercept)	-24.942	-52.471, 2.389	44.402	-1.744	0.088
Corr.EI (RF)	0.054	-0.048, 0.157	46.862	1.014	0.316
Muscle thickness (RF)	5.712	-2.687, 14.151	46.07	1.386	0.172
Age	0.473	0.205, 0.742	44.046	3.362	0.002
Sex	-5.727	-11.54, 0.062	46.113	-1.904	0.063

506 Regression coefficients and 95% CIs of corrected EI (continuous variable) were calculated,
 507 demonstrating that the corrected EI of VM is more predictive than corrected EI of RF for the
 508 WORMS total score (continuous variable) while simultaneously including (1-step model),
 509 muscle thickness (continuous variable), age (continuous variable) and sex.

510 *Abbreviations: 95% CI, 95% confidence interval; Corr. EI, corrected echo intensity; Df,*
 511 *degrees of freedom; EI, echo intensity; RF, rectus femoris; VM, vastus medialis; WORMS,*
 512 *whole-organ magnetic resonance imaging score.*

513

514 **Figure 1. Procedure of ultrasound assessment on quadriceps muscle quality**

515 Example of the data collection procedure in rectus femoris and vastus medialis with
516 ultrasound (**A**). Example of image analysis for the determination of EI, muscle thickness, and
517 subcutaneous fat thickness (**B**). ROIs for EI (solid line circle) were selected at a depth of
518 1.0-4.0 cm to avoid the surrounding tissue. Muscle thickness (solid line arrow) and
519 subcutaneous fat thickness (dashed line arrow) were measured using an electric caliper.

520 *Abbreviations: ASIS, anterior superior iliac spine; EI, echo intensity; RF, rectus femoris;*
521 *ROI, region of interest; VM, vastus medialis.*

522

523

524 **Figure 2. The distribution of WORMS sub-score**

525 The vertical axis shows sub-score in each subcategory. The box plot shows the interquartile
526 range. The inset graph right above shows the breakdown of cartilage sub-score at each joint
527 in the knee.

528 *Abbreviations: WORMS, whole-organ magnetic resonance imaging score.*

529

530

531 **Figure 3. Representative ultrasound images of quadriceps muscle**

532 Images show low corrected EI and low WORMS in her early 60's woman with KL2 (two
533 images on the left) and high corrected EI and high WORMS in her early 70's woman with KL2
534 (two images on the right).

535 *Abbreviations: Corr.EI, corrected echo intensity; FB, femoral bone; KL grade, Kellgren*
536 *Lawrence grade; MTFJ, medial tibiofemoral joint; RF, rectus femoris; SCF, subcutaneous fat;*
537 *VM, vastus medialis; WORMS, whole-organ magnetic resonance imaging score.*

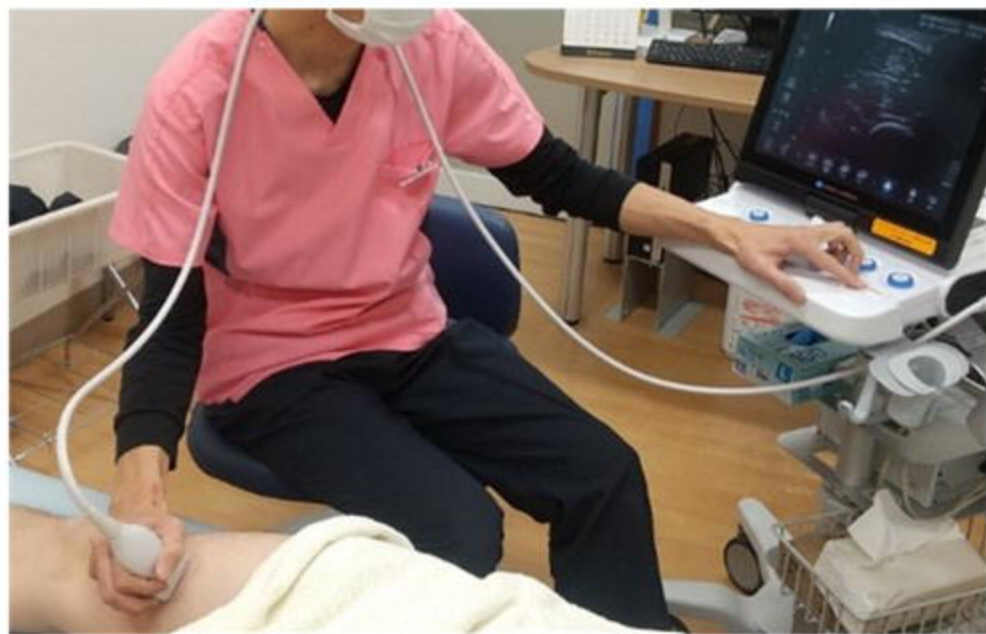538

539 **Figure 4. Relationship between quadriceps muscle quality and structural abnormalities**

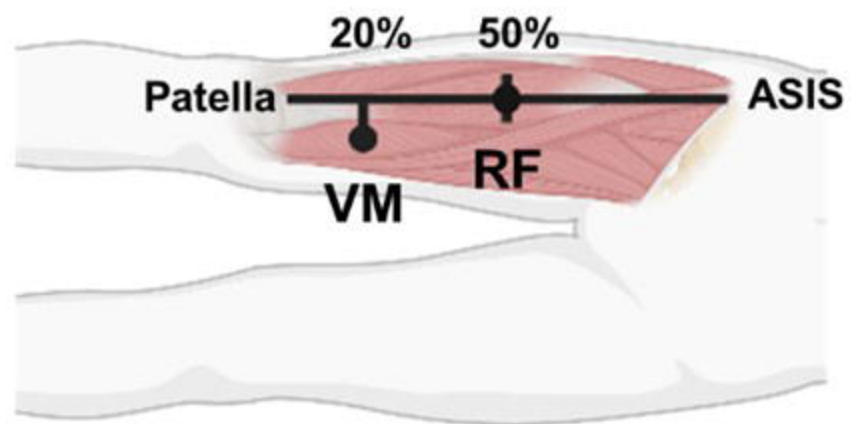
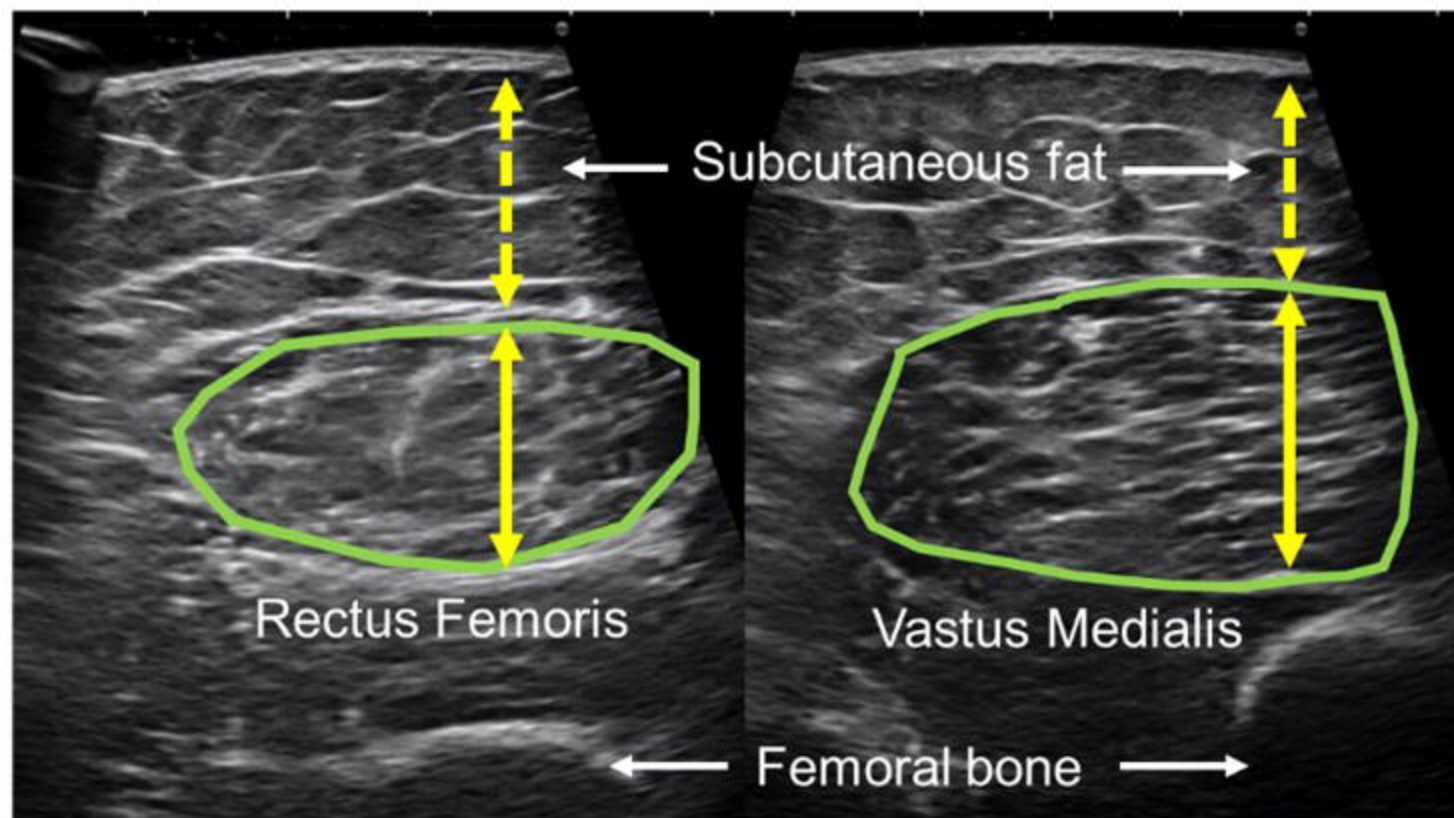
540 Scatter plot and regression line between WORMS total score and EI of VM (A) and corrected
541 EI of VM (B). The regression line was calculated from total data (KL1 and KL2). This study
542 showed that individuals with poor muscle quality in the VM, rather than RF, displayed
543 compromised cartilage integrity in the medial tibiofemoral joint at an earlier stage of the
544 disease (C). These results of present ultrasound study were consistent to previous MRI studies
545 that assessed correlation between increased intramuscular fat and cartilage loss (C).




546 *Abbreviations: Corr.EI, corrected echo intensity; EI, echo intensity; KL, Kellgren and*
547 *Lawrence; MRI, magnetic resonance imaging; RF, rectus femoris; VM, vastus medialis;*
548 *WORMS, whole-organ magnetic resonance imaging score; yrs, years.*

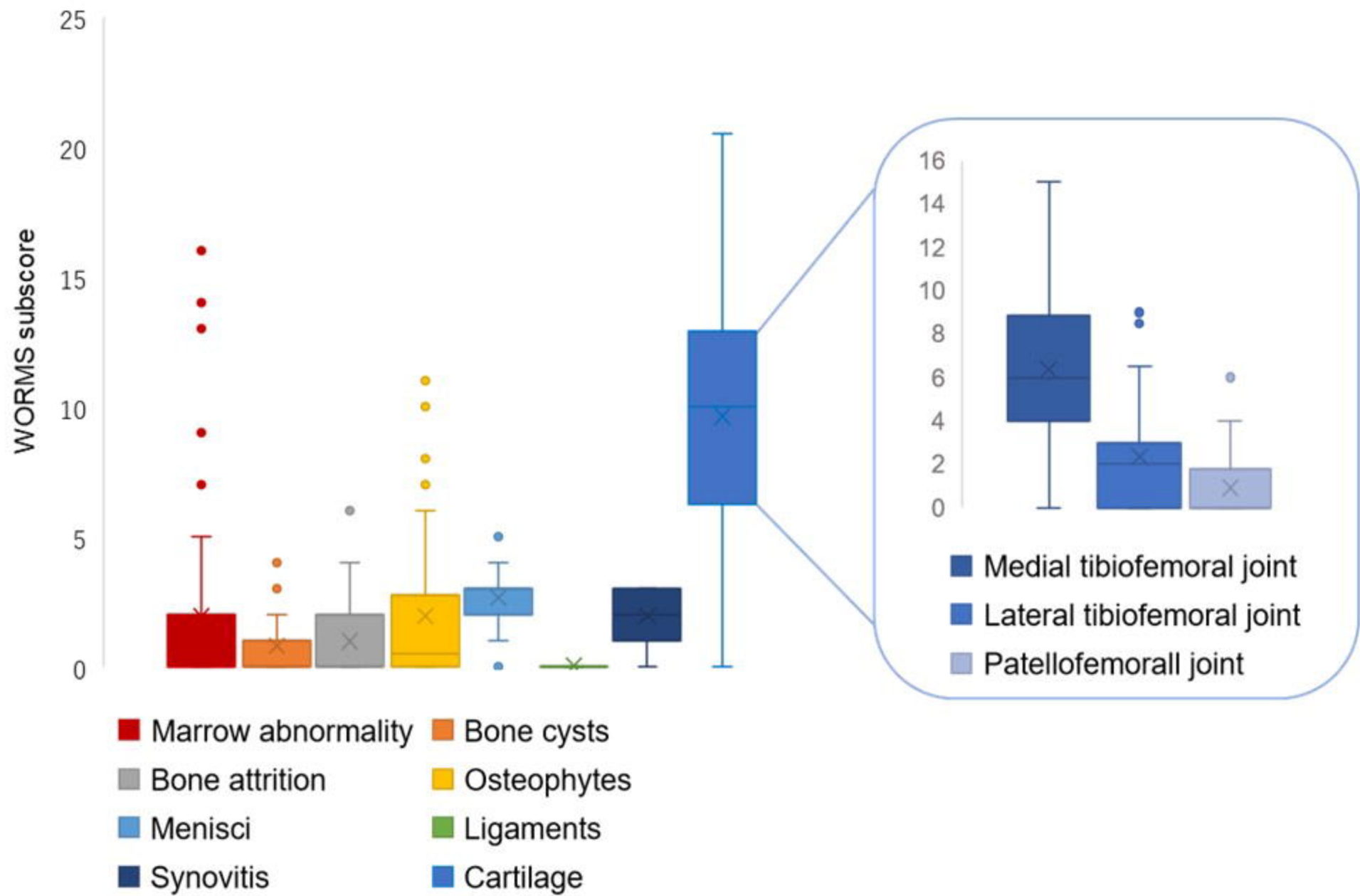
A



B



-  : ROI of echo intensity
-  : Subcutaneous fat thickness
-  : Muscle thickness





Corr.EI

RF: 98.2
VM: 99.0

WORMS

Total: 14.0
Cartilage: 5.0
Cartilage in MTFJ: 7.0

Corr.EI

RF: 154.5
VM: 176.4

WORMS

Total: 29.0
Cartilage: 11.0
Cartilage in MTFJ: 4.0

