

Two phenotypes of Chronic Recurrent Multifocal Osteomyelitis with different patterns of bone involvement

Dita Cebecauerová¹, Hana Malcová¹, Veronika Koukolská², Zuzana Kvíčalová³, Ondřej Souček⁴, Lukáš Wagenknecht⁵, Jiří Bronský⁴, Zdeněk Šumník⁴, Martin Kynčl², Marek Cebecauer³ and Rudolf Horváth¹

¹ Department of Paediatric and Adult Rheumatology, Motol University Hospital , Prague, Czech Republic

² Department of Radiology, Second Faculty of Medicine, Charles University and Motol University Hospital, Prague, Czech Republic.

³ Department of Biophysical Chemistry, J. Heyrovsky Institute of Physical Chemistry of the Czech Academy of Sciences, Prague, Czech Republic

⁴ Department of Pediatrics, Second Faculty of Medicine, Charles University and Motol University Hospital, Prague, Czech Republic.

⁵ Department of Ortopaedics, Second Faculty of Medicine, Motol University Hospital, Prague, Czech Republic

Corresponding author: Dita Cebecauerova M.D, PhD., dita.cebecauerova@fnmotol.cz

1 Abstract

2

3 **Introduction:** Chronic Recurrent Multifocal Osteomyelitis (CRMO) is an autoinflammatory bone
4 disorder with predominantly paediatric onset. Children present with multifocal osteolytic lesions
5 accompanied by bone pain and soft tissue swelling. Patients often exhibit extraosseous co-morbidities
6 such as psoriasis, inflammatory bowel disease, and arthritis.

7 **Objectives:** Comparison of children with two different phenotypes of CRMO defined by presence or
8 absence of extraosseous co-morbidities.

9 **Methods:** Children diagnosed with CRMO at the Motol University Hospital between 2010-2020 were
10 retrospectively reviewed, and according to the absence or presence of extraosseous manifestations
11 divided into two cohorts – osteolytic CRMO and complex CRMO. The two groups were compared in
12 terms of demographic data, age at disease onset, number and site of bone lesions, laboratory
13 biomarker values, and need of escalation to a second-line therapy

14 **Results:** Thirty-seven children (30 female, 7 male) with confirmed CRMO were included in the analysis.
15 The mean age at disease onset was ten years. All but 3 patients presented with multifocal disease.
16 Twenty-three children (62%) had at least one extraosseous manifestation (13 sacroiliitis, 8
17 inflammatory bowel disease, 6 skin disease [acne, pustulosis, or psoriasis], 7 arthritis). Complex CRMO
18 was associated with a significantly higher ESR rate ($p=0.0064$) and CRP level ($p=0.018$). The groups did
19 not differ in number of foci or in age at disease onset. Bone lesion distribution differed between the
20 two groups with significantly more frequent involvement of clavicle ($p=0.011$) and pelvis ($p=0.038$) in
21 patients with complex CRMO. Children with complex CRMO more often needed escalation of therapy
22 to DMARDs and biologic agents.

23 **Conclusion:** Our data suggest that CRMO affecting solely the skeleton has milder course compared to
24 complex CRMO with extraskeletal features. Further studies are needed to explore the clinical as well
25 as the patient reported outcomes and promote individually tailored therapeutic strategies in both
26 CRMO phenotypes.

27 Keywords

28 Autoinflammatory disease, chronic non-bacterial osteomyelitis, chronic recurrent multifocal
29 osteomyelitis, inflammatory bowel disease, sacroiliitis, whole-body magnetic resonance imaging

30

31 Introduction

32

33 Chronic Recurrent Multifocal Osteomyelitis (CRMO) is a rare autoinflammatory disorder characterized
34 by sterile bone lesions ^{1,2}. It is often referred to as a subgroup within Chronic Non-Bacterial
35 Osteomyelitis (CNO). For patients with concomitant acne or pustulosis the acronym SAPHO (Synovitis,
36 acne, pustulosis, hyperostosis, osteitis) is used. CRMO incidence is estimated at 1:250 000 ³; precise
37 values remain unknown. However, the number of diagnosed cases has increased lately with improved
38 public and care-provider awareness and better accessibility of whole-body magnetic resonance
39 imaging (WB-MRI) ^{4,5}. It affects predominantly young girls with peak presentation at age 10 years ⁶⁻⁸,
40 typically with bone pain accompanied by local warmth and soft tissue swelling. The disease course is
41 recurrent or persistent with a variable number of osteolytic lesions developing over time. The unifocal
42 and persistent form is more common in adult patients ⁹. Adults and adolescents often display
43 involvement of clavicle and sternum and have various cutaneous manifestations ^{9,10}.

44 The molecular pathogenesis is not fully understood, but there is a consensus that CRMO is an
45 autoinflammatory disease, characterized by unprovoked spontaneous flares of tissue-specific bone
46 inflammation. The fact that different autoimmune conditions frequently affect pedigrees of CRMO
47 patients emphasizes the role of genetic predispositions. However, specific genetic variants are
48 characterised only in a small proportion of patients ¹¹⁻¹⁴. Typical examples of monogenic forms of
49 osteomyelitis represent Majeed syndrome or DIRA (Deficiency of Interleukin-1 Receptor Antagonist),
50 with an altered IL-1 signalling pathway. Mutations in the coding and regulatory parts of *FLBIM1* are
51 found in a minority of children with non-syndromic CRMO together with an altered IL-10 signalling
52 pathway ^{11,12}. These variants are, nevertheless, considered as contributing to rather than as underlying
53 CRMO. At this writing, no other entries for CRMO exist in the Online Mendelian Inheritance in Man
54 database¹⁵. Clinically, CRMO shares significant overlap with TNF α -related autoimmune conditions
55 such as spondyloarthritis, psoriasis, and inflammatory bowel disease (IBD). Indeed, CRMO and/or
56 SAPHO syndrome may, over time, evolve into spondyloarthropathy in some patients ¹⁶. The available
57 data are limited but suggest that aetiopathogenesis of CRMO is complex and that a probably
58 heterogenous genetic background underlies a seemingly uniform phenotype.

59 Recent reports indicate that about half of CRMO patients have associated extraosseous involvement,
60 mostly psoriasis and palmo-plantar pustulosis, IBD, and arthritis. The frequency of particular co-
61 morbidities varies significantly among reported cohorts^{6,8,9,17,18}. Whilst cutaneous involvement is
62 reported in 10-30% of patients, IBD is diagnosed in a much smaller group (5-13%). Arthritis varies
63 significantly between individual cohorts (6-56%). Evidently, more studies are required better to
64 understand these complex relations between CRMO and associated conditions.

65 So far, no specific guidelines exist for the treatment of children with CRMO. Therapy response
66 assessment is complicated by the lack of a definition of disease remission. Based on current treatment
67 practices, Zhao et al. published consensus treatment plans for CRMO refractory to non-steroidal anti-

68 inflammatory drugs (NSAIDs)¹⁰. Whereas NSAIDs represent first-line treatment, bisphosphonates are
69 used in case of spinal involvement or NSAIDs failure. Disease-modifying anti-rheumatic drugs
70 (DMARDs) and short-course corticosteroids can be used to escalate therapy; however, disease
71 remission is achieved in fewer patients for whom these approaches are required^{6,9,19,20}. Biologic
72 DMARDs, primarily tumour necrosis factor α inhibitors (TNFi), are the preferred choice in refractory
73 disease or associated conditions, including sacroiliitis or IBD^{21,22}.

74 This study postulated that the two distinct phenotypic manifestations of CRMO – a solely osteolytic
75 form, with only bone involvement, and a complex form, characterised by the presence of extrasosseous
76 associated conditions – might differ in clinical and laboratory aspects of disease, and sought to
77 compare cohorts of children with the two forms of CRMO.

78

79 **Methods**

80 We retrospectively reviewed and analysed a cohort of paediatric CRMO patients diagnosed and
81 treated at Motol University Hospital, Prague, between 2010 and 2020. Only children still followed-up
82 in Motol University Hospital, were included in the study. The diagnosis was based on the typical clinical
83 and radiological findings and in 62% of children was completed by histologic and microbiologic
84 confirmation of chronic non-bacterial osteomyelitis. Bristol criteria^{17,23} were applied retrospectively
85 to all patients included in the study. The study was approved by the local Ethics Committee (EK
86 1412/20). Written informed consent was obtained from patients or legal guardians before study
87 enrolment. From medical records we collected clinical data, including family history, gender, ethnicity,
88 age of disease onset, first symptoms at manifestation, number and distribution of bone lesions, biopsy
89 results, microbiologic results, spinal involvement, inflammatory and immunological marker values,
90 faecal calprotectin levels, extrasosseous disease, and therapy. WB-MRI and X-ray imaging were re-
91 assessed by an experienced radiologist. Sacroiliac-joint involvement was diagnosed only when typical
92 oedema of subchondral bone was present.

93 *Statistical analysis*

94 Fisher's exact test was used to compare the two groups of patients with lesions present and absent at
95 a given site. All datasets (age at onset, number of foci, erythrocyte sedimentation rate [ESR], and
96 serum C-reactive protein [CRP]) were first tested for normality using quantile-quantile plots and the
97 Anderson-Darling test. Number of lesions and age at onset showed normal distributions with equal
98 variance (two-sample F-test). Two-sample unpaired Student's t-testing was used to compare the
99 means between the osteolytic and complex CRMO groups. For ESR and CRP parameters not following
100 a normal distribution, means were compared with the two-sample Kolmogorov-Smirnoff test.
101 Statistical analyses were performed using appropriate functions of MATLAB software (Mathworks,
102 Natick, MA).

103

104 Results

105 Thirty-seven children, 30 girls (81%) and 7 boys (19%), were enrolled in the study (Fig. 1). Their clinical
106 characteristics are summarized in Tab. 1. The initial symptom in most cases was limb pain (51%),
107 followed by back pain (38%). The prevalently affected site was pelvis (59%), followed by femur (49%),
108 tibia (43%), spine (38%), and clavicle (35%). Clavicular swelling as a first sign was present in 2 patients
109 (5%); however, WB-MRI revealed asymptomatic clavicular lesions in 11 more children, with bilateral
110 involvement in 4. Diaphyseal regions were affected in 9 children (24%). In six the lesion laid within the
111 large metaphyseal-diaphyseal region. Solely diaphyseal lesions were confirmed in 4 children (11%).
112 The least involved regions were skull, mandible, and scapula, with involvement in 2 children each. Just
113 3 patients (8%) were proven to have a single osteolytic site on WB-MRI. These solitary lesions were in
114 10th thoracic vertebra, clavicle, and humerus.

115 Inflammation-marker values were elevated at presentation in most of the patients. ESR and/or CRP
116 were increased in 24 children (65%) at the time of diagnosis, but they did not intercorrelate in all
117 patients, *i.e.*, some children had elevated ESR but not CRP and *vice versa*. Only 5 children had
118 inflammatory-marker values within normal range. ANA were identified in 2 patients (5%). HLA-B27
119 positivity was detected in 6 children (16%), an incidence twice as high as that in a general Central
120 European population ²⁴.

121 Twenty-five children (68%) had family histories of one or more autoimmune diseases in first- and
122 second-degree relatives (Fig. 2a), most often IBD (6) and psoriasis (3). Twenty-three CRMO patients
123 (62%) had associated extraosseous conditions (Fig. 2b) at the time of diagnosis or developed them
124 during follow-up (1-10 years). These were considered as 'complex CRMO' in this study. Thirteen
125 children (35%) had sacroiliitis (Tab. 1), 7 of them symptomatic. In 6 patients, sacroiliitis remained
126 clinically silent. Bilateral sacroiliitis was more frequent than unilateral and was not associated with
127 HLA-B27 positivity. Only one HLA-B27 positive child had MRI-proved sacroiliitis (Fig. 3). In this patient,
128 sacroiliitis remained asymptomatic despite ongoing inflammation detectable by MRI. On the other
129 hand, 5 out of 6 HLA-B27 positive children had vertebral lesions (Fig. 3). Four children who were
130 treated with bisphosphonates achieved regression of sacroiliitis.

131 Eight children in our cohort (22%) developed enteropathic CRMO, osteomyelitis associated with IBD.
132 Four had family histories of IBD. Tab. 2 summarizes characteristic features and the sequential course
133 of their disease. CRMO preceded IBD in 3 patients and IBD preceded CRMO in 5. The average delay
134 between presentation and manifestation of the associated disorder was 4 years. Two children who
135 initially presented with CRMO and in whom complete remission of bone disease was achieved later
136 developed IBD without relapse of CRMO. Enteropathic CRMO appears to be a specific subtype of the
137 disease with a more severe phenotype. Such children in our study frequently suffered from more than
138 one extraosseous manifestation, including skin disease, sacroiliitis, arthritis, primary sclerosing
139 cholangitis, and uveitis. All children with enteropathic CRMO had elevated faecal calprotectin levels

140 (Tab. 2). Mild elevation of faecal calprotectin (FCP; up to 250 $\mu\text{g/g}$) was found in samples from 9 other
141 CRMO patients, but they did not progress to IBD, and their FCP levels dropped during follow-up.

142 Arthritis was diagnosed in 7 children (19%); 6 of them had a family history of autoimmune disease.
143 Arthritis primarily but not exclusively adjoined foci of osteomyelitis. Eight patients (22%) developed
144 skin disease including acne ($n=3$), pustular psoriasis ($n=1$), palmoplantar pustulosis ($n=2$), and atopic
145 or unspecified dermatitis ($n=3$). SAPHO syndrome was diagnosed in 3 individuals (8%) based on severe
146 nodulocystic acne and clavicular involvement with typical imaging findings. All 3 patients had an
147 inflammatory phenotype at the time of diagnosis. Palmoplantar pustulosis occurred as a paradoxical
148 effect of TNFi therapy (1x infliximab, 1x adalimumab) in 2 children who initially suffered from IBD and
149 later manifested CRMO. Their skin disease was managed by topical treatment without withdrawal of
150 TNFi therapy. One patient presented with chronic remitting pustular dermatitis but was not diagnosed
151 with psoriasis. Her skin disease continues into adulthood. Two different patients with enteropathic
152 CRMO had atopic dermatitis and nail pitting, but not skin disease corresponding to psoriasis.

153 In the next part of our study, we aimed to compare solely osteolytic and complex CRMO in children.
154 A family history of autoimmune diseases was present in 71% of children with osteolytic CRMO and in
155 65% of children with complex CRMO. No differences were found for blood markers like leukocyte and
156 platelet counts, haemoglobin, and mean cell volume (MCV) (Fig. 4A). By contrast, inflammatory
157 activity was significantly higher in complex than in osteolytic disease (CRP, $p=0.018$; ESR, $p=0.0064$;
158 Fig. 4B). Children with osteolytic CRMO manifested disease slightly earlier (mean 105 ± 36 months)
159 than did children with complex CRMO (mean 123 ± 38 months); however, the difference was
160 statistically not significant ($p=0.1336$). Nor did the number of lesions differ between the two groups
161 (Fig. 4B). Interestingly, we found statistically significant differences in affected sites between the two
162 groups. Whereas children with osteolytic CRMO often displayed long-bone involvement, children with
163 complex CRMO presented predominantly with involvement of clavicle and pelvis (clavicle, $p=0.011$;
164 pelvis, $p=0.038$; Fig. 5). Frequent and almost equal between both patient groups was femoral (50% in
165 osteolytic CRMO, 48% in complex CRMO) and spinal involvement (43% in osteolytic CRMO, 35% in
166 complex CRMO; see also Tab. 3).

167 Treatment options used in our cohort are summarized in Fig. 6. All children with osteolytic CRMO and
168 74% of those with complex CRMO received NSAIDs, including ibuprofen, naproxen, or diclofenac. Half
169 of the patients were treated with bisphosphonates (pamidronate or zoledronate) because of spinal
170 involvement or inefficacy of NSAIDs. The percentage of bisphosphonate treatment was similar for the
171 osteolytic and complex CRMO groups (respectively 43% and 50%), while spinal involvement was
172 identified in respectively 43% and 35% of children. Children with complex CRMO more often received
173 conventional synthetic DMARDs, corticosteroids, and biologic therapy (TNFi) (Fig. 6). Substantial
174 improvement or disease remission was achieved in 27 patients (73%); 7 children (19%) still have active
175 chronic or remittent disease. Three patients with complex CRMO were lost to follow-up due to non-
176 compliance.

177 Discussion

178 In this study, we focused on different phenotypes of CRMO. We observed that children with
179 extrasosseous involvement present with significantly increased inflammatory activity, have a distinct
180 type of bone involvement, and more frequently require escalation to a second-line therapy. No
181 differences in number of bone lesions and in age at disease onset were found.

182 Some earlier studies noticed phenotypic differences between CRMO patients and endeavoured to
183 stratify their patients according to severity and disease course ^{7,17,25}. Wippf et al. defined three
184 subgroups of CRMO patients ⁷. Compared to the mild form, children with intermediate and severe
185 phenotypes more frequently presented with extraskeletal co-morbidities, multifocal disease, and
186 inflammatory syndrome. The more aggressive CRMO phenotype, with higher rates of multifocality,
187 higher ESR, and predominant involvement of feet, tibia, pelvis, and humerus was described in children
188 with extrasosseous manifestation by Borzutzky and colleagues ⁶. In accordance with these findings,
189 O'Leary et al. demonstrated multifocality of lesions and low response rate to NSAIDs in their Irish
190 cohort with a high prevalence of extrasosseous involvement. We observed similar differences between
191 children with and without extrasosseous manifestations. Our findings further suggest that lesions in
192 complex CRMO patients with affected extraskeletal tissues, particularly skin, gut, and joints, are
193 differently distributed. Clavicular and pelvic lesions dominated in complex CRMO whereas lesions in
194 metaphysis of long bones and foot were less frequent (Fig. 5B). On the contrary, foot and long bones,
195 specifically tibia, were prevalent sites of lesions in osteolytic CRMO. In our group of patients, we
196 noticed an unusually high incidence of IBD compared with other cohorts. In the subgroup of patients
197 with IBD, the dominant osteolytic pattern comprises clavicle and pelvis. However, further studies on
198 a large cohort are required for generalisation of our observations and determination of predictive
199 value of lesion distribution in CRMO subtypes.

200 Family history has an important, yet not fully understood role in CRMO. More than 50% of children in
201 reported cohorts had family histories of autoimmune disorders, especially of those on the
202 spondyloarthritis spectrum. One of the characteristics of these disorders, recently extensively studied,
203 is the alteration of gut homeostasis and of the enterobiome. Extrasosseous manifestations observed in
204 our patients and autoimmune diseases in families exhibit similarities (Fig. 2). Arthritis, IBD, and
205 psoriasis are conditions shared between the two groups. However, specific autoimmune diseases are
206 not clustered within the families in any apparent pattern. For example, only half of the children with
207 enteropathic CRMO in our cohort have a family history of IBD. On the other hand, arthritis or psoriasis,
208 also present in pedigrees of our patients, is known to be associated with alteration of gut microbiota
209 ²⁶⁻²⁹. Thus, it can represent an additional factor contributing to the development of enteropathic
210 CRMO. Indeed, such correlation was proposed in two CRMO studies ^{27, 30}. A recent report also
211 describes successful deployment of a Crohn- disease exclusion diet in a paediatric patient with
212 enteropathic CRMO ³¹. Interestingly, we observed elevated FCP levels in 31% of our patients with
213 active CRMO (apart from those with the enteropathic form), indicating the presence of subclinical gut

214 inflammation. The retrospective character of this study prevented analysis of the microbiome in our
215 patients. Nevertheless, a better understanding of the interplay between genetic predispositions,
216 mirrored in family history of the probands, and environmental factors could promote our
217 understanding of disease aetiopathogenesis and possibly shape future therapy strategies. A possible
218 inference is that children with a higher risk of IBD may profit from an earlier switch to TNFi or from
219 NSAIDs avoidance. Similarly, to identify patients at high risk for development of psoriasis, including
220 paradoxical disease during TNFi treatment, could encourage concomitant treatment with DMARDS,
221 such as methotrexate ^{32,33}.

222 Even though our study has yielded several interesting findings, we must mention limitations that
223 restrain us from offering general recommendations. First and foremost, the number of children with
224 CRMO in this cohort is low. The retrospective approach in this study did not allow implementation of
225 a uniform treatment protocol for all patients and a comprehensive evaluation of the treatment
226 response. Importantly, our findings are in line with other studies indicating that CRMO is a
227 heterogeneous disease ^{34,35} and that “CMRO” might be considered as an umbrella term for
228 phenotypically similar disorders with potentially diverse etiopathogenetic backgrounds and sterile
229 osteomyelitis as a dominant feature.

230 In conclusion, osteomyelitis as a dominant phenotypic feature of CRMO is accompanied by
231 inflammation of other tissues in a substantial group of patients. The disease thus presents in two main
232 forms, osteolytic and complex. The concept of CRMO as a clinical continuum between these two
233 distinctive forms impedes definition of diagnostic and therapeutic strategies. A tailored therapy of
234 CRMO patients remains unavailable. However, a detailed clinical stratification of patients followed by
235 genetic-epigenetic studies can promote early identification of high-risk patients, who could benefit
236 from more aggressive treatment with early therapy escalation.

237 [Availability of data and materials](#)

238 The datasets used and/or analysed during the current study are available from the corresponding
239 author on reasonable request.

240 [Abbreviations](#)

241 CNO – chronic non-bacterial osteomyelitis

242 CRMO - chronic recurrent multifocal osteomyelitis

243 CRP – C-reactive protein

244 DIRA – deficiency of interleukin-1 receptor antagonist

245 DMARD – disease-modifying anti-rheumatic drug

246 FCP – foetal calprotectin

247 HLA – human leukocyte antigen

248 IBD – inflammatory bowel disease

- 249 MRI – magnetic resonance imaging
- 250 NSAID – non-steroidal anti-inflammatory drug
- 251 SAPHO – synovitis, acne, pustulosis, hyperostosis, osteitis
- 252 TNFi – tumour necrosis factor inhibitor
- 253 WB-MRI – whole-body MRI

References

1. Bjorksten, B., Gustavson, K.H., Eriksson, B., Lindholm, A. & Nordstrom, S. Chronic recurrent multifocal osteomyelitis and pustulosis palmoplantaris. *J Pediatr* **93**, 227-31 (1978).
2. Giedion, A. Subacute and chronic "symmetrical" osteomyelitis. *Ann Radiol (Paris)* **15**, 329-342 (1972).
3. Jansson, A.F., Grote, V. & Group, E.S. Nonbacterial osteitis in children: data of a German Incidence Surveillance Study. *Acta Paediatr* **100**, 1150-7 (2011).
4. Zhao, Y. & Ferguson, P.J. Chronic Nonbacterial Osteomyelitis and Chronic Recurrent Multifocal Osteomyelitis in children. *Pediatr Clin North Am* **65**, 783-800 (2018).
5. Andronikou, S. et al. Whole-body MRI in the diagnosis of paediatric CNO/CRMO. *Rheumatology (Oxford)* **59**, 2671-2680 (2020).
6. Borzutzky, A. et al. Pediatric chronic nonbacterial osteomyelitis. *Pediatrics* **130**, e1190-7 (2012).
7. Wipff, J. et al. A large national cohort of French patients with chronic recurrent multifocal osteitis. *Arthritis Rheumatol* **67**, 1128-37 (2015).
8. O'Leary, D., Wilson, A.G., MacDermott, E.J., Lowry, C. & Killeen, O.G. Variability in phenotype and response to treatment in chronic nonbacterial osteomyelitis; the Irish experience of a national cohort. *Pediatr Rheumatol Online J* **19**, 45 (2021).
9. Girschick, H. et al. The multifaceted presentation of chronic recurrent multifocal osteomyelitis: a series of 486 cases from the Eurofever international registry. *Rheumatology (Oxford)* **57**, 1203-1211 (2018).
10. Zhao, Y. et al. Consensus treatment plans for Chronic Nonbacterial Osteomyelitis refractory to Nonsteroidal Antiinflammatory Drugs and/or with active spinal lesions. *Arthritis Care Res (Hoboken)* **70**, 1228-1237 (2018).
11. Cox, A.J. et al. Recessive coding and regulatory mutations in FBLIM1 underlie the pathogenesis of chronic recurrent multifocal osteomyelitis (CRMO). *PLoS One* **12**, e0169687 (2017).
12. d'Adamo, A.P. et al. High prevalence of rare FBLIM1 gene variants in an Italian cohort of patients with Chronic Non-bacterial Osteomyelitis (CNO). *Pediatr Rheumatol Online J* **18**, 55 (2020).
13. Ferguson, P.J. et al. Homozygous mutations in LPIN2 are responsible for the syndrome of chronic recurrent multifocal osteomyelitis and congenital dyserythropoietic anaemia (Majeed syndrome). *J Med Genet* **42**, 551-7 (2005).
14. Aksentijevich, I. et al. An autoinflammatory disease with deficiency of the interleukin-1-receptor antagonist. *N Engl J Med* **360**, 2426-37 (2009).
15. <https://omim.org/>.
16. Vittecoq, O. et al. Evolution of chronic recurrent multifocal osteitis toward spondylarthropathy over the long term. *Arthritis Rheum* **43**, 109-19 (2000).
17. Jansson, A. et al. Classification of non-bacterial osteitis: retrospective study of clinical, immunological and genetic aspects in 89 patients. *Rheumatology (Oxford)* **46**, 154-60 (2007).
18. Beck, C. et al. Chronic nonbacterial osteomyelitis in childhood: prospective follow-up during the first year of anti-inflammatory treatment. *Arthritis Res Ther* **12**, R74 (2010).
19. Kostik, M.M., Kopchak, O.L., Chikova, I.A., Isupova, E.A. & Mushkin, A.Y. Comparison of different treatment approaches of pediatric chronic non-bacterial osteomyelitis. *Rheumatol Int* **39**, 89-96 (2019).
20. Schnabel, A., Range, U., Hahn, G., Berner, R. & Hedrich, C.M. Treatment response and longterm outcomes in children with Chronic Nonbacterial Osteomyelitis. *J Rheumatol* **44**, 1058-1065 (2017).

21. Dushnicky, M.J. et al. Pediatric patients with a dual diagnosis of Inflammatory Bowel Disease and Chronic Recurrent Multifocal Osteomyelitis. *J Pediatr Gastroenterol Nutr* **73**, 626-629 (2021).
22. Sag, E. et al. Chronic recurrent multifocal osteomyelitis in children: a single center experience over five years. *Turk J Pediatr* **61**, 386-391 (2019).
23. Roderick, M.R., Shah, R., Rogers, V., Finn, A. & Ramanan, A.V. Chronic recurrent multifocal osteomyelitis (CRMO) - advancing the diagnosis. *Pediatr Rheumatol Online J* **14**, 47 (2016).
24. Khan, M.A. HLA-B27 and its subtypes in world populations. *Curr Opin Rheumatol* **7**, 263-9 (1995).
25. Chamot, A.M. et al. [Acne-pustulosis-hyperostosis-osteitis syndrome. Results of a national survey. 85 cases]. *Rev Rhum Mal Osteoartic* **54**, 187-96 (1987).
26. Gracey, E. et al. Revisiting the gut-joint axis: links between gut inflammation and spondyloarthritis. *Nat Rev Rheumatol* **16**, 415-433 (2020).
27. Zhao, D.Y., McCann, L., Hahn, G. & Hedrich, C.M. Chronic nonbacterial osteomyelitis (CNO) and chronic recurrent multifocal osteomyelitis (CRMO). *J Transl Autoimmun* **4**, 100095 (2021).
28. Myers, B. et al. The gut microbiome in psoriasis and psoriatic arthritis. *Best Pract Res Clin Rheumatol* **33**, 101494 (2019).
29. Verwoerd, A., Ter Haar, N.M., de Roock, S., Vastert, S.J. & Bogaert, D. The human microbiome and juvenile idiopathic arthritis. *Pediatr Rheumatol Online J* **14**, 55 (2016).
30. Ter Horst, R. et al. Host and environmental factors influencing individual human cytokine responses. *Cell* **167**, 1111-1124 e13 (2016).
31. Cantarelli, E., Baccelli, F., Simonini, G. & Alvisi, P. Chronic Recurrent Multifocal Osteomyelitis associated with Crohn Disease: A potential role of exclusion diet? Comment on Starz et al. The Modification of the gut microbiota via selected specific diets in patients with Crohn's Disease. *Nutrients* 2021, 13, 2125. *Nutrients* **13**(2021).
32. Pugliese, D. et al. Paradoxical psoriasis in a large cohort of patients with inflammatory bowel disease receiving treatment with anti-TNF alpha: 5-year follow-up study. *Aliment Pharmacol Ther* **42**, 880-8 (2015).
33. Rosenwasser, N., Lee, D., Sidbury, R. & Zhao, Y. Paradoxical Psoriasis in children receiving anti-TNFalpha treatment for inflammatory/autoimmune disease. *Paediatr Drugs* **23**, 131-141 (2021).
34. Prakken, B., Albani, S. & Martini, A. Juvenile idiopathic arthritis. *Lancet* **377**, 2138-49 (2011).
35. Thatayatikom, A., Modica, R. & De Leucio, A. Juvenile Idiopathic Arthritis. in *StatPearls* (Treasure Island (FL), 2022).

Acknowledgement

We would like to thank A. S. Knisely (Med Univ Graz, Austria) for critical comments and revision of the manuscript.

Funding

This study was supported by a grant from the Czech Health Research Council, Ministry of Health, Czech Republic (NU20-05-00320) and Ministry of Health, Czech Republic – conceptual development of research organization, Motol University Hospital, Prague, Czech Republic (00064203). MC and ZK were funded by Czech Science Foundation (19-0704S).

Author information

Contributions

DC designed the study, provided patient information and wrote the manuscript, HM provided patient information and reviewed manuscript, VK re-assessed X-ray and WBMR imaging and reviewed manuscript, ZK performed statistical analyses, OS contributed to data analyses and reviewed the manuscript, LW provided patient data and reviewed the manuscript, JB contributed to data analyses and reviewed the manuscript, ZŠ contributed to data analyses and reviewed the manuscript, MK re-assessed X-ray and WBMR imaging, provided WBMR pictures for Fig. 5B and reviewed manuscript, MC contributed to the critical revisions of manuscript, data analyses and prepared the figures and tables, RH contributed to data analyses and reviewed the manuscript. All authors agreed with final version of the manuscript.

Corresponding author

Correspondence to Dita Cebecauerova (Dita.Cebecauerova@fnmotol.cz).

Ethics declarations

Ethics approval and consent to participate

All participants or their legal guardians gave written consent in participating in the study. The study was performed as an retrospective cohort study according to the principles of the Declaration of Helsinki and was approved by the local ethics committee at the University Hospital Motol (protocol No. EK 1412/20).

Figure legends

Figure 1. A graphical scheme summarising critical findings in our cohort. CRP – C-reactive protein, DMARD - disease-modifying antirheumatic drugs, ESR - erythrocyte sedimentation rate, IBD – inflammatory bowel disease, NSAID - non-steroidal anti-inflammatory drugs, TNFi – tumour necrosis factor α inhibitors.

Figure 2. Autoimmunity profiles. A) Summary of total autoimmune disease manifestations in the first- and second-degree relatives and of **B)** extraosseous comorbidities in CRMO patients. CGD – chronic granulomatous disease, GPA – granulomatosis with polyangiitis, HSP – Henoch-Schönlein purpura, IBD – inflammatory bowel disease, PD – phagocytic dysfunction, PPP – palmoplantar pustulosis, PSC – primary biliary cirrhosis RA – rheumatoid arthritis

Figure 3. Vertebral and sacroiliac involvement. HLA-B27 positive children with CRMO displayed sacroiliac involvement less frequently than spinal involvement. Vertebral lesions were twice as frequent as in the cohort. Sacroiliitis in HLA-B27 positive CRMO was less frequent than sacroiliitis in HLA-B27 negative CRMO children and in non-selected CRMO children.

Figure 4. Comparison of laboratory characteristics between osteolytic and complex CRMO patients. A. Charts comparing blood markers, white blood count, platelets, haemoglobin, and mean cell volume (MCV) for the two groups of CRMO patients. Data are presented as boxplots with the 25th, 50th (median), and 75th percentiles marked. Whiskers extend to the most extreme data points. Squares represent individual patients. An asterisk (*) indicates statistical significance ($p < 0.05$). **B.** Comparison of inflammatory markers, number of lesions, and age at onset between osteolytic and complex CRMO. Data are presented as boxplots with the 25th, 50th (median), and 75th percentiles marked. Whiskers extend to the most extreme data points. Squares represent individual patients. An asterisk (*) and two asterisks (**) indicate statistical significance ($p < 0.05$ and $p < 0.01$, respectively).

Figure 5. Distribution of CRMO lesions in osteolytic CRMO patients (left) and complex CRMO patients (right). A. Frequencies $\geq 35\%$ are considered important (bold). P-values for each site are summarized in Table 3. **B.** Dominant patterns (red) of affected bones in osteolytic CRMO (left) and complex CRMO (right) with illustrative cases of WB-MRI. Arrowheads indicate main affected sites.

Figure 6. Treatments applied in patients with osteolytic (dark grey) and complex (light grey) CRMO. NSAID - non-steroidal anti-inflammatory drugs, DMARDs – disease modifying antirheumatic drugs, CS – corticosteroids, BIS – bisphosphonates, TNFi – tumour necrosis factor α inhibitors

Tables

Table 1. Demographic and clinical characteristics of the cohort

Total number of patients	37
Female	30 (81%)
Male	7 (19%)
Ethnicity	
- Romani	4 (11%)
- Other Czech	33 (89%)
Age at onset, years; median (range)	10 (4.6 – 17.3)
Number of lesions; median (range)	7 (1-19)
Skeletal involvement	
- Unifocal	3 (8%)
- Multifocal	34 (92%)
Initial symptom	
- Back pain	14 (38%)
- Limb pain	19 (51%)
- Other	4 (11%)
Bone biopsy	23 (62%)
Spinal lesions	14 (38%)
- Spinal surgery	7 (19%)
Sacroiliac joint involvement	13 (35%)
Inflammatory bowel disease	8 (22%)
Psoriasis / palmoplantar pustulosis	3 (8%)
Nodulocystic acne	3 (8%)
Unspecific dermatitis involvement	3 (8%)
Autoimmune comorbidities in family history	25 (68%)
- First-degree (I) relatives	15
- Second-degree (II) relatives	13
Anti-nuclear antibodies present	2 (5%)
HLA-B27 present	6 (16%)

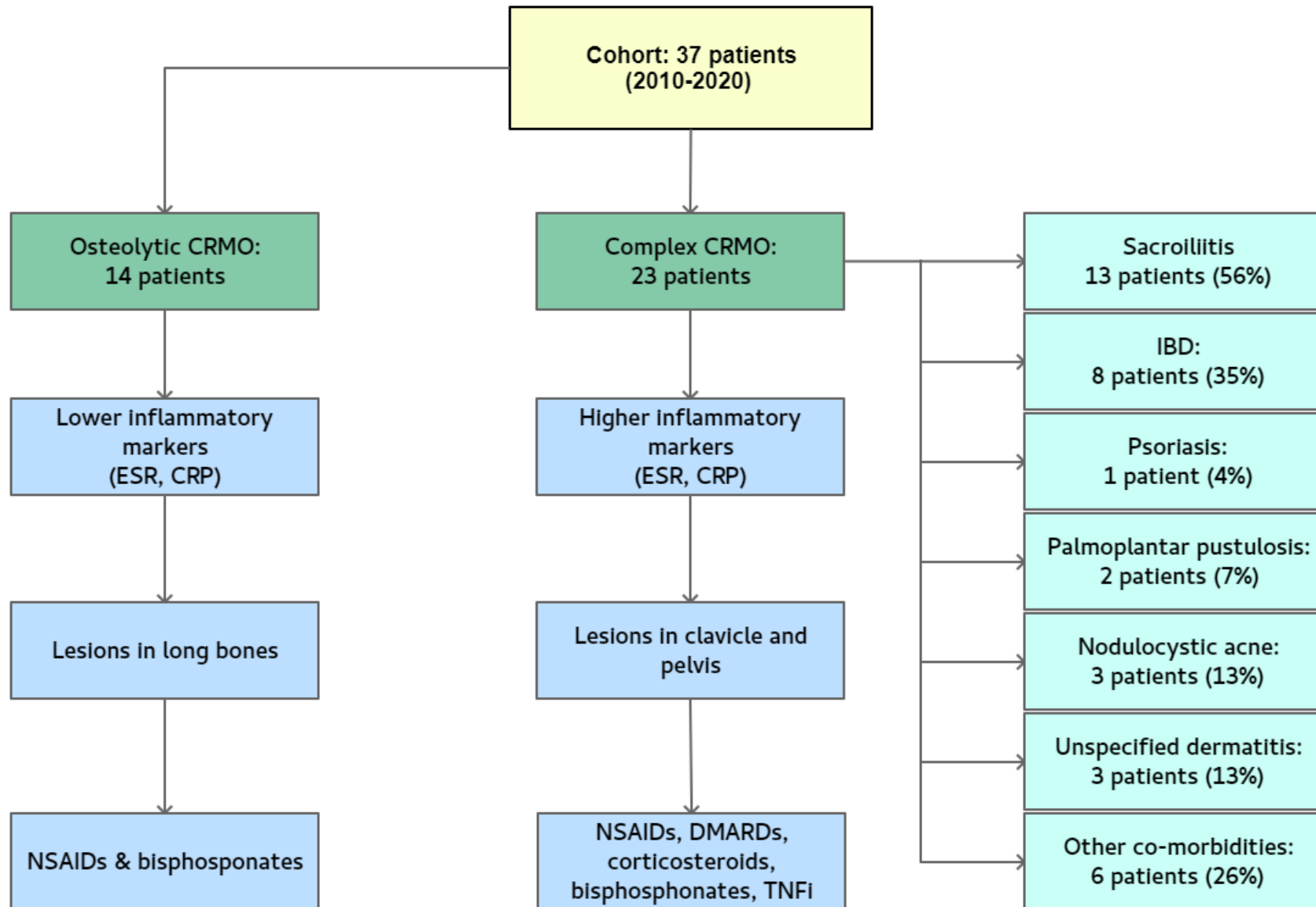
No.	Gender	No. foci	Autoantibodies	Histology	Disease course	Delay (years)	Therapy	Outcome	HLA-B27	FCP (µg/g)	Family history
1.	F	7	ASCA positive	NS colitis	1. CRMO, arthritis 2. colitis + CRMO relapse	5.0	SSZ --> P-->ADA+MTX --> none	remission, now without therapy	negative	1000	II. HLA-B27 AS
2.	M	10	p-ANCA positive	CD	1. IBD 2. PPP 3. CRMO + IBD relapse	4.0	AZA, IFX, IFX+MTX -->ADA	relapsing IBD and CRMO	negative	1736	I. IBD
3.	F	2	ASCA positive	CD	1. CRMO, arthritis 2. IBD 3. HSP 4. acute uveitis	0.5	SSZ --> ETA+MTX --> ADA, AZA	remission on therapy	positive	350	I. IBD
4.	F	9	ASCA positive	CD	1. IBD 2. CRMO+PPP	4.0	AZA -->IFX-->ADA-->ADA+SSZ-->ADA+MTX+SSZ	remission on therapy	negative	3329	II. psoriasis
5.	F	3	p-ANCA positive	UC	1. IBD 2. relapsed IBD+CRMO	2.5	P+AZA-->5-ASA-->ADA+MTX	remission on therapy	negative	938	negative
6.	F	11	negative	UC, PSC	1. IBD, PSC 2. CRMO	4.0	5-ASA, UDCA, PAM-->ADA	active CRMO, IBD in remission	negative	1680	II. IBD
7.	M	7	p-ANCA positive	CD	1. CRMO, arthritis 2. IBD (arthritis and CRMO in remission)	7.5	NSAID--> SSZ, P, MTX --> ADA	active IBD, CRMO in remission	negative	1230	unknown
8.	M	9	negative	CD	1. CRMO 2. IBD (CRMO in remission)	4.0	NSAID--> P-->5-ASA-->non-compliance	active IBD, CRMO in remission	negative	545	I. IBD, II. psoriasis

Table 2. Characteristics of patients with enteropathic chronic recurrent multifocal osteomyelitis

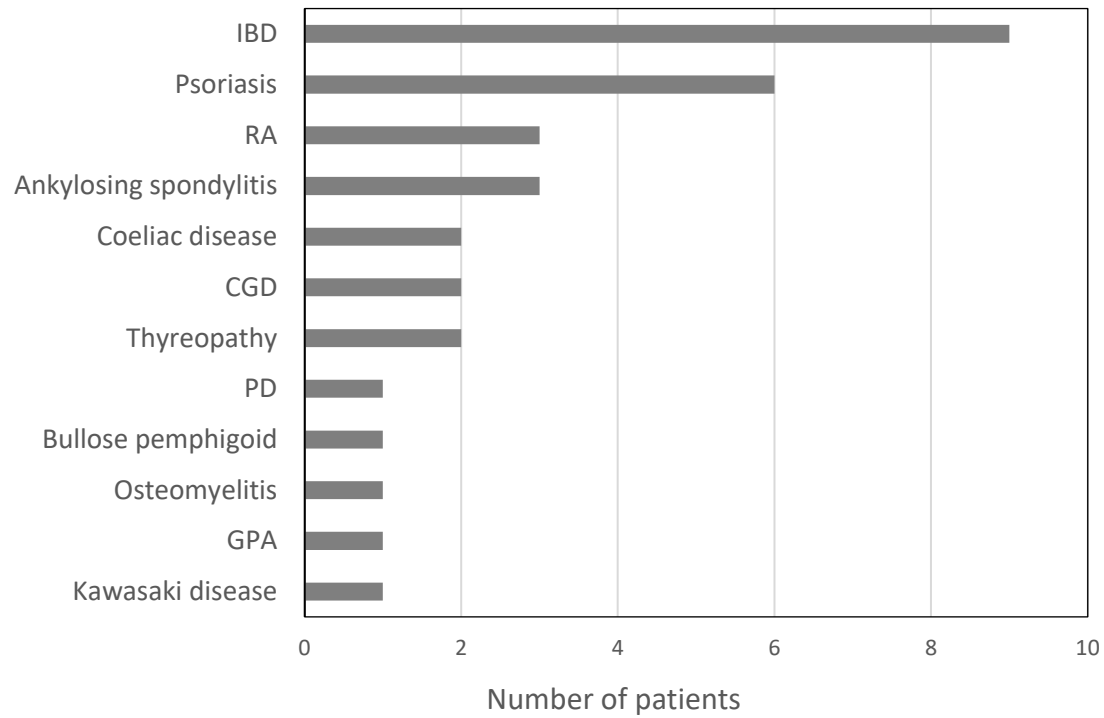
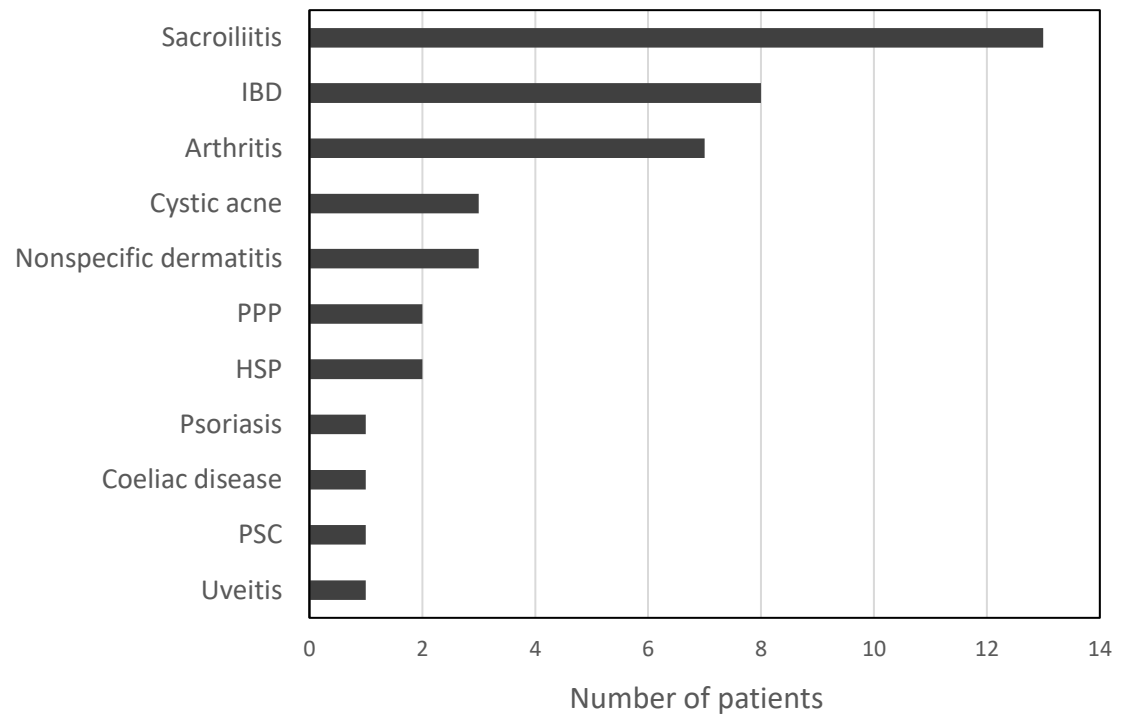
Abbreviations: ADA – adalimumab, ANCA – anti-neutrophil cytoplasmic antibody, ASCA – anti-*Saccharomyces cerevisiae* antibody, 5-ASA – 5-aminosalicylic acid, AZA – azathioprine, CD – Crohn disease, CRMO – chronic recurrent multifocal osteomyelitis, ETA – etanercept, FCP – foetal calprotectin, I. – first-degree relative, II. – second-degree relative, HLA-B27 – human leucocyte antigen B27, HLA-B27 AS – HLA-B27 positive ankylosing spondylitis, IBD – inflammatory bowel disease, IFX – infliximab, MTX – methotrexate, NS colitis – non-specific colitis, NSAID – non-steroidal anti-inflammatory drug, P – prednisone, PAM – pamidronate, PPP – palmo-plantar pustulosis, PSC – primary sclerosing cholangitis, SSZ – sulphasalazine, UC – ulcerative colitis, UDCA – ursodeoxycholic acid.

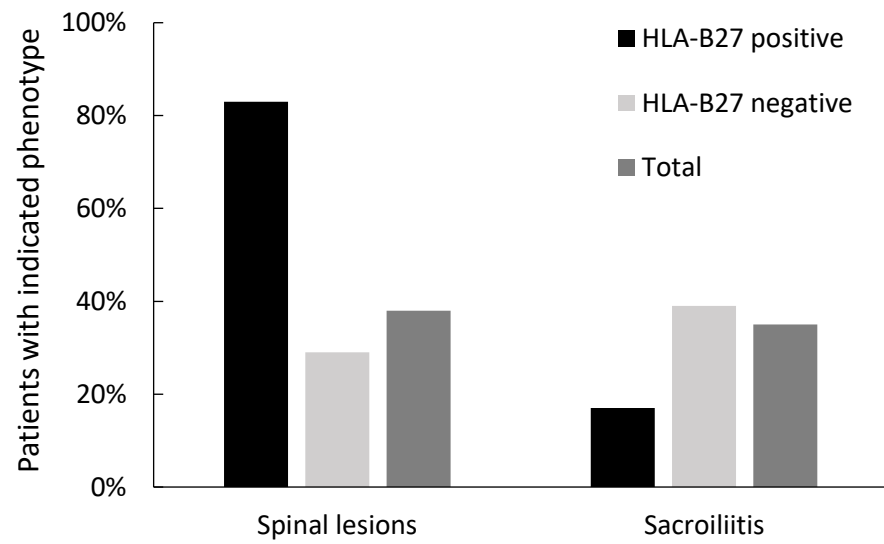
Table 3. Distribution of lesions in patients with osteolytic and complex CRMO

Affected site	Osteolytic CRMO (no = 14)	Complex CRMO (n = 23)	P value
skull	1	1	1.000
mandible	2	0	0.137
scapula	1	1	1.000
clavicle	1	12	0.011
sternum	1	6	0.217
humerus	5	3	0.215
radius	3	3	0.653
ribs	3	2	0.346
spine	6	8	0.732
pelvis (incl. sacrum)	5	17	0.038
femur	7	11	1.000
tibia	9	7	0.086
fibula	2	3	1.000
talus	2	3	1.000
calcaneus	4	2	0.173
feet with digits	7	6	0.171

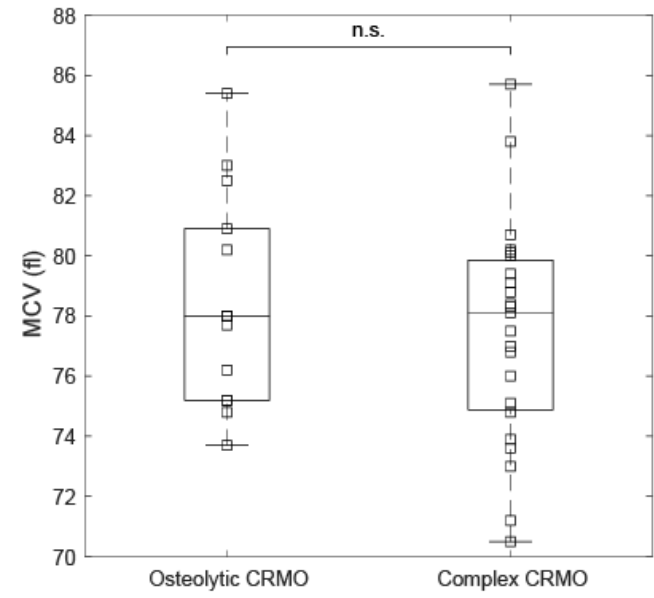
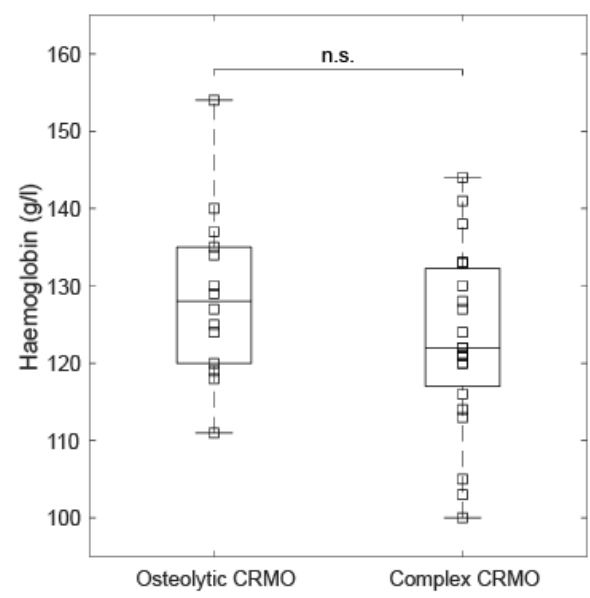
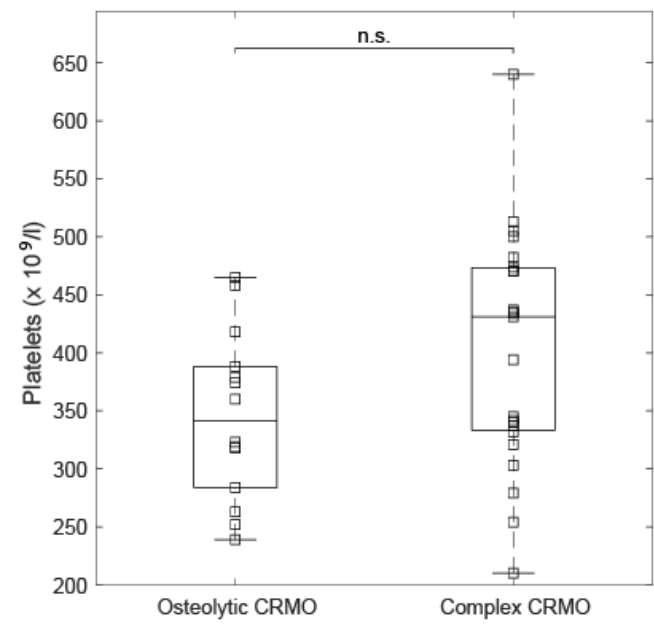
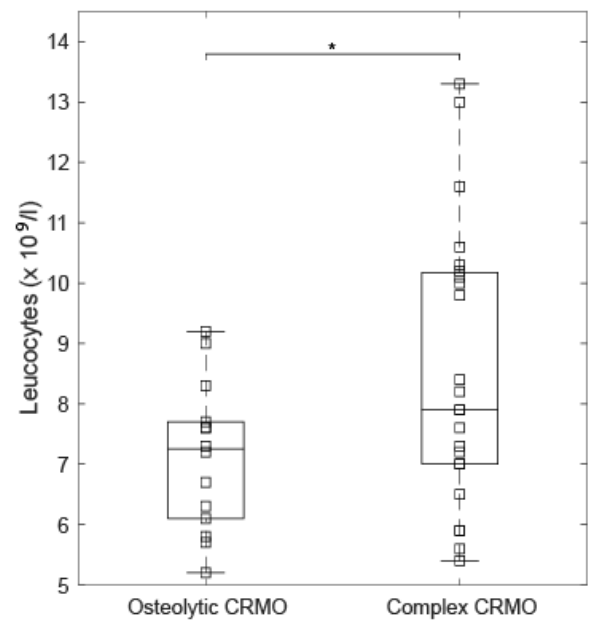


Cebecauerova Figure 1

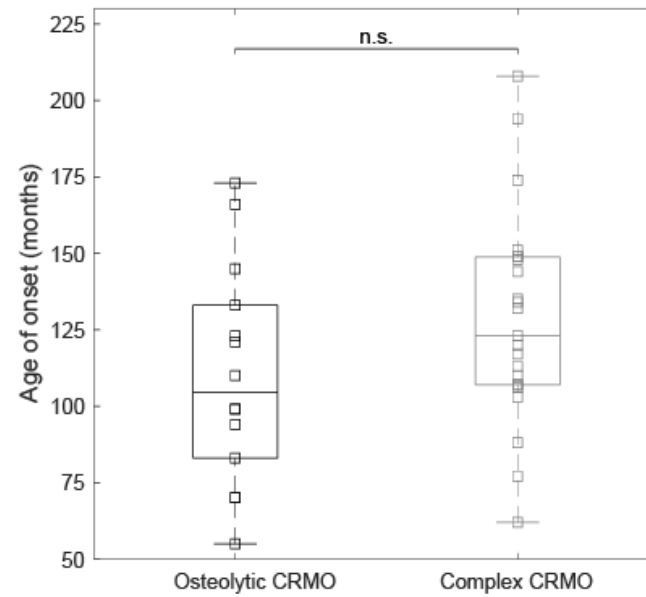
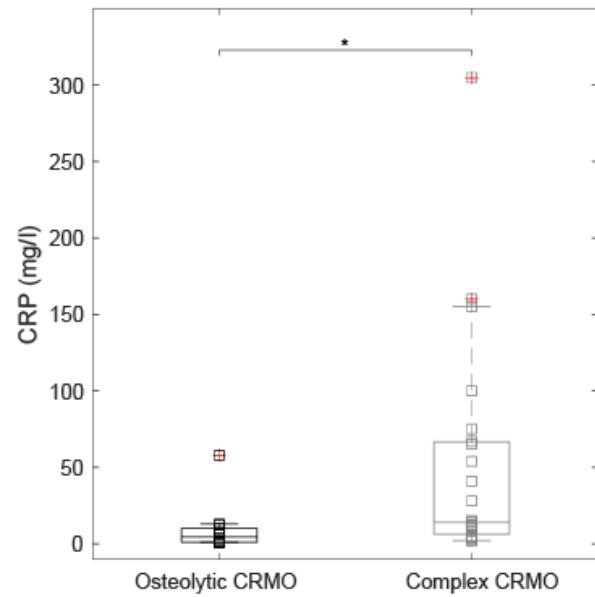
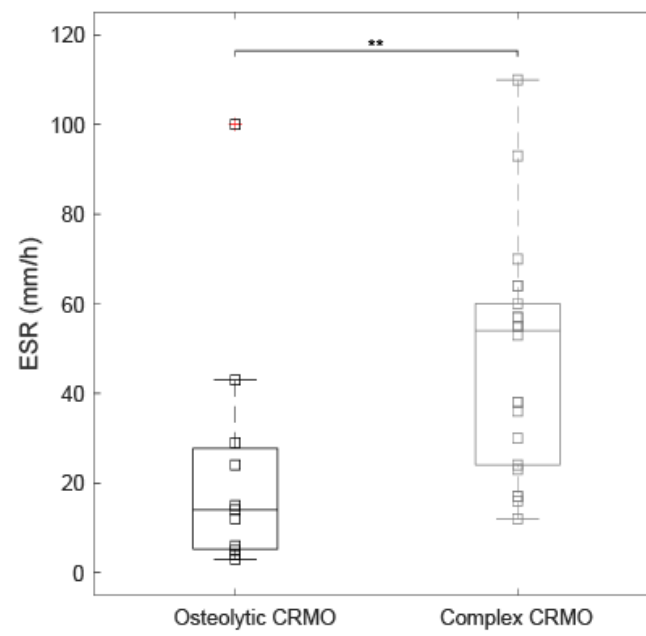
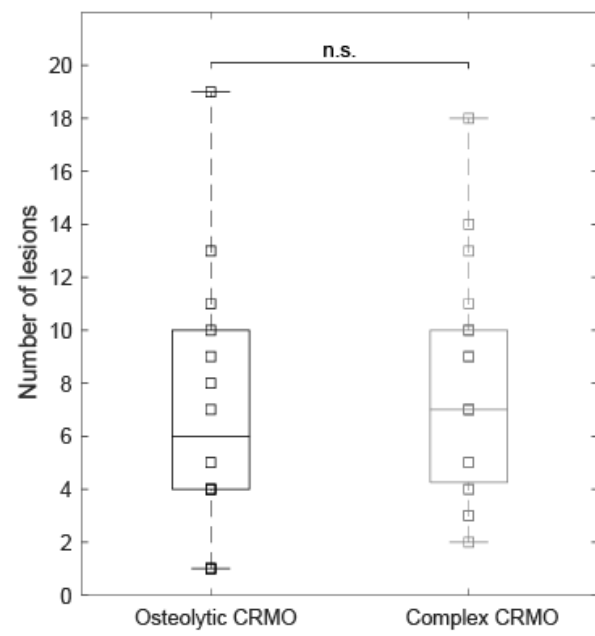
A**Autoimmune diseases in first- or second-degree relatives****B****Extraosseous manifestations**



Cebecauerova Figure 3



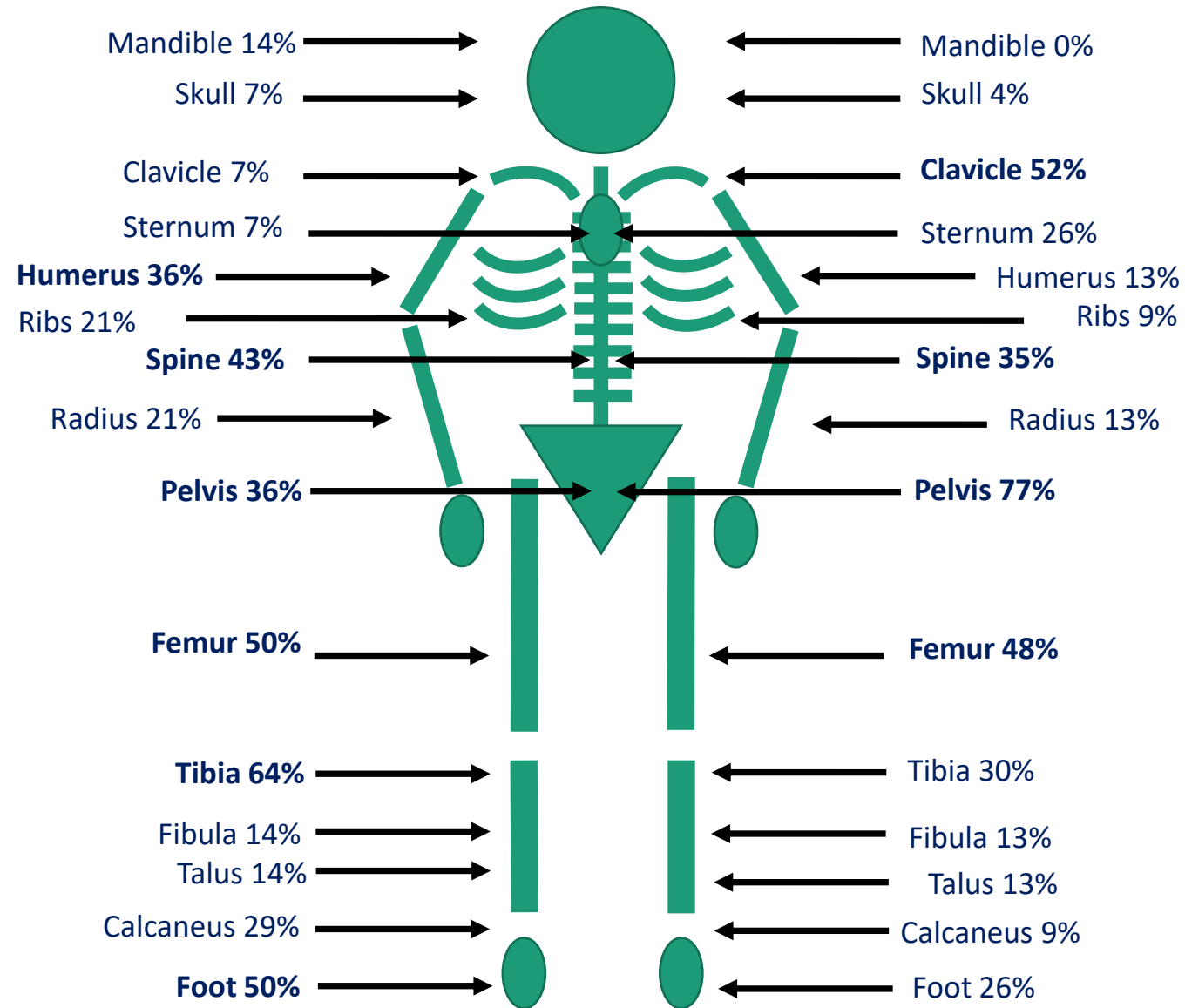
Cebecauerova Figure 4A

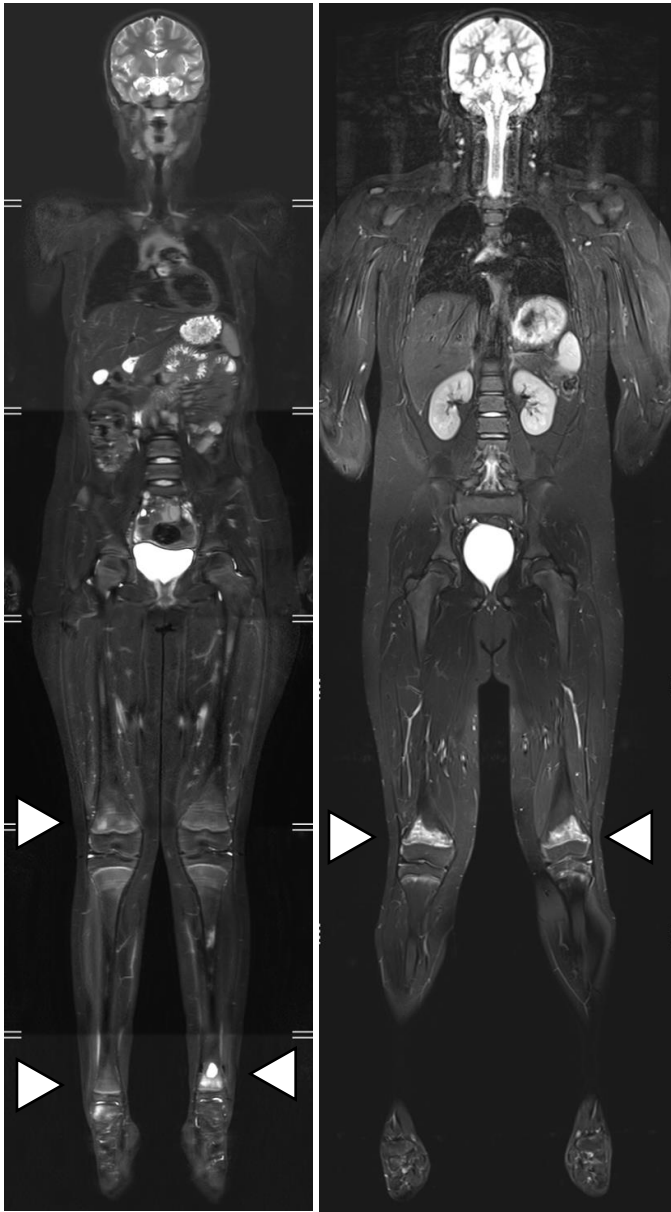


Cebecauerova Figure 4B

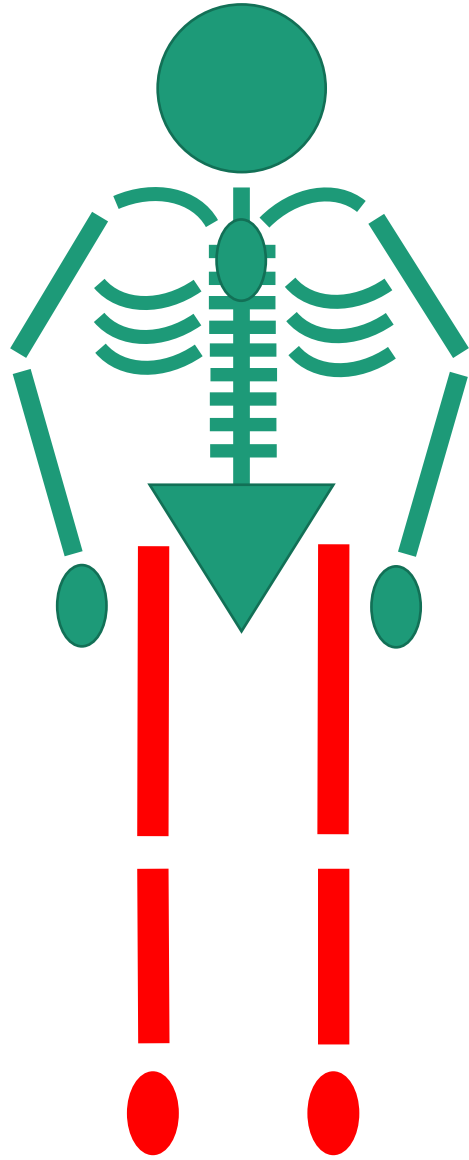
Osteolytic CRMO (14 patients)

Complex CRMO (23 patients)

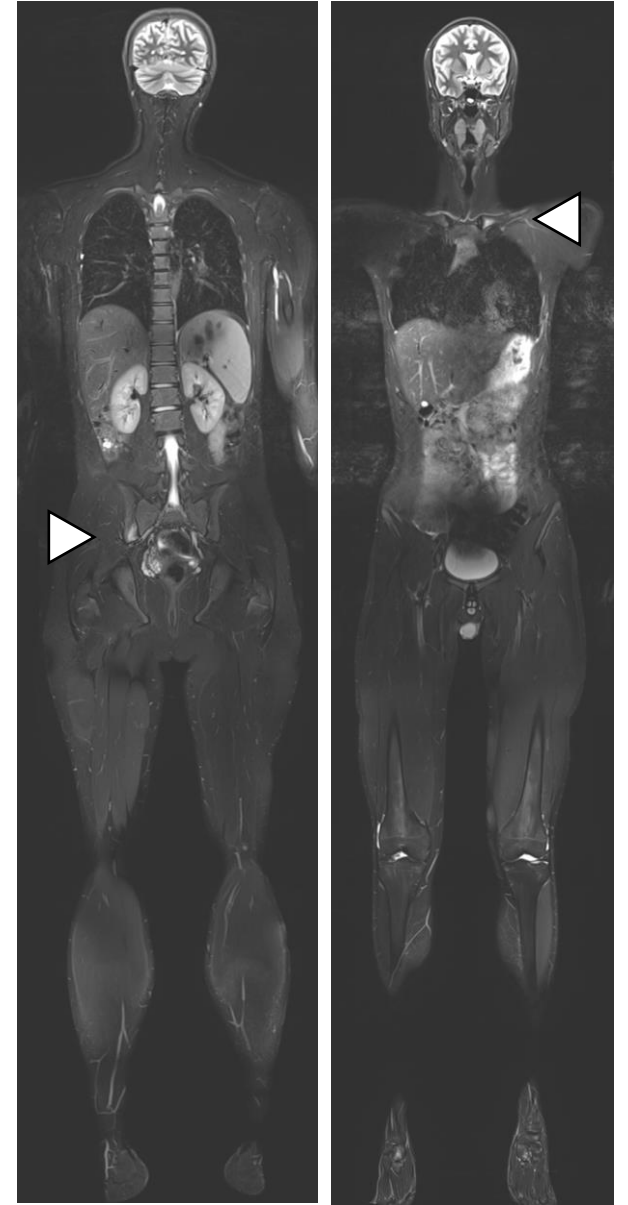
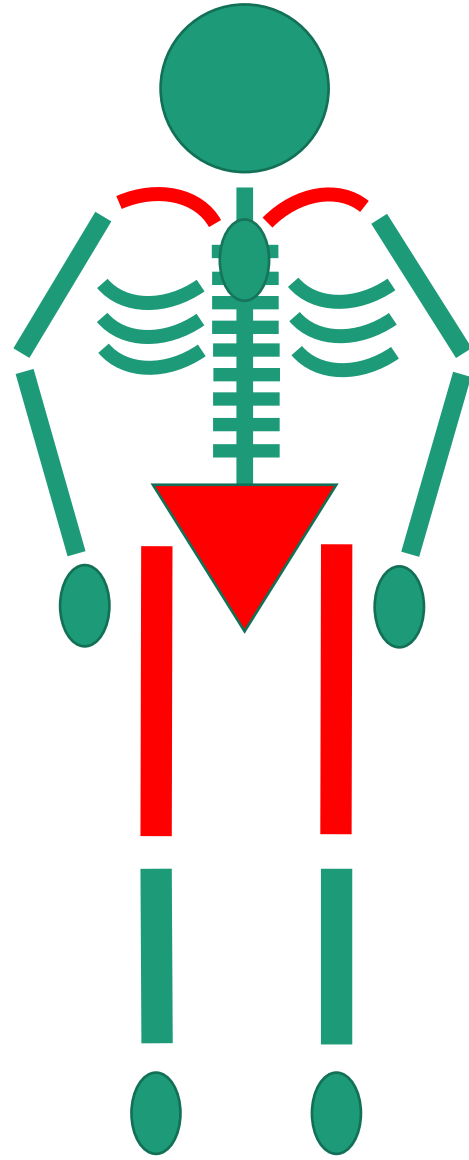




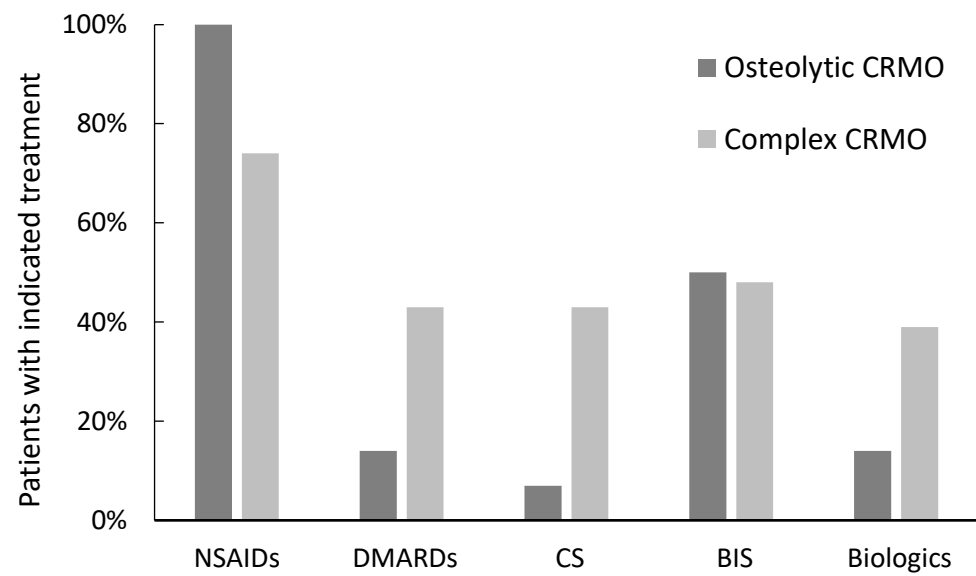
Osteolytic CRMO



Complex CRMO



Cebecauerova Figure 5B



Cebecauerova Figure 6