

1 **Intraoperative calculus or hemorrhage in transurethral seminal vesiculoscopy as a risk factor for**  
2 **recurrent hemospermia**

3 Cheng-En Mei<sup>1,2</sup>, Ju-Chuan Hu<sup>2</sup>, Jian-Ri Li<sup>2</sup>, Kun-Yuan Chiu<sup>2</sup>, Shian-Shiang Wang<sup>2</sup>, Chuan-Shu Chen<sup>2</sup>

4 \*

5 <sup>1</sup>Division of Traumatology, Department of Emergency Medicine, Taichung Veterans General

6 Hospital, Taichung, Taiwan

7 <sup>2</sup>Division of Urology, Department of Surgery, Taichung Veterans General Hospital, Taichung,

8 Taiwan

9

10 \* Corresponding author

11 E-mail: r2060d@gmail.com (CSC)

## 12 **Abstract**

13           We summarized our experience regarding Transurethral Seminal Vesiculoscopy (TUSV) and  
14 analyzed both recurrence status and risk factors for recurrence. From January 2010 to December  
15 2020, 48 patients with intractable hemospermia received successful TUSV at Taichung Invalids  
16 General Hospital. For the intraoperative findings, the five-year Disease-free Survival rates (DFS)  
17 were 74.1% in the no calculus group compared to 37.1% in the calculus group with a significant  
18 difference (log-rank  $p = 0.015$ ), 75.0% in the no hemorrhage or no blood clot group compared to  
19 43.2% in the hemorrhage or blood clot group with significant difference (log-rank  $p = 0.032$ ).  
20 Univariate analysis showed intraoperative calculus ( $p = 0.040$ ; HR: 2.94, 95% CI: 1.05–8.21) to be  
21 significantly associated with recurrence ( $p < 0.05$ ). Patients with intractable hemospermia who  
22 were diagnosed with stones or blood clots found during TUSV experienced a higher rate of  
23 hemospermia recurrence.

## 24 **Introduction**

25       Hemospermia, hematospermia, or haematospermia is defined as blood appearance in the  
26 semen. [1] The symptom usually resolves spontaneously in most cases. The mechanisms  
27 surrounding the occurrence of hemospermia can be inflammation, infection, lithiasis, cyst  
28 formation, obstruction, tumor, vascular related, trauma, iatrogenic related and systemic origin.  
29 Recommended imaging studies include Transrectal Ultrasound (TRUS), Computed Tomography  
30 (CT), and Magnetic Resonance Imaging (MRI). [2] TRUS is less expensive and less diagnostic than  
31 the other tests, but is more commonly used as a diagnostic tool. [3, 4]

32       Through advancements in endoscopy technology, in vivo Transurethral Seminal Vesiculoscopy  
33 (TUSV) was first introduced in 2002. [5] Subsequently, TUSV has been used as a diagnostic and  
34 treatment procedure for recurrent hemospermia, persistent hemospermia and intractable  
35 hemospermia, with symptoms persisting over 3 months regardless of medical treatment. [6-11]  
36 TUSV also has a higher diagnostic rate than TRUS. [3]

37       The recurrence rate after TUSV treatment has been mentioned to be in a range from 3.4% to  
38 11.76%. [6-11] To the best of our knowledge, there are currently no studies investigating  
39 recurrence after TUSV. In this study, we sorted through 48 successful cases and analyzed their  
40 recurrence status and risk factors for recurrence.

## 41 **Materials and Methods**

### 42 **Patients**

43 This study enrolled patients who had intractable hemospermia and received successful TUSV  
44 treatment during the period from January 2010 to December 2020 in Taichung Veterans General  
45 Hospital, Taiwan, Republic of China. The diagnosis of hemospermia relied on photos of semen  
46 which patients took after sexual activity. The enrolled patients took serum Prostate-specific  
47 Antigen (PSA), coagulation tests and TRUS.

48 For the treatment of hemospermia, an empiric antibiotic ciprofloxacin, 400 mg every 12  
49 hours per os (PO), was administered for at least 2 weeks. For patients with intractable  
50 hemospermia who were willing to undergo surgery to relieve symptoms, we provided TUSV.

51 The study protocol conformed to the ethical guidelines of the 1975 Declaration of Helsinki  
52 and was granted by the ethics committee of Taichung Veterans General Hospital, Taiwan, Republic  
53 of China. The institutional review board number was CE22060A.

### 54 **Surgical techniques**

55 Each patient received either general anesthesia or spinal anesthesia and was placed in the  
56 lithotomy position. A semi-rigid ureteroscope (6/7.5-Fr; Olympus, Tokyo, Japan) was inserted into  
57 the urethra and introduced to the verumontanum. The bilateral seminal vesicles were then  
58 entered through the ejaculation duct or fenestrated from the utricle. Intraoperative  
59 manifestations, such as Calculus, hemorrhage, mucosal lesion, were recorded. Seminal vesicle fluid  
60 would then be collected for a culture exam. Calculus removal or a biopsy would be performed

61 depending on intraoperative manifestations. After the procedure, 10ml normal saline with 80mg  
62 gentamycin irrigation into the seminal vesicle would then be done. [9]

### 63 **Statistical analysis**

64 Numeric variables are expressed as medians (interquartile ranges) and subsequently  
65 compared using the Chi-square test, with significance set at  $p < 0.05$ . Continuous variables are  
66 presented as medians (ranges) and compared using the Mann-Whitney U test, with significance  
67 also set at  $p < 0.05$ . Rates of Disease-free Survival (DFS) up to January 2022 were calculated using  
68 the Kaplan-Meier life table method and compared across groups using the log-rank test.  
69 Differences with  $p$  values  $< 0.05$  were regarded as statistically significant. Univariate and  
70 multivariate analysis utilizing Cox proportional hazard ratios were derived for the outcomes of  
71 interest. All  $p$  values  $< 0.05$  were considered significant in univariate analysis and thus included in  
72 multivariate analyses.

## 73 **Result**

74 Forty-eight (48) patients diagnosed with intractable hemospermia who underwent successful  
75 TUSV were studied. All patients achieved remission. Sixteen (16) patients (33.3%) underwent  
76 recurrence up until January 2022. The characteristics between recurrence and non- recurrence are  
77 shown in Table 1. In TURS findings, 22 non-recurrent patients (68.8%) experienced overall calculus,  
78 while 13 recurrent patients (86.7%) had overall calculus. Eight non-recurrent patients (25%) had  
79 Seminal Vesicle (SV) or ejaculation duct calculus, while 2 recurrent patients (13.3%) had SV or  
80 ejaculation duct calculus. The median time of follow-up was 39.4 months in the non- recurrent  
81 group and 49.8 months in the recurrent group. Complications such as epididymitis occurred in only  
82 2 cases in the non-recurrent group. The median follow-up period was 40.1 months (range,  
83 0.95–134.5 months).

**Table 1. Characteristics of patients between recurrence and non-recurrence.**

Total (n=48)	Non-recurrence (n=32)	Recurrence (n=16)	p value
<b>Age</b>	<b>54.5</b> (48.3-63.8)	53.5 (38.3-58.8)	0.330
<b>Duration (months)</b>	<b>12.0</b> (4.0-23.3)	13.0 (6.0-24.0)	0.676
<b>Diabetes mellitus</b>	<b>2</b> (6.3%)	1 (6.3%)	1.000
<b>Hypertension</b>	<b>6</b> (18.8%)	4 (25.0%)	0.712
<b>Previous urinary tract infection</b>	<b>2</b> (6.3%)	1 (6.3%)	1.000
<b>Urolithiasis history</b>	<b>5</b> (15.6%)	1 (6.3%)	0.648
<b>Erectile dysfunction</b>	<b>4</b> (12.5%)	1 (6.3%)	0.652
<b>Sexually transmitted disease</b>	<b>1</b> (3.1%)	0 (0.0%)	1.000
<b>Anti-platelet agent</b>	<b>2</b> (6.3%)	3 (20.0%)	0.309
<b>PSA</b>	<b>1.1</b> (0.6-1.4)	1.0 (0.7-1.7)	0.803
<b>Digital rectal examination</b>			
Elastic consistency	<b>32</b> (100%)	16 (100%)	--
Hard consistency	<b>0</b> (0%)	0 (0%)	--
<b>TRUS findings</b>			
Overall calcification	22 (68.8%)	13 (86.7%)	0.288
Prostate calculus	19 (59.4%)	13 (86.7%)	0.094
SV or ejaculation duct calculus	8 (25.0%)	2 (13.3%)	0.465
<b>Post operative complication</b>			
Epididymitis	2 (6.3%)	0 (0.0%)	0.546
Perineal pain	0 (0.0%)	0 (0.0%)	--
<b>Follow-up period (months)</b>	39.4 (1.6-66.1)	49.8 (20.9-96.7)	0.120
<b>Time to remission (weeks)</b>	4.0 (3.0-4.0)	4.0 (4.0-7.75)	0.097

Chi-square test or Mann-Whitney U test, Median (IQR). \* $p < 0.05$ , \*\* $p < 0.01$

Numeric variables expressed as medians (interquartile ranges)

Seminal vesicle (SV)

## 85 Intraoperative findings

86 Intraoperative findings of TUSV between the recurrence and non-recurrence groups are  
87 shown in Table 2. Overall calculus was found in the utricle or SV in 10 non-recurrent patients  
88 (31.3%) and 9 recurrent patients (56.3%). Hemorrhage was found in the utricle or SV in 11  
89 non-recurrent patients (34.4%) and 10 recurrent patients (62.5%).

**Table 2. Intraoperative findings of TUSV between recurrence and non-recurrence.**

Total (n=48)	Non-recurrence (n=32)	Recurrence (n=16)	p value
<b>Intraoperative findings</b>			
<b>Overall calculus</b>	10 (31.3%)	9 (56.3%)	0.175
<b>Utricle</b>	10 (31.3%)	7 (43.8%)	0.594
<b>Left SV</b>	3 (10.0%)	4 (26.7%)	0.199
<b>Right SV</b>	2 (6.9%)	1 (6.3%)	1.000
<b>Hemorrhage or blood clot</b>	11 (34.4%)	10 (62.5%)	0.123
<b>Utricle</b>	2 (6.3%)	0 (0.0%)	0.546
<b>Left SV</b>	6 (20.7%)	7 (46.7%)	0.092
<b>Right SV</b>	4 (14.3%)	5 (31.3%)	0.250

Chi-square test. \* $p < 0.05$ , \*\* $p < 0.01$

Seminal vesicle (SV)

## 90 Disease free survival

91 Regarding the TRUS findings, five-year Disease-free Survival (DFS) rates were 75.0% in the no  
92 calculus group compared to 59.0% in the overall calculus group, with the Kaplan–Meier survival  
93 curves represented in Fig 1 (log-rank  $p = 0.273$ ). The five-year DFS rates were 54.5% in the no SV or  
94 ejaculation duct calculus group compared to 100.0% in the SV or ejaculation duct calculus group,  
95 with the Kaplan–Meier survival curves represented in Fig 2 (log-rank  $p = 0.227$ ). In this study, the  
96 five-year DFS rates taken from the TRUS findings were insignificantly different.



97 **Fig 1. Kaplan–Meier curves of the disease-free survival rates by TRUS findings of overall**

98 **calcification.** No calcification compared to overall calcification

99 **Fig 2. Kaplan–Meier curves of the disease-free survival rates by TRUS findings of SV or**

100 **ejaculation duct stone.** No Seminal vesicle (SV) or ejaculation duct calculus compared to SV or

101 ejaculation duct calculus.

102 For the intraoperative findings, the five-year DFS rates were 74.1% in the no calculus group

103 compared to 37.1% in the calculus group, with the Kaplan–Meier survival curves represented in Fig

104 3 (log-rank  $p = 0.015$ ). The five-year DFS rates were 75.0% in the no hemorrhage or blood clot

105 group compared to 43.2% in the hemorrhage or blood clot group, with the Kaplan–Meier survival

106 curves represented in Fig 4 (log-rank  $p = 0.032$ ). The five-year DFS rates were 73.7% in the

107 negative intraoperative finding group compared to 47.7% in the positive intraoperative finding

108 group, with the Kaplan–Meier survival curves represented in Fig 5 (log-rank  $p = 0.093$ ). In this study,

109 the five-year DFS rates were significant higher in the intraoperative no calculus group when

110 compared to the calculus group, and in the no hemorrhage or blood clot group when compared to

111 the hemorrhage or blood clot group. The five-year DFS rate was insignificant but trending upward

112 in intraoperative negative findings when compared to positive findings.

113 **Fig3. Kaplan–Meier curves of the disease-free survival rates by intraoperative findings of**

114 **calculus.** No calculus compared to overall calculus.

115 **Fig4. Kaplan–Meier curves of the disease-free survival rates by intraoperative findings of**

116 **hemorrhage or blood clot.** No hemorrhage or blood clot compared to hemorrhage or blood clot.

117 **Fig5. Kaplan–Meier curves of the disease-free survival rates by intraoperative findings.** Negative  
118 intraoperative finding compared to positive intraoperative finding.

119 Univariate analysis showed intraoperative calculus ( $p = 0.040$ ; HR: 2.94, 95% CI: 1.05–8.21) to  
120 be significantly associated with recurrence, and intraoperative hemorrhage or blood clot ( $p =$   
121 0.068; HR: 2.63, 95% CI: 0.93–7.43) to be insignificant but trending upward with recurrence.

122 Multivariate Cox proportional hazard analysis showed intraoperative calculus ( $p = 0.051$ ; HR: 2.80,  
123 95% CI: 1.00–7.90) to be insignificant but trending upward with recurrence.

## 124 **Discussion**

### 125 **Effectiveness of preoperative imaging**

126 TRUS has been mentioned in other studies as having a lower diagnostic yield for hemospermia.  
127 [3] In this study, preoperative TRUS provided a low SV or ejaculatory duct stone detection. TUSV  
128 provides better diagnostic rates than a TRUS exam alone. This result is consistent with previous  
129 research findings. In this study, TRUS results showed no significant difference in DFS. TRUS  
130 findings also failed to provide an association with recurrence prediction. Although TRUS is  
131 relatively less invasive and carries less cost, the diagnostic significance and benefit of TRUS in  
132 patients with persistent hemospermia requires additional follow-up studies.

## 133 **Recurrence and hypothesis of hemospermia**

134       The recurrence rate after TUSV treatment is mentioned as being in the range of 3.4% to  
135 11.76%. [6-11] Amongst the 48 patients in this study, 16 had recurrent hemospermia, with the  
136 recurrence rate being 33.33%, which was higher than other studies. However, the median  
137 follow-up time in our study was 40.1 months, while the follow-up time in other studies was 5-24  
138 months. [6-11] Compared with the previous study performed in our hospital, the follow-up time  
139 was 12 months, with 4 of 34 patients experiencing recurrence at a rate of 11.76%. [9] Our patients  
140 were more regionalized so follow-up at the same hospital was easier. The high recurrence rate  
141 may be related to the long follow-up time.

142       In our study, recurrence-free survival from intraoperative detected stones, hemorrhages, or  
143 blood clot was significantly lower when compared with the undetected group. The current  
144 hypothesis is that the occurrence of hemospermia, calculus, strictures and inflammation is a  
145 vicious cycle. [3, 12] According to that hypothesis, TUSV could interrupt the vicious cycle in  
146 addition to providing a diagnosis. For patients with negative intraoperative findings, we believe  
147 that TUSV can block the vicious cycle of stricture and inflammation, thus resulting in symptom  
148 relief with low recurrence rates. Inflammation may be worse in patients experiencing stones,  
149 hemorrhage, or blood clots as detected by TUSV. Fortunately, TUSV can still stop the vicious  
150 cycle and relieve symptoms. Because the inflammation is more severe, the possibility of  
151 hemospermia recurrence will also increase.

## 152 **Success rate**

153       The success rate of TUSV treatment, as mentioned in the relevant literature, ranges from  
154 90.9% to 96.53%.[8, 9, 11] In this study, 51 patients underwent TUSV, while 6 of them received  
155 second TUSV due to recurrent hemospermia. Among the total 57 TUSV treatments, 54 of which  
156 were successfully performed. Such a success rate of 94.7% is comparable with the studies  
157 reported in the relevant literature. The 3 patients whose TUSV failed all received MRI exams. It  
158 turned out that one of them had a seminal vesicle cyst, while the other 2 patients had small  
159 prostate cysts. These structural abnormalities may affect the orientation of the ejaculatory ducts  
160 or the location of the seminal vesicles, thereby affecting the success rate of TUSV.

## 161 **Safety considerations**

162       Perineal pain, retrograde ejaculation, epididymitis, prolonged hematuria, rectal injury and  
163 urinary incontinence are known complications of TUSV. [9, 14] Only 2 patients in this study had  
164 postoperative complication of epididymitis. After antibiotic treatment, the infection in these 2  
165 patients was eventually controlled and resolved. Some studies have raised concerns that  
166 disruption of normal structures by TUSV could lead to infertility. [14] In recent studies, endoscopic  
167 treatments including both TUSV and Transurethral Ejaculation Duct resection (TURED) have shown  
168 positive results in the treatment of infertility. [10, 15-18] Real-time TRUS-guided TUSV has also  
169 been reported as being a safe procedure that helps avoid rectal injury. [19] Therefore, this study  
170 provides strong evidence for the safety of TUSV.

## 171 **Limitations and future prospects**

172       The present study is retrospective and with a rather small sample size. Further prospective  
173 studies with more patients involved would provide more convincing reference and therefore  
174 stronger evidence. Besides the aforementioned limitations, the condition of patients with  
175 hemospermia usually improves spontaneously without any aggressive treatment. Furuya et al.  
176 reported that the spontaneously resolved rate of hemospermia is as high as 88.9%. [19] It is  
177 possible that at the time of analysis, this natural process, i.e. hemospermia being relieved  
178 spontaneously, had, to a certain extent, contributed to the excellent remission rate after TUSV as  
179 well as complicated the assumed cause-and-effect relationship between TUSV and the remission  
180 of hemospermia.

## 181 **Conclusion**

182       As analyzed and concluded in this present study, intraoperative findings can help assess the  
183 risk of recurrent hemospermia. Specifically speaking, stones or blood clots found during TUSV for  
184 patients with intractable hemospermia contribute to a higher rate of recurrent hemospermia.

## 185 **Acknowledgments**

186 We would like to thank the editors of PLOS ONE and the reviewers for their thoughtful comments  
187 that helped us strengthen this article.

## 188 References

- 189 1. Kumar, P., S. Kapoor, and V. Nargund, *Haemospermia - a systematic review*. Ann R Coll  
190 Surg Engl, 2006. 88(4): p. 339-42.
- 191 2. Suh, Y., et al., *Etiologic classification, evaluation, and management of hematospermia*.  
192 Transl Androl Urol, 2017. 6(5): p. 959-972.
- 193 3. Xing, C., et al., *Prospective trial comparing transrectal ultrasonography and transurethral*  
194 *seminal vesiculoscopy for persistent hematospermia*. Int J Urol, 2012. 19(5): p. 437-42.
- 195 4. Han, H., et al., *Magnetic resonance imaging compared to ultrasound as the preferred*  
196 *method for diagnosing intractable haemospermia*. Andrologia, 2021. 53(6): p. e14054.
- 197 5. Yang, S.C., et al., *Transutricular seminal vesiculoscopy*. J Endourol, 2002. 16(6): p. 343-5.
- 198 6. Han, W.K., et al., *Transutricular seminal vesiculoscopy in hematospermia: technical*  
199 *considerations and outcomes*. Urology, 2009. 73(6): p. 1377-82.
- 200 7. Kang, P.M., et al., *Transutricular seminal vesiculoscopy in the management of symptomatic*  
201 *midline cyst of the prostate*. World J Urol, 2016. 34(7): p. 985-92.
- 202 8. Chen, R., et al., *Transurethral seminal vesiculoscopy for recurrent hemospermia: experience*  
203 *from 419 cases*. Asian J Androl, 2018. 20(5): p. 438-441.
- 204 9. Hu, J.C. and C.S. Chen, *Transurethral seminal vesiculoscopy acts as a therapeutic*  
205 *investigation for intractable hemospermia: Step-by-step illustrations and single-surgeon*  
206 *experience*. Int J Urol, 2018. 25(6): p. 589-595.
- 207 10. Liao, L.G., et al., *Etiology of 305 cases of refractory hematospermia and therapeutic options*

- 208 *by emerging endoscopic technology*. Sci Rep, 2019. 9(1): p. 5018.
- 209 11. Chen, W.K., et al., *Transurethral seminal vesiculoscopy for intractable hematospermia:*  
210 *experience from 144 patients*. BMC Urol, 2021. 21(1): p. 48.
- 211 12. Ren, Z.J., et al., *Transurethral resection of ejaculatory duct combined with seminal*  
212 *vesiculoscopy for management of persistent or recurrent hemospermia in men with*  
213 *ejaculatory duct obstruction*. BMC Urol, 2020. 20(1): p. 34.
- 214 13. Furuya, S., N. Masumori, and A. Takayanagi, *Natural history of hematospermia in 189*  
215 *Japanese men*. Int J Urol, 2016. 23(11): p. 934-940.
- 216 14. Pang, K., B.Z. Dong, and C.H. Han, *Commentary on "Transurethral seminal vesiculoscopy for*  
217 *recurrent hemospermia: experience from 419 cases"*. Asian J Androl, 2020. 22(2): p.  
218 227-228.
- 219 15. Dong, Q., et al., *[Minimally invasive surgery for ejaculatory duct obstruction in infertile*  
220 *men]*. Zhonghua Nan Ke Xue, 2016. 22(4): p. 291-3.
- 221 16. Tang, S.X., H.L. Zhou, and Y.L. Ding, *[Effectiveness of transurethral seminal vesiculoscopy in*  
222 *the treatment of persistent hematospermia, and oligoasthenozoospermia and azoospermia*  
223 *from ejaculatory duct obstruction]*. Zhonghua Yi Xue Za Zhi, 2016. 96(36): p. 2872-2875.
- 224 17. Lira, F.T.N., et al., *Management of Ejaculatory Duct Obstruction by Seminal Vesiculoscopy:*  
225 *Case Report and Literature Review*. JBRA Assist Reprod, 2020. 24(3): p. 382-386.
- 226 18. Wang, H.B., et al., *[Transurethral seminal vesiculoscopy in treatment of*  
227 *oligoasthenozoospermia secondary incomplete ejaculatory duct obstruction: A report of 8*

228 *cases*]. Beijing Da Xue Xue Bao Yi Xue Ban, 2020. 52(4): p. 642-645.

229 19. Wang, X.S., et al., *Real-time transrectal ultrasound-guided seminal vesiculoscopy for the*

230 *treatment of patients with persistent hematospermia: A single-center, prospective,*

231 *observational study*. Asian J Androl, 2020. 22(5): p. 507-512.

232

## 233 **Supporting information**

234 **S1 File. Raw data. File containing data of TUSV follow-up, TRUS findings, Intraoperative findings**

235 **and recurrence**



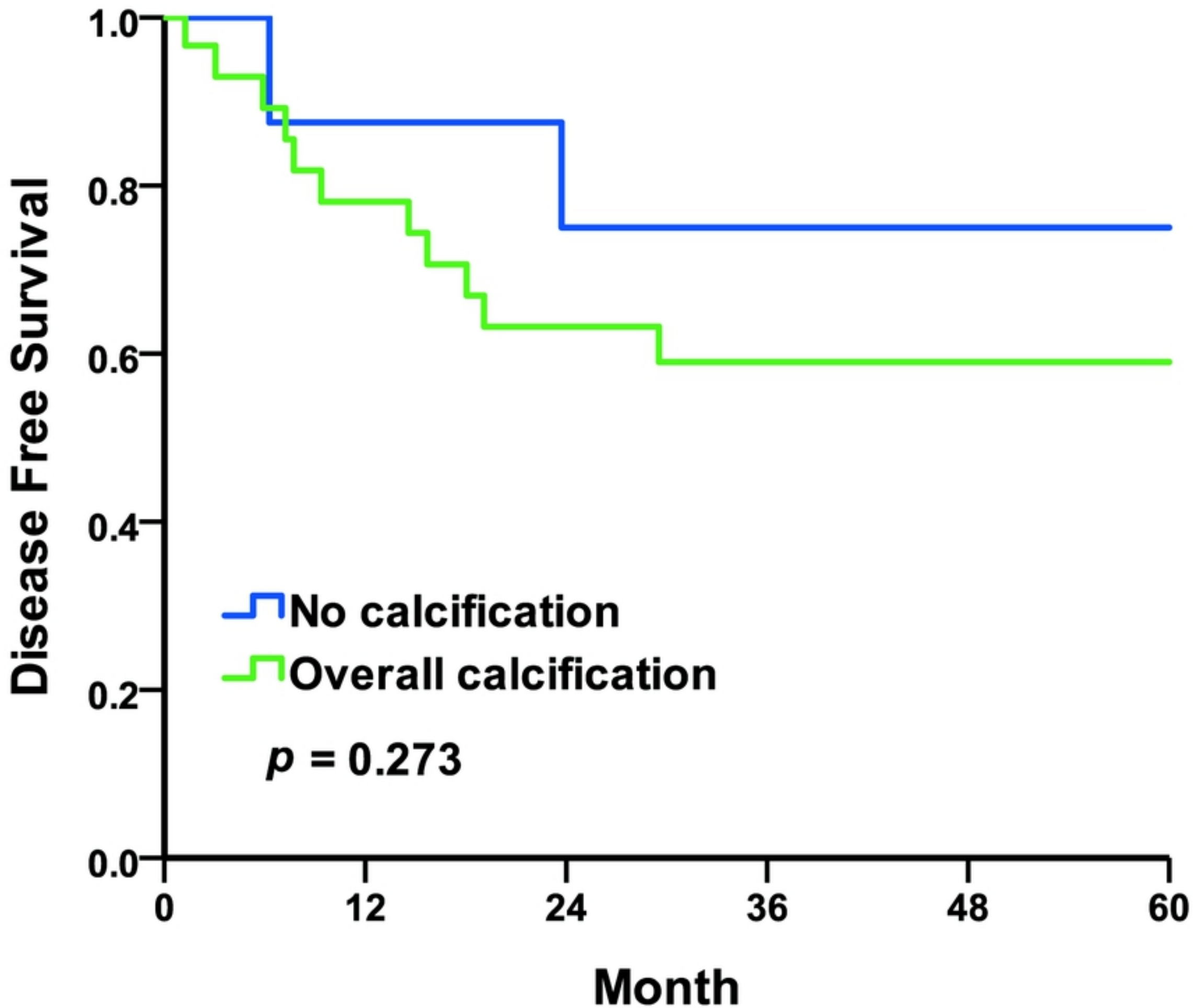


Fig 1. Kaplan-Meier curves of the disease-free survival rates by T

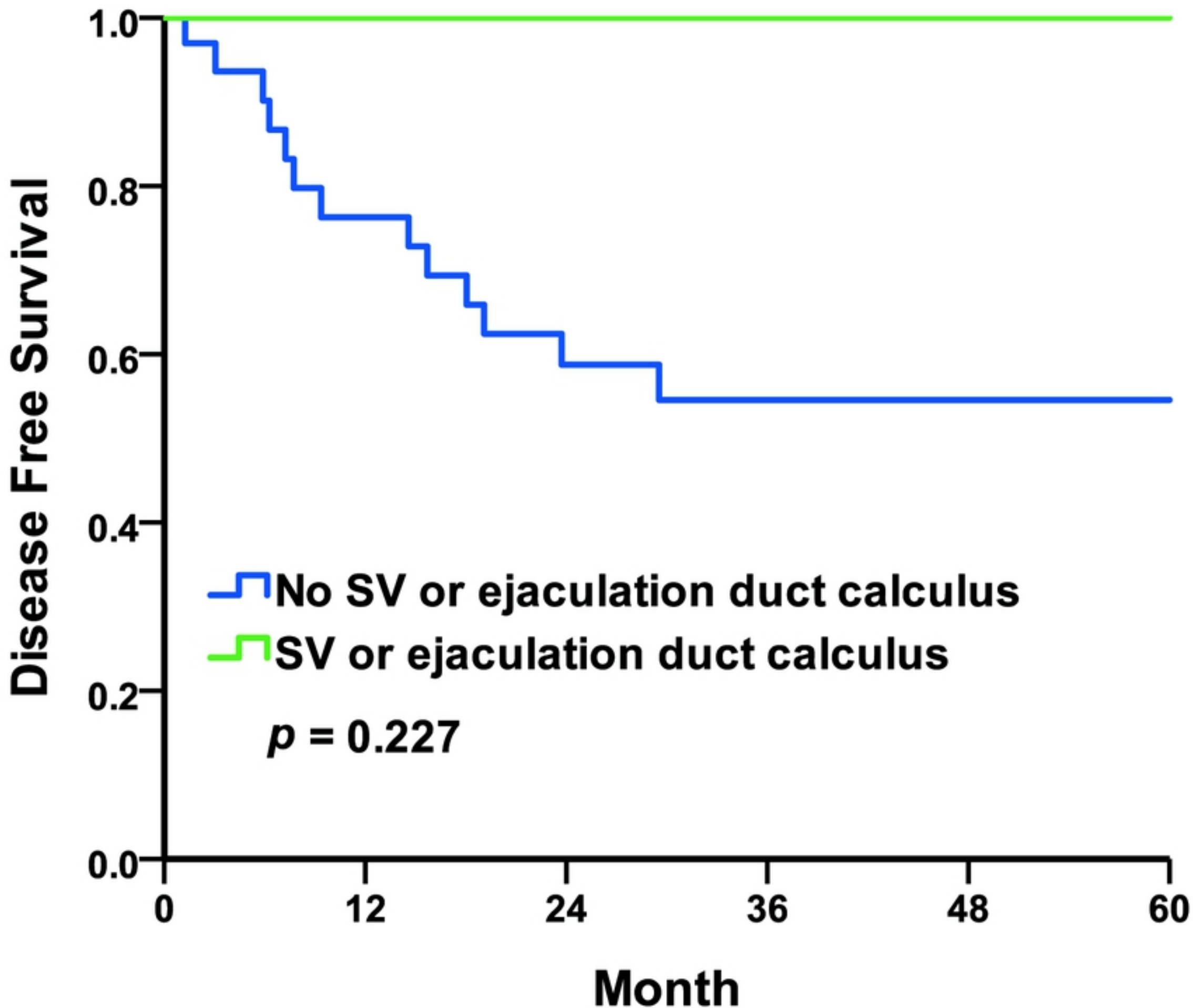


Fig 2. Kaplan-Meier curves of the disease-free survival rates by T

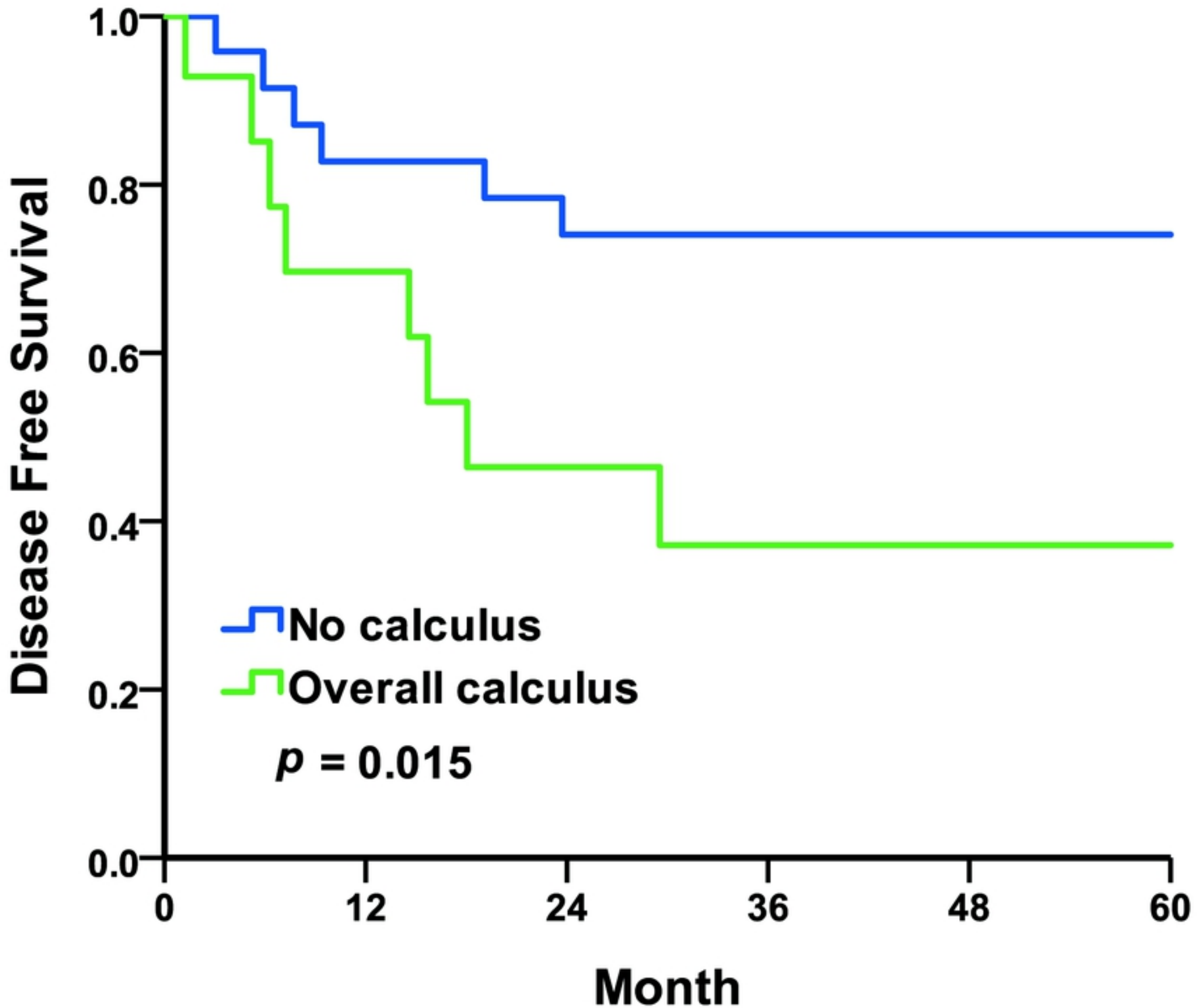


Fig3. Kaplan-Meier curves of the disease-free survival rates by in

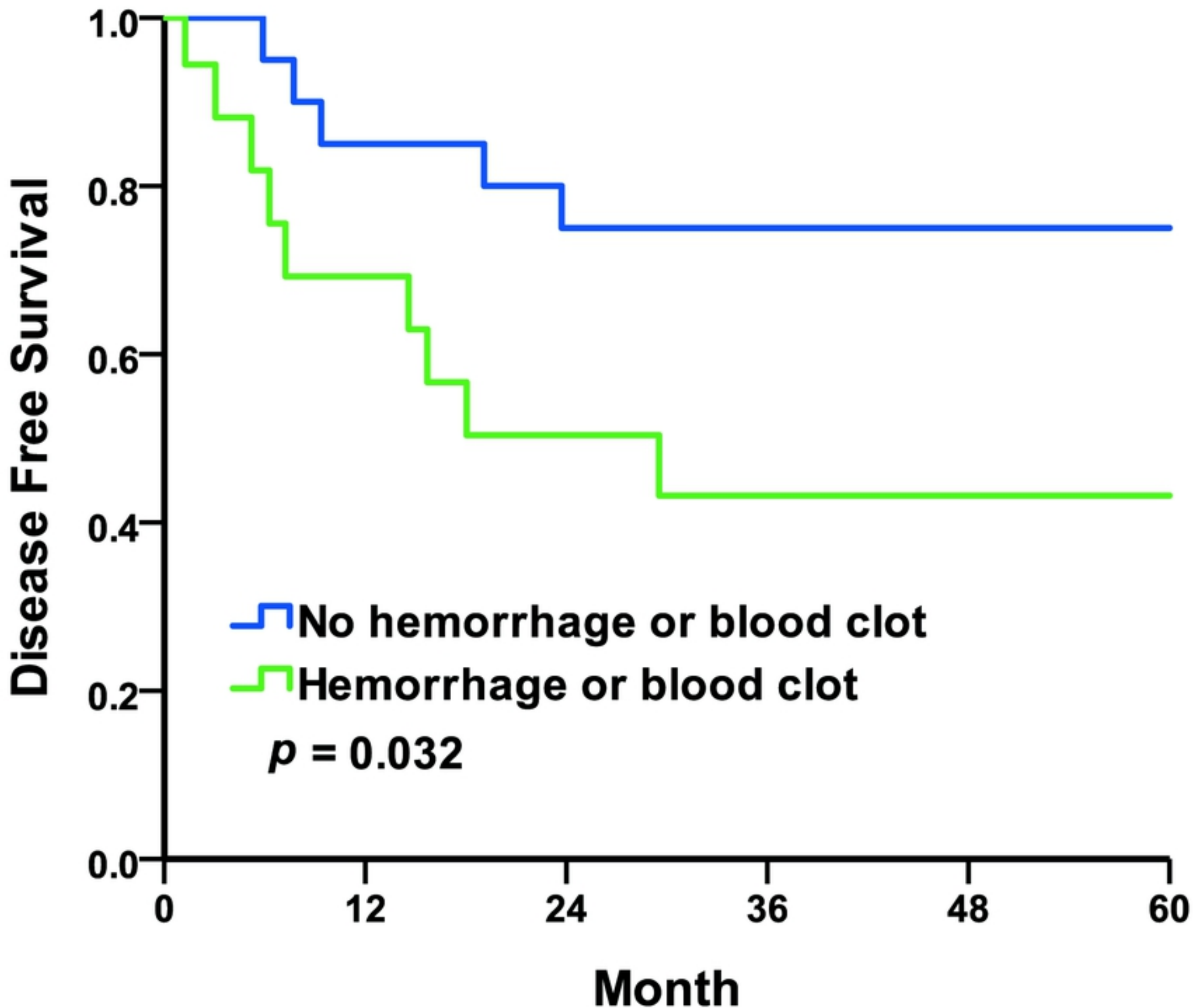


Fig4. Kaplan-Meier curves of the disease-free survival rates by in

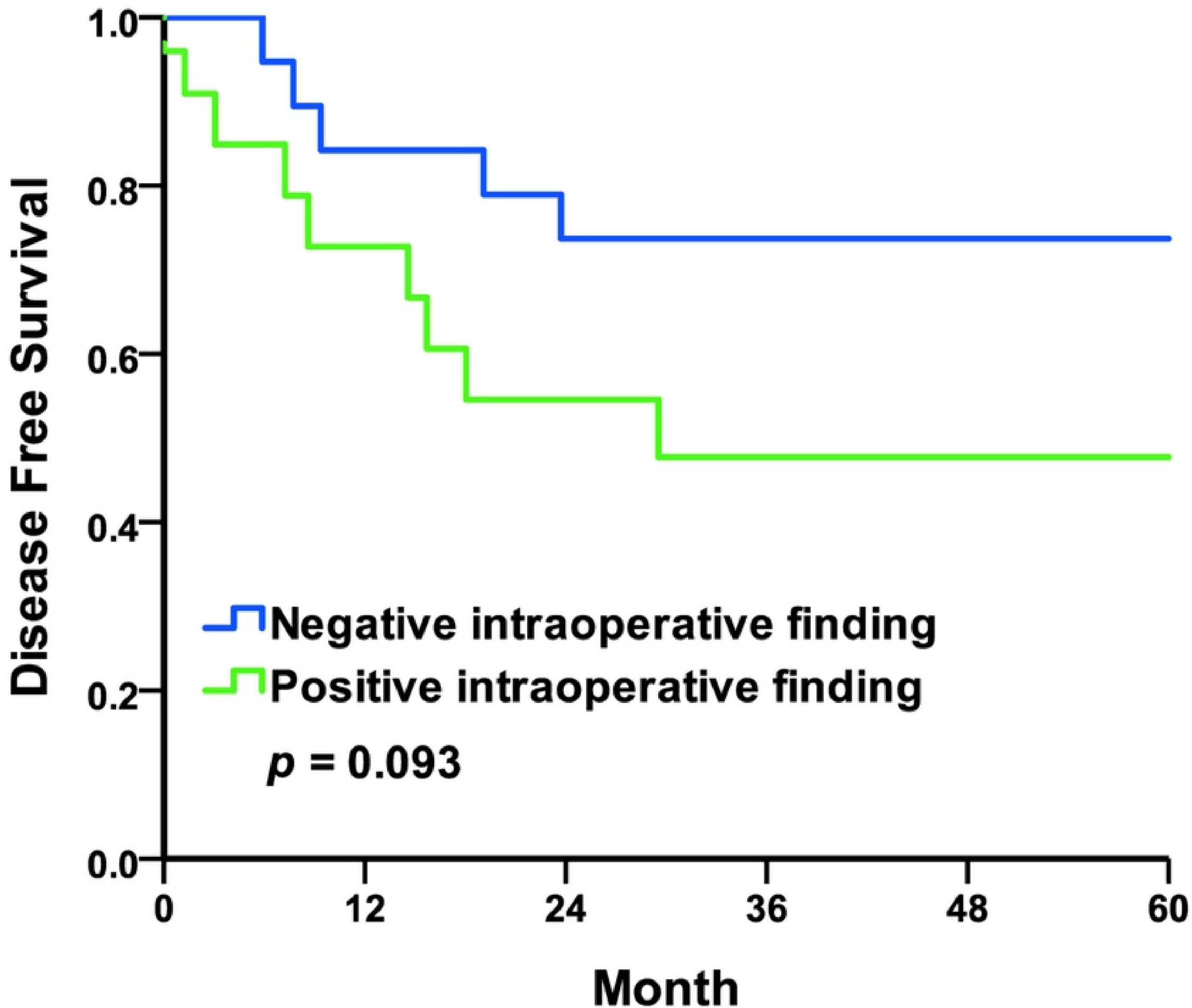


Fig5. Kaplan-Meier curves of the disease-free survival rates by in