

Global Reports of Myocarditis Following COVID-19 Vaccination: A Systematic Review and Meta-Analysis

Sirwan Khalid Ahmed^{a,b,c,d}, Mona Gamal Mohamed^e, Rawand Abdulrahman Essa^{a,b,c,d}, Eman Abdelaziz Ahmed Rashad^e, Peshraw Khdir Ibrahim^f, Awat Alla Khdir^{a,c}, Zhiar Hussien Wsu^{a,c}

Affiliations

^aDepartment of Emergency, Rania Teaching Hospital, Rania, Sulaimani, Kurdistan-region, Iraq

^b Department of Cardiothoracic and Vascular Surgery, Rania Medical City Hospital, Rania, Sulaimani, Kurdistan-Region, Iraq

^c Department of Emergency, Rania Pediatric & Maternity Teaching Hospital, Rania, Sulaimani, Kurdistan-region, Iraq

^d Department of Biotechnology, Institute of Science and Modern Technology, Rojava University, Qamishlo, Syria

^e Department of Adult Nursing, RAK Medical and Health Sciences University, Ras Al Khaimah, UAE

^fDepartment of Nursing, University of Raparin, Sulaimani, Rania, Kurdistan-region, Iraq

Corresponding Author:

Sirwan Khalid Ahmed

Department of Emergency, Rania Teaching Hospital, Rania 46012, Kurdistan region-Iraq, and Department of Biotechnology, Institute of Science and Modern Technology, Rojava University, Qamishlo, Syria

TEL: +9647501553224

Email: sirwan.ahmed1989@gmail.com

Abstract

In December 2020, the FDA granted emergency approval to Pfizer-BioNTech (BNT162b2) and Moderna (mRNA-1273) COVID-19 vaccines. There have been recent media reports of myocarditis after receiving COVID-19 vaccines, particularly the messenger RNA (mRNA) vaccines, causing public concern. This review summarizes information from published case series and case reports, with a strong emphasis on reporting patient and disease characteristics, investigation, and clinical outcome, to provide a comprehensive picture of the condition. Forty studies, including 147 cases, participated in this systematic review. The median age was 28.9 years; 93.9% were male and 6.1% were female. 72.1% of patients received the Pfizer-BioNTech (BNT162b2) vaccine, 24.5% of patients received the Moderna COVID-19 Vaccine (mRNA-1273), and the rest of the 3.3% received other types of vaccines. Furthermore, most myocarditis cases (87.1%) occurred after the second vaccine dose, after a median time interval of 3.3 days. The most frequently reported symptoms were chest pain, myalgia/body aches and fever. Troponin levels were consistently elevated in 98.6%. The admission ECG was abnormal in 88.5% of cases, and the left LVEF was lower than 50% in 26.5% of cases. The vast majority of patients (93.2%) resolved symptoms and recovered, and only 3 patients died. These findings may help public health policy to consider myocarditis in the context of the benefits of COVID-19 vaccination as well as to assess the cardiac condition before the choice of vaccine, which is offered to male adults. In addition, it must be carefully weighed against the very substantial benefit of vaccination.

Keywords

COVID-19, Myocarditis, COVID-19 Vaccines, mRNA vaccine, pericarditis

Introduction

International efforts to drive vaccinations are critical to restoring health and attempting economic and social recovery as the SARS-CoV-2 coronavirus (COVID-19)-caused pandemic continues [1]. The COVID-19

vaccines developed by Pfizer-BioNTech (BNT162b2) and Moderna (mRNA-1273) were granted emergency approval by the Food and Drug Administration (FDA) of the United States in December 2020. Reports of myocarditis after the COVID-19 vaccination, notably after the messenger RNA (mRNA) vaccines, have received widespread media attention in recent months, causing widespread concern among the general public [1]. Myocarditis is diagnosed in about ten to twenty people per 100,000 in the general population each year, and it has been shown to be more common in men and younger age groups [2]. Myocarditis following mRNA vaccination was first reported in Israel in April 2021, and then several case reports and case series were reported around the world.

Specifically, this report examines the current literature on myocarditis following COVID-19 vaccination, summarizing available information from previously published case reports and case series, with a strong attention on reporting patient and disease characteristics, as well as investigation and clinical outcome, in order to provide a comprehensive picture of the condition.

Methods

Review objectives

The main objective is to clarify the potential occurrence of myocarditis associated with COVID-19 vaccination and elaborate on the demographic and clinical characteristics of COVID-19 vaccinated individuals who develop myocarditis and how many cases have been reported in the literature.

Protocol and Registration

The review is written in accordance with the Preferred Reporting Items for Systematic Reviews and Meta-Analyses (PRISMA) 2020 guidelines for the systematic review of available literature [3]. The protocol of the review was registered in the International Prospective Register of Systematic Reviews (PROSPERO) with ID CRD42022308997. The AMSTAR-2 checklist was also used to evaluate this study, and it was found to be of high quality [4]. This review article didn't need to get ethics approval.

Search strategy

A comprehensive search of major electronic databases (PubMed and Google Scholar) was conducted on February 10, 2022, to locate all publications. The AND operator was used to connect two of the most important concepts in the search terminology ("COVID-19" AND "Myocarditis"). ("Myocarditis" and "COVID-19" OR "SARS-CoV-2" OR "Coronavirus Disease 2019" OR "severe acute respiratory syndrome coronavirus 2" OR "coronavirus infection" OR "2019-nCoV" AND "vaccine, vaccination, OR vaccine" were used in the search. To make sure the search was completed, we checked the references of all relevant papers.

Eligibility criteria

All case series and case reports on post-COVID-19 vaccine myocarditis in humans were included. Individuals who develop myocarditis after receiving the COVID-19 vaccine, regardless the type of vaccine and dose. The references of the relevant articles will also be reviewed for additional articles that meet the inclusion criteria. Narrative and systematic reviews, original and unavailable data papers were excluded in this review. Moreover, articles other than English were excluded in this review.

Data extraction and selection process

PRISMA 2020 was used to guide every step of the data extraction process from the original source. The Rayyan website was used by two independent authors (SKA and RAE) to screen abstracts and full-text articles based on inclusion and exclusion criteria [5]. The third author (RAE) resolved any discrepancies between the two independent authors. Microsoft Excel spreadsheets were used to collect the necessary information from the extracted data. Author names, year of publication, age, gender, type of COVID-19 vaccine, dose, days to symptoms onset, symptoms, troponin level, LVEF 50% or LVEF > 50%, ECG, length of hospital stay/days, treatment, and outcomes were extracted from each study.

Critical appraisal

To assess the quality of all included studies, we used the Joanna Briggs Institute's critical appraisal tool for case series and case reports [6]. Each article was evaluated by two different authors (SKA and RAE), each of whom worked independently. Paper evaluation disputes were resolved either through discussion or by a third author (RAE) depending on the circumstances. Articles with an average score of 50 percent or higher were included in the data extraction process. The AMSTAR 2 criteria [4]. were used to evaluate the results of our systematic review. The AMSTAR 2 tool assigned a "medium" rating to the overall quality of our systematic review.

Data synthesis and analysis

All the articles included in the current systematic review were analysed, and the data was extracted and pooled. This included (authors' names, year of publication; gender; type of COVID-19 vaccine, dose, days to symptoms onset, troponin level, LVEF below or above 50%, ECG, length of hospital stay/days; treatment and outcomes). We gathered this data from the results of eligibility studies. COVID-19 vaccine recipients who developed myocarditis were included in the study.

Results

Selection of studies

When we searched the major databases (PubMed and Google Scholar) on February 10, 2022, we discovered 2712 articles that were relevant to our search criteria. A citation manager tool (Mendeley) was then used to organize the references, and 283 articles were automatically removed because they contained duplicate content. Next, the titles, abstracts, and full texts of 2429 articles were checked for accuracy, and 2365 articles were rejected because they did not meet the criteria for inclusion. Besides that, 64 articles were submitted for retrieval, but twenty-four were rejected because they did not meet our inclusion requirements. The current systematic review was limited to 40 articles in total (**Fig 1**). The details of case reports and case series are shown in (**Table 1**).

Characteristics of the included studies

Overall, forty studies, including 147 cases each, from the United States, Italy, Israel, Germany, Poland, France, Korea, Brazil, Japan, Mexico, and Iran participated in this systematic review. The median age was 28.9 years; 93.9% were male and 6.1% were female. 72.1% of patients received the Pfizer-BioNTech (BNT162b2) vaccine, 24.5% of patients received the Moderna COVID-19 Vaccine (mRNA-1273), and the rest of the 3.3% received other types of vaccines (Johnson & Johnson, AstraZeneca, Sinovac).

The vast majority of cases are from the United States. All patients were diagnosed with myocarditis or myopericarditis following COVID-19 vaccination, regardless of the type of vaccine and dose.

Furthermore, most myocarditis cases (87.1%, n = 128) occurred after the second vaccine dose, after a median time interval of 3.3 days. The most frequently reported symptoms were chest pain (100% n = 147), fever (46.9% n = 69), myalgia/body aches (54.4% n = 80), and also variable reports of viral prodromes such as chills, headaches, and malaise. Troponin levels were consistently elevated in 98.6% (n = 145) of the cases where they were reported, consistent with myocardial injury. The admission electrocardiogram (ECG) was abnormal in 88.5% (n = 130) of cases, and the left ventricular ejection fraction (LVEF) was lower than 50% in 26.5% (n = 39) of cases. The median length of hospital stay was 5.2 days in 127 patients but unknown in 20 patients. The vast majority of patients (93.2%) (n = 137) resolved symptoms and recovered, and only 3 patients died (**Table 2**).

Discussion

The current systematic review summarized evidence from the original case reports and case series that explored the development of myocarditis after COVID-19 vaccination. Throughout the selected studies, most of the participants were male, from the USA, and their mean age 28.94 was years old. The mechanism of vaccine-induced myocarditis is not known but may be related to the active pathogenic component of the vaccine and specific human proteins, which could lead to immune cross-reactivity resulting in autoimmune disease, which is

one cause of myocarditis [7–10]. The occurrence of myocarditis in men may be related to sex hormone variations, as testosterone hormone suppresses anti-inflammatory immune cells while promoting more aggressive T helper cells [7,11].

These findings were matched with Oster et al (2022) [12], who found the incidence rate of myocarditis among vaccinated male people was similar to that seen in typical cases of myocarditis and there was a strong male predominance for both conditions [13]. Fatima et al (2022) [7] found most patients who developed myocarditis were males. Moreover, Patone et al (2022) [14] mentioned that the incidence of myocarditis was among England males younger than 40 years old. Similarly, a systematic review study found that the Incidence of myocarditis following mRNA vaccines is low but probably highest in males aged 12-29 years old [15].

Another important finding in the current systematic review is that most of the participants received Pfizer-BioNTech (BNT 162b2) followed by the Moderna COVID-19 vaccine (mRNA-1273), and most of the cases who complained of myocarditis received two doses of the vaccine. This indicates that mRNA vaccines are associated with a higher risk of developing myocarditis than viral vector vaccines, including Janssen, Oxford, and Sinovac. Bozkurt et al (2021) [2], have assumed that autoantibody generation could attack cardiac myocytes in response to mRNA vaccine, which increases the risk.

This finding is matched with Patone (2022) [14], who mentioned the risk of myocarditis increased within a week of receiving the first dose of both adenovirus and mRNA vaccines and after the second dose of mRNA vaccine. Oster et al (2022) [12] concluded that the risk of myocarditis after the mRNA vaccine was increased after the second dose in adolescents and young males. On the other hand, Simone et al (2021) [16] concluded that there is no relationship between COVID-19 mRNA vaccination and post vaccination myocarditis.

The findings extend these observations, which include the median onset of symptoms after vaccine administration was 3.32 days. The most common symptoms are chest pain, followed by myalgia/ body aches and fever. These findings matched with Pillay et al (2021) [15], who reported in a systematic review observation that the majority of myocarditis cases had a short symptoms onset of 2 to 4 days after a second dose, and the

majority presented with chest pain. These findings matched with Oster et al (2022) [12], who mentioned myocarditis was diagnosed within days of vaccination.

In patients with severe myocarditis, the diagnosis is often established by heart biopsy. In patients with mild myocarditis, the diagnosis is based on compatible clinical findings and confirmed by elevated levels of blood markers or an electrocardiogram (ECG) indicative of cardiac injury, with the presence of new abnormalities on echocardiography or cardiac MRI [17].

Cardiac-specific investigations revealed that troponin levels were elevated in almost all of the cases, consistent with myocardial injury, which is associated with autoimmune processes matched with vaccine protein and the case immune system.

In the same line with Lee et al. (2022) [1], a systematic review to investigate myocarditis following COVID-19 Vaccination in October 2020–October 2021, mentions that all reported cases have an elevated troponin level in keeping with myocardial injury.

In our study, less than one third of cases had left ventricle ejection fraction (LVEF) was less than 50%. Compared to patients with COVID-19 illness, patients with vaccine associated myocarditis had a higher LVEF.

This finding is consistent with the findings of Fronza et al. (2022) [18], who investigated myocardial injury patterns at MRI in COVID-19 Vaccine and discovered that more than half of the cases had more than 50% LVEF. Also, Shiyovich et al. (2022) [19], who analyzed myocarditis following the third (Booster) dose of COVID-19 vaccination found that the mean left ventricular ejection fraction was $61 \pm 7\%$ (range 53–71%) and regional wall motion abnormalities were present in one of the patients only. Global T1 values were increased in one (25%) of the patients, while focal values were increased in 3 (75%) of the patients. Global T2 values were increased in one (25%) of the patients, while focal values were increased in all of the patients (100%). Global ECV was increased in 3 (75%) of the patients, while focal ECV was increased in all the patients (100%). LGE was present in all the patients.

In our systematic review and meta-analysis study, 88.5% of cases had abnormal changes in the electrocardiogram (ECG) result, regardless of the vaccine type.

Vidula et al. (2021) [20] support our findings by reporting two patients with clinically suspected myocarditis who presented with acute substernal chest pain and/or dyspnea after receiving the second dose of the vaccine and were found to have diffuse ST elevations on electrocardiogram (ECG), elevated cardiac biomarkers and inflammatory markers, and mildly reduced left ventricular (LV) function on echocardiography.

Also, Puchalski et al. [21] reported the findings of a case series regarding COVID-19-Vaccination-Induced Myocarditis in Teenagers. Electrocardiogram (ECG) patterns varied, but in all cases, characteristic features of acute myocardial injury, including ST segment elevation or depression, and repolarization time abnormalities, were present.

Management of myocarditis remains largely supportive and is based on the restoration of hemodynamic stability and the administration of guideline-directed heart failure and arrhythmia treatment. Patients with preserved ventricular function and non-severe features were often treated with colchicine or non-steroidal anti-inflammatory drugs. According to our findings, all cases were treated with NSAIDs, beta blockers, calcium channel blockers, and/or diuretics. The median length of hospital stay was 5.2 days in 127 patients, and the vast majority of patients resolved symptoms and recovered, and only 3 patients died.

This finding broadly supports the work of other studies in this area. Woo et al [22] reported that many patients who received anti-inflammatory agents such as NSAIDs, colchicine, steroids, and intravenous immunoglobulin recovered without further medical treatment, with a hospital stay lasting 3-6 days.

In accordance with the present results, previous studies have demonstrated that almost all of the cases experienced a prompt recovery with no residual cardiac dysfunction. The median length of stay for all myocarditis cases was around 2–3 days, with a range of 2–10 days [23].

Conclusion

In conclusion, these findings may help public health policy to consider myocarditis in the context of the benefits of COVID-19 vaccination as well as to assess the cardiac condition before the choice of vaccine, which is offered to male adults. In addition, it must be carefully weighed against the very substantial benefit of vaccination. Moreover, further research is required to assess the long-term consequences and other risk factors following immunization, specifically the mRNA-1273 vaccine.

Conflicts of interest

There is no conflict to be declared.

Funding

This research did not receive any specific grant from funding agencies in the public, commercial, or not-for-profit sectors.

Author Agreement Statement

We declare that this manuscript is original, has not been published before and is not currently being considered for publication elsewhere. We confirm that the manuscript has been read and approved by all named authors and that there are no other persons who satisfied the criteria for authorship but are not listed. We confirm that the order of authors listed in the manuscript has been approved by all of us. We understand that the Corresponding Author is the sole contact for the Editorial process. He is responsible for communicating with the other authors about progress, submissions of revisions and final approval of proofs.

Data availability Statement

All relevant data are within the manuscript and its supporting information files.

Authors' contributions: Conception and design SKA acquisition of data SKA, RAE, MGM, EAA analysis and interpretation of data SKA, MGM, RAE, EEA, drafting of the manuscript SKA, RAE, MGM, EAA, PKI critical revision of the manuscript for important intellectual content statistical analysis SKA, MGM, RAE, EEA, PKI,

AAK, ZHW administrative SKA, MGM, EAA technical SKA, AAK, ZHW, supervision SKA, RAE and all authors approving final draft.

Provenance and peer review

Not commissioned, externally peer-reviewed

Acknowledgments

Not applicable

References

- [1] A.S.Y. Lee, D.D. Iswaree, O. Balakrishnan, C.Y. Khoo, C.T. Ng, J.K.X. Loh, L.L. Chan, L.L.Y. Teo, D.K.L. Sim, Myocarditis Following COVID-19 Vaccination: A Systematic Review (October 2020–October 2021), *Hear Lung Circ.* (2022) S1443-9506.
<https://doi.org/https://doi.org/10.1016/j.hlc.2022.02.002>.
- [2] B. Bozkurt, I. Kamat, P.J. Hotez, Myocarditis with COVID-19 mRNA vaccines, *Circulation.* 144 (2021) 471–484.
- [3] M.J. Page, J.E. McKenzie, P.M. Bossuyt, I. Boutron, T.C. Hoffmann, C.D. Mulrow, L. Shamseer, J.M. Tetzlaff, E.A. Akl, S.E. Brennan, The PRISMA 2020 statement: an updated guideline for reporting systematic reviews, *Int J Surg.* 88 (2021) 105906.
<https://doi.org/https://doi.org/10.1016/j.ijisu.2021.105906>.
- [4] B.J. Shea, B.C. Reeves, G. Wells, M. Thuku, C. Hamel, J. Moran, D. Moher, P. Tugwell, V. Welch, E. Kristjansson, AMSTAR 2: a critical appraisal tool for systematic reviews that include randomised or non-randomised studies of healthcare interventions, or both, *Bmj.* 358 (2017).
- [5] M. Ouzzani, H. Hammady, Z. Fedorowicz, A. Elmagarmid, Rayyan—a web and mobile app for systematic reviews, *Syst Rev.* 5 (2016) 1–10.

- [6] S. Moola, Z. Munn, C. Tufanaru, E. Aromataris, K. Sears, R. Sfetcu, M. Currie, R. Qureshi, P. Mattis, K. Lisy, Chapter 7: Systematic reviews of etiology and risk, Joanna Briggs Inst Rev Manual Joanna Briggs Inst. 5 (2017). <https://synthesismanual.jbi.global/>.
- [7] M. Fatima, H.A. Cheema, M.H.A. Khan, H. Shahid, M.S. Ali, U. Hassan, M.W. Murad, M.A.U. Rehman, H. Farooq, Development of myocarditis and pericarditis after COVID-19 vaccination in adult population: A systematic review, *Ann Med Surg.* (2022) 103486.
- [8] A. Pollack, A.R. Kontorovich, V. Fuster, G.W. Dec, Viral myocarditis—diagnosis, treatment options, and current controversies, *Nat Rev Cardiol.* 12 (2015) 670–680.
- [9] J.R. Su, Myopericarditis following COVID-19 vaccination: Updates from the Vaccine Adverse Event Reporting System (VAERS), (2021).
- [10] J. Montgomery, M. Ryan, R. Engler, D. Hoffman, B. McClenathan, L. Collins, D. Loran, D. Hrcir, K. Herring, M. Platzer, Myocarditis following immunization with mRNA COVID-19 vaccines in members of the US military, *JAMA Cardiol.* 6 (2021) 1202–1206.
- [11] D. Fairweather, L.T. Cooper Jr, L.A. Blauwet, Sex and gender differences in myocarditis and dilated cardiomyopathy, *Curr Probl Cardiol.* 38 (2013) 7–46.
- [12] M.E. Oster, D.K. Shay, J.R. Su, J. Gee, C.B. Creech, K.R. Broder, K. Edwards, J.H. Soslow, J.M. Dendy, E. Schlaudecker, Myocarditis Cases Reported After mRNA-Based COVID-19 Vaccination in the US From December 2020 to August 2021, *JAMA.* 327 (2022) 331–340.
- [13] V. Kytö, J. Sipilä, P. Rautava, The effects of gender and age on occurrence of clinically suspected myocarditis in adulthood, *Heart.* 99 (2013) 1681–1684.
- [14] M. Patone, X.W. Mei, L. Handunnetthi, S. Dixon, F. Zaccardi, M. Shankar-Hari, P. Watkinson, K. Khunti, A. Harnden, C.A.C. Coupland, Risks of myocarditis, pericarditis, and cardiac arrhythmias associated with COVID-19 vaccination or SARS-CoV-2 infection, *Nat Med.* (2021) 1–13.

- [15] J. Pillay, L. Bialy, L. Gaudet, A. Wingert, A. Mackie, D.I. Paterson, L. Hartling, Myocarditis and Pericarditis following COVID-19 Vaccination: Rapid Systematic Review of Incidence, Risk Factors, and Clinical Course, *MedRxiv*. (2021).
- [16] A. Simone, J. Herald, A. Chen, N. Gulati, A.Y.-J. Shen, B. Lewin, M.-S. Lee, Acute myocarditis following COVID-19 mRNA vaccination in adults aged 18 years or older, *JAMA Intern Med*. 181 (2021) 1668–1670.
- [17] S. Heymans, L.T. Cooper, Myocarditis after COVID-19 mRNA vaccination: clinical observations and potential mechanisms, *Nat Rev Cardiol*. (2021) 1–3.
- [18] M. Fronza, P. Thavendiranathan, V. Chan, G.R. Karur, J.A. Udell, R.M. Wald, R. Hong, K. Hanneman, Myocardial Injury Pattern at MRI in COVID-19 Vaccine-associated Myocarditis, *Radiology*. (2022) 212559.
- [19] A. Shiyovich, G. Witberg, Y. Aviv, R. Kornowski, A. Hamdan, A Case Series of Myocarditis Following Third (Booster) Dose of COVID-19 Vaccination: Magnetic Resonance Imaging Study, *Front Cardiovasc Med*. 9 (2022).
- [20] M.K. Vidula, M. Ambrose, H. Glassberg, N. Chokshi, T. Chen, V.A. Ferrari, Y. Han, Myocarditis and other cardiovascular complications of the mRNA-based COVID-19 vaccines, *Cureus*. 13 (2021).
- [21] M. Puchalski, H. Kamińska, M. Bartoszek, M. Brzewski, B. Werner, COVID-19-Vaccination-Induced Myocarditis in Teenagers: Case Series with Further Follow-Up, *Int J Environ Res Public Health*. 19 (2022) 3456.
- [22] W. Woo, A.Y. Kim, D.K. Yon, S.W. Lee, J. Hwang, L. Jacob, A. Koyanagi, M.S. Kim, D.H. Moon, J.W. Jung, Clinical characteristics and prognostic factors of myocarditis associated with the mRNA COVID-19 vaccine, *J Med Virol*. (2021).
- [23] T. Almas, S. Rehman, E. Mansour, T. Khedro, A. Alansari, J. Malik, N. Alshareef, V.R. Nagarajan, A.H.

- Al-Awaid, R. Alsufyani, Epidemiology, clinical ramifications, and cellular pathogenesis of COVID-19 mRNA-vaccination-induced adverse cardiovascular outcomes: A state-of-the-heart review, *Biomed Pharmacother.* 149 (2022) 112843.
- [24] S.A. Mouch, A. Roguin, E. Hellou, A. Ishai, U. Shoshan, L. Mahamid, M. Zoabi, M. Aisman, N. Goldschmid, N.B. Yanay, Myocarditis following COVID-19 mRNA vaccination, *Vaccine.* 39 (2021) 3790–3793.
- [25] M. Marshall, I.D. Ferguson, P. Lewis, P. Jaggi, C. Gagliardo, J.S. Collins, R. Shaughnessy, R. Caron, C. Fuss, K.J.E. Corbin, Symptomatic acute myocarditis in 7 adolescents after Pfizer-BioNTech COVID-19 vaccination, *Pediatrics.* 148 (2021).
- [26] T. D’Angelo, A. Cattafi, M.L. Carerj, C. Booz, G. Ascenti, G. Cicero, A. Blandino, S. Mazziotti, Myocarditis after SARS-CoV-2 vaccination: a vaccine-induced reaction?, *Can J Cardiol.* 37 (2021) 1665–1667.
- [27] M. Nassar, N. Nso, C. Gonzalez, S. Lakhdar, M. Alshamam, M. Elshafey, Y. Abdalazeem, A. Nyein, B. Punzalan, R.J. Durrance, COVID-19 vaccine-induced myocarditis: case report with literature review, *Diabetes Metab Syndr.* 15 (2021) 102205.
- [28] H.W. Kim, E.R. Jenista, D.C. Wendell, C.F. Azevedo, M.J. Campbell, S.N. Darty, M.A. Parker, R.J. Kim, Patients with acute myocarditis following mRNA COVID-19 vaccination, *JAMA Cardiol.* 6 (2021) 1196–1201.
- [29] A.K. Verma, K.J. Lavine, C.-Y. Lin, Myocarditis after Covid-19 mRNA vaccination, *N Engl J Med.* 385 (2021) 1332–1334.
- [30] C.M. Rosner, L. Genovese, B.N. Tehrani, M. Atkins, H. Bakhshi, S. Chaudhri, A.A. Damluji, J.A. De Lemos, S.S. Desai, A. Emaminia, Myocarditis temporally associated with COVID-19 vaccination, *Circulation.* 144 (2021) 502–505.

- [31] A. Dionne, F. Sperotto, S. Chamberlain, A.L. Baker, A.J. Powell, A. Prakash, D.A. Castellanos, S.F. Saleeb, S.D. de Ferranti, J.W. Newburger, Association of myocarditis with BNT162b2 messenger RNA COVID-19 vaccine in a case series of children, *JAMA Cardiol.* 6 (2021) 1446–1450.
- [32] B. García, P. Ortega, B.F. JA, C. León, R. Burgos, C. Dorta, Acute myocarditis after administration of the BNT162b2 vaccine against COVID-19, *Rev Esp Cardiol.* 74 (2021) 812–814.
- [33] J.B. Dickey, E. Albert, M. Badr, K.M. Laraja, L.M. Sena, D.S. Gerson, J.E. Saucedo, W. Qureshi, G.P. Aurigemma, A series of patients with myocarditis following SARS-CoV-2 vaccination with mRNA-1279 and BNT162b2, *Cardiovasc Imaging.* 14 (2021) 1862–1863.
- [34] E. Tano, S. San Martin, S. Girgis, Y. Martinez-Fernandez, C. Sanchez Vegas, Perimyocarditis in adolescents after Pfizer-BioNTech COVID-19 vaccine, *J Pediatric Infect Dis Soc.* 10 (2021) 962–966.
- [35] K.F. Larson, E. Ammirati, E.D. Adler, L.T. Cooper Jr, K.N. Hong, G. Saponara, D. Couri, A. Cereda, A. Procopio, C. Cavalotti, Myocarditis after BNT162b2 and mRNA-1273 vaccination, *Circulation.* 144 (2021) 506–508.
- [36] A. Deb, J. Abdelmalek, K. Iwuji, K. Nugent, Acute myocardial injury following COVID-19 vaccination: a case report and review of current evidence from vaccine adverse events reporting system database, *J Prim Care Community Health.* 12 (2021) 21501327211029230.
- [37] A. Abbate, J. Gavin, N. Madanchi, C. Kim, P.R. Shah, K. Klein, J. Boatman, C. Roberts, S. Patel, S. Danielides, Fulminant myocarditis and systemic hyperinflammation temporally associated with BNT162b2 mRNA COVID-19 vaccination in two patients, *Int J Cardiol.* 340 (2021) 119–121.
- [38] A. Muthukumar, M. Narasimhan, Q.-Z. Li, L. Mahimainathan, I. Hitto, F. Fuda, K. Batra, X. Jiang, C. Zhu, J. Schoggins, In-depth evaluation of a case of presumed myocarditis after the second dose of COVID-19 mRNA vaccine, *Circulation.* 144 (2021) 487–498.
- [39] A. Isaak, A. Feisst, J.A. Luetkens, Myocarditis following COVID-19 vaccination, *Radiology.* 301 (2021)

E378–E379.

- [40] A. Cereda, C. Conca, L. Barbieri, G. Ferrante, G. Tumminello, S. Lucreziotti, M. Guazzi, A. Mafri, Acute myocarditis after the second dose of SARS-CoV-2 vaccine: Serendipity or atypical causal relationship?, *Anatol J Cardiol.* 25 (2021) 522.
- [41] K. Watkins, G. Griffin, K. Septaric, E.L. Simon, Myocarditis after BNT162b2 vaccination in a healthy male, *Am J Emerg Med.* 50 (2021) 815-e1.
- [42] B. Chamling, V. Vehof, S. Drakos, M. Weil, P. Stalling, C. Vahlhaus, P. Mueller, M. Bietenbeck, H. Reinecke, C. Meier, Occurrence of acute infarct-like myocarditis following COVID-19 vaccination: just an accidental co-incidence or rather vaccination-associated autoimmune myocarditis?, *Clin Res Cardiol.* 110 (2021) 1850–1854.
- [43] J. Mansour, R.G. Short, S. Bhalla, P.K. Woodard, A. Verma, X. Robinson, D.A. Raptis, Acute myocarditis after a second dose of the mRNA COVID-19 vaccine: a report of two cases, *Clin Imaging.* 78 (2021) 247–249.
- [44] D. Levin, G. Shimon, M. Fadlon-Derai, L. Gershovitz, A. Shovali, A. Sebbag, S. Bader, N. Fink, B. Gordon, Myocarditis following COVID-19 vaccination—a case series, *Vaccine.* 39 (2021) 6195–6200.
- [45] J. Schauer, S. Buddhe, J. Colyer, E. Sagiv, Y. Law, S.M. Chikkabyrappa, M.A. Portman, Myopericarditis after the Pfizer messenger ribonucleic acid coronavirus disease vaccine in adolescents, *J Pediatr.* 238 (2021) 317–320.
- [46] M. Shumkova, D. Vassilev, K. Karamfiloff, R. Ivanova, K. Stoyanova, T. Yaneva-Sirakova, R.J. Gil, Acute myocarditis associated with the Pfizer/BioNTech vaccine, *Kardiol Pol (Polish Hear Journal).* 79 (2021) 1282–1283.
- [47] P.K. Minocha, D. Better, R.K. Singh, T. Hoque, Recurrence of acute myocarditis temporally associated with receipt of the mRNA coronavirus disease 2019 (COVID-19) vaccine in a male adolescent, *J*

- Pediatr. 238 (2021) 321–323.
- [48] A.A. Hasnie, U.A. Hasnie, N. Patel, M.U. Aziz, M. Xie, S.G. Lloyd, S.D. Prabhu, Perimyocarditis following first dose of the mRNA-1273 SARS-CoV-2 (Moderna) vaccine in a healthy young male: a case report, *BMC Cardiovasc Disord.* 21 (2021) 1–6.
- [49] J. Starekova, D.A. Bluemke, W.S. Bradham, T.M. Grist, M.L. Schiebler, S.B. Reeder, Myocarditis associated with mRNA COVID-19 vaccination, *Radiology.* 301 (2021) E409–E411.
- [50] T. Koizumi, T. Awaya, K. Yoshioka, S. Kitano, H. Hayama, K. Amemiya, Y. Enomoto, Y. Yazaki, M. Moroi, M. Nakamura, Myocarditis after COVID-19 mRNA vaccines, *QJM An Int J Med.* 114 (2021) 741–743.
- [51] K. McLean, T.J. Johnson, Myopericarditis in a previously healthy adolescent male following COVID-19 vaccination: A case report, *Acad Emerg Med.* 28 (2021) 918–921.
- [52] P.G. Riedel, V.F. Sakai, S. de C.C. Toniasso, M.C.B. Brum, F.S. Fernandes, R.M. Pereira, C.P. Baldin, C. de Campos Baldin, A.Y. Takahasi, H. Shiki, Heart failure secondary to myocarditis after SARS-CoV-2 reinfection: a case report, *Int J Infect Dis.* 113 (2021) 175–177.
- [53] K. In-Cheol, K. Hyungseop, L.H. Jeong, K.J. Yoon, K. Jin-Young, Cardiac Imaging of Acute Myocarditis Following COVID-19 mRNA Vaccination, *J Korean Med Sci.* 36 (2021) 1–6.
- [54] T.D. Nguyen, G. Mall, J.G. Westphal, O. Weingärtner, S. Möbius-Winkler, P.C. Schulze, Acute myocarditis after COVID-19 vaccination with mRNA-1273 in a patient with former SARS-CoV-2 infection, *ESC Hear Fail.* (2021).
- [55] N. Azdaki, M. Farzad, Long QT interval and syncope after a single dose of COVID-19 vaccination: a case report, *Pan Afr Med J.* 40 (2021).
- [56] J.M. Sokolska, J. Kurcz, W. Kosmala, Every rose has its thorns—acute myocarditis following COVID-19 vaccination, *Kardiol Pol (Polish Hear Journal).* 79 (2021) 1153–1154.

- [57] Y.R. Patel, D.W. Louis, M. Atalay, S. Agarwal, N.R. Shah, Cardiovascular magnetic resonance findings in young adult patients with acute myocarditis following mRNA COVID-19 vaccination: a case series, *J Cardiovasc Magn Reson.* 23 (2021) 1–8.
- [58] D. Kim, J.H. Choi, J.Y. Jang, O. So, E. Cho, H. Choi, K.S. Hong, K.T. Park, A Case Report for Myopericarditis after BNT162b2 COVID-19 mRNA Vaccination in a Korean Young Male, *J Korean Med Sci.* 36 (2021).
- [59] P. Ehrlich, K. Klingel, S. Ohlmann-Knafo, S. Hüttinger, N. Sood, D. Pickuth, M. Kindermann, Biopsy-proven lymphocytic myocarditis following first mRNA COVID-19 vaccination in a 40-year-old male: case report, *Clin Res Cardiol.* 110 (2021) 1855–1859.
- [60] P. Schmitt, R. Demoulin, R. Poyet, E. Capilla, G. Rohel, F. Pons, C. Jégo, S. Sidibe, A. Druelle, F.-X. Brocq, Acute Myocarditis after COVID-19 vaccination: A case report, *La Rev Med Interne.* 42 (2021) 797–800.
- [61] M. Kadwalwala, B. Chadha, J. Ortoleva, M. Joyce, Multimodality imaging and histopathology in a young man presenting with fulminant lymphocytic myocarditis and cardiogenic shock after mRNA-1273 vaccination, *BMJ Case Reports CP.* 14 (2021) e246059.
- [62] M. Azir, B. Inman, J. Webb, L. Tannenbaum, STEMI Mimic: Focal Myocarditis in an Adolescent Patient After mRNA COVID-19 Vaccine, *J Emerg Med.* 61 (2021) e129–e132.

Fig 1: PRISMA flow-diagram

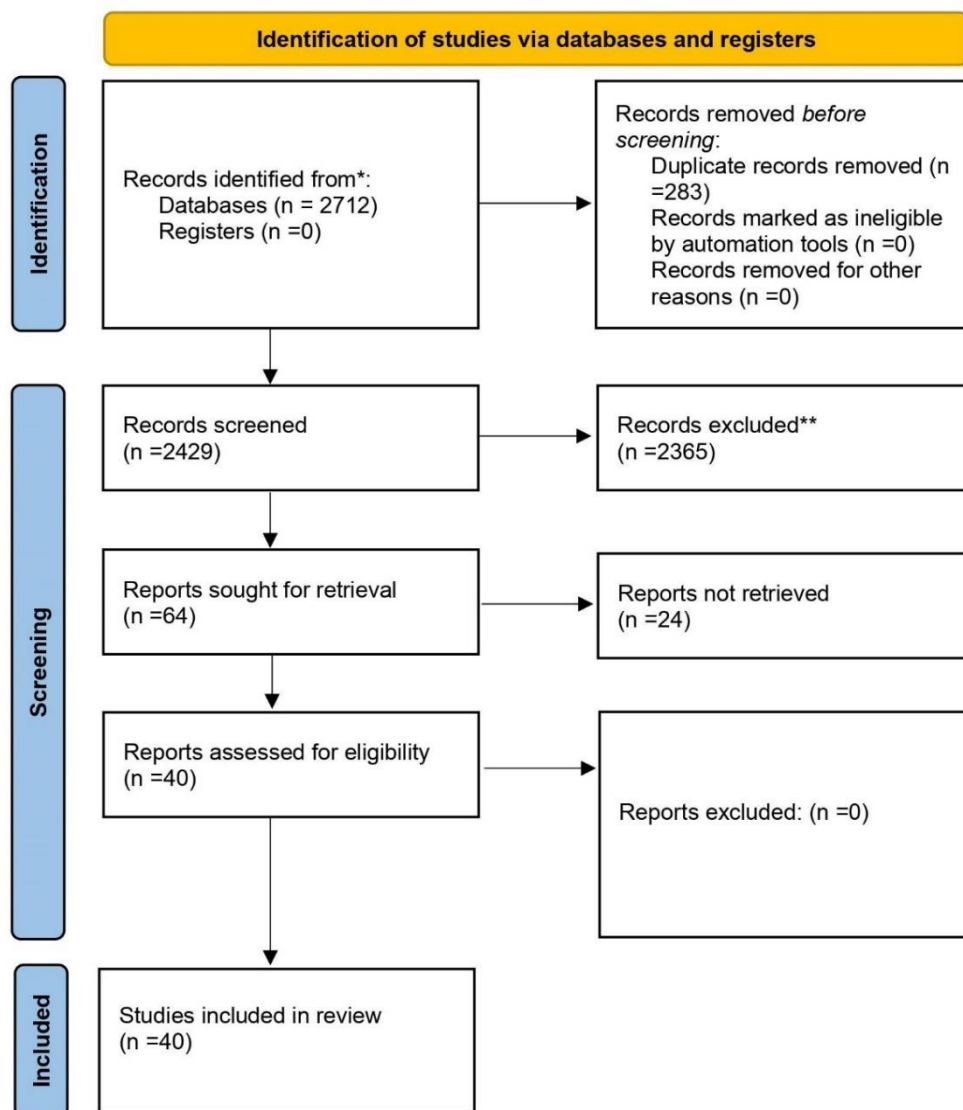


Table 1: Characteristics and outcomes of patients with myocarditis related to COVID-19 vaccine.

Author/Year of publication	Country	Age	Gender	Type of COVID-19 vaccine	Dose	Days to symptom onset	Symptoms	Troponin level	LVEF <50% or LVEF >50%	Electrocardiogram (ECG)	Treatment	Length of hospital stay (days)	Outcome
Abu Mouch et al 2021 [24]	Israel	6 cases mean age 22 years	All of them were male	BNT162b 2	2 nd in 5 cases and 1 st in one case	Mean 4.5 days	Chest pain/discomfort	Elevated in all cases	LVEF >50% in all cases	Abnormal in all cases	NSAIDs and colchicine	Mean 5.6 days	Recovered
Marshall et al 2021 [25]	USA	7 cases mean age 16.7 years	All of them were male	BNT162b 2	2 nd	Mean 2.57 days	Chest pain	Elevated in all cases	LVEF >50% in 6 cases and LVEF <50% in one case	Abnormal in all cases	NSAIDs, IVIg, IV methylprednisolone, PO prednisone, famotidine, aspirin	Mean 11.57 days	Recovered
D'Angelo et al 2021 [26]	Italy	30 years	Male	BNT162b 2	1 st	21 days	dyspnea, constrictive retrosternal pain, nausea, and profuse sweating	Elevated	LVEF >50%	Abnormal	Bisoprolol, aspirin, and prednisolone	7 days	Recovered
Nassar et al 2021 [27]	USA	70 years	Female	Ad26.CO V2. S	1 st	2 days	The patient arrived at the emergency department in severe respiratory distress	Elevated	LVEF >50%	Abnormal	vasopressors and antibiotic therapy	8 days	Died
Kim et al 2021 [28]	USA	4 cases mean age 38.25 years	3 males and 1 female	mRNA-1273 in 2 cases And BNT162b 2 in 2 cases	2 nd	Mean 2.75 days	Chest pain	Elevated in all cases	LVEF >50% in 3 cases and LVEF <50% in one case	Abnormal in all cases	Corticosteroids NSAIDs and colchicine	Mean 2.5 days	Recovered
Montgomery et al 2021 [10]	USA	23 cases mean age 25 years	All of them were male	BNT162b 2 in 7 cases and 16 cases mRNA-1273	2 nd in 20 cases and 1 st in 3 cases	Mean 2 days	Chest pain	Elevated in all cases	LVEF <50% in 4 cases and LVEF ≥50% in 19 cases	Abnormal in 19 cases and normal in 4 cases	All patients received brief supportive care	Mean 7 days	16 cases were fully recovered and 7 cases under follow-up
Verma et al 2021 [29]	USA	2 cases (45, 42) years Mean age 43.5 years	1 male and 1 female	BNT162b 2- in 1 case and 1 case mRNA-1273	1 st in one case and 2 nd in another case	Mean 12 days	Chest pain, dyspnea and dizziness,	Elevated in all cases	LVEF >50% in all cases	Abnormal in all cases	intravenous diuretics, methylprednisolone, lisinopril, spironolactone, and metoprolol succinate).	7 days	female case recovered and male case died
Rosner et al 2021 [30]	USA	7 cases Mean age 27.42 years	All of them were male	BNT162b 2 in 5 cases, one case mRNA-1273 and one case Ad26.CO V2. S	2 nd in 6 cases and 1 st in one case	Mean 3.85 days	Chest pain	Elevated in all cases	LVEF >50% in 6 cases and LVEF <50% in one case	Abnormal in 6 cases and normal in one case	β-blocker and anti-inflammatory medication	Mean 2.85 days	Recovered

Dionne et al 2021 [31]	USA	15 cases mean age 15 years	14 cases male and one case female	BNT162b 2 in all cases	2 nd in all cases	Mean 3 days	Chest pain, fever, myalgia, headache	Elevated in all cases	Mean LVEF <50% in all cases	Abnormal in all cases	β-blocker therapy.	Mean 2 days	Recovered
García et al 2021 [32]	Mexico	39 years	Male	BNT162b 2	2 nd	¼ day	Chest pain	Elevated	LVEF >50%	Abnormal	anti-inflammatory medication	6 days	Recovered
Dickey et al 2021 [33]	USA	6 cases mean age 27 years	All of them were male	BNT162b 2 in 5 cases and one case mRNA-1273	2 nd	Mean 3.33 days	chest pain, chills, myalgia, malaise, headache and fever	Elevated in all cases	LVEF >50% in 3 cases and LVEF <50% in 3 cases	Abnormal in 5 cases and normal in one case	Unknown	Unknown	Recovered
Tano et al 2021 [34]	USA	8 cases mean age 16.61 years	All of them were male	BNT162b 2 in all cases	2 nd in 7 cases and 1 st in one case	Mean 2.37 days	Chest pain, fatigue, abdominal pain, fever, shortness of breath	Elevated in all cases	LVEF >50% in all cases	Abnormal in 6 cases and normal in 2 cases	NSAIDs	Mean 2.36 days	Recovered
Larson et al 2021 [35]	USA and Italy	8 cases mean age 31.62 years	All of them were male	BNT162b 2 in 5 cases and 3 cases mRNA-1273	2 nd in 7 cases and 1 st in one case	Mean 2.75 days	Chest pain, myalgia, fever, chills, shortness of breath and cough	Elevated in all cases	LVEF >50% in 6 cases and LVEF <50% in 2 cases	Abnormal in 7 cases and normal in 1 case	NSAIDs, colchicine and prednisone	Unknown	Recovered
Deb et al 2021 [36]	USA	67 years	Male	mRNA-1273	2 nd	¼ day	Nausea, orthopnea, fatigue	Elevated	LVEF >50%	Normal	intravenous furosemide, bronchodilators	2 days	Recovered
Abbate et al 2021 [37]	USA	2 cases mean age 30.5 years	One male and one female	BNT162b 2 in all cases	2 nd in one case and 1 st in second case	Mean 5.5 days	Fever, cough, chest pain, nausea and vomiting	Unknown	LVEF <50% in all cases	Abnormal in all cases	Prednisone	73 days for one case	One case died and one recovered
Muthukumar et al 2021 [38]	USA	52 years	Male	mRNA-1273	2 nd	1 day	Chest pain, fevers, shaking chills, myalgias, and headache	Elevated	LVEF <50%	Abnormal	low-dose lisinopril and carvedilol	4 days	Recovered
Isaak et al 2021 [39]	Germany	15 years	Male	BNT162b 2	2 nd	1 day	fever, myalgia	Elevated	LVEF <50%	Abnormal	Unknown	7 days	Recovered
Cereda et al 2021 [40]	Italy	12 years	Male	BNT162b 2	2 nd	1 day	Chest pain	Elevated	LVEF >50%	Abnormal	Bisoprolol and ramipril	7 days	Recovered
Watkins et al 2021 [41]	USA	20 years	Male	BNT162b 2	2 nd	2 days	Chest pain and shortness of breath	Elevated	LVEF >50%	Abnormal	Colchicine, metoprolol, ibuprofen	Unknown	Recovered
Chamling et al 2021 [42]	Germany	3 cases mean age 37.66 years	2 males and 1 female	BNT162b 2 in 2 cases, and ChAdOx1 nCoV-19 in 1 case	1 st in 2 cases and 2 nd in 1 case	Mean 7 days	Chest pain	Elevated in 2 case and not elevated in 1 case	LVEF >50% in all cases	Abnormal in 2 cases and normal on 1 case	Unknown	Unknown	Recovered
Mansour et al 2021 [43]	USA	2 cases mean age 23 years	1 male and 1 female	mRNA-1273 in all cases	2 nd in all cases	1 day	Chest pain, fever,	Elevated in all cases	LVEF >50% in all cases	Abnormal in all cases	metoprolol	Mean 2 days	Recovered

Levin et al 2021 [44]	Israel	7 cases mean age 20.42 years	All of them were male	BNT162b 2 in all cases	2 nd in all cases	Mean 7 days	Chest pain, fatigue, fever and headache	Elevated in all cases	LVEF >50% in 5 cases LVEF <50% in 2 cases	Abnormal in all cases	Colchicine, Ibuprofen, Bisoprolol, and Ramipril	Mean 2.5 days	Recovered
Schauer et al 2021 [45]	USA	13 cases mean age 15.07 years	12 male and 1 female	BNT162b 2 in all cases	2 nd in all cases	Mean 2.76 days	chest pain, shortness of breath, fever and myalgia	Elevated in all cases	LVEF >50% in 11 cases LVEF <50% in 2 cases	Abnormal in 9 cases and normal in 4 cases	NSAIDs	Mean 2 days	Recovered
Shumkova et al 2021 [46]	Poland	23 years	Male	BNT162b 2	2 nd	1 day	chest pain, shortness of breath and fever	Elevated	LVEF >50%	Abnormal	Aspirin and methylprednisolone	6 days	Recovered
Minocha et al 2021 [47]	USA	17 years	Male	BNT162b 2	2 nd	2 days	chest pain	Elevated	LVEF >50%	Abnormal	NSAIDs	6 days	Recovered
Hasnie et al 2021 [48]	USA	22 years	Male	mRNA-1273	1 st	3 days	Chest pain	Elevated	LVEF >50%	Abnormal	Aspirin and colchicine	2 days	Recovered
Starekova et al 2021 [49]	USA	5 cases mean age 25.2 years	4 males and 1 female	BNT162b 2 in 3 cases and mRNA-1273 in 2 cases	2 nd in all cases	Mean 2,6 days	Chest pain, fatigue, nausea, fever, chills and myalgia	Elevated in all cases	LVEF >50% in 4 cases LVEF <50% in 1 case	Abnormal in 4 cases and normal in 1 case	Unknown	Unknown	Recovered
Koizumi et al 2021 [50]	Japan	2 cases mean age 24.5 years	All of them were male	mRNA-1273 in all cases	2 nd in all cases	Mean 2.5 days	Chest pain	Elevated in all cases	LVEF >50% in all cases	Abnormal in all cases	NSAIDs	Mean 4 days	Recovered
McLean et al 2021 [51]	USA	16 years	Male	BNT162b 2	2 nd	1 day	Chest pain	Elevated	LVEF >50%	Abnormal	NSAIDs	7 days	Recovered
Riedel et al 2021 [52]	Brazil	47 years	Male	Sinovac COVID-19 vaccine in activated (China)	2 nd	Unknown	Chest pain Cough and myalgia	Elevated	LVEF <50%	Abnormal	Unknown	Unknown	Recovered
In-Cheol et al 2021 [53]	Korea	24 years	Male	BNT162b 2	2 nd	1 day	Chest pain	Elevated	LVEF >50%	Abnormal	Unknown	5 days	Recovered
Nguyen et al 2021 [54]	Germany	20 years	Male	mRNA-1273	1 st	1 day	Chest pain, fatigue and myalgia	Elevated	LVEF >50%	Abnormal	Unknown	Unknown	Recovered
Azdaki et al 2021 [55]	Iran	70 years	Male	ChAdOx1 nCoV-19.	1 st	3 days	Syncope	Elevated	LVEF >50%	Abnormal	magnesium sulfate	7 days	Recovered
Sokolska et al 2021 [56]	Poland	21 years	Male	BNT162b 2	1 st	3 days	Chest pain	Elevated	LVEF >50%	Abnormal	Unknown	Unknown	Recovered
Patel et al 2021 [57]	USA	5 cases mean age 23.2 years	All of them were male	BNT162b 2 in 4 cases and mRNA-1273 in 1 case	2 nd in 4 cases and 1 st in 1 case	Mean 2.2 days	Chest pain, dyspnea, nausea, headache and chills	Elevated in all cases	LVEF >50% in all cases	Abnormal in all cases	Colchicine, Ibuprofen and aspirin	Mean 1.8 days	Recovered
Kim et al 2021 [58]	Korea	29 years	Male	BNT162b 2	2 nd	1 day	Chest pain	Elevated	LVEF >50%	Normal	corticosteroids and NSAIDs.	7 days	Recovered
Ehrlich et al 2021 [59]	Germany	40 years	Male	BNT162b 2	1 st	6 days	chest pain and shortness of breath, and fever	Elevated	LVEF <50%	Abnormal	Aspirin, heparin, beta-blocker and a mineralocorticoid antagonist	2 days	Recovered

Schmitt et al 2021 [60]	France	19 years	Male	BNT162b 2	2 nd	3 days	Chest pain and dyspnea	Elevated	LVEF >50%	Abnormal	Unknown	1 day	Recovered
Kadwalwala et al 2021 [61]	USA	38 years	Male	mRNA-1273	1 st	2 days	Chest pain, fatigue and fever	Elevated	LVEF <50%	Abnormal	Methylprednisolone, lisinopril, and spironolactone	6 days	Recovered
Azir et al 2021 [62]	USA	17 years	Male	BNT162b 2	2 nd	1 day	Chest pain	Elevated	LVEF >50%	Abnormal	aspirin and sublingual nitroglycerin	1 day	Recovered

Table 2: Summary of pooled data from included research papers have been reported in the literature (n = 147)

Age	Mean age - 28.94 years
Gender (n) %	Male – 138 (93.9%)
	Female – 9 (6.1%)
Type of COVID-19 vaccine (n) %	Pfizer-BioNTech (BNT162b2) – 106 (72.1%)
	Moderna COVID-19 Vaccine (mRNA-1273) - 36 (24.5%)
	Janssen (Johnson & Johnson) (Ad26.COV2. S) – 2 (1.3%)
	Oxford, AstraZeneca COVID-19 vaccine ChAdOx1 nCoV-19 – 2 (1.3%)
	Sinovac COVID-19 vaccine in activated – 1 (0.7%)
Dose (n) %	First dose – 19 (12.9%)
	Second dose – 128 (87.1%)
Days to symptom onset	Median 3.32 days
Symptoms (n) %	Chest pain - 147 (100%)
	Fever – 69 (46.9%)
	Myalgia/body aches – 80 (54.4)
	Shortness of breath – 11 (7.5%)
Troponin level (n) %	Elevated – 145 (98.6%)
	Not elevated – 1 (0.6%)
	Unknown – 1 (0.6%)
LVEF (n) %	LVEF >50% - 108 (73.5%)
	LVEF <50% - 39 (26.5%)
Electrocardiogram (ECG) (n) %	Abnormal – 130 (88.5%)
	Normal – 17 (11.5%)
Length of hospital stay (days)	Median 5.2 days in 127 patients
	Unknown in 20 patients
Outcome (n) %	Recovered – 137 (93.2%)
	Under follow-up – 7 (4.7%)
	Died – 3 (2%)