

Effect of Platelet OIC on ACL Surgery

**TUNNEL WIDENING OF ACL RECONSTRUCTION AUGMENTED BY AN
PLATELET RICH OSTEOCONDUCTIVE-OSTEOINDUCTIVE ALLOGRAFT
COMPOUND: A RANDOMIZED BLIND-ANALYSIS PILOT STUDY**

Ruth Solomon¹, Jan Pieter Hommen², Francesco Travascio^{1,3,4,5*}

¹Department of Industrial Engineering, University of Miami, Coral Gables, FL

²Department of Orthopedics, Florida International University, Miami, FL

³Department of Mechanical and Aerospace Engineering, University of Miami, Coral Gables, FL

⁴Department of Orthopaedic Surgery, University of Miami, Miami, FL

⁵Max Biedermann Institute for Biomechanics at Mount Sinai Medical Center, Miami Beach, FL

Submitted to PLOS ONE on February the 22nd, 2022

*Corresponding author:

Dr. Francesco Travascio, PhD
Associate Professor
College of Engineering
University of Miami
1251 Memorial Drive, MEB 276
Coral Gables, FL 33146
USA
Telephone: +1-(305)-284-2371
Fax: +1-(305)-284-4040
f.travascio@miami.edu

Funding

The project described was supported by Grant Number GR004579 from Arthrex, Inc.

This study was registered at clinicaltrials.gov NCT04993339

Effect of Platelet OIC on ACL Surgery

ABSTRACT

Background: The anterior cruciate ligament (ACL) is a commonly injured ligament in the knee. Bone tunnel widening is a known phenomenon after soft-tissue ACL reconstruction and etiology and clinical relevance have not been fully elucidated. Osteoconductive compounds are biomaterials providing an appropriate scaffold for bone formation such as demineralized bone matrix. Osteoinductive materials contain growth factors stimulating bone lineage cells and bone growth. A possible application of osteoinductive/osteoconductive (OIC) material is in ACL surgery.

Questions/Purposes: We hypothesized that OIC placed in ACL bone tunnels: 1) reduces tunnel widening, 2) improves graft maturation and 3) reduces tunnel ganglion cyst formation. To test this hypothesis, this study evaluated the osteogenic effects of demineralized bone matrix (DBM) and platelet rich plasma (PRP) on tunnel widening, graft maturation, and ganglion cyst formation.

Study Design: Randomized controlled clinical trial pilot study.

Methods: A total of 26 patients electing ACL reconstruction surgery were randomized between OIC and control group. Measurements of tunnel expansion and graft-tunnel incorporation were conducted via quantitative image analysis of MRI scans performed at six months after surgery for both groups.

Results: No patients had adverse post-operative reactions or infections. The use of OIC significantly reduced tunnel widening ($p < 0.05$) and improved graft maturation ($p < 0.05$). Patients treated with OIC presented with a significantly lower prevalence of ganglion cyst compared to the control group ($p < 0.05$).

Conclusion: The use of OIC has measurable effects on the reduction of tunnel widening, improved graft maturation and decreased size of ganglion cyst after ACL reconstruction.

Clinical Relevance: This study explored the utilization of biologics to minimize bone tunnel widening in ACL reconstruction surgery.

Effect of Platelet OIC on ACL Surgery

1. INTRODUCTION

Anterior cruciate ligament (ACL) reconstruction surgery is a standard treatment with more than 100,000 procedures performed annually in the United States [2, 4, 16, 20, 34]. The surgery aims to restore knee stability and improve the patient's quality of life. Historically, the success rate of ACL surgery in returning patients to their previous level of sports activity ranges between 75-90% [17]. However, the process of rehabilitation after ACL injury can last for several months or even years, and represents a significant psychological and economic burden for the patient [42].

Bone tunnel widening is a known phenomenon after ACL reconstruction and has a significant correlation with the utilization of all-soft tissue grafts [5]. The largest percentage of tunnel widening occurs during the first six weeks after surgery and can continue over two years after surgery [32]. The incidence of tunnel widening ranges from 25 to 100% and 29 to 100% in femoral and tibial tunnels respectively [9, 14, 28, 33]. Graft fixation implants including cortical fixation devices and bioabsorbable interference screws have been correlated with increased tunnel widening [8]. The etiology of widening is multifactorial, including mechanical factors (e.g., tunnel mal-positioning, graft motion wind-shield wiper effect, longitudinal elongation bungee-cording etc.), bone necrosis from the drilling technique, early rehabilitation, cytokine induced bone resorption, and synovial fluid ingress into the bone tunnels [5, 8]. Although the correlation of tunnel widening and clinical outcomes remains unclear, significant widening of the tunnels may complicate revision surgery [23].

Osteoinductive/osteoconductive compounds (OIC) are biomaterials characterized by bioactive properties: they provide an appropriate scaffold for bone formation (osteoconductivity) and are able to bind and concentrate endogenous bone morphogenetic proteins (BMP) (osteoinductivity) in circulation, thus promoting osteogenesis [19]. The use of demineralized bone matrix (DBM) has gained popularity in ACL reconstruction. DBM is a type I collagen matrix of allograft bone that remains after extensive

Effect of Platelet OIC on ACL Surgery

processing of removing blood, cells, and minerals. The final result is a small particulate which can be applied to form a three-dimensional scaffold (osteoconductive) with osteogenic growth factors like BMPs, a family of transforming growth factor- β (TGF- β). Moreover, autologous platelet-rich plasma (PRP) is a concentrated solution of a patient's own platelets (or thrombocytes). By centrifuging the patient's whole blood, the red blood cells can be separated from the serum containing the concentrated platelets. Activated platelets have demonstrated osteoinductive properties on mesenchymal stem cells [43]. A possible application of DBM and PRP is to facilitate the osseointegration of the ACL graft into the bone tunnels to minimize tunnel widening and improve the structural stability of the graft construct. This in turn may allow the knee joint to adapt to bearing physiological mechanical loads sooner, with ultimately faster recovery of the patient.

As an initial step to validate our research hypothesis, this pilot study aimed to observe the osteogenic effects of DBM and PRP on tunnel widening, graft maturation, and tunnel ganglion cyst formation relative to control groups.

2. 2. METHODS

2.1 Patients allocation: Twenty-seven patients (twenty-eight knees) were prospectively enrolled in a randomized controlled trial from 2016 to 2019. Patients were randomized to the OIC group after electing to have surgery. There were a total of 13 patients in the OIC group and 14 in the control group. There were 14 males and 12 females with an average age of 31 y.o. One patient declined to participate to the study after undergoing treatment, and four others were lost to follow-up MRI. The Reporting Trials flow diagram is shown in figure 1. The demographic data of all participants are summarized in Table 1. The experimental protocol was approved by the Institutional Review Board at the University of Miami. All subjects provided written consent prior to participation in the study. All the surgical

Effect of Platelet OIC on ACL Surgery

procedures were performed by JPH. Data analysis was conducted at the University of Miami and the Hommen Orthopedic Institute.

2.2 Inclusion and Exclusion Criteria: Inclusion criterion was indication for primary anterior cruciate ligament reconstruction with all-soft tissue allografts fashioned into a GraftLink® (Arthrex, Inc., Naples, FL) construct with cortical button fixation on the tibia and femur. Exclusion criteria were revision surgery, multi-ligament surgery, autografts, and patients under 18 years of age. Excluded patients were: 32 autografts, 9 ACL repairs, 7 revisions, 5 multi-ligaments, and 19 with interference screw fixation. Patients with concomitant procedures were included: 14 with meniscus repair (9 OIC, 5 control), 4 with partial meniscectomy (1 OIC, 3 control), and 3 with chondroplasty (0 OIC, 3 control).

2.3 Surgical Procedures: Patients randomized to the OIC group had blood drawn in the pre-op holding area, which was subsequently prepared utilizing the Arthrex ACP® system to yield platelet rich plasma (PRP). The PRP was mixed with 5 ml of StimuBlast® (Arthrex, Inc., Naples, FL). The graft was constructed using an allograft peroneus longus tendon with an ACL Tightrope® button (Arthrex, Inc., Naples, FL) at each end. The femoral and tibial tunnels were reamed to match the graft size. We utilized a low-profile reamer through a medial portal to create the femoral tunnel and a FlipCutter® (Arthrex, Inc., Naples, FL) for the tibia tunnel. Prior to docking the graft into the femoral and tibial sockets in the OIC group, 1 to 2 ml of mixed PRP/DBM was injected via a syringe into each tunnel with the arthroscopic irrigation turned off to avoid extravasation. The graft was then secured into the sockets utilizing the tension-slide button mechanism. Additional PRP/DBM was injected into both tunnels at the graft-bone interface after securing the graft. Concomitant meniscus pathology was addressed by meniscectomy or repaired utilizing the surgeon's choice of an all-inside, inside-out, or outside-in technique. Chondral injuries were addressed with chondroplasty. A hinged knee brace was

Effect of Platelet OIC on ACL Surgery

placed postoperatively for three weeks for isolated ACL reconstructions and six weeks for concomitant meniscus repairs. Immediate weight bearing as tolerated versus partial foot flat weight bearing was allowed for isolated ACL reconstructions and meniscus repairs, respectively.

2.4 MRI scanning protocol: The intra-articular graft, tunnels, and graft-tunnel interface were assessed using a 1.5T MR System (Optima MR430s; GE Healthcare) with sequences in the sagittal and coronal planes as well as axial cuts perpendicular to the femoral and tibia tunnels. A summary of the parameters used in the MRI scanning protocol is reported in Table 2.

2.5 Measurement of tunnel widening: All measurements were conducted by a researcher blinded to treatment allocation prior to statistical analysis. Measurements of both tunnel expansion and graft maturation were conducted via quantitative image analysis of MRI scans performed at six months after surgery for both groups. Measurements of the tibial and femoral tunnel widening diameters were conducted using an established approach [6]. The femoral tunnel and tibial tunnels were measured at four points: the aperture, midpoint, tunnel end, and at the greatest tunnel diameter by taking the measurement of the diameter perpendicular to the tunnel, see Figure 2A-F. The tunnel expansion was calculated in the femur and tibia by subtraction of the initial surgical tunnel diameters from the largest measurement taken in each respective region. The quantity of patients with moderate (5mm) and large (10mm+) tunnel expansion was also noted for each group.

2.6 Measurement of graft maturation: Graft maturation was quantified using a previously reported approach to evaluate the signal/noise quotient (SNQ) by taking the average intensity across three areas of the ACL graft: the proximal, central, and distal intra-articular regions [11, 22, 37], see Figure 3. The measurement of SNQ was carried out as follows: in correspondence of each region where the measurement was performed, a circular region of interest of 5-mm diameter was defined and the signal intensity from the MRI scan was measured and averaged across the region (S_{ROI}). In a similar manner,

Effect of Platelet OIC on ACL Surgery

the signal intensity (S_{PCL}) was also measured in the intact PCL with the purpose of normalizing the signal intensities measured in the ACL graft. To eliminate background noise, the signal intensity (S_{BACK}) was also measured at a background region of interest 2 cm anterior to the patellar tendon. The SNQ was then calculated using the following equation [39]:

$$SNQ = (S_{ROI} - S_{PCL}) / S_{BACK} \quad (1)$$

2.7 Tunnel ganglion cyst formation: Additionally, patients with tunnel ganglion cysts were quantified for each group by the blinded radiologist. Post-surgical graft failures were also assessed.

2.8 Statistical Analysis: All the statistical analyses were conducted in Minitab® 19.2 (Minitab.LLC, State College, PA). A Mann-Whitney test was utilized to assess differences in tunnel expansion associated with OIC and Control groups in both femur and tibia tunnels. A similar approach was used to infer possible differences in tunnel diameter measurements between the femur and tibia. A quantifiable difference in proportion of ganglion cyst formation between the OIC and Control groups was determined and compared via a Chi-Squared test with Yates correction. Differences in measurements of SNQ were also investigated via Mann-Whitney test to compare OIC to Control groups within the intra-articular region. For each test conducted, a level of significance of 0.05 ($\alpha = 0.05$) was used. All the data were reported in terms of mean \pm standard deviation.

3. RESULTS

No patients had adverse post-operative reactions or infections. One patient in the OIC group suffered graft failure 3 months postoperative after falling on a boat. No other participants of the study presented with graft failure.

3.1 Tunnel Widening.

Effect of Platelet OIC on ACL Surgery

A summary of the measurements of average tunnel expansion are reported in Figure 4. A summary of the tunnel expansion and their categorical sizes are shown in Tables 3 and 4. A significant difference was determined in femoral tunnel expansion ($P=0.00736$) between the OIC ($1.00 \pm 0.64mm$) vs. Control group ($2.46 \pm 1.44mm$). Additionally, a significant difference in tibial tunnel expansion ($P=0.0001$) was found between the OIC ($1.08 \pm 0.63mm$) and Control group ($4.13 \pm 2.32mm$). For the Control group, the tibial tunnel expansion ($4.13 \pm 2.32mm$) was found to be larger ($P=0.046$) than the femoral tunnel expansion ($2.46 \pm 1.47mm$). However, no significant difference was found between the femoral and tibial expansion of the OIC group ($P>0.05$).

3.2 Graft maturation.

A 1-tailed Mann Whitney test showed a decreased SNQ in OIC group ($2.28 \pm 1.97mm$) when compared to the Control group ($4.28 \pm 2.55mm$) ($P=0.04363$).

3.3 Tunnel ganglion cyst formation.

Two of the ten OIC patients (20%) and eight of the eleven Control patients (72.72%) presented with ganglion cysts in the tibial tunnel. The difference between these proportions was statistically significant ($P=0.048$).

4. DISCUSSION

Injury at the ACL may represent a significant psychological and economic burden to patients, given the lengthy recovery process [42]. There is significant research aimed at increasing the rate of graft-to-tunnel incorporation and graft maturation [3, 38] as well as reducing the recovery time after surgery via innovative rehabilitation modalities [17]. Since OIC materials have been heralded as osteogenic [19], we hypothesized that the injection of these materials into the bone tunnel would enhance graft incorporation and graft maturation. Aimed at testing this hypothesis, we compared the use of DBM

Effect of Platelet OIC on ACL Surgery

combined with PRP in soft-tissue graft reconstructions to a control group, and monitored the post-operative events of tunnel widening, graft maturation and tunnel ganglion cyst formation through a quantitative analysis of MRI images. We adopted StimuBlast®, a DBM, due to its osteoconductive and inductive properties. The DBM is manufactured with a reverse phase medium that allows it to be fluid-phased during handling and more viscous at body temperature. The DBM putty was augmented with anabolic properties of ACP®, a leukocyte-poor PRP, to promote the healing response during the phases of inflammation, cellular proliferation, and subsequent tissue remodeling. Unlike leukocyte-rich PRP, this does not induce the potential catabolic cytokines such as interleukin-1 β , tumor necrosis factor- α , and metalloproteinases involved in the inhibition of bone-tunnel osteointegration [36]. The intra-operative application of DBM/PRP is relatively simple for the surgeon and assistants. The mixture is easily mixed and can be readily injected from a syringe through a curved needle applicator into the tunnels. Once placed, the mixture is viscous enough to remain in the tunnels and becomes more viscous at body temperature.

Tunnel widening has several implications after ACL surgery including the possibility of postoperative tibia stress fractures [7, 24, 35] and delays or failures of graft incorporation [31]. In the setting of revision surgery, significant tunnel widening may require a bone grafting procedure followed by subsequently staged ACL revision surgery [23, 32]. The presence of ganglion cysts within the tunnels has been associated with possible incomplete graft-bone incorporation [10, 15]. Tunnel widening and ganglion cysts formation may represent a localized osteolytic process due to a cell-mediated cytokine response [44]. Our results indicate that the use of DBM and PRP: 1) significantly reduced tunnel widening, 2) had a positive effect on graft maturation, and 3) reduced presence of ganglion cyst formation within the tibial tunnel.

Effect of Platelet OIC on ACL Surgery

It should be noted that the present contribution is a pilot study, and its findings do not allow establishing causal relationships among the DBM/PRP injected and the postoperative outcomes. Nevertheless, we postulate that the use of DBM/PRP may have enhanced the organization of the fibrocartilage insertion and mineralization, as well as reduced the cell-mediated osteolysis at the graft-bone interface. In animal studies, the use of DBM has been shown to create a 4-zone fibrocartilage tendon-to-bone healing [12]. In a rabbit model, Anderson et al. wrapped a BMP and TGF- β soaked collagen sponge around the graft inside the tunnel. Histologically, they observed more consistent bone-to-graft apposition and a fibrocartilaginous interface relative to controls at 2, 4 and 8 weeks. Biomechanically, the grafts also demonstrated significantly increased ultimate tensile strength at 2 and 8 weeks [1]. It has been proposed that synovial cytokines, such as TNF- α , interleukin 1 β , IL-6, BMPs, and nitric oxide may mediate ACL tunnel widening [44]. DBM/PRP may have served as a grout, limiting the ingress of synovial fluid into at the interface between the graft and tunnel wall. The use of DBM/PRP may also have improved the location of graft fixation within the tunnel. In the control group, the graft relied solely on cortical suspensory fixation which may have led to increased graft motion due windshield wiper and bungee cord effects [30]. Instead, in the treatment group, the grafts were “potted” into a DBM/PRP putty which may have resulted in more aperture fixation and less micromotion. If DBM/PRP can enhance osteointegration of the graft within the tunnels, this may lead to earlier graft “ligamentization”, or maturation, due to increased revascularization of the implanted graft, as may have been demonstrated by the MRI signal intensity findings in our study [25, 39].

Several studies have investigated the effects of injectable OICs in tendon-to-bone healing. Animal studies conducted on rats [40], dogs [13], rabbits [18, 41] and goats [27] have found accelerated graft-to-bone healing rates with calcium phosphate. In fact, Ma et al. demonstrated that calcium phosphate could deliver increased local BMPs in tendon-to-bone healing [21]. Accordingly, in a

Effect of Platelet OIC on ACL Surgery

randomized controlled human trial, Mutsuzaki et al. used calcium phosphate on 64 patients with follow-ups at 1 and 2 years [26]. At 1 year, tunnel expansion in patients treated with calcium phosphate was reduced by approximately 7% when compared to the control group. The use of calcium phosphate remains controversial due to its potentially slow degradation rate, which may slow osteointegration [29].

As a pilot study, we used a convenience sample of 26 patients performed by a single surgeon. A multicenter study, including a larger sample size and more surgeons will be needed to confirm the preliminary evidence reported in this contribution. Another limitation of this study is the short observation period of less than 1 year as a longer-term analysis may show larger differences in graft incorporation and maturation between OIC and Control groups.

In conclusion, an *in vivo* study was conducted to evaluate the effects of an injectable OIC compound on the graft incorporation and tunnel widening after ACL reconstructive surgery. The results of this investigation indicate that the injection of OIC has measurable effects on the reduction of tunnel widening and ganglion formation and enhanced graft maturation after ACL reconstruction. A comparison of our findings to those of previous studies suggests that the benefits of augmenting ACL reconstruction with the injection of OIC may be observed within one year after surgery. The use of osteogenic compounds may enhance ACL reconstruction graft incorporation and thereby promote earlier rehabilitation and return to sports.

Effect of Platelet OIC on ACL Surgery

REFERENCES

1. Anderson K, Seneviratne AM, Izawa K, Atkinson BL, Potter HG, Rodeo SA. Augmentation of tendon healing in an intraarticular bone tunnel with use of a bone growth factor. *The American journal of sports medicine* 2001; 26: 689-698.
2. Bach BR. Revision anterior cruciate ligament surgery. *Arthroscopy* 2003; 19: 14-29.
3. Beasley LS, Weiland DE, Vidal AF, Chhabra A, Herzka AS, Feng MT, West RV. Anterior cruciate ligament reconstruction: A literature review of the anatomy, biomechanics, surgical considerations, and clinical outcomes. *Operative Techniques in Orthopaedics* 2005; 15: 5-19.
4. Buller LT, Best MJ, Baraga MG, Kaplan LD. Trends in anterior cruciate ligament reconstruction in the United States. *Orthopaedic journal of sports medicine* 2014; 3: 2325967114563664.
5. Clatworthy MG, Annear P, Bulow JU, Bartlett RJ. Tunnel widening in anterior cruciate ligament reconstruction: a prospective evaluation of hamstring and patella tendon grafts. *Knee Surgery, Sports Traumatology, Arthroscopy* 1999; 7: 138-145.
6. Drews BH, Merz C, Huth J, Gulkin D, Guelke J, Gebhard F, Mauch F. Magnetic resonance imaging in evaluation of tunnel diameters prior to revision ACL reconstruction: a comparison to computed tomography. *Skeletal radiology* 2017; 46: 1361-1366.
7. El-Hage ZM, Mohammed A, Griffiths D, Richardson JB. Tibial plateau fracture following allograft anterior cruciate ligament (ACL) reconstruction. *Injury* 1998; 29: 73-74.
8. Foldager C, Jakobsen BW, Lund B, Christiansen SE, Kashi L, Mikkelsen LR, Lind M. Tibial tunnel widening after bioresorbable poly-lactide calcium carbonate interference screw usage in ACL reconstruction. *Knee Surgery, Sports Traumatology, Arthroscopy* 2010; 18: 79-84.
9. Fules PJ, Madhav RT, Goddard RK, Newman-Sanders A, Mowbray MA. Evaluation of tibial bone tunnel enlargement using MRI scan cross-sectional area measurement after autologous hamstring tendon ACL replacement. *The Knee* 2003; 10: 87-91.
10. Ghazikhanian V, Beltran J, Nikac V, Feldman M, Bencardino JT. Tibial tunnel and pretibial cysts following ACL graft reconstruction: MR imaging diagnosis. *Skeletal radiology* 2012; 41: 1375-1379.
11. Grassi A, Bailey JR, Signorelli C, Carbone G, Wakam AT, Lucidi GA, Zaffagnini S. Magnetic resonance imaging after anterior cruciate ligament reconstruction: a practical guide. *World journal of orthopedics* 2016; 7: 638.
12. Hexter AT, Pendegrass C, Haddad F, Blunn G. Demineralized bone matrix to augment tendon-bone healing: a systematic review. *Orthopaedic Journal of Sports Medicine* 2017; 5: 2325967117734517.
13. Huangfu X, Zhao J. Tendon-bone healing enhancement using injectable tricalcium phosphate in a dog anterior cruciate ligament reconstruction model. *Arthroscopy: The Journal of Arthroscopic & Related Surgery* 2007; 23: 455-462.
14. Jansson KA, Harilainen A, Sandelin J, Karjalainen PT, Aronen HJ, Tallroth K. Bone tunnel enlargement after anterior cruciate ligament reconstruction with the hamstring autograft and endobutton fixation technique A clinical, radiographic and magnetic

Effect of Platelet OIC on ACL Surgery

- resonance imaging study with 2 years follow-up. *Knee Surgery, Sports Traumatology, Arthroscopy* 1999; 7: 290-295.
15. Joshi YV, Bhaskar D, Phaltankar PM, Charalambous CP. Tibial Tunnel Cyst Formation after Anterior Cruciate Ligament Reconstruction Using a Non-Bioabsorbable Interference Screw. *Knee surgery & related research* 2015; 27: 269.
 16. Kim S, Bosque J, Meehan JP, Jamali A, Marder R. Increase in outpatient knee arthroscopy in the United States: a comparison of National Surveys of Ambulatory Surgery, 1996 and 2006. *JBJS* 2011; 93: 994-1000.
 17. Kruse LM, Gray B, Wright RW. Rehabilitation After Anterior Cruciate Ligament Reconstruction. A Systematic Review. *The Journal of Bone & Joint Surgery* 2012; 94: 1737-1748.
 18. Kuang GM, Yau WP, Lu WW, Chiu KY. Local application of strontium in a calcium phosphate cement system accelerates healing of soft tissue tendon grafts in anterior cruciate ligament reconstruction: experiment using a rabbit model. *The American journal of sports medicine* 2014; 42: 2996-3002.
 19. Legeros RZ. Properties of Osteoconductive Biomaterials: Calcium Phosphates. *Clinical Orthopaedic and Related Research* 2002; 395: 81-98.
 20. Lyman S, Koulouvais P, Sherman S, Do H, Mandl LA, Marx RG. Epidemiology of Anterior Cruciate Ligament Reconstruction. *The Journal of Bone & Joint Surgery* 2009; 91: 2321-2328.
 21. Ma CB, Kawamura S, Deng XH, Ying L, Schneidkraut J, Hays P, et al. Bone morphogenetic proteins-signaling plays a role in tendon-to-bone healing: a study of rhBMP-2 and noggin. *The American journal of sports medicine* 2007; 35: 597-604.
 22. Ma Y, Murawski CD, Rahnama-Azar AA, Maldjian C, Lynch AD, Fu FH. Graft maturity of the reconstructed anterior cruciate ligament 6 months postoperatively: a magnetic resonance imaging evaluation of quadriceps tendon with bone block and hamstring tendon autografts. *Knee Surgery, Sports Traumatology, Arthroscopy* 2015; 23: 661-668.
 23. Maak TG, Voos JE, Wickiewicz TL, Warren RF. Tunnel widening in revision anterior cruciate ligament reconstruction. *JAAOS-Journal of the American Academy of Orthopaedic Surgeons* 2010; 18: 695-706.
 24. Mithöfer K, Gill TJ, Vrahas MS. Tibial plateau fracture following anterior cruciate ligament reconstruction. *Knee Surgery, Sports Traumatology, Arthroscopy* 2004; 12: 325-328.
 25. Muramatsu K, Hachiya Y, Izawa H. Serial evaluation of human anterior cruciate ligament grafts by contrast-enhanced magnetic resonance imaging: comparison of allografts and autografts. *The Journal of Arthroscopic & Related Surgery* 2008; 24: 1038-1044.
 26. Mutsuzaki H, Kanamori A, Ikeda K, Hioki S, Kinugasa T, Sakane M. Effect of calcium phosphate-hybridized tendon graft in anterior cruciate ligament reconstruction: a randomized controlled trial. *The American journal of sports medicine* 2012; 40: 1772-1780.
 27. Mutsuzaki H, Sakane M. Calcium phosphate-hybridized tendon graft to enhance tendon-bone healing two years after ACL reconstruction in goats. *Sports Medicine, Arthroscopy, Rehabilitation, Therapy & Technology* 2011; 3: 31.

Effect of Platelet OIC on ACL Surgery

28. Nebelung W. Bone tunnel enlargement after anterior cruciate ligament reconstruction with semitendinosus tendon using Endobutton fixation on the femoral side. *Arthroscopy* 1998; 14: 810-815.
29. Pan W, Wei Y, Zhou L, Li D. Comparative in vivo study of injectable biomaterials combined with BMP for enhancing tendon graft osteointegration for anterior cruciate ligament reconstruction. *Journal of Orthopaedic Research* 2011; 29: 1015-1021.
30. Porter MD, Shadbolt B. Femoral aperture fixation improves anterior cruciate ligament graft function when added to cortical suspensory fixation: an in vivo computer navigation study. *Orthopaedic Journal of Sports Medicine* 2016; 4: 2325967116665795.
31. Rabuck SJ, Baraga M, Fu FH. Anterior Cruciate Ligament Healing and Advances in Imaging. *Clinics in Sports Medicine* 2013; 32: 13-20.
32. Sauer S, Lind M. Bone tunnel enlargement after ACL reconstruction with hamstring autograft is dependent on original bone tunnel diameter. *The Surgery Journal* 2017; 3: e96-e100.
33. Segawa H, Omori G, Tomita S, Koga Y. Bone tunnel enlargement after anterior cruciate ligament reconstruction using hamstring tendons. *Knee Surgery, Sports Traumatology, Arthroscopy* 2001; 9: 206-210.
34. Sudevan PJ, Chandrasekharan J, Sambandam SN, Rohinikumar GJ, Annamalai S, Mounasamy V. Arthroscopic ACL reconstruction using patellar bone tendon autograft and Rigidfix fixation-A midterm functional outcome. *Muscles, Ligaments and Tendons Journal* 2017; 7: 247.
35. Sundaram RO, Cohen D, Barton-Hanson N. Tibial plateau fracture following gracilis-semitendinosus anterior cruciate ligament reconstruction: the tibial tunnel stress-riser. *The Knee* 2006; 13: 238-240.
36. Sundman EA, Cole BJ, Fortier LA. Growth factor and catabolic cytokine concentrations are influenced by the cellular composition of platelet-rich plasma. *The American journal of sports medicine* 2011; 39: 2135-2140.
37. Tashiro Y, Gale T, Sundaram V, Nagai K, Irrgang JJ, Anderst W, Nakashima Y, Tashman S, Fu FH. The graft bending angle can affect early graft healing after anterior cruciate ligament reconstruction: in vivo analysis with 2 years' follow-up. *The American Journal of Sports Medicine* 2017; 45: 1829-1836.
38. Vaisha R, Agarwal AK, Ingole S, Vijay V. Current Trends in Anterior Cruciate Ligament Reconstruction: A Review. *Cureus* 2015; 7: e378.
39. Weiler A, Peters G, Mäurer J, Unterhauser FN, Südkamp NP. Biomechanical properties and vascularity of an anterior cruciate ligament graft can be predicted by contrast-enhanced magnetic resonance imaging: a two-year study in sheep. *The American journal of sports medicine* 2001; 29: 751-761.
40. Weimin P, Dan L, Yiyong W, Yunyu H, Li Z. Tendon-to-bone healing using an injectable calcium phosphate cement combined with bone xenograft/BMP composite. *Biomaterials* 2013; 34: 9926-9936.
41. Wen CY, Qin L, Lee KM, Chan KM. The use of brushite calcium phosphate cement for enhancement of bone-tendon integration in an anterior cruciate ligament reconstruction rabbit model. *Journal of Biomedical Materials Research Part B: Applied Biomaterials: An Official Journal of The Society for Biomaterials, The Japanese Society for Biomaterials, and The Australian Society for Biomaterials and the Korean Society for Biomaterials* 2009; 89: 466-474.

Effect of Platelet OIC on ACL Surgery

42. Wiese-Bjornstal DM, Smith AM, Shaffer SM, Morrey MA. An Integrated Model of Response to Sport Injury: Psychological and Sociological Dynamics. *Journal of Applied Sport Psychology* 1998; 10: 46-69.
43. Yu T, Pan H, Hu Y, Tao H, Wang K, Zhang C. Autologous platelet-rich plasma induces bone formation of tissue-engineered bone with bone marrow mesenchymal stem cells on beta-tricalcium phosphate ceramics. *Journal of Orthopaedic Surgery and Research* 2017; 12: 1-10.
44. Zysk SP, Fraunberger P, Veihelmann A, Dörger M, Kalteis T, Maier M, Pellengahr C, Refior HJ. Tunnel enlargement and changes in synovial fluid cytokine profile following anterior cruciate ligament reconstruction with patellar tendon and hamstring tendon autografts. *Knee Surgery, Sports Traumatology, Arthroscopy* 2004; 12: 98-103.

Effect of Platelet OIC on ACL Surgery

LIST OF TABLES

Table 1. Summary of the demographic data of participants

	OIC (StimuBlast® /PRP)	Control
Male	8	7
Female	5	7
Age at Time of Surgery	32.7±10.5	32.7 ± 12.7 y.o.
Age Range	16 to 50 y.o.	15 to 55 y.o.

Table 2. Summary of MRI scanning parameters by image type. Parameters shown are repetition time (TR), echo time (TE), inversion time (TI), echo train length (ETL), matrix size, field of view (FOV), and slice thickness (with 0 mm gaps)

	TR/TE/TI	ETL	Matrix Size	FOV	Slice thickness
	(msec)			(mm)	(mm)
FSE Sagittal PD	3200/30	10	512 × 256	140	4
FSE Sagittal STIR	4000/36/130	10	256 × 192	160	4
FSE Sagittal (meniscus)	1500/19	10	256 × 224	140	3
FSE Coronal PD	3200/30	10	512 × 256	120	4
FSE Coronal STIR	4000/36/130	10	256 × 192	140	4
FSE Axial PD	3200/30	10	512 × 256	140	4
FSE Axial PD (Additional-perpendicular to graft tunnels)	3000/34-40	10	256 × 224	140	3

Effect of Platelet OIC on ACL Surgery

Table 3. Summary of femoral tunnel expansion by categorical size

	OIC (StimuBlast®/ACP®)	Control
Minimal Expansion (<1mm)	5	0
Mild Expansion (<5mm)	6	11
Moderate Expansion (5-10mm)	0	1
Large Expansion (10+ mm)	0	0

Table 4. Summary of tibial tunnel expansion by categorical size

	OIC (StimuBlast®/ACP®)	Control
Minimal Expansion (<1mm)	4	0
Mild Expansion (<5mm)	8	9
Moderate Expansion (5-10mm)	0	2
Large Expansion (10+ mm)	0	1

Effect of Platelet OIC on ACL Surgery

FIGURES LIST

Figure 1: The chart shows the Consolidated Standards of Reporting Trials flow diagram for this randomized controlled trial with intention to treat analysis.

Figure 2A-F: Measurement of tunnel expansion are shown in diagrams A-F: the femoral tunnel diameter was determined in each region of interest by taking measurement of the diameter perpendicular to the greatest diameter in the (A) sagittal (C) coronal, and (E) axial MRI images; the tibial tunnel diameter was measured in each region of interest by taking the measurement of the diameter perpendicular to the tunnel in the (B) sagittal, (D) coronal, and (F) axial MRI images.

Figure 3: The locations of each region of interest used for the calculation of the SNQ are shown, including S_{PCL} (x), S_{BACK} (y) and the proximal (a), central (b), and distal (c) intra-articular regions, S_{ROI} .

Figure 4: The figure shows the tunnel diameters measured from the post-operative MRI scans. Values for StimuBlast®/ACP® (OIC) (white) and Control (grey) groups are reported for both the femur and tibia.

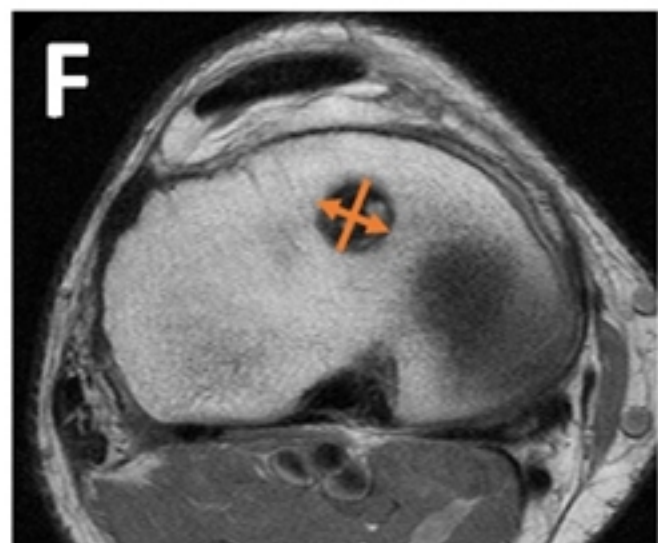
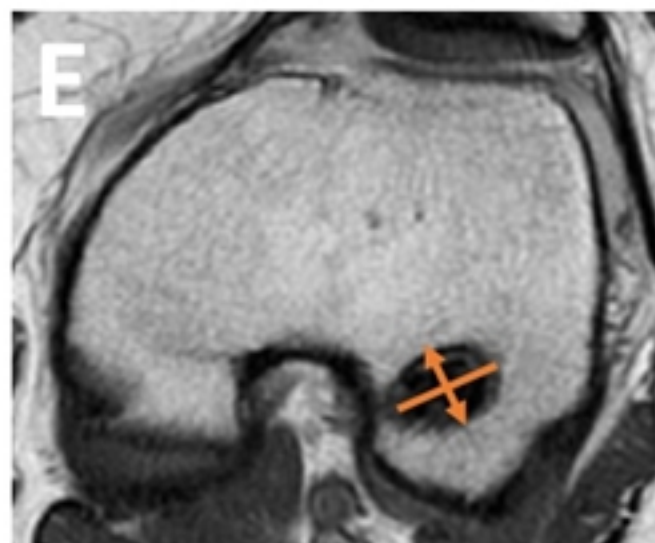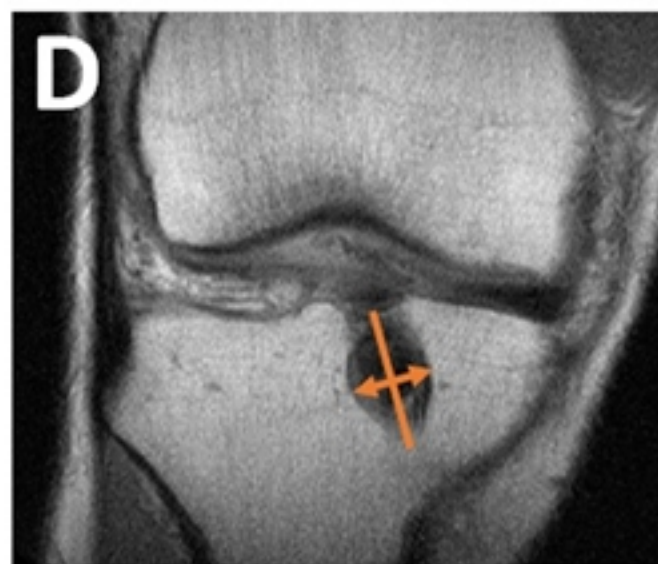
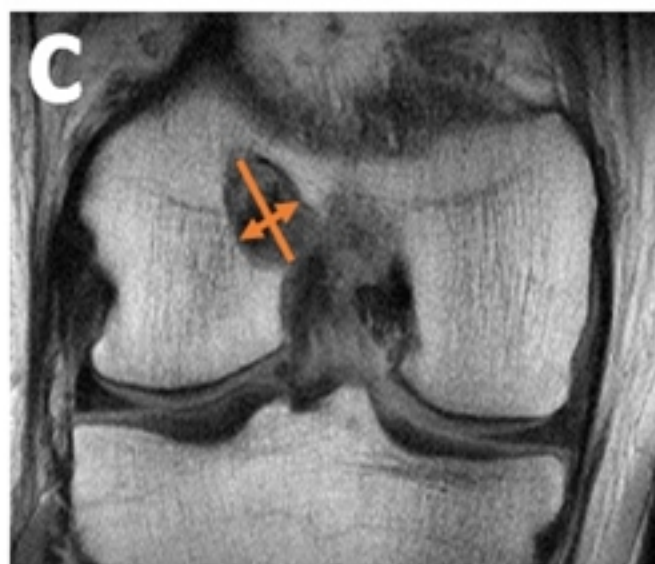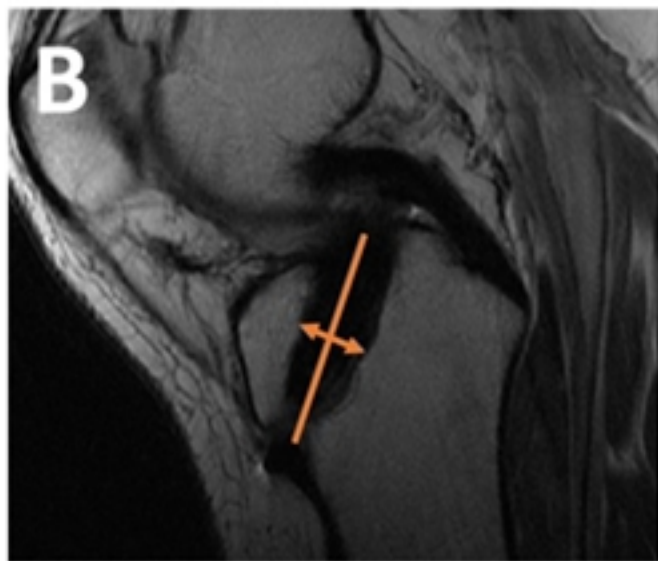
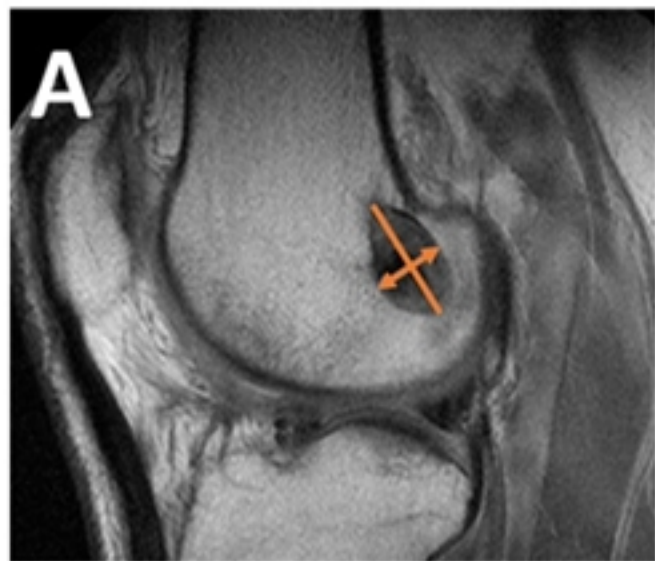


Figure 2

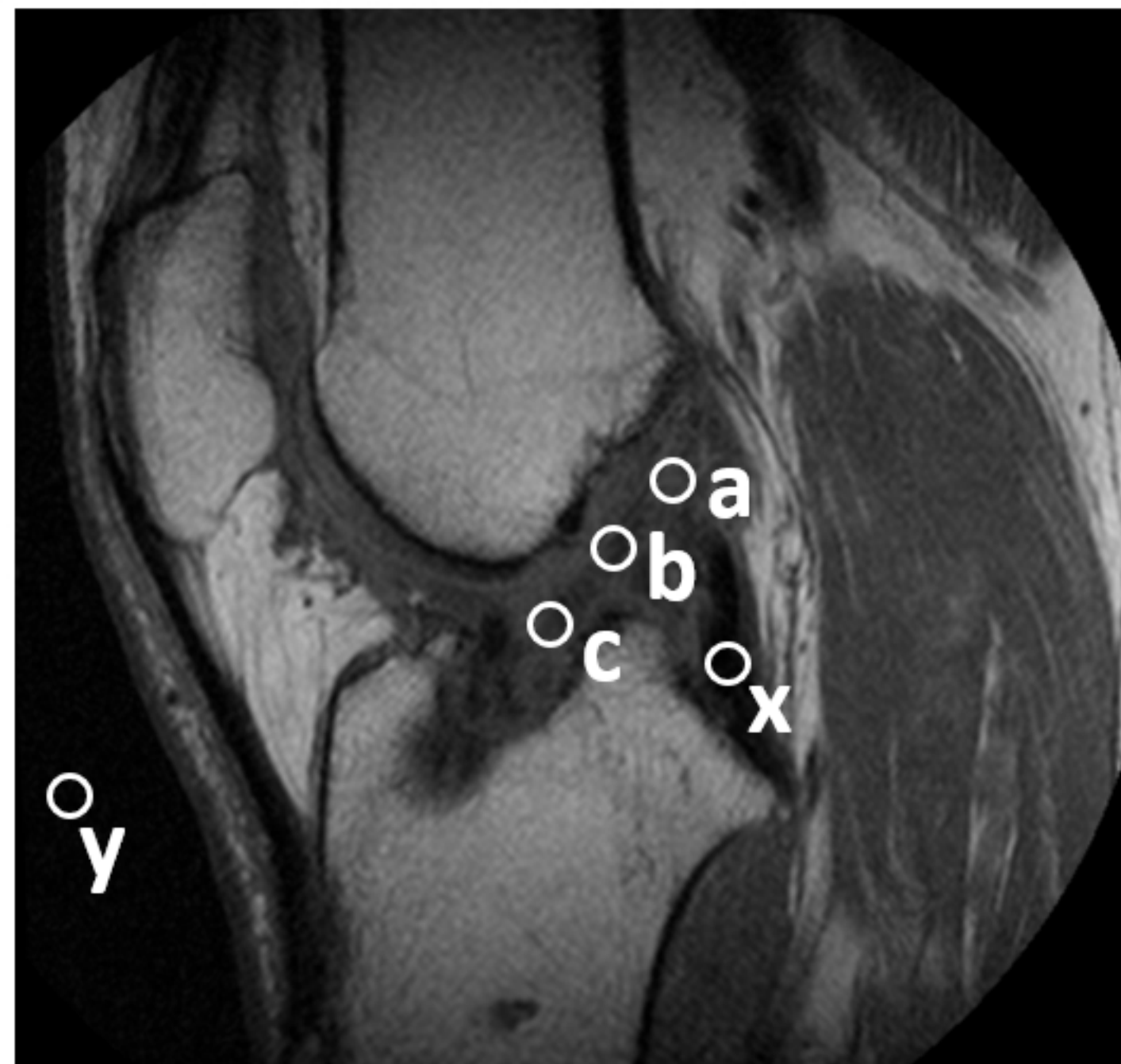


Figure3

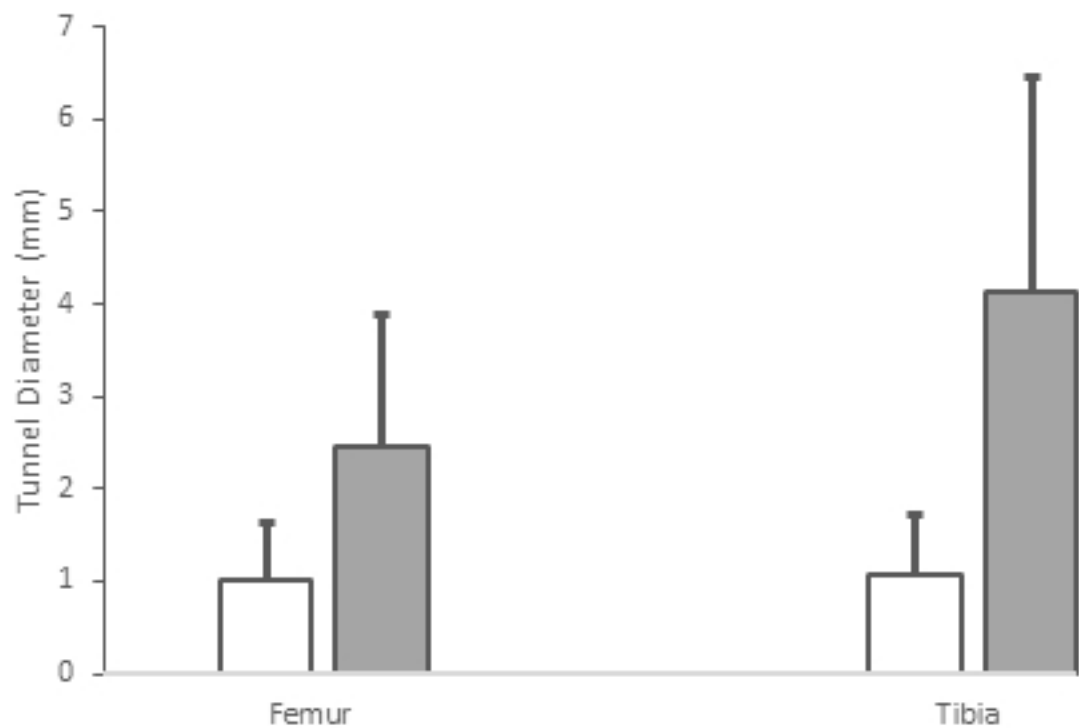


Figure4

CONSORT 2010 Flow Diagram

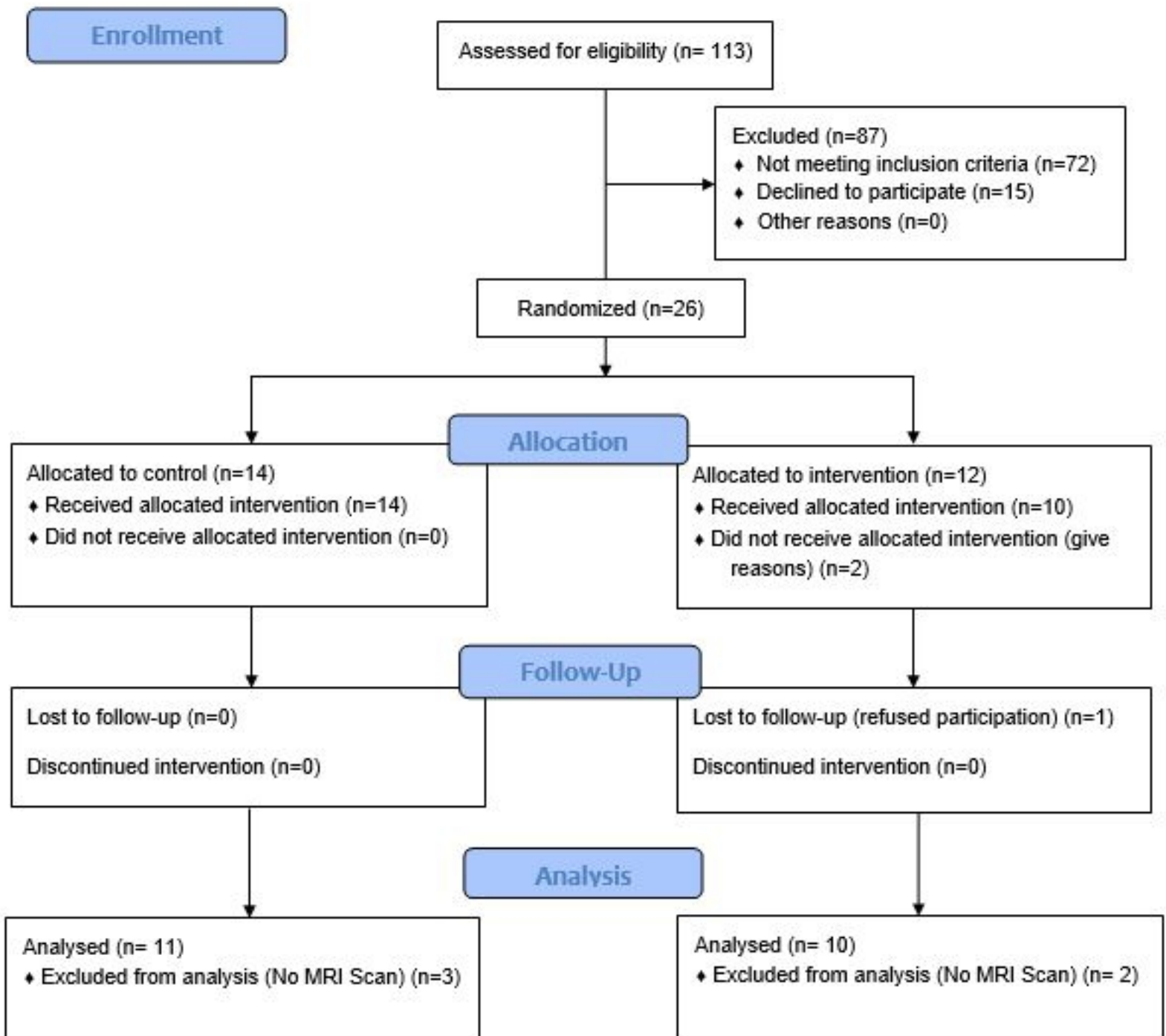


Figure 1