

Heart Block in the Patients with COVID-19

¹Md Ripon Ahammed, MBBS, ¹Medha Sharath, MBBS, ¹Mehul Sinha, MBBS, ¹Cristina Sestacovschi, MD, ¹Varadha Retnakumar, MBBS, ¹Naisargee Solanki, MBBS

¹Research and Academic Affairs, Larkin Community Hospital, South Miami, Florida, USA

Abstract

Background: Since the emergence of the SARS COV-19 pandemic, multiple extrapulmonary manifestations of the virus have been reported from around the world. Cardiovascular complications including arrhythmias in patients with COVID-19 have been described in multiple studies. Our aim was to review various case reports detailing the new onset of heart block in COVID-19 patients and to summarise the clinical course of these patients.

Methods: We systematically reviewed all reports published and indexed in PubMed, Scopus, and Embase between March 2020 to May 2021, analyzing the relation between the demographics of the patients, pre-existing comorbidities, and the progression of heart block in patients infected with COVID-19.

Results: We identified and included in this study 30 relevant articles describing 49 COVID-19 patients with heart block. Among them, 69.3% (n=34) of patients suffered from at least one comorbidity. 36.73% (n=18) of the patients showed spontaneous resolution of the heart block. Conversely, 63.26% (n=31) of the patients had persistent heart block, out of which 16.33% (n=8) and 42.86% (n=21) were implanted with a temporary and permanent pacemaker respectively. The reported mortality rate was 22.45% (n=11) during hospitalization. We noted that 45.45% (n=5) of the patients who died had complete heart block. 24.49% (n=12) of the patients in the studies we reviewed were suspected of having myocarditis. However, none were confirmed with MRI or cardiac biopsy.

Conclusions:

Additional research is necessary to unearth the mechanism of development of heart block in COVID-19 patients as well as its implications on the clinical course and prognosis. Physicians must be aware of the importance of monitoring patients hospitalized for COVID-19 for arrhythmias including heart blocks, especially in the presence of comorbidities. Early detection can improve the prognosis of the patient.

Keywords: Heart Block; Arrhythmia; COVID-19; SARS-CoV-19; Heart

Background:

Since the first reports of atypical pneumonia in Wuhan province of China, the coronavirus disease 2019 (COVID-19) has evolved into a major world health issue. Although pneumonia is the most significant manifestation of severe acute respiratory syndrome coronavirus-2 (SARS-CoV-2) infection¹, a range of extra-pulmonary manifestations have been reported, such as venous thromboembolism, cardiac complications, gastrointestinal abnormalities, acute kidney insult, hepatocellular injury, hyperglycemic state, neurological illnesses and dermatological complications². 14.1% of hospitalized COVID-19 cases have been reported to develop cardiovascular abnormalities which mainly include acute coronary syndrome, arrhythmia, and acute heart failure³; although patients with fulminant myocarditis, pericarditis, cardiac tamponade, Takotsubo cardiomyopathy, and cor pulmonale have also been described⁴⁻⁷. It is recognized that cardiac involvement in COVID-19 leads to a worse prognosis⁸. Ventricular arrhythmias, atrial arrhythmias, sinus bradycardia, heart block, ST-segment changes, and prolonged QTc have all been reported in COVID-19 patients. Meta-analyses have estimated the arrhythmia incidence rate in patients hospitalized for COVID-19 to be from 6.9% to 10.3%^{9,10}.

Heart block is the least documented form of arrhythmia that is seen in COVID-19 patients¹⁰ and the incidence, nature, and impact of this type of arrhythmia among COVID-19 patients is yet to be studied. Hence, the aim of this systematic review is to understand potential patterns of heart block, association with pre-existing comorbidities, and the effect on the clinical course including the outcome of heart block in this group of patients.

METHODS

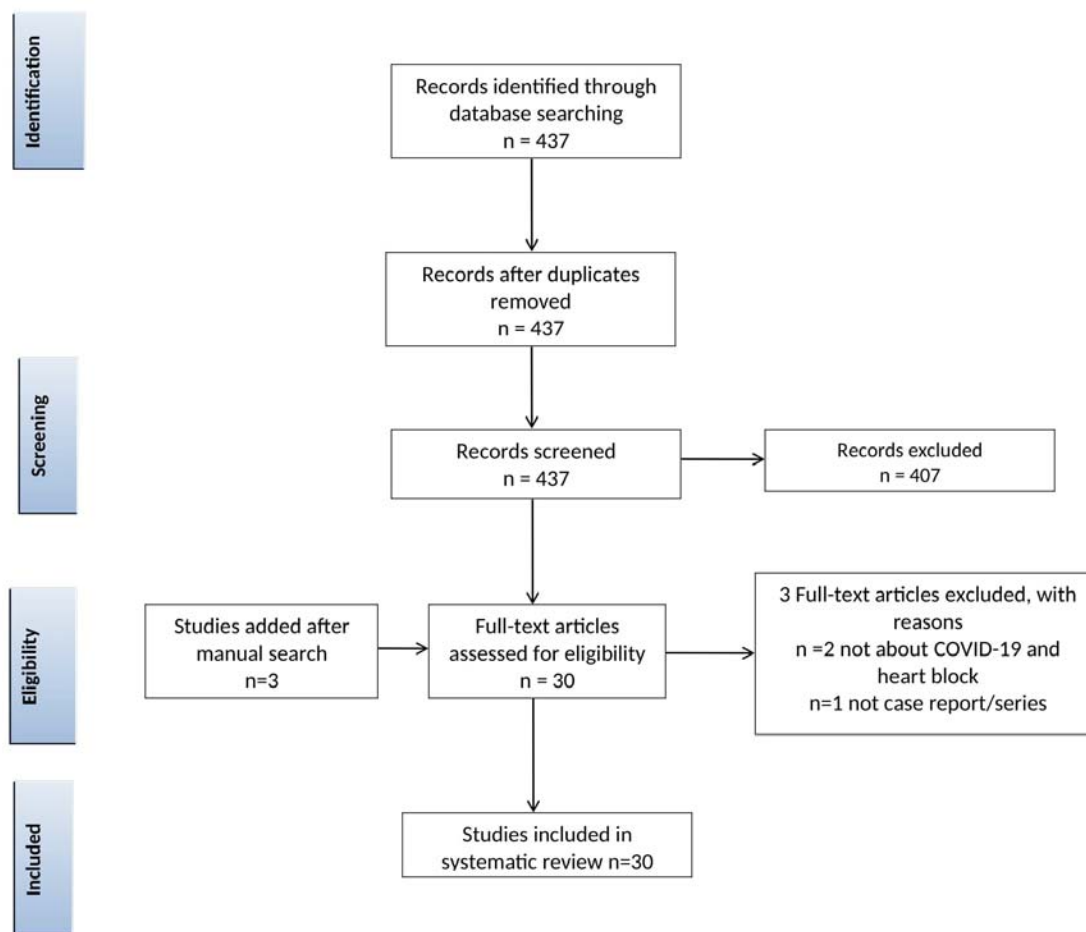
Literature Search

2 researchers (RA, and MS) independently conducted the search and selection of the studies. We included case reports and case series published from March 2020 to May 2021. The systematic search was carried out in May 2021 utilizing PubMed (Medline), Scopus, and Embase. The keywords that we searched for include: heart block OR arrhythmia OR dysrhythmia OR bradyarrhythmia OR brady-arrhythmia OR atrioventricular block OR atrioventricular block AND novel coronavirus OR new coronavirus OR nCoV OR Cov-2 OR Cov2 OR COVID AND case OR case report OR case reports OR case series.

Screening, Inclusion and Exclusion Criteria

There was no pre-specified exposure/ intervention, comparison groups, or outcomes as we intended to summarize all available case reports of COVID-19 and heart block. Titles, abstracts, and full-texts were screened by RA and MS independently. Letters to the editor, commentaries, systematic reviews, meta-analyses, and duplicates were excluded. Figure 1 is the PRISMA flow diagram which shows the selection process of our study. Our search criteria yielded the identification of 437 articles. 407 articles were excluded after screening. 2 articles were further

excluded after review since they did not describe heart block or COVID-19, and 1 article was excluded since it was a systematic review. 3 articles were added after a manual search. Finally, 30 eligible articles were selected for our systematic review.



From: Moher D, Liberati A, Tetzlaff J, Altman DG, The PRISMA Group (2009). Preferred Reporting Items for Systematic Reviews and Meta-Analyses: The PRISMA Statement. PLoS Med 6(6): e1000097. doi:10.1371/journal.pmed1000097

For more information, visit www.prisma-statement.org.

Fig 1: Prisma Flow Chart

Extraction of Data

Data from included studies were extracted by reviewers and verified by using a standard form. Data regarding patient demographics; comorbidities; medications; baseline ECG abnormalities; laboratory findings; onset, duration, characteristics, and resolution of heart block; as well as details of pacemaker implant were collected in an excel sheet. The data was verified twice to check for any inaccuracies or discrepancies.

RESULTS

We identified and included in this study 30 relevant articles describing 49 patients. Our selected studies include 7 case series and 23 case reports. Most patients described were from the USA, followed by India and Iran. Tables 1, 2, and, 3 detail the data extracted from our selected studies.

Overall the age of the patients varied from 16 months to 82 years (Mode=64) and were predominantly males (61.2%; n=30). In 69.3% (n=34) of the cases, patients suffered from at least one comorbidity: 64.7% (n=22) of them had arterial hypertension (men being affected twice as much as women), 52.9% (n=18) had Diabetes mellitus, 17.6% (n=6) had hyperlipidemia, 11.7% (n=4) reported a previous myocardial infarction, and 8.8% (n=3) had a previous stroke. The duration of active COVID-19 infection varied from 3 to 90 days, with most cases lasting around 14 days. 97.9% (n=48) of all patients were hospitalized but only around 1/3 of them were admitted into ICU (30.6%). 32.65% (n=16) of the hospitalized patients required concurrent mechanical intubation/ventilation.

Regarding laboratory findings, 20.4% (n=10) of the total number of patients diagnosed with heart block had reduced left ventricular ejection fraction (LVEF) in the echocardiogram. Among these, LVEF was mildly reduced (LVEF=54-40%) in 50% (n=5) and severely reduced (LVEF<35%) in 10% (n=1). CRP was elevated in 55.4% (n=27) of the patients, and 37% (n=10) of them tested positive for HsCRP. WBC count was raised in 20.4% (n=10) of the patients. Myocardial involvement was measured in terms of increased Troponin I, which was raised in 22.4% (n=11) of the cases.

Our review found that 89.8% (n=44) of the patients described in the included studies developed heart block during hospitalization for COVID-19 infection, while 10.20% (n=5) of the patients developed heart block following recovery. The type of heart block varied throughout the studies we reviewed, but the most common was third-degree heart block present in 61.22% (n=30) of the patients. Junctional escape rhythm was seen in 30.61% (n=15), and Ventricular escape rhythm was seen in 26.53% (n=13) of the patients. The heart block was symptomatic in 53.06% (n=26), the most common symptom being dyspnea. 36.73% (n=18) of the patients showed spontaneous resolution of the heart block. On the other hand, 63.26% (n=31) of the patients had persistent heart block, out of which 16.33% (n=8) and 42.86% (n=21) were implanted with a temporary and permanent pacemaker, respectively. 24.49% (n=12) of the patients in the studies we reviewed were suspected of having myocarditis. However, none were confirmed with MRI or cardiac biopsy. The reported mortality rate in our study was 22.45% (n=11) during hospitalization. We noted that 45.45% (n=5) of the patients who died had complete heart block¹¹⁻

¹⁷. The other types of heart block reported in the other patients who died include Mobitz type 1 heart block with RBBB¹¹, sinus pauses and sinus arrest, sinus tachycardia with an incomplete right bundle branch block (RBBB)¹⁸, trifascicular block¹⁷, RBBB and left anterior fascicular block (LAFB), RBBB, left posterior fascicular block (LPFB) and incomplete trifascicular block¹³.

TABLE 1: Characteristics of included studies

<u>ID</u>	<u>Authors/Country/Study Design</u>	<u>Patient number</u>	<u>Age</u>	<u>Sex</u>	<u>Co-morbidities</u>
1	Babapoor-Farrokhran et al./USA/Case Series ¹⁹	1	69	Female	NA
2	Sardana et al./USA/Case Report ²⁰	1	49	Female	Healthy
3	Al-Assaf et al./UAE/Case Report ^{21(p)}	1	58	Male	Hypertension
4	Gupta et al./India/Case Series ²²	1	55	Female	Diabetes mellitus
		2	56	Female	NA
		3	67	Male	Diabetes mellitus, Hypertension
		4	80	Male	Hypertension, Prior Myocardial Infarction
		5	45	Female	NA
		6	55	Male	Prior Myocardial Infarction
		7	69	Male	Prior Heart Failure
5	Chinitz et al./USA/Case Series ¹⁶	Total 7	64 ± 9.6	males (n=3), females(n=4)	Hypertension, Diabetes mellitus, Obesity, Hypercholesterolemia, Hepatic disease/Cirrhosis, Cerebrovascular Disease / Stroke prior to admission, Chronic Kidney Disease

6	Kochav et al./USA/Case Series ¹¹	1	76	Male	Diabetes mellitus, Hypertension
		2	70	Male	Hypertension, Hyperlipidemia, Diabetes mellitus, Ischemic cardiomyopathy
7	Haddadin et al./USA/Case Report ²³	1	71	Female	Parkinson's disease, tardive dyskinesia, Diabetes mellitus, bipolar disorder
8	Malekrah et al./Iran/Case Report ²⁴	1	71	Male	NA
9	Ashok & Loke/UK/Case Report ²⁵	1	53	Male	NA
10	Asli et al./Brunei/Case Report ²⁶	1	60	Female	Hypertension, hyperlipidemia, obesity
11	He et al./China/Case Series ²⁷	1	66	Female	NA
		2	70	Male	Hypertension, Diabetes mellitus
12	Dehghani Firouzabadi et al./Iran/Case Report ²⁸	1	38	Female	NA
13	El-Assaad et al./USA/Case Report ^{29(p)}	1	10	Male	Pityriasis lichenoides chronica
14	Eneizat Mahdawi et al./USA/Case Series ¹²	1	82	Male	Hypertension, Stroke
		2	55	Male	NA
		3	43	Male	NA
15	Kir et al./ USA/Case Report ³⁰	1	49	Male	Mild intermittent asthma
16	Dagher et al./USA/Case Series ³¹	1	42	Female	Diabetes mellitus, Obesity
		2	62	Male	Hypertension, Diabetes mellitus, coronary artery disease, obesity
		3	61	Female	Hypertension, obesity
		4	64	Male	Hypertension, obesity
17	Domico et al./USA/Case Report ³²	1	11	Male	NA

18	Bahaidarah et al./Saudi Arabia/Case Report ¹⁷	1	1.3	Male	Malnutrition, Persistent pulmonary hypertension, Large mid-muscular VSD with percutaneous closure
19	Gubitosa et al./USA/Case Report ¹³	1	74	Female	Diabetes mellitus
20	Aa et al./SA/Case Report ³³	1	35	Male	NA
21	Hosseini et al./Iran/Case Report ³⁴	1	48	Male	NA
22	Jean-Louis et al./USA/Case Report ³⁵	1	60	Male	Hypertension, nonischemic dilated cardiomyopathy, COPD, hyperlipidemia and marijuana/cocaine abuse
23	Nikoo et al./Iran/Case Report ¹⁴	1	38	Female	Previous history of mild covid infection 2 months ago
24	Azarkish et al./Iran/Case Report ¹⁵	1	54	Male	NA
25	Pecora et al./Italy/Case Report ³⁶	1	54	Female	NA
26	Maknoja et al./USA/Case Report ¹⁸	1	57	Male	Hypertension
27	Jallad et al./USA/Case Report ³⁷	1	71	Male	Hypertension, Diabetes mellitus, RBBB
28	Ali et al./USA/2021 ³⁸	1	70	Male	NA
29	Ignatiuk et al./Italy/Case Report ³⁹	1	78	Male	Hypertension, Diabetes mellitus, dyslipidemia, moderate aortic stenosis
30	Khalil et al./USA/Case Report ⁴⁰	1	53	Female	End-stage-renal disease on peritoneal dialysis, Anemia of chronic disease, Hypertension, Diabetes mellitus

TABLE 2: Outcome of the included patients

ID	Baseline ECG abnormality	Echo findings	ICU admitted	Death
1	Sinus arrhythmia, non-specific T-wave abnormality, and prolonged QTc of 474 ms.	Normal, LVEF>65%	No	No
2	NA	Normal, LVEF>65%	NA	No
3	Initial ECG showed sinus bradycardia with no ST-T wave changes and a repeat ECG 1 hour later showed 2:1 second degree AV block	Mildly dilated ascending aorta	No	No
4	NA	LVEF=60%	No	No
	NA	LVEF=60%	No	No
	NA	LVEF=60%	No	No
	NA	LVEF=50%	No	No
	NA	LVEF=60%	No	No
	NA	LVEF=60%	No	No
	NA	LVEF=40%	No	No
5	RBBB (n=2), LAHB + RBBB (n=1), 1st degree AV block (n=1).	Normal left ventricular systolic function in all patients ;Severe pulmonary HTN and/or right ventricular dysfunction was identified in 29%	1 patient admitted	Yes,n=4
6	NA	Normal EF	Yes	Yes
	NA	LVEF decreased 10% to 15% with global hypokinesis	Yes	Yes
7	Complete heart block with junctional escape rhythm	LVEF70%,normal biventricular wall motion, thickened mitral valve leaflets, and dilated left atrium.	NA	No
8	Second degree AV block with intermittent left bundle branch block eventually changing into Mobitz II type with fixed	Normal EF	No	No

	LBBB			
9	Normal sinus rhythm and no features of atrioventricular (AV) dissociation	Mild left ventricular (LV) systolic impairment	No	No
10	NA	Normal LVEF	Yes	No
11	NA	Enlarged right atrium and right ventricle accompanied by severe tricuspid regurgitation	Yes	No
	NA	Diffuse hypokinesis, especially in the anterior and inferior walls.	Yes	Yes
12	NA	Normal	NA	No
13	Sinus tachycardia at 140 bpm	LVEF 32%	No	No
14	Normal sinus rhythm at a rate of 82 beats per minute	Normal	Yes	Yes
	NA	Day 2 - right heart strain and McConnell's sign concerning for pulmonary embolism; Day 3 - improved right ventricular function	Yes	No
	Normal sinus rhythm at 74 bpm	Normal	Yes	No
15	NA	Normal LVEF	No	No
16	NA	Normal	No	No
	NA	Normal	No	No
	NA	Normal	No	No
	NA	Normal	No	No
17	NA	LVEF 74%, severe diffuse coronary artery ectasia	Yes	No
18	Sinus rhythm with trifascicular block and precordial T-wave inversion	LVEF 40%	Yes	Yes
19	NA	NA	No	Yes
20	NA	Normal	No	No
21	NA	Normal, LVEF - 55%	No	No
22	High grade AV block with RBBB	LVEF 55%, dilated cardiomyopathy	NA	No

23	NA	LVEF 20-25%, Biventricular dilatation, Global hypokinesia	No	No
24	NA	LVEF>50%	Yes	Yes
25	NA	LVEF 59%, moderate regurgitation of mitral valve	No	No
26	NA	normal-size left ventricle with a low LVEF - 50%	No	No
27	NSR, RBBB, Type 2 AV block and Prolonged QT interval	EF 45% and global hypokinesia with minor regional wall motion abnormalities	Yes	No
28	NA	Normal	No	No
29	NA	Nondilated hypertrophic left ventricle with normal ejection fraction	Yes	No
30	Prolonged QT interval and complete AV heart block.	Normal LVEF, mild left atrial dilation, mild to moderate AP and MT valvular regurgitation, pericardial effusion, and a dilated ICV	Yes	No

TABLE 3: Different types of heart block in the studied patients

ID	Heart block during COVID-19 illness or after recovery?	Self-resolving or persistent	Type of heart block	Escape rhythm	Was the heart block symptomatic	Pacemaker required?
1	during illness	self-resolving	Mobitz type 1	junctional	No	No
2	after recovery	persistent	Intrahisian block	NA	Yes	permanent
3	during illness	persistent	Mobitz type 1	NA	No	permanent
4	during illness	persistent	Third degree	ventricular	Yes	permanent
	during illness	persistent	Third degree	ventricular	Yes	permanent
	during illness	persistent	Third degree	ventricular	Yes	permanent
	during illness	persistent	Third degree	ventricular	Yes	permanent
	during illness	self-resolving	Sick Sinus syndrome	junctional	Yes	No
	during illness	persistent	Third degree	junctional	Yes	permanent
	during illness	self-resolving	Sick Sinus syndrome	junctional	Yes	No
5	during illness	persistent	2:1 AV block with preexisting RBBB(patient 1) ,Sinus bradycardia and intermittent CHB with junctional escape rhythm(patient 2),CHB with wide complex escape rhythm with preexisting LAHB + RBBB(patient 3), CHB with narrow complex escape rhythm with preexisting First degree AVB(patient	junctional	symptomatic in 3 patients	temporary (n=2) and permanent pacemakers (n=5)

			4), Sinus pauses(patients 5,6,7) , RBBB in 7			
6	during illness	persistent	Mobitz type 1 and RBBB	junctional	Yes	No
	during illness	persistent	Day 0 - LBBB, Day 5 - complete heart block (4) with no escape rhythm	NA	Yes	No
7	during illness	persistent	Third degree	junctional	No	permanent
8	during illness	persistent	Day 3 - 2:1 AV block with intermittent LBBB; Day 4 - 2:1 AV block with fixed LBBB; Day 6 - Atrial fibrillation with bradycardia 1 month follow-up - Persistence of AV block	NA	No	permanent
9	during illness	persistent	Mobitz type 2 initially followed by Third degree on the next day	junctional	Yes	permanent
10	during illness	self-resolving	RBBB	NA	No	No
11	during illness	persistent	Day 0 - 1st degree, Day of intubation - Mobitz type 1, Next day - Third degree [nearly complete AVB (or high-grade AVB) developed], Soon after - revert to 1st degree (SITIIIQIII disappeared)	Junctional	NA	No
	during illness	persistent	First ECG - sinus tachycardia with an incomplete RBBB.	NA	No	No
12	after recovery	self-resolving	Temporary complete heart block (4)	NA	Yes	No
13	during illness	self-resolving	1st degree, Mobitz type 1, Mobitz type 2, Third degree (transient lasting for few minutes)	junctional	No	No
14	during illness	persistent	Day 0 - Complete Heart Block Day 6 [post discontinuation of drugs] - Heart block with narrow escape rhythm with intermittent Wenckebach pattern and escape-capture Wenckebach consistent with AV nodal disease	ventricular	Yes	No
	during illness	self-resolving	Days 6-9 admission - Second degree AV block with 2:1 conduction	NA	No	No

	during illness	self-resolving	Third degree	NA	No	No
15	during illness	self-resolving	Third degree	ventricular	Yes	temporary
16	during illness	self-resolving	Third degree	junctional	No	No
	during illness	self-resolving	Third degree	ventricular	Yes	temporary
	during illness	self-resolving	Third degree	ventricular	No	No
	during illness	self-resolving	Third degree	junctional	No	No
17	after recovery	self-resolving	Early ECGs demonstrated normal sinus rhythm. On day 4, he developed sinus bradycardia with varying degrees of first and second-degree heart block, intraventricular conduction abnormalities with varying QRS morphologies, and periods of idioventricular rhythm. He had a brief run of nonsustained ventricular tachycardia. He then developed second degree type II heart block with variable nonspecific intraventricular conduction delay. The following day, his conduction system abnormalities improved, progressing to second degree type I block. Approximately 48 hours later, he was had first-degree atrioventricular block. This was followed by complete resolution of conduction abnormalities, and a return to normal sinus rhythm.	junctional and ventricular	No	temporary
18	during illness	persistent	Trifascicular block	NA	No	temporary
19	during illness	persistent	RBBB and LAFB, RBBB and LPFB, 3 (incomplete trifascicular block)	NA	No	No
20	during illness	persistent	Mobitz type 2 followed by Third degree	ventricular	No	temporary, followed by permanent on

						day 18
21	during illness	persistent	Third degree	junctional	Yes	permanent
22	during illness	self-resolving	In October 2019, patient demonstrated normal sinus rhythm (NSR) with a left bundle branch block. Upon admission to hospital in 2020, he had a high-degree AV block with a right bundle branch block (RBBB) escape morphology. On day 2 of hospitalization, his ECG had converted to NSR with LBBB, which was consistent with his ECG prior to this admission. He remained without any recurrence of AV block.	ventricular	Yes	No
23	after recovery	self-resolving	4; After dexa the patient recovered to 1 with LBBB; in 4 days it also resolved.	NA	Yes	temporary
24	during illness	self-resolving	Third degree	NA	No	No
25	during illness	persistent	Left posterior hemiblock and high -grade AV block	NA	Yes	temporary
26	during illness	persistent	Third degree	ventricular	Yes	permanent
27	during illness	persistent	Mobitz type 1	NA	Yes	permanent
28	during illness	self-resolving	Third degree	NA	Yes	permanent
29	during illness	persistent	second degree 2:1 AV block; transient 4	NA	No	permanent
30	after recovery	persistent	Third degree	NA	Yes	permanent

Changes in the type of heart block during the clinical course:

We have found that 61.22% of the patients in our case studies developed a third-degree heart block. Some other ECG findings reported after COVID-19 infection include first-degree heart block (n=4); Mobitz type 1 (n=7); Mobitz type 2 (n=10); atrial fibrillation (AF) with bradycardia (n=1); Intrahisian block (n=1) and Trifascicular block (n=1). Six patients experienced RBBB and four patients experienced LBBB. Sick sinus syndrome was also detected in 2 patients²². Many patients had changes in the type of heart block during the course of illness. Alabdulgader et al. described a patient who had persistent heart block and received a temporary pacemaker; this was later replaced with a permanent pacemaker on day 18 of hospitalization³³. Pecora et al described a patient with left posterior hemiblock and high-grade AV block, which resolved with implantation of a temporary pacemaker³⁶. 2 patients developed Mobitz type 2 heart block, which was followed by 3rd-degree complete heart block^{13,41}. Azakirsh et al illustrated a patient who developed Mobitz type 2 AV block (2:1) with intermittent LBBB on the 3rd day of hospitalization; this evolved on the fourth day to Mobitz type 2 AV block (2:1) with fixed LBBB, and on the sixth day to AF with bradycardia. The persistence of AV block was observed one month after discharge¹⁵. Domico et al reported a child with a high-grade heart block, which resolved with temporary pacing. Upon admission, the patient's ECGs exhibited normal sinus rhythm. On the fourth day, the patient developed sinus bradycardia along with varying degrees of first and second-degree heart block, episodes of idioventricular rhythm, and intraventricular conduction abnormalities associated with fluctuating morphologies in QRS complexes. Consequently, the patient experienced a transient nonsustained ventricular tachycardia (VT) followed by a second-degree type II heart block with inconsistent nonspecific intraventricular conduction delay. On day 5, the irregularities of the conduction system improved and settled into a second-degree type I block. On day 7, he demonstrated a first-degree AV block which was followed by complete resolution of conduction abnormalities and return to sinus rhythm³².

One patient showed inferior and precordial leads ST-segment elevation on day 35 of hospitalization. In addition, there was a progressive increase in ST-elevation amplitude which transformed into a triangular QRS-ST-T waveform. Two attacks of multifocal ventricular tachycardia were observed during the development of ST-segment elevation²⁷.

Additional ECG findings reported in the included studies are sinus bradycardia¹⁹, sinus tachycardia²⁶, sinus pauses in 3 patients¹⁶, and QT prolongation^{24,32,37,40}.

DISCUSSION

Every day brings about a new discovery about the pathogenesis and clinical manifestations of COVID-19. According to the fast-growing availability of scientific literature on this topic, the heart appears to be one of the elective targets of the virus. It is known that SARS-CoV enters into human cells via Angiotensin-Converting Enzyme 2 (ACE-2) receptors which are found in alveolar epithelial cells and endothelium of arteries and veins. Multiple hypotheses have been made to explain the mechanism of heart blocks in COVID-19 infection. In autopsy studies, SARS-CoV-2 virus and inflammatory infiltrate have been found in the myocardium, which implies direct viral invasion of the heart. ACE-2 downregulation decreases the action of angiotensin 1–7 leading to increased synthesis of inflammatory mediators like TNF α , CRP, and TGF β which produces a cytokine storm. TGF β induces interstitial fibrosis, which damages

cardiac architecture. Troponin elevation and contractility dysfunction occur in the setting of severe hypoxia due to inflammatory damage or hypercoagulability. These phenomena initiated by the virus can occur in parallel with direct viral damage and interact with each other, enhancing their effect^{8,42}.

In our study, only 24.49% of the patients were suspected of myocarditis. However, none were confirmed with MRI or cardiac biopsy. Kir et al. reported one patient with no evidence of myocardial involvement indicated by normal levels of cardiac enzymes and no findings on ECG, who developed a self-resolving 3rd-degree heart block. It is postulated that COVID-19 triggered subclinical myocarditis may have given rise to high-degree AV block in this patient³⁰. The mechanism of heart block in other cases is poorly understood. In our review, all the patients who died after developing heart block were on mechanical ventilation in the intensive care unit.

Deterioration of any pre-existing diseases in the conduction system such as AV node disease, bundle branch blocks, or His-Purkinje system disorder can cause new advanced blocks, leading to poor clinical outcomes³⁴. Another big role in COVID-19 progression is played by comorbidities and risk factors. Cardiovascular diseases, hypertension, diabetes mellitus, renal disease, liver disease, cerebrovascular disease, obesity, hyperlipidemia, and smoking history have a crucial impact on disease progression and complications⁸. In our review, hypertension and diabetes mellitus were present in the majority of patients who passed away due to heart block during COVID-19 infection. Since many of these risk factors are modifiable, lifestyle changes, early diagnosis, and management of comorbidities must be considered for better outcomes in COVID-19 patients.

Pathophysiological, histological, and imaging data^{8,43} indicate that SARS-CoV-2 could induce tissue damage, which would predispose patients to recurrent cardiac issues long-term after discharge. However, the long-term impact of COVID-19 induced heart blocks on late cardiac manifestations are not well studied, thus leading to poor clinical guidance regarding remote cardiac follow-up after discharge.

Limitations

One of the limitations of our systematic review was the restricted number of studies and size of the sample population. We have only included studies published until May 2021. Future reports of heart block in COVID-19 patients might reveal new relations between the severity of the infection and the prognosis of patients who develop heart block.

The resolution of ECGs changes after discontinuation of HCQ in a case suggests a causal relationship between hydroxychloroquine and ECG abnormalities. Thus the role of certain medications, like hydroxychloroquine, on the development of arrhythmias in the presence of COVID-19 infection must also be further investigated²⁶.

Also, the presence of COVID-19 induced myocarditis was not confirmed via biopsy or MRI in any of the patients who developed heart block in our included studies.

Conclusion

The exact pathogenesis of heart block in COVID-19 patients must be further explored. More research is required to determine whether myocarditis due to COVID-19 is associated with the development of heart blocks. It is also needed to be studied further whether heart block is an independent risk factor for a worse prognosis in COVID-19 cases.

Patients hospitalized for COVID-19 must be continuously monitored for arrhythmias including heart blocks, especially in the presence of comorbidities. Physicians must be made aware of these cardiac manifestations of the infection, as early detection can shorten the hospital stay and improve the prognosis of the patient.

Contributions:

MRA contributed to research idea, design of the study, collecting data, statistical analysis and interpretation, writing the first draft, writing and editing the final manuscript. MSh contributed to study design, data extraction, statistical analysis and interpretation, writing the first draft. MS, CS, VR and NS contributed to data extraction, statistical analysis & interpretation and writing the first manuscript.

Corresponding Author: Correspondence to Md Ripon Ahammed

Conflict of Interest: None

Acknowledgment: To Larkin Community Hospital, FL, USA for supporting and providing our research platform.

Funding: None

Ethical Approval: Not applicable

References:

1. Wang D, Hu B, Hu C, et al. Clinical Characteristics of 138 Hospitalized Patients With 2019 Novel Coronavirus-Infected Pneumonia in Wuhan, China. *JAMA*. 2020;323(11):1061-1069. doi:10.1001/jama.2020.1585
2. Gupta A, Madhavan MV, Sehgal K, et al. Extrapulmonary manifestations of COVID-19. *Nat Med*. 2020;26(7):1017-1032. doi:10.1038/s41591-020-0968-3

3. Sabatino J, Rosa SD, Salvo GD, Indolfi C. Impact of cardiovascular risk profile on COVID-19 outcome. A meta-analysis. *PLOS ONE*. 2020;15(8):e0237131. doi:10.1371/journal.pone.0237131
4. Creel-Bulos C, Hockstein M, Amin N, Melhem S, Truong A, Sharifpour M. Acute Cor Pulmonale in Critically Ill Patients with Covid-19. *N Engl J Med*. 2020;382(21):e70. doi:10.1056/NEJMc2010459
5. Inciardi RM, Lupi L, Zaccone G, et al. Cardiac Involvement in a Patient With Coronavirus Disease 2019 (COVID-19). *JAMA Cardiol*. 2020;5(7):819-824. doi:10.1001/jamacardio.2020.1096
6. Singh S, Desai R, Gandhi Z, et al. Takotsubo Syndrome in Patients with COVID-19: a Systematic Review of Published Cases. *SN Compr Clin Med*. Published online October 6, 2020:1-7. doi:10.1007/s42399-020-00557-w
7. Hua A, O’Gallagher K, Sado D, Byrne J. Life-threatening cardiac tamponade complicating myo-pericarditis in COVID-19. *Eur Heart J*. 2020;41(22):2130. doi:10.1093/eurheartj/ehaa253
8. Babapoor-Farrokhran S, Gill D, Walker J, Rasekhi RT, Bozorgnia B, Amanullah A. Myocardial injury and COVID-19: Possible mechanisms. *Life Sciences*. 2020;253:117723. doi:10.1016/j.lfs.2020.117723
9. Malaty M, Kayes T, Amarasekera AT, Kodsí M, MacIntyre CR, Tan TC. Incidence and treatment of arrhythmias secondary to coronavirus infection in humans: A systematic review. *Eur J Clin Invest*. 2021;51(2):e13428. doi:10.1111/eci.13428
10. Garcia-Zamora S, Lee S, Haseeb S, et al. Arrhythmias and electrocardiographic findings in Coronavirus disease 2019: A systematic review and meta-analysis. *Pacing and Clinical Electrophysiology*. 2021;44(6):1062-1074. doi:10.1111/pace.14247
11. Kochav SM, Coromilas E, Nalbandian A, et al. Cardiac Arrhythmias in COVID-19 Infection. *Circ Arrhythm Electrophysiol*. 2020;13(6):e008719. doi:10.1161/CIRCEP.120.008719
12. Eneizat Mahdawi T, Wang H, Haddadin FI, Al-Qaysi D, Wylie JV. Heart block in patients with coronavirus disease 2019: A case series of 3 patients infected with SARS-CoV-2. *HeartRhythm Case Rep*. 2020;6(9):652-656. doi:10.1016/j.hrcr.2020.06.014
13. Gubitosa JC, Xu P, Ahmed A, Pergament K. Incomplete Trifascicular Block and Mobitz Type II Atrioventricular Block in COVID-19. *Cureus*. 2020;12(9):e10461. doi:10.7759/cureus.10461
14. Nikoo MH, Mozaffari R, Hatamnejad MR, Bazrafshan M, Kasaei M, Bazrafshan H. Systolic dysfunction and complete heart block as complications of fulminant myocarditis in a recovered COVID-19 patient. *J Cardiol Cases*. Published online April 20, 2021. doi:10.1016/j.jccase.2021.03.009

15. Azarkish M, Laleh Far V, Eslami M, Mollazadeh R. Transient complete heart block in a patient with critical COVID-19. *Eur Heart J*. 2020;41(22):2131. doi:10.1093/eurheartj/ehaa307
16. Chinitz JS, Goyal R, Harding M, et al. Bradyarrhythmias in patients with COVID-19: Marker of poor prognosis? *Pacing Clin Electrophysiol*. 2020;43(10):1199-1204. doi:10.1111/pace.14042
17. Bahaidarah SA, Dohain AM, Abdelmohsen G, Alnajjar AA, Al-Ata J. Impact of coronavirus disease 2019 in a child who underwent ventricular septal defect device closure: a case report. *European Heart Journal - Case Reports*. 2021;5(1). doi:10.1093/ehjcr/ytaa478
18. Complete Heart Block: A Rare Presentation of COVID-19. HMP Global Learning Network. Published May 3, 2021. Accessed September 21, 2021. <https://www.hmpgloballearningnetwork.com/site/cathlab/content/complete-heart-block-rare-presentation-covid-19>
19. Babapoor-Farrokhran S, Batnyam U, Wiener PC, et al. Atrioventricular and Sinus Node Dysfunction in Stable COVID-19 Patients. *SN Compr Clin Med*. Published online September 4, 2020:1-4. doi:10.1007/s42399-020-00497-5
20. Sardana M, Scheinman MM, Moss JD. Atrioventricular block after COVID-19: What is the mechanism, site of block, and treatment? *Heart Rhythm*. 2021;18(3):489-490. doi:10.1016/j.hrthm.2020.10.020
21. Al-Assaf O, Mirza M, Musa A. Atypical presentation of COVID-19 as subclinical myocarditis with persistent high-degree atrioventricular block treated with pacemaker implant. *HeartRhythm Case Rep*. 2020;6(11):884-887. doi:10.1016/j.hrcr.2020.09.003
22. Gupta MD, Qamar A, Mp G, et al. Bradyarrhythmias in patients with COVID-19: A case series. *Indian Pacing Electrophysiol J*. 2020;20(5):211-212. doi:10.1016/j.ipej.2020.08.004
23. Haddadin FI, Mahdawi TE, Hattar L, Beydoun H, Fram F, Homoud M. A case of complete heart block in a COVID-19 infected patient. *J Cardiol Cases*. 2020;23(1):27-30. doi:10.1016/j.jccase.2020.08.006
24. Malekrah A, Fatahian A. A case report of a rare cardiac complication in novel coronavirus disease. *Eur Heart J Case Rep*. 2020;4(6):1-4. doi:10.1093/ehjcr/ytaa323
25. Ashok V, Loke WI. Case report: high-grade atrioventricular block in suspected COVID-19 myocarditis. *Eur Heart J Case Rep*. 2020;4(F11):1-6. doi:10.1093/ehjcr/ytaa248
26. Asli R, Abdullah MS, Chong PL, et al. Case Report: Right Bundle Branch Block and QTc Prolongation in a Patient with COVID-19 Treated with Hydroxychloroquine. *Am J Trop Med Hyg*. 2020;103(1):79-82. doi:10.4269/ajtmh.20-0376

27. He J, Wu B, Chen Y, et al. Characteristic Electrocardiographic Manifestations in Patients With COVID-19. *Can J Cardiol*. 2020;36(6):966.e1-966.e4. doi:10.1016/j.cjca.2020.03.028
28. Dehghani Firouzabadi M, Goudarzi S, Dehghani Firouzabadi F, Moosaie F. Complete heart block and itchy rash in a patient with COVID-19. *Caspian J Intern Med*. 2020;11(Suppl 1):569-571. doi:10.22088/cjim.11.0.569
29. El-Assaad I, Hood-Pishchany MI, Kheir J, et al. Complete Heart Block, Severe Ventricular Dysfunction, and Myocardial Inflammation in a Child With COVID-19 Infection. *JACC Case Rep*. 2020;2(9):1351-1355. doi:10.1016/j.jaccas.2020.05.023
30. Kir D, Mohan C, Sancassani R. Heart Brake: An Unusual Cardiac Manifestation of COVID-19. *JACC Case Rep*. 2020;2(9):1252-1255. doi:10.1016/j.jaccas.2020.04.026
31. Dagher L, Wanna B, Mikdadi G, Young M, Sohns C, Marrouche NF. High-degree atrioventricular block in COVID-19 hospitalized patients. *Europace*. 2021;23(3):451-455. doi:10.1093/europace/euaa333
32. Domico M, McCanta AC, Hunt JL, Ashouri N, Nugent D, Kelly RB. High-grade heart block requiring transvenous pacing associated with multisystem inflammatory syndrome in children during the COVID-19 pandemic. *HeartRhythm Case Rep*. 2020;6(11):811-814. doi:10.1016/j.hrcr.2020.08.015
33. Aa A, A A, M S, H E, K AK. Novel Behavior of the 2019 Novel Coronavirus With Invasion of the Cardiac Conduction System in the Young. *Cureus*. 2020;12(10). doi:10.7759/cureus.11115
34. Hosseini Z, Ghodsi S, Hejazi SF. Persistent Complete Heart Block in a Patient with COVID-19 Infection: a Case Report. *SN Compr Clin Med*. Published online January 6, 2021:1-4. doi:10.1007/s42399-020-00712-3
35. Jean-Louis F, Adedayo AM, Ajibawo T, Upadhya G, Syed A. A Rare Case of Resolution of High-Degree Atrioventricular Block Associated With COVID-19. *J Med Cases*. 2020;11(8):243-245. doi:10.14740/jmc3524
36. Pecora D, La Greca C, Pezzotti E, Botti P, Campana M, Cuccia C. [An unusual presentation of cardiac involvement during the COVID-19 pandemic]. *G Ital Cardiol (Rome)*. Published online 2020:594-597.
37. Jallad A, Doodnauth AV, Lee J, et al. New Onset, Irreversible, Prolonged QT-Interval Requiring Permanent Biventricular Pacemaker in a COVID-19 Patient. *Am J Med Case Rep*. 2021;9(4):249-252. doi:10.12691/ajmcr-9-4-11
38. Ali AA, Maaliki N, Omar M, Roemer A, Ruiz J, Esmail K. Transient Third-degree Heart Block Secondary to Asymptomatic COVID-19 Infection. *American Journal of Medical Case Reports*. 2021;9(4):259-260. doi:10.12691/ajmcr-9-4-13

39. Ignatiuk B, Baratto F, Monticelli J, Bacchion F, Marchese GM, Pasquetto G. Pacemaker implantation in a COVID-19 patient. Balancing the patient's needs and the team's risk of exposure. *J Arrhythm*. 2020;37(1):261-263. doi:10.1002/joa3.12480
40. Khalil S, Collins A, Mubarak N, Khalil T. Third degree heart block and elevated troponin following acute respiratory hypoxic failure in a COVID-19 recovered patient in the absence of coronary artery disease. *J Cardio Case Rep*. 2020;4(2). doi:10.15761/JCCR.1000159
41. John T-J, Kyriakakis C, Zachariah D, Doubell A. Inferior ST-elevation myocardial infarction managed with a pharmacoinvasive strategy and conservative management of delayed atrioventricular block: classical case report. *Eur Heart J Case Rep*. 2020;4(6):1-7. doi:10.1093/ehjcr/ytaa375
42. Liu PP, Blet A, Smyth D, Li H. The Science Underlying COVID-19: Implications for the Cardiovascular System. *Circulation*. 2020;142(1):68-78. doi:10.1161/CIRCULATIONAHA.120.047549
43. Rajpal S, Tong MS, Borchers J, et al. Cardiovascular Magnetic Resonance Findings in Competitive Athletes Recovering From COVID-19 Infection. *JAMA Cardiol*. 2021;6(1):116-118. doi:10.1001/jamacardio.2020.4916