

A Nonrandomized Phase 2 Trial of EG-Mirotin, a Novel, First-in-class, Subcutaneously Delivered Peptide Drug for Non-Proliferative Diabetic Retinopathy

Seunghoon Yoo^{1*}, Dae Hyuk You^{2*}, Jeongyoon Lee³, H. Christian Hong⁴, Sung Jin Lee^{5‡}

¹Nune Eye Hospital, Seoul, Korea

²College of Letters & Science, University of Wisconsin-Madison, Madison, WI 53715

³Brain and Cognitive Sciences Research Center, Daegu Gyeongbuk Institute of Science and Technology (DGIST), Daegu, South Korea

⁴Department of Medicine and Medical Microbiology, School of Medicine, New Tokyo Medical College, Pohnpei, FM 96941

⁵Department of Ophthalmology, Soonchunhyang University College of Medicine, Soonchunhyang University Hospital, Seoul, South Korea.

* Both authors contributed equally

‡Corresponding author

Correspondence:

Dr. Prof. Sung Jin Lee

Department of Ophthalmology

Soonchunhyang University College of Medicine

Soonchunhyang University Hospital

59 Daesagwan-ro, Seoul 04401, South Korea.

Tel: +82-2-709-9114

NOTE: This preprint reports new research that has not been certified by peer review and should not be used to guide clinical practice.
e-mail: wismile@schmc.ac.kr or secondary mirotinclinicaltrials@gmail.com

ABSTRACT

Background EG-Mirotin, which includes an active ingredient; EGT022, targeting Non-Proliferative Diabetic Retinopathy (NPDR), the early stage of retinopathy. EG-Mirotin is a drug that is used before capillary damage progresses to an irreversible stage. Safety and efficacy of EG-Mirotin were investigated in subjects with Type 1 or 2 diabetes and NPDR with the degree from moderate to severe.

Methods Subjects (n=10, 20 eyes) satisfying the selection criteria through the screening test were administered EG-Mirotin once a day (3 mg in 1.5 ml of sterile saline) for 5 days, 5 times in total, and were evaluated of the Ischemic index changes and safety. End-of-study (EOS) is performed approximately 8 weeks \pm 1 (57 days \pm 7) from the first dose.

Results A total of 4 Treatment Emergent Adverse Events (TEAE) were observed in 2 subjects out of 10 (20.00%) who received the investigational drug. Among them, no subjects were reported experiencing a TEAE related to the investigational drug. All injections were well tolerated (3 mg in 1.5 ml of sterile saline) with no dose-limiting adverse events, deaths, serious adverse events. The overall average percent change in ischemic index at each evaluation point compared to baseline was statistically significant (Greenhouse-Geisser $F=9.456$, $p=0.004$ for the main effect of time), and a larger change was observed when the baseline ischemic index value was high (Greenhouse-Geisser $F=10.946$, $p=0.002$ for the time*group interaction).

Conclusions EG-Mirotin was well tolerated and found to reverse the ischemia and

leakage of capillaries in the retina caused by diabetes.

Key Words: Diabetic Retinopathy, Non-Proliferative Diabetic Retinopathy, Retinal Ischemia

INTRODUCTION

Even in the 21st century, diabetes is rapidly spreading as a global epidemic. Currently, there are 463 million adults (20-79 years) with diabetes worldwide, and it will reach 700 million by 2045 (Saeedi, P *et al.*, 2019). Diabetic retinopathy (DR) is a complication of diabetes and the leading cause of blindness in people between the ages of 20 and 74 years (Fong, DS *et al.*, 2004).

DR occurs when diabetes damages the tiny blood vessels inside the retina in back of the eye and it is further classified as Non Proliferative diabetic retinopathy (NPDR), proliferative diabetes retinopathy (PDR) (Chistiakov, DA, 2011). In addition to PDR, diabetic macular edema (DME) is the cause of severe visual impairment (Wilkinson, CP *et al.*, 2003)

Diabetes damages endothelial cells (Suganya, N *et al.*, 2016), which causes stimulation of cell division and promotion of the movement of cells. The increase of the vascular relaxing factor makes to loosen the microvessels. Microvessels are composed of tubules that form vascular endothelial cells and pericytes that support and surround them (Bergers, G *et al.*, 2005; Zhao H *et al.*, 2019). Pericytes are vascular cells that contribute to stabilization capillary beds and their correct interaction with the extracellular matrix (ECM) is very important for microvascular development (Jang, JW *et al.*, 2016).

If these changes continue to worsen, the loss of pericytes and the thickening of the basement membrane will eventually lead to the loss of microvessels (Non proliferative Diabetic Retinopathy; NPDR) (Kuwabara, T *et al.*, 1963). If these abnormalities in the vessels block the microvessels, then the number of areas where

blood flow is inadequate will increase. Therefore, angiogenesis will occur, which will cause undesired neovascularization adjust to the area of vascular occlusion. And the detachment of the retina will eventually lead to the loss of sight. If DM persists for more than 20 years, it is estimated that more than 86% of patients will experience severe vision loss with type 1 diabetes, and it is estimated that 77% of patients with type 2 diabetes will simultaneously experience loss of vision (Klein, R *et al*, 1984). Furthermore, patients with DR contribute disproportionately to health care and societal costs of the disease.

Prevention of diabetic retinopathy consists primarily of an optimal control of the blood glucose levels (Lee, R *et al.*, 2015), as well as treatment of other risk factors, especially hypertension and hyperlipidemia. Still there is no appropriate possibility of treatment for NPDR (the early stage retinopathy), while there is only limited treatment for proliferative diabetic retinopathy (late stage retinopathy). Once apparent, late diabetic retinopathy can be treated by laser coagulation and intraocular injections of compounds with anti-angiogenetic activities, such as bevacizumab, ranibizumab and pegaptanib (Das, A *et al.* 2015). Current treatment for DR is inject anti-VEGF to inhibit angiogenesis from ischemic retina or vascular leakage by pericyte loss. However, this treatment is unable to restore the condition of retina since capillary is already damaged irreversibly. A new treatment paradigm is needed to minimize patient discomfort. To achieve this paradigm shift, it is necessary to delay the patient's vision loss as much as possible by preventing or restoring capillary damage early in the NPDR stage.

EyeGene Inc. developed a new drug, EG-Mirotin including active ingredient; EGT022, targeting NPDR, the early stage of retinopathy. EG-Mirotin is a drug that is used before capillary damage progresses to an irreversible stage. It is a drug that

offers a completely new treatment method. Most DR patients may have vague anxiety when they hear the medication being injected directly into their eyes. However, in the case of EG-Mirotin, it is a revolutionary product that can alleviate patient anxiety because it can be injected via subcutaneously with a relatively small gauge needle (31-29 Gauge).

EGT022 is a recombinant polypeptide that is being developed to treat diabetic retinopathy. It is derived from human ADAM-15 protein (A Disintegrin And Metalloproteinase domain containing protein 15), contains 58 amino acids and weighs 6.1 kilo Dalton. After subcutaneous injection of EGT022, it binds to integrin on the surface of thrombocytes, and stimulates the thrombocytes to produce growth factors (including Angiopoietin 1, Ang-1). In retinopathy, the capillaries are prone to rupture and subsequently retinal hemorrhages, and prone to fluid leakage, which results in retinal and macular edema (Romero-Aroca, P, 2011). The primary activity of the growth factors released from thrombocytes (especially Ang-1), involved after administration of EGT022, appears to be the recruitment and development of pericytes. The pericytes are specialized connective tissue cells which together with the endothelial cells build up the capillaries (Diaz-Flores, L *et al*, 1991).

EG-Mirotin has successfully completed phase 1 clinical trials to show excellent safety. The aim of EG-Mirotin trial was to evaluate the efficacy and safety of Disintegrin via SC injection in adult patients with diabetic edema in NPDR.

MATERIALS AND METHODS

Study Drug

EG-Mirotin was provided by EyeGene, Inc. (Seoul, Korea). EG-Mirotin was supplied as a freeze-dried powder form in a glass vial. EG-Mirotin contains 3mg of EGT022, dissolved in 1.2mL of Sterile Water for Injection (SWFI) before administration.

EGT022 was cloned using the N-terminal primer 5'-CTCGAGAAAGAACCTGCCAGCTGA-3' and the C-terminal primer 5'-GCGGCCGCTCAGCCATCCCCTAGGC-3' from the human fetal liver cDNA library. We used the previously described *Pichia pastoris* expression system (Jeon, OH *et al.*, 2007)

Trial Design

An Open-label, Single-Arm, Single center, Exploratory Phase II study to evaluate the Efficacy and Safety of EG-Mirotin in patients with Diabetic Retinopathy. The protocol was approved by the Ministry of Food and Drug Administration of Korea (Approval No. 32764) and by Soonchunhyang University Hospital investigational review boards.

Ischemic Index and Leakage Index Evaluation

The value of the Ischemic Index and the Leakage Index was measured by Ultra-Wide Field Fluorescein Angiography (UWFA) (Fig 1). Ischemic Index and Leakage Index were measured using Optos California (Optos PLC, Dunfermline, UK) for ultra-wide angiography and ultra-wide fluorescence angiography. To obtain the Ischemic Index

or Leakage Index, a program called Optos Advance (Optos PLC) was used, and the Total Retinal Area, Ischemic Area, and Leakage Area were measured through this. Based on two images obtained at about 40 seconds (initial) and about 8 minutes (late) after contrast medium injection through ultra-wide-range fluorescein angiography, one objective evaluator drew the retina of the maximum identifiable range with a continuous line and calculated the area obtained. It was defined as the Total Retinal Area, and the areas obtained by drawing the retina of the capillary non-perfusion region identifiable in the image obtained in the early stage were summed to define the ischemic area. It was defined as Leakage Area. All units are in mm². And the Ischemic Index was defined as the value obtained by dividing the Ischemic Area by the Total Retinal Area in the image obtained in the early stage, and the Leakage Index was defined as the value obtained by dividing the Leakage Area obtained in the image obtained in the later stage by the Total Retinal Area. The unit of Ischemic Index and Leakage Index is %. The Ischemic Index was defined as the non-perfused area divided by the total retinal area in percent. The Leakage Index was defined as the capillary leakage area divided by the total retinal area in percent. The total retinal area considered for ischemic index and leakage index could be different for each individual, but the total area values remained unchanged throughout the study. The subjects were received 3 mg of the study drug once daily for 5 days subcutaneously (V2 - V6 respectively) and were monitored for safety and efficacy. All the Ischemic and Leakage Index was measured at the baseline first (V1). The value of the non-perfused area and the capillary leakage area were measured at 2, 4, and 8 weeks after administration (V7, V8, V9, respectively). The average interval between the baseline and the second visit is 23.22(±3.32) days, 12.12(±3.36) days between the second and the third, and 31.89(±5.52) days between the third and the fourth visit.

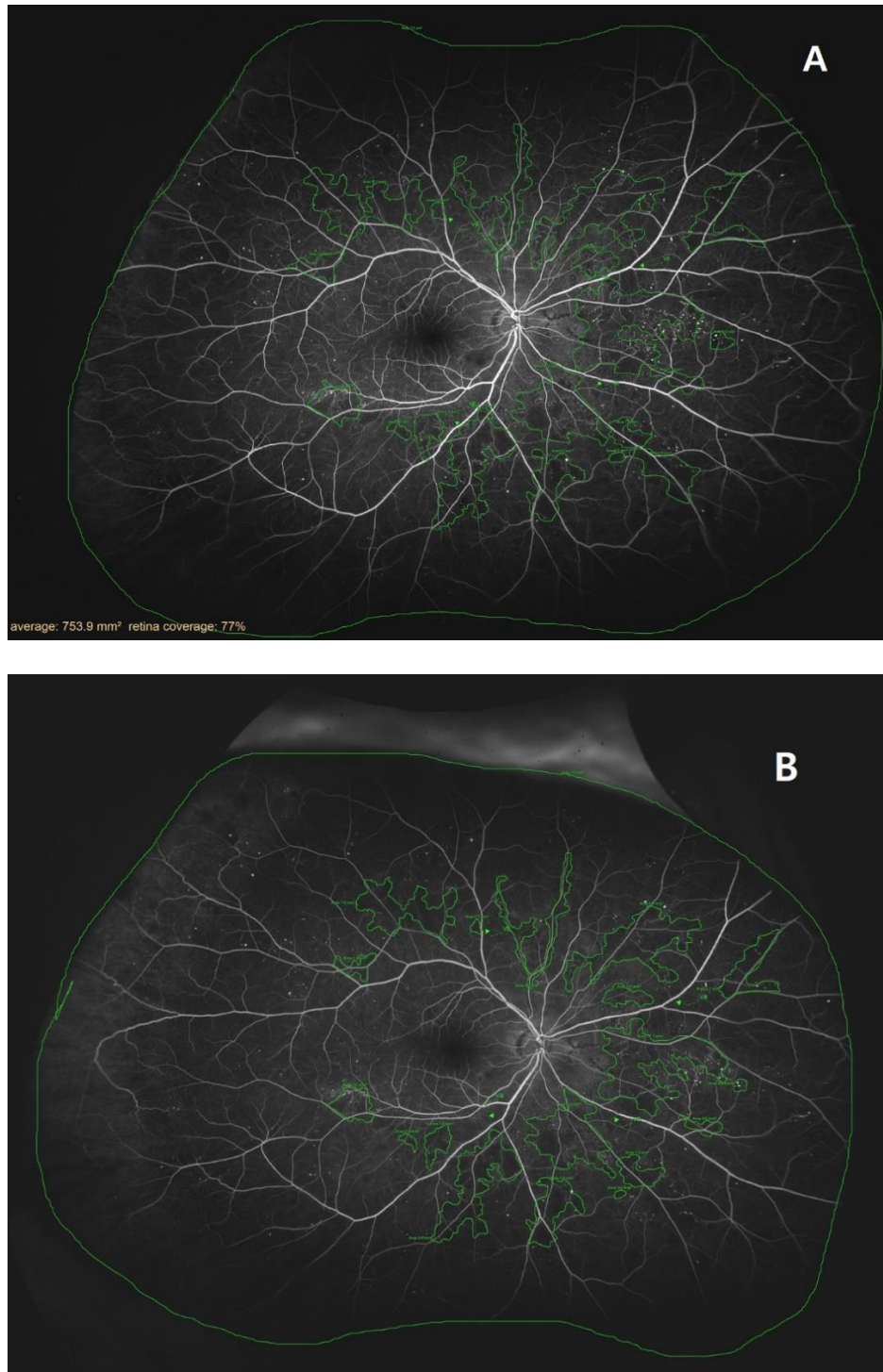


Figure 1. Example of tracing image of retina with Ultra-Wide Field Fluorescein Angiography (A= V1, -2 weeks of treatment; B=V9, 8 weeks \pm 7 days of treatment)

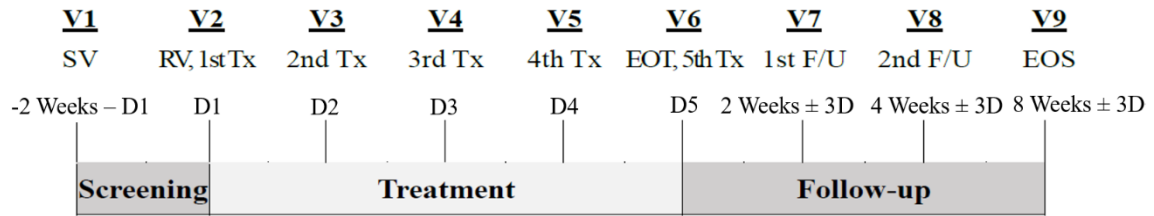


Figure 2. Study design. EOT = End of Treatment. EOS = End of Study

Eligible Subject (Diagnosis and main criteria for inclusion)

10 male or female diabetic retinopathy patients having moderate to severe non-proliferative diabetic retinopathy (NPDR)

Table 1 Patient demographics and main clinical findings

Patients/Eyes	10/20
Age	61.50± 0.17
Sex(Male/Female)	8/2
VA1	0.89±0.17
CMT1	288.90±21.05
RV1	0.23±0.02
Total Ischemic Retina	793.00±20.03
Non-Perfused Retina	29.78±36.33
Ischemic Index	2.12±4.78
Total Leakage Retina	796.00±21.62
Capillary Leakage	108.65±90.26
Leakage Index	13.595±11.21

Inclusion Criteria

(i) A patient who voluntarily decides to participate and gives his/her written consent after knowing the characteristics of this clinical trial and investigational drug, (ii) Adult men and women over 19 years of age, (iii) Patients with type 1 or type 2 diabetes who meet one of the following criteria: Diabetes that meets the American Diabetic Association (ADA) and / or World Health Organization (WHO) criteria; Those who take insulin regularly or receive parenteral treatment for the treatment of diabetes; those who regularly take oral hypoglycemic agents for the treatment of diabetes, (iv)

Moderate to severe non-proliferative diabetic retinopathy (NPDR) (e.g., severity scale ETDRS 43A-53) for the study eye, (v) When the investigator considers that the following treatments can be safely postponed until V9 (8 weeks): photocoagulation and anti-VEGF treatment, (vi) Maintain media clarity and pupillary dilation as far as fundus imaging is possible, maintain adequate quality for evaluation of reference fundus imaging results, and subject for the case of ophthalmology and other examinations.

Exclusion Criteria

For study eye: Subjects were excluded from participation if any of the following exclusion criteria applied:

(i) Glaucoma (glaucomatous optic neuropathy, etc.), retinal detachment, macular degeneration, (ii) Cataracts and vitreous hemorrhage, (iii) Eye diseases other than diabetic retinopathy determined by the investigator to affect evaluation (e.g., retinal vein occlusion, uveitis, other inflammatory ophthalmic diseases, eye tumors, etc.), (iv) New blood vessels in disc, retina, iris, angle, etc., (v) Fluorescein angiography (macular ischemia) (\geq grade 2), (vi) Those who have undergone pan-retinal photocoagulation (PRP) or are scheduled to undergo PRP prior to visit 9 (8 weeks), (vii) Triamcinolone acetonide intravitreal and peribulbar steroid injections within 6 months of clinical trial drug administration, vitrectomy, intravitreal injection of anti-VEGF treatment), (viii) Within 2 months after capsulotomy (yttrium-aluminum-garnet capsulotomy), (ix) Those who have undergone major ophthalmic surgery within 3 months (cataracts, glaucoma, etc.) or are scheduled to undergo surgery prior to visit 9 (8 weeks), (x) Acquired aphakia as congenital, surgical and traumatic., (xi) In case the eye or periocular infection is not cured.

For systemic consideration:

(i) Diabetic patients with difficult glycemic control who are receiving or planning intensive insulin therapy, (ii) Uncontrolled hypertension, (iii) Subjects with clinically significant arrhythmias difficult to participate in clinical trials, (iv) Patients with a history of myocardial infarction in the last 3 months, (v) Patients with known severe kidney failure (kidney failure, patients on kidney dialysis, etc.), (vi) Patients with known severe liver failure , (vii) History of malignancy within 3 years, except thyroid cancer (papillary, follicular, medullary types corresponding to stage I or II), basal cell or squamous cell carcinoma of the skin, CIN and CIS of the cervix and carcinoma intraepithelial from other sites, (viii) Patients with known immunodeficiency, (ix) Patients with known autoimmune diseases (multiple sclerosis, myasthenia gravis, acute disseminated encephalomyelitis, etc.), (x) History of hypersensitivity reaction to components of this investigational drug, (xi) History of hypersensitivity to fluorescein, (xii) Subjects who have received contraindicated drugs or treatments before participating in the clinical trial and have not passed the prescribed period (data not shown), (xiii) Patients taking contraindicated drugs (data not shown), (xvi) Pregnant or lactating women who do not intend to stop breastfeeding, (xv) Women of childbearing age who are not permanently infertile (natural and artificial) or whose pregnancy is not confirmed by a pregnancy test (under 50 years), (xvi) Those who did not accept an effective contraceptive method during the clinical trial period, (xvii) Patients who have not passed 30 days from the date of signature of the consent form after participating in the previous clinical trial or who are currently participating in another clinical trial, (xix) Other diseases other than those listed above.

Study Drug Dose

Subjects satisfying the selection criteria through the screening test were administered EG-Mirotin once a day (3 mg in 1.5 ml of sterile saline), 5 times in total, for 5 days, and an additional follow-up period of about 7 weeks (total participation for 8 weeks; screening (V1), treatment period) 5 days (V2-V6), with a follow-up period of approximately 7 weeks (V7-V9)). End-of-study (EOS) is performed approximately 8 weeks \pm 1 (57 days \pm 7) from the first dose.

Criteria for Evaluation

The primary endpoint is the mean percent change in the ischemic index at each assessment point compared to baseline.

The Secondary endpoints are: (i) Fraction of subjects who progressed to Proliferative Diabetic Retinopathy (PDR) [ETDRS \geq 61] at each time of evaluation, (ii) Changes related to diabetic macular edema at each assessment point compared to baseline [No DME; non-Clinically significant macular edema (CSME), (iii) Changes in CSF thickness and retinal volume assessed by Spectral Domain-Optical Coherence Tomography (SD-OCT) at each assessment point, (iv) Best corrected Early Treatment Diabetic Retinopathy Study (ETDRS) visual acuity measured at each assessment time point, (v) Proportion of eyes that changed \geq 1 stage and \geq 2 stage (each improved and worsened) from baseline on the Diabetic Retinopathy Severity Scale (DRSS) at each time of assessment, (vi) Fraction of eyes that changed \geq 3 steps (each improvement and deterioration) from the baseline value on the Diabetic Retinopathy Severity Scale (DRSS) at each time of evaluation, (vii) Vascular leakage evaluated by UWFA at each time of evaluation, (viii) Changes in severity and frequency of peripheral lesions on

UWFA and fundus examination measured at each assessment point compared to baseline.

Safety endpoints are: (i) Incidence and characteristics of adverse events after administration of study drug (event pattern, severity, outcome, etc.); (ii) Incidence and characteristics of prespecified adverse events [ocular adverse events]; (iii) Physical examination, vital signs, electrocardiogram and clinical laboratory examination findings related to the administration of investigational drug.

Statistical analysis

Safety assessment group: This refers to a group of patients who have received at least one dose of the investigational drug after being assigned to this clinical trial and have undergone safety-related follow-up.

Assessment group FA (full analysis set): All clinical trial subjects assigned to randomization in this clinical trial are eligible. However, it refers to a group of patients who have been administered at least one clinical trial drug and whose efficacy can be assessed. The statistical analysis of the primary endpoint of this clinical study is performed as a two-tailed test below the significance level (α) of 0.1, and all other statistical analyzes are generally based on a two-tailed test below the significance level (α) of 0.05.

After the administration of the investigational drug, the number of subjects in the clinical trial, the incidence rate and the number of occurrences of adverse events related to the investigational drug, their severity, severity, measures taken and results, etc. are presented. The number of clinical trial subjects by System Organ Class (SOC) and Preferred Term (PT), the incidence rate and the number of occurrences are

summarized. Vital signs and quantitative laboratory tests provide descriptive statistics on the amount of change before and after administration of the investigational drug. The amount of change within the administration group is tested for the difference between before and after drug administration by the paired t-test or the Wilcoxon signed rank test. Changes in normal / abnormal (NCS, CS) before and after administration of the investigational drug in physical examination, laboratory examination, and electrocardiogram examination are presented in a contingency table, and the significance of the change within the group of Administration is statistically tested by McNemar's test or Bowker's test.

To investigate the effect of EG-Mirotin further, the cutoff point of V1 which means the significant decrease of the Ischemic Index was set. The ischemic index is divided into two groups by the cutoff point. This process was done by using "Maxstat" function in R packages. The repeated measures ANOVA test was used to identify changes of Ischemic and Leakage Index in time. To observe the average Ischemic Index changes difference between the two groups divided by the cutoff point, the Wilcoxon test, Repeated Measures ANOVA, and Bonferroni Post Hoc Analysis was used. R program version 4.0.4 (R Project for Statistical Computing, Vienna, Austria), SPSS version 28 (IBM, New York, USA), and SAS version 9.4 (SAS Institute, North Carolina, USA) was used for the statistical analysis and graphs of this clinical study.

RESULTS

Study Population

Total 10 subjects were selected randomly under the condition who are over 19 years old and have Type 1 or 2 diabetes and Non-Proliferative Diabetic Retinopathy (NPDR) with the degree from moderate to severe (ETDRS Severity Scale 43A~53). Also, the media clarity should be clear enough for Ultra-Wide Field Fluorescein Angiography (UWFA). The patients were excluded if they meet at least one criterion which can affect the results for this study. And the patients who have media opacity for UWFA were also excluded.

Safety Results

Adverse reaction: A total of 4 Treatment Emergent Adverse Events (TEAE) were observed in 2 subjects out of 10 (20.00%) who received the investigational drug. Among them, no subjects were reported experiencing a TEAE related to the investigational drug. No adverse events leading to death were reported among the 10 patients who received the drug, and 1 patient (10.00%) developed other serious adverse events. There were no reports of serious adverse events (serious adverse reactions) with a causal relationship to the investigational drug. No subject reported TEAE that resulted in premature discontinuation. One subject (10.00%, 2 cases) reported an adverse event scheduled for collection in advance [ocular adverse events: SOC Eye disorders or ophthalmic procedures between surgical and medical procedures].

All adverse reactions scheduled for collection in advance did not correspond to

TEAEs related to investigational drugs. As a result, there were no adverse drug reactions, so the safety was very good in terms of evaluation of adverse reactions.

Efficacy Results

The primary efficacy outcome: The overall average percent change in ischemic index at each evaluation point compared to baseline was statistically significant (Greenhouse-Geisser $F=9.456$, $p=0.004$ for the main effect of time), and a larger change was observed when the baseline ischemic index value was high (Greenhouse-Geisser $F=10.946$, $p=0.002$ for the time*group interaction). The baseline ischemic index (V1) for a total of 20 eyes was $3.82 \pm 4.78\%$, and at visits 7, 8 and 9 after administration of the study drug, they were $3.50 \pm 4.66\%$, $3.59 \pm 4.24\%$ and $3.11 \pm 3.85\%$, respectively. The changes from baseline were $-0.28 \pm 0.46\%$, $-0.52 \pm 0.76\%$, and $-0.71 \pm 1.02\%$, respectively (V7: $p = 0.0025$; V8: $p = 0.0095$; V9: $p = 0.0005$, respectively). When the baseline ischemic index is greater than 1.59%, a statistically significant improvement effect over time was observed (Wilk's lambda $F=9.142$, $p=0.002$ for the simple main effect of time for the >1.59 group). When the baseline ischemic index value is low, no improvement or deterioration is observed.

The Secondary Efficacy Outcomes

Progression to proliferative diabetic retinopathy (PDR) [ETDRS ≥ 61] was not observed. Change in degree of diabetic macular edema [without AMD; not CSME (Clinically Significant Macular Edema)]: (i) Most changes were not observed from baseline, (ii) 2 of 6 eyes (33.33%) assessed as baseline SMD improved to a grade 'no

SMD' after treatment (V8 and V9), (iii) Edema: No Eyes (eyes) with degree of worsening were reported. (iv) Changes in CSF thickness and retinal volume: No significant changes were observed with time before and after administration. (v) Best corrected ETDRS visual acuity change compared to baseline: No significant changes were observed before and after administration.

Changes in the Diabetic Retinopathy Severity Scale (DRSS) from baseline: (i) No eyeballs improved in 1 or 2 steps compared to baseline, (ii) One eye that deteriorated further from stage 1 or stage 2 was observed, (iii) No eyeballs with ≥ 3 steps (improvement and deterioration, respectively) were observed compared to baseline.

Change in vascular leakage rate from baseline: the average leakage index was decreased over time as the overall main effect of time was significant (Greenhouse-Geisser $F=6.442$, $p=0.008$). After test drug administration, changes at visits 7, 8, and 9 were $-0.69 \pm 1.17\%$, $-0.85 \pm 1.53\%$ and $-2.09 \pm 2.32\%$, respectively, and the changes were statistically significant (vs. V7: $p = 0.0233$; V8: $p = 0.0305$; V9: $p = 0.0001$, respectively).

Changes in the severity and frequency of peripheral lesions: (i) Retinal hemorrhage/retinal microvascularization: "no change" in severity in 18 eyes (90.00%); "Best" 2 eyes (10.00%); No change was observed in the distribution, (ii) venous beading : 'No change' in all (100.00%) V9 visits compared to baseline in severity; One eye each with a dilated venous beading with intraretinal and superonasal microvascular abnormalities, (iii) severity "unchanged" 18 eyes (90.00%); "Best" 2 eyes (10.00%); No changes were observed in the distribution

Overall, the statistically significant improvement in ischemic and leakage index

was observed by UWFA. These indices measure lesions related to fundus microvascularization, by which EG-Mirotin exerts a therapeutic effect.

Considering that the subjects with the higher initial baseline ischemic index showed the greater improvement in the index, the follow-up clinical trial may require the recruitment of the subjects with a high baseline ischemic index.

Ischemic Index

The UWFA images of 17 eyes from 9 patients were assessed at before administration (V1, baseline), 2-, 4-, and 8-weeks post-administration (V7, V8, V9, respectively). There was an overall significant decrease in the ischemic index across each visit (Greenhouse-Geisser $F=9.456$, $p=0.004$ for the main effect of time). The average Ischemic Index decreased over the visits except for the interval between V7 and V8 (Fig. 3). The administration of EG-Mirotin significantly decreased the average of the Ischemic Index of the subjects as compared with the baseline (3.82 ± 4.78) and the last visit (3.11 ± 3.85) (V9) ($p=0.0005$).

IPD1 was the difference of the Ischemic Index between V1 and V7 (Fig. 4 A), IPD2 was the difference between V1 and V8 (Figure 4 B), and IPD3 was the difference between V1 and V9 (Figure 4 C). The patients were divided into two groups by the cutoff points calculated from the baseline ischemic index by 'maxstat' package in R (1.59). All eyes with an ischemic index of more than 1.59 decreased in size (Fig. 4 & 5). To observe whether there was a significant difference between two groups, the Wilcoxon test was used. Between two groups, there was a statistically significant difference in IPD1 ($p < 0.001$), IPD2 ($p=0.004$), and IPD3 ($p<0.001$) (Fig. 4).

To observe the change in Ischemic Index in each group, the Repeated Measures ANOVA test was used. The Ischemic Index significantly decreased over time (Greenhouse-Geisser $F=9.456$ for the main effect of time). There was a significant interaction effect between the time and the group (Greenhouse-Geisser $F=10.946$ for the time*group interaction). A statistically significant change in Ischemic Index was observed in the >1.59 group (Wilk's lambda $F=9.142$, $p=0.002$ for the simple main effect of time), while no change in Ischemic Index was observed in the ≤ 1.59 group (Wilk's lambda $F=0.038$, $p=0.990$ for the simple main effect of time).

Bonferroni Post Hoc Analysis showed that the Ischemic Index at all visits (V7, V8, V9) ($p=0.001$, $p<0.001$, $p=0.001$, respectively) had a significant difference compared to the baseline in the group greater than 1.59. The group less than or equal 1.59 the Ischemic Index did not have a significant difference by the visit. In the group greater than 1.59, the administration of EG-Mirotin decreased the average of the Ischemic index as compared with the baseline (7.131 ± 4.86) and the last visit (5.714 ± 3.97) (V9). With the Ischemic Index cutoff of 1.59, the higher Ischemic Index indicated a statistically significant decreasing rate.

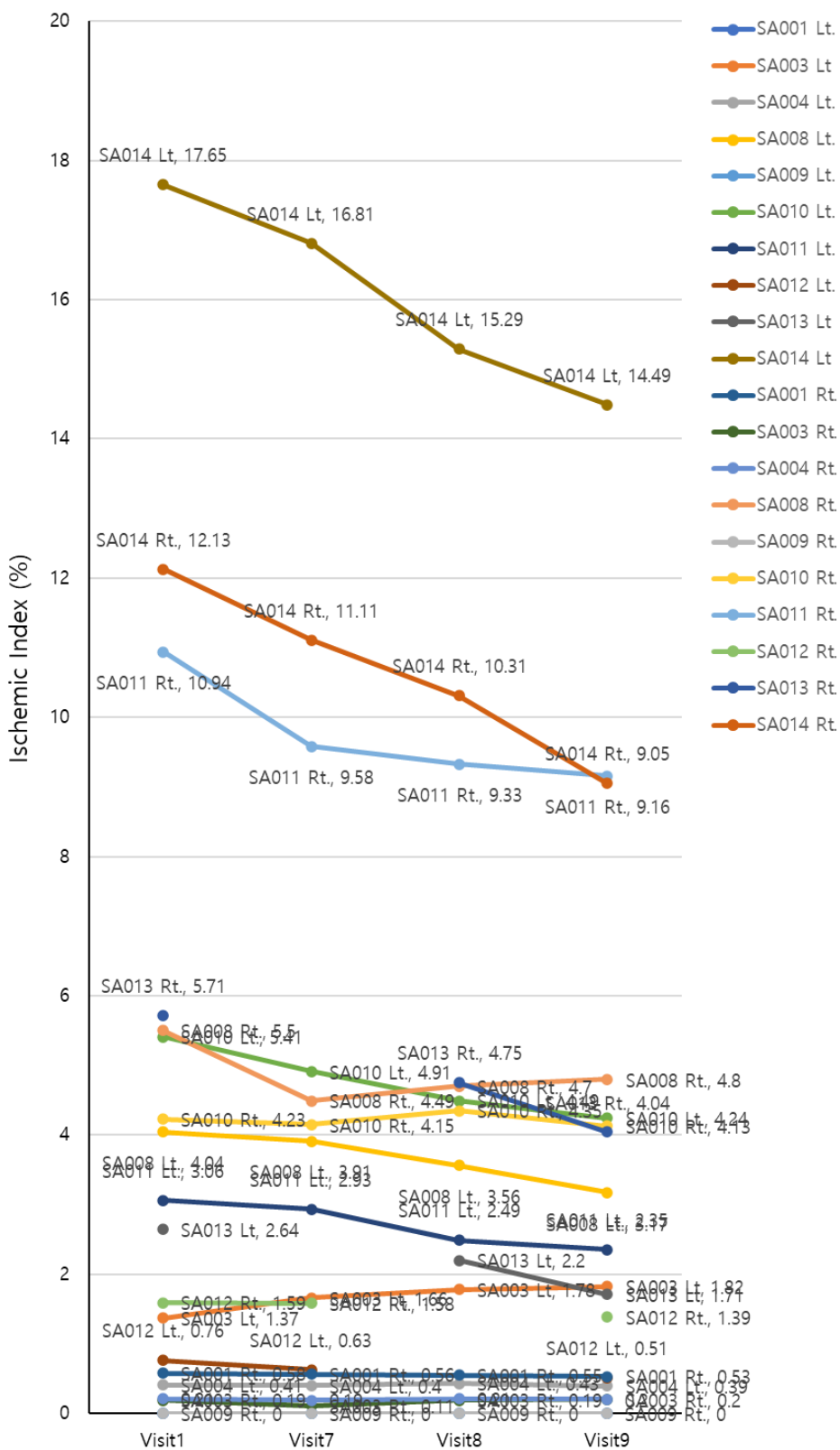


Figure 3. The Ischemic Index changes of subjects through all visits.

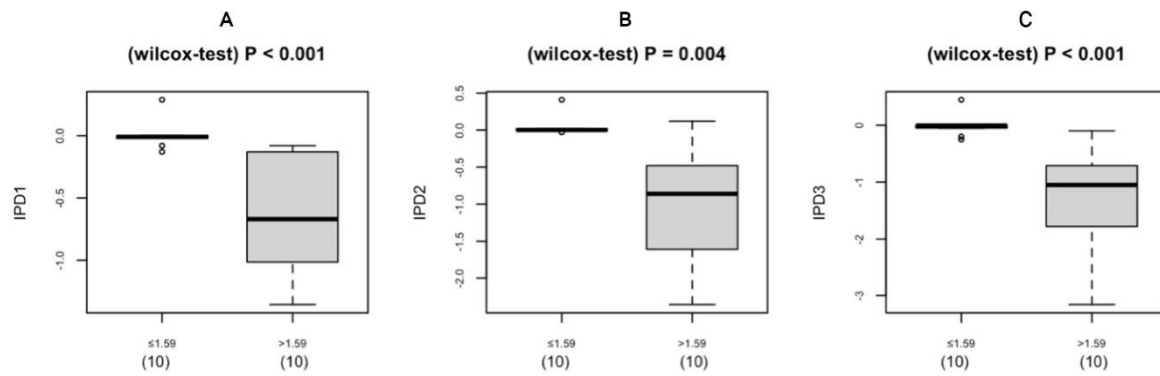


Figure 4. The boxplot of the IPD distribution.

*IPD (Ischemic Percent Difference), the changes of Ischemic Index from earlier to later visit. A: Ischemic Index between V1 and V7; B: the difference between V1 and V8; C: the difference between V1 and V9.

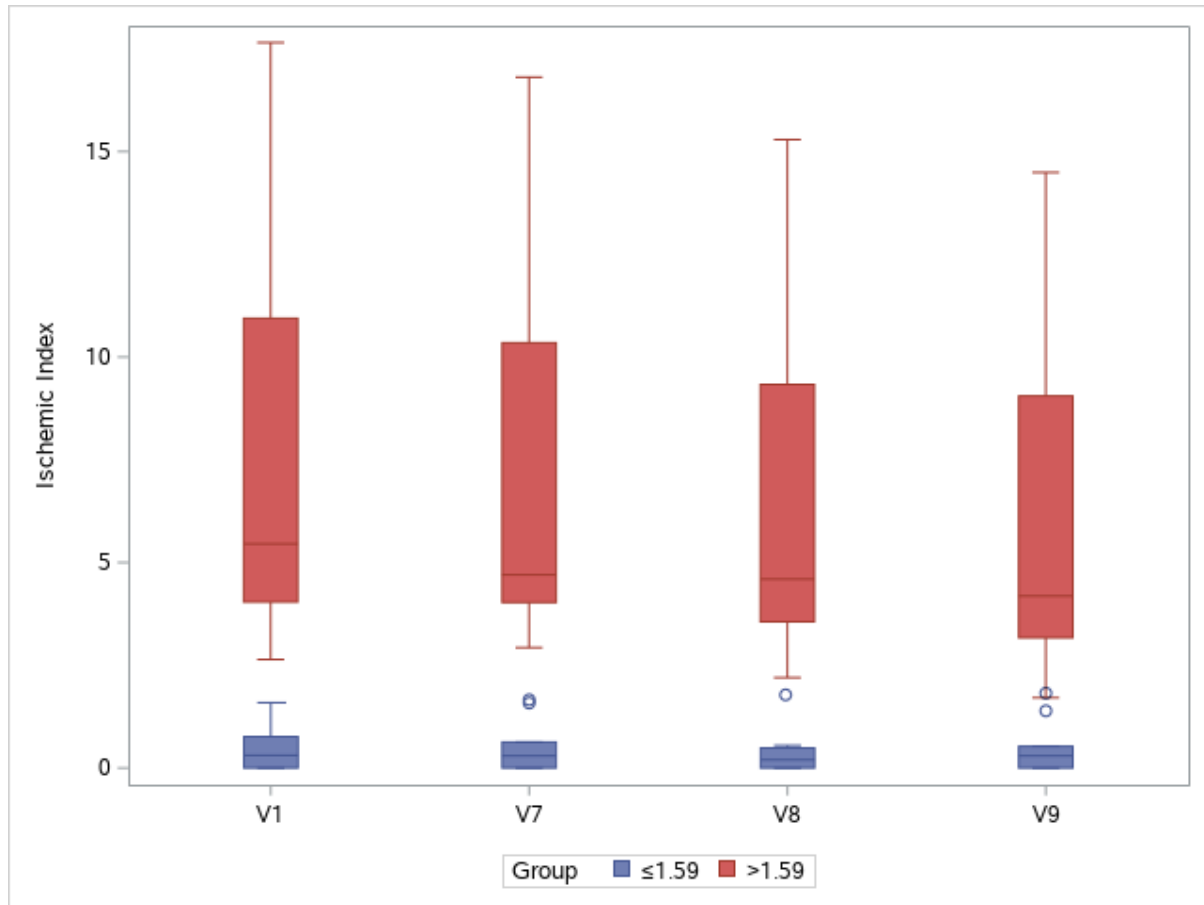


Figure 5. The changes of Ischemic Index through all visits. Groups are separated by cutoff value of 1.59.

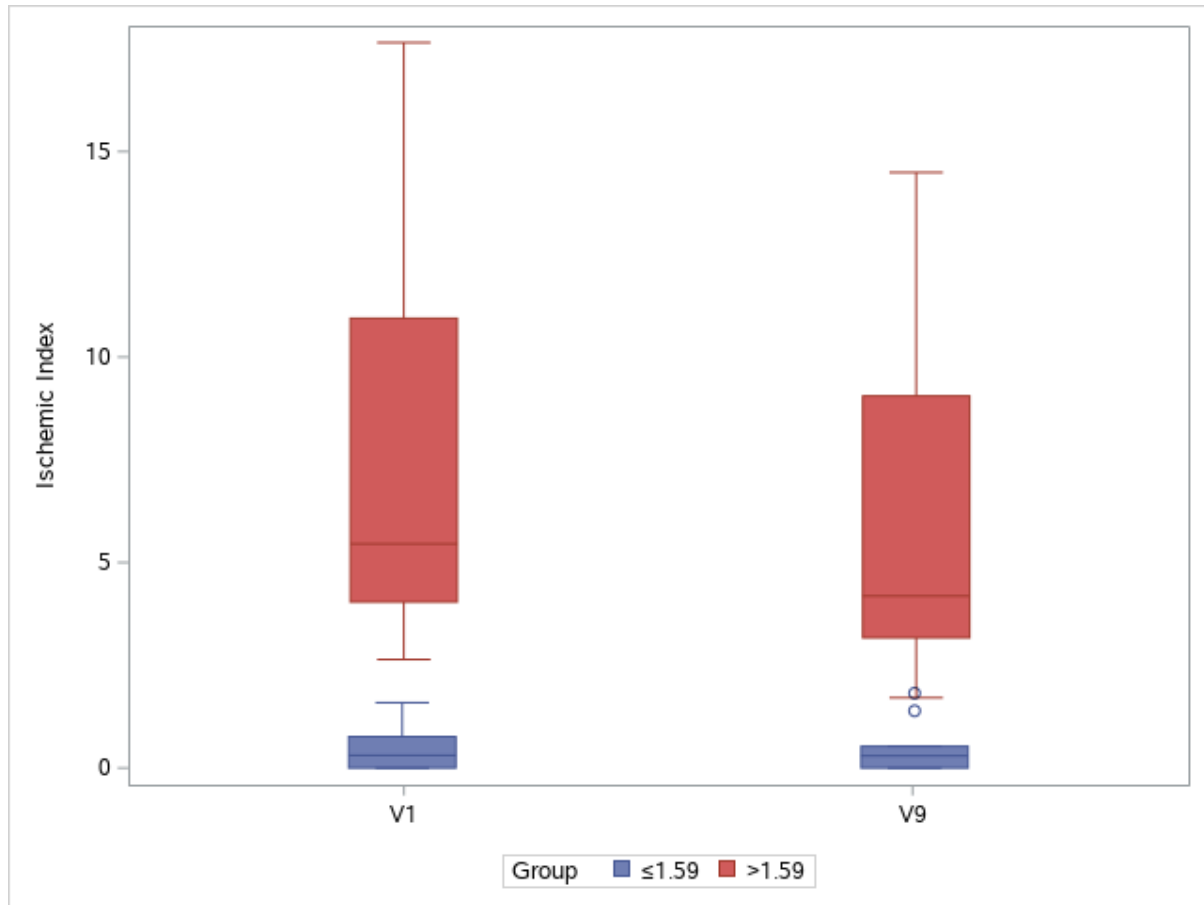


Figure 6. The changes of Ischemic Index between V1 and V9. Groups are separated by cutoff value of 1.59.

Leakage Index

The UWFA images of 20 eyes from 10 patients were assessed at before administration (V1, baseline), 2, 4, and 8 weeks post-administration (V7, V8, V9, respectively). There was an overall significant decrease in the leakage index across each visit (Greenhouse-Geisser $F=6.442$, $p=0.008$ for the main effect of time). The average Leakage Index decreased over the visits except for the interval between V7 and V8. Though the mean value increased between V7 and V8, the changes were not statistically significant ($p=0.14$). The administration of EG-Mirotin decreased the average of the Leakage Index compared with the baseline (13.60 ± 11.21) and the last visit (11.51 ± 9.80) (V9) ($p=0.0001$) (Fig. 7).

To identify whether the ischemic index and leakage index are correlated at each timepoint, the Spearman's rank correlation test was conducted, as these indices were not normally distributed (Shapiro-Wilk $w=0.7868$, $p<0.0001$ for the ischemic index, $w=0.9167$, $p<0.0001$ for the leakage index). The two indices were moderately correlated (Spearman $\rho=0.3779$, $p=0.0007$) (Fig. 8).

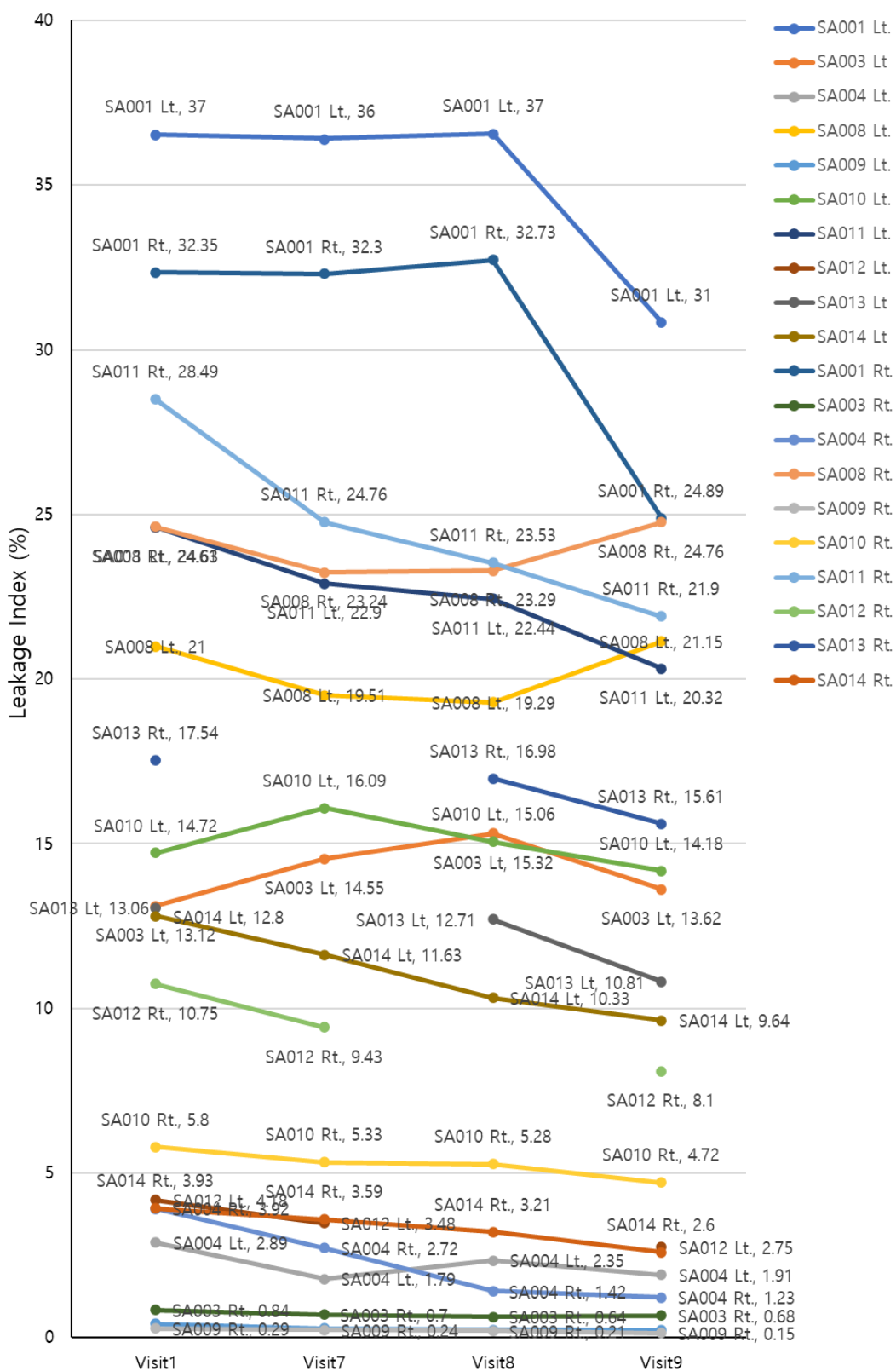


Figure 7. The Leakage Index changes of subjects through all visits.

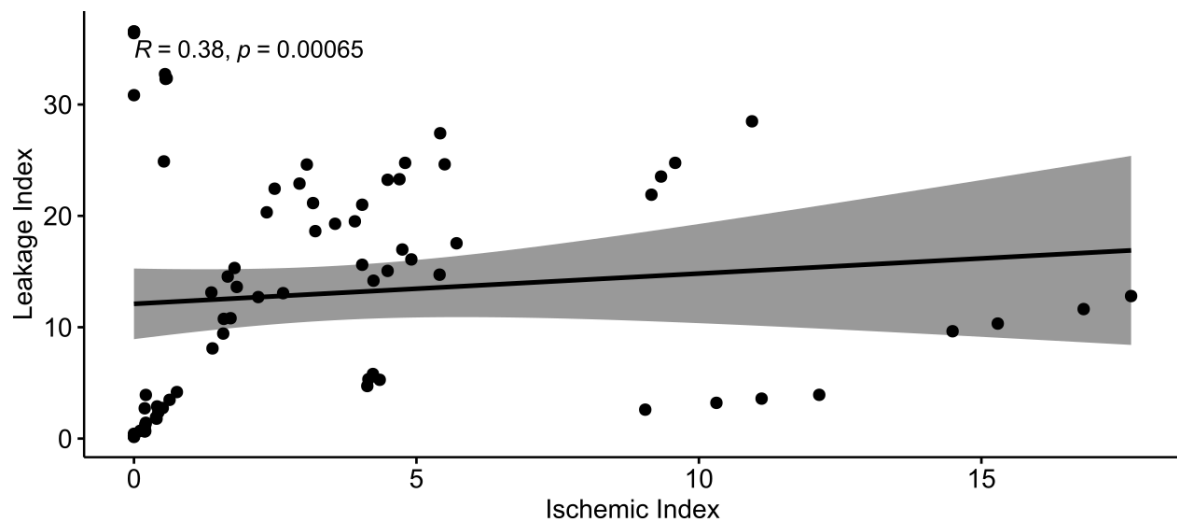


Figure 8. The Spearman correlation between the Ischemic and Leakage Index.

DISCUSSION

Diabetes mellitus is perhaps the most persistent disease in human history. After a tremendous amount of work has been invested into diabetes research, diabetes still negatively affects well-being of the patients with numerous complications varying in the locus and severity. Diabetic retinopathy a common but severe complication of diabetes in eyes, is a major cause of blindness and thus greatly deteriorates of the quality of life over a long period of time. However, there is no approved drug for the early stage of DR (NPDR), and therefore the patients are left treated until the disease has progressed severely (PDR). For this reason, we believe that improving the quality of life of patients by slowing or halting the progression of visual impairment with an early-stage intervention is a challenge in modern medicine.

Based on recent treatment trends, there are two main therapeutic goals for DR: (1) prevent progression from non-proliferative diabetic retinopathy (NPDR) to proliferative diabetic retinopathy (PDR), which has a high risk of visual loss due to vitreous hemorrhage or tractional retinal detachment; (2) and to prevent loss of central vision due to diabetic macular edema. To achieve the goals of treatment, it is necessary to prevent capillary leakage or suppress the appearance of new blood vessels, which are due to an increase in VEGF in the eye due to retinal ischemia. Classic panretinal photocoagulation (PRP), which has been used for a long time, is effective in lowering VEGF. However, PRP irreversibly destroys the retina so that the eyes will not return to NPDR status after receiving PRP treatment (EMA, 2019). In addition, the recent popular method, intraocular injection of anti-VEGF ab is a potent therapy that can achieve these goals more quickly. However, this type of anti-VEGF ab injection aims to obtain short-term effects in an irreversible stage where the blood

vessels cannot return to normal, so the patient's eye condition will continue to deteriorate little by little. If it is possible to reduce the damage and ischemia of retinal capillaries, which are the causes of capillary leakage and neovascularization, it can be speculated that the risk of blindness may be reduced by preventing the progression of DME and PDR.

EG-Mirotin was developed as a medication to help maintain normal blood vessels in DR patients before the capillary damage progresses irreversibly. Diabetes is a disease in which high blood sugar circulates through the body and damages blood vessels. In the human body, the kidney and retina are the places with the most capillaries and the places with the highest blood flow per unit area. Therefore, the kidneys and retina are the most damaged areas in the presence of diabetes, and damage to the retina ultimately increases the risk of blindness. Abnormally high blood sugar damages capillary endothelial cells, which are only made up of a layer of endothelial cells. For an average of 5 years suffering from diabetes, the surrounding cells located outside the capillaries restore the endothelial cells to normalize the capillaries. However, after an average of 5 years, even the surrounding cells become damaged and capillary microaneurysms form, causing blockage or bleeding. Therefore, perivascular cells become ghost cells, irreversible capillary damage begins and the retina cannot maintain its normal appearance, and diabetic retinopathy eventually progresses regardless of treatment. First, the peripheral capillaries of the retina become occluded and disappear. And when the ischemic region of the retina increases, VEGF increases to demand the creation of new capillaries in the retina with ischemia. If it is possible to revive or maintain the surrounding cells at the stage where the endothelial cells are damaged, the retinal capillaries can be revived and ischemia can be reduced.

EG-Mirotin was developed for the purpose of preventing retinal damage and blindness by restoring capillaries before damage to retinal capillaries progresses to an irreversible stage. Existing intraocular anti-VEGF Ab drugs are a treatment method to reduce damage to new blood vessels in the irreversible stage. While aflibercept (Eylea®), one of the anti-VEGF treatments, is also indicated for NPDR in the USA, a need of frequent injections into the eye causes burden for both physicians and patients and thus precludes accessibility at the NPDR stage. However, EG-Mirotin is considered a treatment to prevent capillary damage as early as possible in the stage of NPDR so that it does not progress to an irreversible stage with the ease of subcutaneous injection. In this study, it was confirmed that when EG-Mirotin was administered, the capillaries were restored at the interface where retinal ischemia occurred by a certain mechanism, and the ischemic area was also reduced. In other words, by blocking irreversible capillary damage by recruiting surrounding cells and actively initiating treatment at the NPDR stage, progression to the proliferative stage can be prevented as much as possible. Furthermore, since EG-Mirotin is administered by subcutaneous injection rather than an injection into or around the eye, the effect of reducing the patient's fear of ocular injection is encouraging. Since the drug with this mechanism is the first in the world, research data is continually accumulating. In the future, more research will be done on EG-Mirotin develop better medicine for NPDR.

In our study, the progression to proliferative DR did not occur in any subjects. Moreover, the ischemic index and the leakage index, evaluated from the UWFA imaging of the lesions related to the microvascularization of the fundus, were significantly reduced compared to the baseline. It is important to note that a greater degree of change was observed in patients who had a large ischemic index value at the baseline. In this study, the subjects were assigned into two groups (high

and low) based on the cutoff point of baseline ischemic indices (1.59) calculated by 'maxstat' package in R. There was a significant interaction between the group assignment and the therapeutic effects over time, of which statistical significance was observed only in 'high' group in the post-hoc comparison.

Although the 'low' group showed no difference in ischemic index over time, this is expected because there were small room for changes as initial ischemic value is extremely low ($\leq 1.59\%$) with a few patients having zero ischemic index. Therefore, no change in index can also be interpreted as no deterioration of the disease. As retinal ischemia is a major factor for the pathogenesis of PDR (Wiley, 2013), the prevention of ischemia may protect the patients from the progression to PDR. A larger, placebo-controlled, follow-up clinical with longer duration of observation will be required to reveal the protecting effects of EG-Mirotin.

EG-Mirotin is a drug containing an RGD sequence (Coller, BS *et al.*, 1995) and our in-house experimental data provide novel observations: (i) EGT022, containing an RGD sequence, restores retinal blood vessels in OIR mouse model (data not shown), (ii) the EGT022-induced maturation of functional retinal blood vessels is closely associated with pericyte recruitment and blood vessel integrity (Jang, JW *et al.*, 2015). Interestingly, it is assumed that the statistically significant ameliorating effect on ischemia and leakage can be attributed to the active ingredient and molecular mode of action of EG-Mirotin by aforementioned recruiting pericytes (Papetti, M *et al.*, 2002) and then stabilizing blood vessels

We found no serious side effects or safety concerns with EG-Mirotin in this study. None of the subjects reported TEAEs that resulted in premature termination. In preclinical studies, EG-Mirotin has shown to have no acute toxicity or genotoxicity. On

itself EG-Mirotin does not induce angiogenesis; it was found to have no growth promoting effects on malignancies. Efficacy of EG-Mirotin in retinal edema has been demonstrated in the Miles assay model as a supplemental assay to assess the vascular permeability of the microvessels. EG-Mirotin appeared to be effective to ameliorate retinopathy-related abnormalities for up to 3 weeks as demonstrated by OCT, fundoscopy, angiography and histopathology in the streptozotocin (STZ) induced model of diabetic retinopathy in rats (Jang, JW *et al.* 2016)

Our study has several limitations. Based on our preclinical experience, we elected to use 3 mg of EG-Mirotin which may not be a sufficient dose to cause dramatic changes in the retinal blood vessels. Theoretically, we could increase the dose up to 10 mg per administration. However, we still need to accumulate more safety data to increase the dose of administration. In this study the participants had to visit the clinic during the treatment period (i.e., a total of 5 days: V2-V6). The daily visit to the clinic is a nuisance for many patients. Therefore, our future goal is to make our EG-Mirotin similar to insulin for self-injection. So that patients do not have to make a daily visit to the clinic for a long period of time

CONCLUSION

We developed EG-Mirotin (EGT022), a novel, first-in-class, subcutaneously-delivered peptide drug for non-proliferative diabetic retinopathy (NPDR), for which currently has no selectively designed drug. From this clinical trial, it was concluded that the safety and efficacy of EG-Mirotin were demonstrated, as no serious adverse events with a causal relationship were reported during this study, and there was an overall improvement of ischemic and leakage index with no progression to PDR.

To further verify the therapeutic effects of EG-Mirotin on diabetic retinopathy, it was determined that larger clinical trials with a focus on patients with high baseline ischemic index would be required.

In conclusion, EG-Mirotin has given a new hope to the treatment of NPDR, which has so far had few treatment options. Not only being the selectively designed first-in-class drug for NPDR, EG-Mirotin is also subcutaneously administered, eliminating the burden of and the fears against the intraocular injection, which is the only currently available treatment for the PDR, which is a late, irreversible stage of DR. Moreover, EG-Mirotin was found to reverse the ischemia and leakage of capillaries in the retina caused by diabetes. Therefore, we hope that EG-Mirotin will preserve the well-being of the diabetic retinopathy patients at the reversible stage by greatly reducing the risk of loss of vision with the additional benefit of simple administration.

DECLARATIONS

Competing Interest Statement

Dae Hyuk You, Jeongyoon Lee, and Sung Jin Lee are independently contracted consultants of EyeGene Inc. and H. Christian Hong is an employee of EyeGene Inc.

Author contributions

Study concept/design: SY, SJL

Data acquisition: SY, SJL

Data analysis and interpretation: SY, DHY, JL, HCH, SJL

Review and final approval of the manuscript: SY, DHY, JL, HCH, SJL

Clinical Trial Registration

Clinical Research Information System (CRIS): KCT0005124

The above KCT0005124 has been listed in **International Clinical Trials Registry Platform** by World Health Organization

<https://trialssearch.who.int/Trial2.aspx?TrialID=KCT0005124>

Clinical Trial (IRB Approval Number)

SCHUH2020-03-004

Funding Statement

This study was supported and funded by EyeGene, Inc.

REFERENCES

- Bergers G, Song S. The role of pericytes in blood-vessel formation and maintenance. *Neuro Oncol*. 2005;7(4):452-464. doi:10.1215/S1152851705000232
- Chistiakov DA. Diabetic retinopathy: pathogenic mechanisms and current treatments. *Diabetes Metab Syndr*. 2011;5(3):165-172.
- Coller BS, Anderson K, Weisman HF. New antiplatelet agents: platelet GPIIb/IIIa antagonists. *Thromb Haemost*. 1995;74(1):302-308.
- Das A, Stroud S, Mehta A, Rangasamy S. New treatments for diabetic retinopathy. *Diabetes Obes Metab*. 2015 Mar;17(3):219-30.
- Díaz-Flores L, Gutiérrez R, Varela H, Rancel N, Valladares F. Microvascular pericytes: a review of their morphological and functional characteristics. *Histol Histopathol*. 1991 Apr;6(2):269-86.
- European Medicines Agency. Assessment report: Lucentis. https://www.ema.europa.eu/en/documents/variation-report/lucentis-h-c-715-ii-0076-epar-assessment-report-variation_en.pdf
- Fong DS, Aiello L, Gardner TW, et al. Retinopathy in diabetes. *Diabetes Care*. 2004;27 Suppl 1: S84-S87.
- Jang JW, Cho YJ, Kim HJ, et al. Blood Vessel Maturation by Disintegrin in Oxygen-Induced Retinopathy. *Curr Eye Res*. 2016;41(5):689-699. doi:10.3109/02713683.2015.1050737
- Jeon OH, Kim D, Choi YJ, Kim SH, Choi WS, Kim DS. Novel function of human ADAM15 disintegrin-like domain and its derivatives in platelet aggregation. *Thromb Res*. 2007;119(5):609-619.
- Klein R, Klein BEK, Moss SE (1984) Prevalence of diabetes mellitus in Southern Wisconsin. *Am J Epidemiol* 119: 54–61
- Kuwabara T, Cogan DG. Retinal vascular patterns. VI. Mural cells of the retinal capillaries. *Arch Ophthalmol* 1963; 69: 492–502
- Lausen B, Schumacher, M. Evaluating the effect of optimized cutoff values in the assessment of prognostic factors, *Computational Statistics & Data Analysis*, Volume 21, Issue 3, 1996, Pages 307-326
- Lee R, Wong TY, Sabanayagam C. Epidemiology of diabetic retinopathy, diabetic macular edema and related vision loss. *Eye Vis (Lond)*. 2015 Sep 30;2:17.
- Papetti M, Herman IM. Mechanisms of normal and tumor-derived angiogenesis. *Am J Physiol Cell Physiol*. 2002;282(5):C947-C970. doi:10.1152/ajpcell.00389.2001
- Romero-Aroca P. Managing diabetic macular edema: The leading cause of diabetes blindness. *World J Diabetes*. 2011 Jun 15;2(6):98-104

Saeedi P, Petersohn I, Salpea P, et al. Global and regional diabetes prevalence estimates for 2019 and projections for 2030 and 2045: Results from the International Diabetes Federation Diabetes Atlas, 9th edition. *Diabetes Res Clin Pract.* 2019;157:107843. doi:10.1016/j.diabres.2019.107843

Suganya N, Bhakkiyalakshmi E, Sarada DV, Ramkumar KM. Reversibility of endothelial dysfunction in diabetes: role of polyphenols. *Br J Nutr.* 2016 Jul;116(2):223-46.

Wiley HE, Ferris FL. Chapter 47 – Nonproliferative Diabetic Retinopathy and Diabetic Macular Edema. *Retina (Fifth Edition).* 2013; 940-968

Wilkinson CP, Ferris FL 3rd, Klein RE, et al. Proposed international clinical diabetic retinopathy and diabetic macular edema disease severity scales. *Ophthalmology.* 2003;110(9):1677-1682. doi:10.1016/S0161-6420(03)00475-5

Zhao H, Chappell JC. Microvascular bioengineering: a focus on pericytes. *J Biol Eng.* 2019;13:26. Published 2019 Mar 29. doi:10.1186/s13036-019-0158-3