

1 **Research Article**

2 **Effect of laser assisted local anesthesia in single-visit root canal treatment for mandibular**
3 **molar teeth with acute irreversible pulpitis**

4 Subashri V BDS, MDS ¹, Nivedha V ¹ BDS, MDS, Anand Sherwood I BDS, MDS, PhD ², Paul V Abbott BDSc, MDS,
5 FRACDS(Endo) ³, James L Gutmann DDS, Cert Endo, PhD, FACD, FICD, FADI, FAAHD, FDSRCSEd, Diplomate ABE ⁴,
6 Omar Farooq BDS, MDS ⁵, Aarthi MV BDS, MDS ⁶

7 ¹ – Post graduate student, Department of Conservative Dentistry and Endodontics, CSI College of Dental Sciences,
8 Madurai, India. shrimitha26@gmail.com

9 ² – Professor and Head, Department of Conservative Dentistry and Endodontics, CSI College of Dental Sciences,
10 Madurai, India. anand.sherwood@gmail.com

11 ³ - Winthrop Professor of Clinical Dentistry, Endodontist, Program Co-ordinator (Endodontics), UWA Dental School,
12 University of Western Australia, Australia. paul.v.abbott@uwa.edu.au

13 ⁴ - Professor and Chair, Department of Endodontics and Postgraduate Program Director in Endodontics at Nova
14 Southeastern University College of Dental Medicine, Florida, United States. jlg4570@aol.com

15 ⁵ – Reader, Department of Conservative Dentistry and Endodontics, CSI College of Dental Sciences, Madurai, India.
16 dr.omarfarooq.endo@gmail.com

17 ⁶ – Senior Lecturer, Department of Conservative Dentistry and Endodontics, CSI College of Dental Sciences,
18 Madurai, India. aarthiravisankar@gmail.com

19 **Running title:** Laser assisted local anesthesia

20 **Corresponding Author**

21 Dr. I. Anand Sherwood, Professor and Head, Department of Conservative Dentistry and
22 Endodontics, CSI College of Dental Sciences and Research, Anand Dental Clinic, No 1 Meenakshi
23 Towers, P T Rajan Road, Bibikulam, Madurai – 625002.Tamil Nadu India

24 Mobile Number: 9443805150

25 Email: anand.sherwood@gmail.com

26 **Acknowledgement**

27 The authors deny any conflicts of interest

28 **Institutional ethical committee**

29 CSI College of Dental Sciences and Research, Madurai – 625001, Institutional Ethical committee
30 and Institutional Review board. CSICDSR/IEC/0052/2018. Members unanimously approved the
31 proposed study and advised to proceed with the study.

32 **Clinical trial registry**

33 Clinical trial registered with ClinicalTrials.gov (NCT04735120)

34

35

36 **Effect of laser assisted local anesthesia in single-visit root canal treatment for mandibular**
37 **molar teeth with acute irreversible pulpitis**

38 **Abstract**

39 Present study evaluated the efficacy of laser activation to control intra- and post-operative pain
40 in single-visit root treatment for mandibular molar teeth with acute irreversible pulpitis
41 following 2% lignocaine inferior alveolar nerve block. Ninety-eight patients presenting with pain
42 were randomly divided into two anesthetic groups. Group-I inferior alveolar nerve block plus
43 buccal infiltration and intra-ligamentary injections, Group-II inferior alveolar nerve block
44 followed by laser irradiation focused directly on the pulp tissue. Intra- and post-operative pain
45 intensities were assessed on a 10-point scale. The mean intra-operative pain scores in group-I
46 was 6.62 ± 1.6 and in group-II before and after laser irradiation pain scores was 6.94 ± 2.1 and
47 1.3 ± 2.04 , respectively. Post-operative pain scores at 24-hrs in the laser group were
48 significantly higher. Laser irradiation applied directly on pulp tissue for control of intra-
49 operative pain was effective, thereby negating the need for additional local anesthesia.

50

51 **Clinical relevance**

52 Laser activation was effective method to control intra-operative pain in irreversibly inflamed
53 pulp.

54 Laser irradiation did not cause adverse post-operative pain.

55 **Keywords:** Acute irreversible pulpitis, diode laser, inferior alveolar nerve block, intra-operative
56 pain, lignocaine, supplemental injection.

57

58

59 Introduction

60 A mandibular molar tooth with acute irreversible pulpitis is one of the most disconcerting
61 situations to be encountered in an endodontic clinic (1). Treatment options for these situations
62 are limited to either pulpotomy, pulpectomy, extraction or prescribing potent analgesics (1).
63 Achieving satisfactory anesthesia and reducing the incidence of post-treatment discomfort are
64 the particular difficulties encountered in the endodontic treatment of these teeth (1). Multiple
65 strategies have been explored to attain profound anesthesia and to control post-operative pain
66 in these situations (2). An earlier report from the authors' department concluded that pre-
67 operative ketorolac tromethamine was not effective in reducing the intra-operative pain for
68 mandibular molar teeth with acute irreversible pulpitis and apical periodontitis when using
69 inferior alveolar nerve blocks (IANB) with both lignocaine and articaine anesthetic agents.
70 However, it was effective in reducing post-operative pain after using lignocaine which was in
71 agreement with a meta-analysis (3, 4). Mean intra-operative pain scores for both anesthetic
72 agents were 4.33 and 4.22, respectively, and 27 (21.4%) patients required supplemental
73 anaesthesia to control their intra-operative pain in the aforementioned study (3). In another
74 clinical study in the authors' department where an inferior alveolar nerve block was used plus
75 buccal nerve infiltration and intra-ligamentary injection with both anesthetic agents for single-
76 visit root canal treatment in mandibular molar teeth with acute irreversible pulpitis, the mean
77 intra-operative pain scores were 2.43 and 3.19 for the two anesthetic agents, respectively, and
78 12 (9.4%) patients required supplemental anesthesia (5). Supplemental anaesthesia
79 requirements were far more reduced in the above-cited clinical trial when patients were given
80 multiple injections prior to commencement of the root canal treatment (5).

81 Patients are generally apprehensive regarding multiple injections before root canal
82 treatment. Furthermore, the patients' medical condition may preclude additional local
83 anaesthetic agents. To circumvent this problem, the use of laser activation was investigated in a
84 pilot study. Laser application for intra-operative pain control in a previous clinical trial was used
85 on the hard tissue of the tooth prior to local anesthetic delivery and never directly on the pulp
86 (6, 7). However, laser application is known to allow painless soft tissue excision. Laser activation
87 directly on the pulp to reduce intra-operative pain in acute irreversible pulpitis after local
88 anesthetic administration has not yet been investigated.

89 The aim of the present study was to assess laser application efficacy when applied
90 directly on the pulp in patients with intra-operative pain following inferior alveolar nerve block
91 in mandibular molar teeth with acute irreversible pulpitis. The secondary aim was to assess
92 their post-operative pain following laser application in single-visit root canal treatment.

93 **Materials and Methods**

94 A total of 172 patients requiring root canal treatment for pain due to acute irreversible pulpitis
95 with primary acute apical periodontitis in carious mandibular first and second molars were
96 identified based on standard subjective and objective criteria (8). The study was conducted from
97 February 2020 to January 2021. The sample size was determined from the assumption of a pilot
98 study conducted in the corresponding author's department in 20 patients managed with a
99 similar protocol where there was intra-operative pain reduction of 80%. Using a χ^2 with effect
100 size = 0.50 and power ($1 - \beta$ err prob) = 0.95 (G*Power 3.1.9.2, Universität Kiel, Germany), 80
101 patients were required. Accounting for attrition in the follow-up, the number was increased to

102 98 patients. Subsequent to approval from the Institutional Ethics Committee, the trial was
103 registered with ClinicalTrials.gov and a total of 172 patients with acute irreversible pulpitis and
104 primary acute apical periodontitis due to carious mandibular molar teeth were enrolled in the
105 study. The patients (or where appropriate, parents or guardian) were informed about the
106 nature of the treatment and the study, and they were asked to sign an informed consent form.
107 The methodology adopted for this study was similar to clinical experiments conducted earlier in
108 the authors' department (3).

109 Patients referred to the Department of Conservative Dentistry and Endodontics with
110 pain due to acute irreversible pulpitis from carious mandibular first and second molar teeth
111 requiring root canal treatment were evaluated as possible candidates for this study. Subjects
112 aged between 13 and 70 years were included in the study. All patients reported mild to severe
113 pain that was continuous, spontaneous, radiating, nocturnal or throbbing in nature. All the
114 teeth included in this study responded to cold pulp sensibility testing (Endo-Frost, Coltene
115 Whaledent, Switzerland) with exaggerated pain, with or without lingering. They also had
116 tenderness on percussion. Additionally, profuse bleeding was evident upon gaining access into
117 the pulp chamber. The teeth included in the study also did not have any evidence of periapical
118 bone changes on the pre-operative periapical radiographs.

119 Exclusion criteria were absence of pain upon gaining access to the pulp following local
120 anesthetic administration, teeth with poor periodontal or restorative prognosis, patients with
121 systemic ailments or conditions hindering single visit root canal treatment, patients not willing
122 to participate in the post-operative recall evaluation, any anatomic variation such as extra roots

123 or root canals, C-shaped roots, and patients with a history of allergy. A PRIRATE 2020 (9) flow
124 chart of the experimental procedure is depicted in Figure 1.

125 Experimental procedure

126 All root canal procedures were done by a single operator. The levels of pre-, intra- and post-
127 operative pain at 24 hrs and 48 hrs for each patient were recorded using a 10-point visual
128 analogue scale (VAS). The participants indicated the intensity of their pain by choosing a
129 number using the following values: levels 1–3, mild pain; levels 4–7, moderate pain; and levels
130 8–10, severe pain. Patients were assisted in their pain assessment where necessary by an
131 independent and calibrated endodontist.

132 The patients were randomly allotted to two local anesthetic groups, Group I – Inferior alveolar
133 nerve block (IANB) plus buccal infiltration and intra-ligamentary injection, and Group II – Only
134 IANB followed by laser irradiation. Randomization was done by an independent endodontist
135 not associated with treatment delivery who picked concealed lots written with group names.

136 Group I

137 An intra-dermal injection of 0.2 mL of the local anesthetic agent to be used was given prior to
138 the IANB in order to rule out any allergy to the anaesthetic agents. Then, 2.5 mL of 2%
139 lignocaine containing 1:80,000 adrenaline (Lignox, Warren Pharmaceuticals, Mumbai, India)
140 was administered as an inferior nerve alveolar nerve block (IANB) plus a 1.5 mL for a buccal
141 infiltration and 0.1 to 0.2 mL as an intra-ligamentary injection using the same anesthetic agent.
142 The intra-ligamentary injections were given at four sites for each tooth on the buccal and

143 lingual sides. The local anesthesia was administered seven minutes prior to commencing the
144 root canal treatment procedure. Cold pulp sensibility tests and percussion evaluations were
145 performed after inquiring about the level of lower lip numbness and before the access cavity
146 opening were commenced. Responses to these tests were recorded. If sufficient anesthesia was
147 not attained, an additional IANB was administered with the same local anesthetic agent used
148 previously.

149 Intra-operative pain was recorded at only one instance with instructions that if pain was
150 felt at any stage of the root canal treatment procedure, the patients were asked to raise their
151 left hand. The intensity of this intra-operative pain was recorded, and patients were re-assessed
152 regarding the need for either supplementary intra-ligamentary or intra-pulp anesthesia, or an
153 additional IANB. If supplementary local anesthetic was required, the same local anaesthetic
154 agent used for the original IANB was employed.

155 Group II

156 Laser application for control of intra-operative pain is a novel technique with no
157 previous investigations to refer to so the pulse rate was assessed as an objective evaluation of
158 the pain control in group II only. Prior to local anesthesia, each patient's basal pulse rate (PR1)
159 was determined using a finger pulse oximeter (Oxywatch, Beijing Choice Electronic Technology
160 Co, Ltd, Beijing, P.R. China). An intra-dermal injection of 0.2 mL of local anesthetic agent was
161 given prior to the inferior alveolar nerve block (IANB) to rule out any allergy to the anesthetic
162 agent. IANB local anesthesia with 2.5 mL of 2% lignocaine containing 1:80,000 epinephrine
163 (Lignox, Warren Pharmaceuticals Pvt Ltd, Mumbai India) was administered seven minutes prior

164 to commencing the root canal treatment procedure. Cold pulp sensibility tests and percussion
165 evaluations were done as in previous group prior to access cavity preparation. Upon access to
166 the pulp, the intensity of intra-operative pain (IP 1) using the VAS score and the pulse rate (PR 2)
167 were determined. Following this, an InGAsP semiconductor diode-based laser (iLase, Biolase,
168 CA, United States) was applied to the pulp both in the pulp chamber and inside the root canals.
169 Activation was with 940 nm wavelength, 1.5 Watts for 60 to 180 seconds in continuous mode
170 for each canal orifice with an E2–20 tip (200 µm diameter and 20 mm length tip). Following
171 laser activation, root canal treatment was commenced with instructions for the patients to
172 raise their left hand if they felt pain – if they did feel unbearable pain, then further intra-
173 operative pain (IP 2) and pulse rate (PR 3) values were recorded. The patients were re-assessed
174 about the need for either supplementary intra-ligamentary or intra-pulp anesthesia, or an
175 additional IANB. If supplemental or additional local anaesthetic was required, the same local
176 anaesthetic agent used for the original IANB was used. Patients experiencing no pain after laser
177 activation were assessed for IP 2 after completion of root canal instrumentation and their pulse
178 rate (PR 3) was also recorded at that stage. Intra-operative pain assessments in both groups
179 were done by an independent, calibrated endodontist.

180 Root canal treatment procedure

181 Working length was determined using a Root ZX Mini Apex Locator (J Morita, Kyoto,
182 Japan) and Flexer files (Mothers Dental International, Adelaide, Australia) were used for root
183 canal preparation according to the manufacturer's instructions using an EndomateTC2 motor
184 (NSK Inc., Tochigi, Japan). Canal lubrication and smear layer management were done with EDTA

185 (10%) and carbamide peroxide (15%) (Endoprep RC, Anabond Stedman Pharmaceuticals,
186 Chennai, India). Sodium hypochlorite (3%) (Septodont Healthcare India Pvt. Ltd, Raigad, India)
187 was used during root canal preparation. In all teeth, the sodium hypochlorite irrigation with
188 upto 5 mL for each canal was used. Initial irrigation of the root canal was done after
189 establishing a glide path upto size 20 or 25K-file (Mani, Co., Tokyo, Japan). Mid-rinse and final
190 irrigation followed the use of the rotary instruments. A total of 7 mL of irrigating solution was
191 used in each canal during the treatment. The irrigation solution was delivered into the root
192 canals using a side-vented 25-gauge needle (RC Twents, Prime Dental Products, Mumbai, India)
193 with a standard syringe. The needle was inserted as far apically into the canal as possible but
194 without any binding within the canal. Gentle force was used on the syringe to deliver the
195 irrigant, and the needle was moved up and down inside the canal to assist with irrigant flow
196 and to ensure no binding of the needle to the canal walls.

197 Upon completion of the root canal preparation to an apical size of either 6% size 20 or
198 25, apical patency was checked using a size 10 K-file (ManiCo., Tokyo, Japan). Root canal filling
199 was done using a greater taper single gutta-percha cone (DiaDentGroup, Seoul, Korea), along
200 with a zinc oxide eugenol-based cement (Prime Dental Products, Thane, India). A post-operative
201 radiograph was taken to ensure the canals were filled to the working length and there was no
202 extrusion of filling material into the periapical tissues. All the patients were prescribed
203 paracetamol 500 mg as analgesics but the patients were advised to only take them in the event
204 of significant pain. The occlusion was not relieved in this study.

205 The post-operative pain levels and the need for analgesics were recorded after 24 and
206 48 hrs by telephoning each patient. The post-operative pain enquiry was made by the same
207 independent endodontist who inquired about intra-operative pain. If analgesics were required,
208 the patients were questioned about which medication they used, the dosage, how often they
209 had taken them and whether they were effective. Furthermore, the trigger mechanism of any
210 post-operative pain in group-II was recorded as spontaneous continuous pain, spontaneous
211 occasional pain, or stimulus-based pain. Trigger mechanism was evaluated for group-II only as
212 the laser usage was attempted for first time and how it matches with other previous
213 investigations.

214 Statistical analysis

215 Statistical analysis was performed using IBM SPSS software version 23 (IBM Corp., Washington,
216 USA). Normality of pre-, intra- (IP – 1 and IP – 2) and post-operative pain scores were checked
217 by the Shapiro–Wilk test. The data were skewed and deviated from normal distribution -
218 therefore, the comparisons of these values were done by non-parametric Wilcoxon signed rank,
219 Mann-Whitney and Kruskal–Wallis tests. Pulse rate increase from PR1 to PR2 and pain
220 experience from IP1 to IP2 were calculated as percentages for group-II, as follows:

$$221 \quad \text{Change in pulse rate } (\Delta \text{ PR}) = \text{PR } 2 - \text{PR } 1$$

$$222 \quad \% \text{ rise in pulse rate} = \Delta \text{ PR} / \text{PR } 1 \times 100$$

$$223 \quad \text{Change in intra-operative pain score } (\Delta \text{ IP}) = \text{IP } 1 - \text{IP } 2$$

$$224 \quad \% \text{ reduction in intra-operative pain score} = \Delta \text{ IP} / \text{IP } 1 \times 100$$

225 The level of significance was set at 5%.

226 **Results**

227 A total of 172 patients enrolled in the study and of these, 98 patients with intra-operative pain
228 following local anesthesia (42 males and 56 females, aged between 13 to 70 years) were
229 included for the statistical analysis. In group I and II, 48 and 50 patients were allotted
230 respectively. The overall mean pre-operative pain score was 6.92 ± 1.78 with no significant
231 difference between the two genders (Mann-Whitney test). Cold test responses after local
232 anesthetic administration did not show a significant association with intra-operative pain
233 (Kruskal-Wallis test). In group II, one male patient aged 16 years requiring root canal treatment
234 for his mandibular first molar did not have the treatment completed in the first appointment
235 because of failure to control his intra-operative pain with laser application and supplemental
236 local anesthesia.

237 **Group I**

238 The mean pre-operative score was 6.62 ± 1.6 . The mean intra-operative pain score was $3.25 \pm$
239 2.20 . No significant difference was observed in intra-operative pain among the two genders
240 (Mann-Whitney test). Three patients (2 males and 1 female) (6.3%) required supplemental
241 injections for control of intra-operative pain. Mean intra-operative pain score for patients
242 requiring supplemental anesthesia was 7.66 ± 2.51 and was significantly different ($P < 0.05$)
243 according to the Mann-Whitney test compared to patients not requiring supplemental
244 injections. None of the patients required additional IANB. One patient did not respond for post-
245 operative evaluation until the completion of the trial. The mean 24 and 48 hrs pain scores were

246 0.89 and 0.31, respectively, with no significant gender difference. Thirteen patients (27.1%)
247 required post-operative analgesics.

248 Group II

249 The mean pre-operative pain score was 7.2 ± 1.91 . The mean IP 1 score was 6.94 ± 2.1 , PR 1 and
250 PR 2 was 82.2 ± 14.3 , 86.3 ± 15.9 respectively with no significant differences for either genders
251 (Mann-Whitney test). The mean intra-operative pain score after laser application (IP 2) was 1.3
252 ± 2.0 and PR 3 was 80.1 ± 12.7 with no significant difference between the two genders (Mann-
253 Whitney test). The Wilcoxon-Signed rank test showed a significant difference ($P = 0.00$)
254 between the intra-operative pain scores before and after laser activation. The basal pulse rate
255 (PR 1) was significantly different ($P = 0.001$) to the rate upon access opening (PR 2) according to
256 the Wilcoxon-Signed rank test. This rise in percentage was 4.96%. Following laser activation, the
257 percentage reduction of intra-operative pain was 81.3% which was significantly different ($P =$
258 0.00) (Wilcoxon-Signed rank test) (Fig.2). The reduction in pulse rate (PR 3) after laser activation
259 from PR 2 was significant ($P = 0.00$) (Wilcoxon-Signed rank test). The pulse rate rise from the
260 basal pulse rate did not have a significant association with intra-operative pain prior to laser
261 application (Kruskal-Wallis test).

262 Four patients (2 males and 2 females) (8%) required supplemental local anesthesia; this
263 was not significantly different from group-I (Mann-Whitney test). All supplemental injections
264 were given intra-pulpally. None of the patients in this group also required an additional IANB.
265 The mean IP 1 and IP 2 scores for the patients requiring supplemental anesthesia were 10 ± 0.0

266 and 6.50 ± 4.12 and these were significantly different from the scores for patients not requiring
267 supplemental injections ($P < 0.05$) in Mann-Whitney test (Table 1).

268 The post-operative pain incidence in this group was 47.9 % (23 patients) with no
269 significant gender difference (Table 2). The post-operative pain incidence had no significant
270 association with pre-operative pain type or the requirement for supplemental anesthesia
271 similar to the earlier group. The mean post-operative pain scores for group-II after 24 and 48
272 hrs were 1.95 ± 2.4 and 0.8 ± 1.56 , respectively. One patient in group-II did not respond and
273 return for post-treatment assessment until completion of this study. Sixteen patients (33.3 %)
274 required post-operative analgesics, and most of these patients required only one dose of
275 analgesic to control the discomfort as in group-I. The trigger mechanism graph (Fig 3) shows the
276 spontaneity nature of the post-operative pain (19 patients (82.61 %)) which made patients
277 report post-treatment discomfort.

278 Inter-group comparison

279 The mean pre-operative pain score was similar for both groups (Mann-Whitney test).
280 Mean intra-operative pain score after laser application (IP 2) was significantly ($P < 0.05$) less
281 compared to group-I intra-operative pain score (Mann-Whitney test) (Table 3). Post-operative
282 pain at 24-hrs scores for group-II patients were significantly ($P < 0.05$) higher compared to
283 group-I (Mann-Whitney test)(Fig 4).

284

285 **Discussion**

286 The primary aim of this study was to evaluate the efficacy of laser activation in reducing the
287 intra-operative pain intensity and thereby indirectly reducing the need for supplemental
288 anaesthesia. Only mandibular molar teeth exhibiting acute irreversible pulpitis were
289 considered, as these teeth are the most difficult teeth to anesthetize with a single IANB
290 injection (3). The result of the present study highlights the efficacy of a laser to reduce both the
291 intra-operative pain intensity and the need for supplemental anesthesia. A previous study from
292 the authors' department (3), using a similar study design and a single 2% lignocaine IANB
293 injection indicated that the mean intra-operative pain score for patients with intra-operative
294 pain was 4.6 ± 2.4 . Furthermore, the requirement for supplemental anesthesia was 23.8 % (15
295 patients), which was far greater than the group-II of the present study (IP2 - 1.3 ± 2.0 ;
296 supplemental injection requirement - 4 (8%) patients). Additional IANB was required in 9 (14.3
297 %) patients in the above cited study (3) compared to none of the patients requiring this
298 intervention in the present study. The mean intra-operative pain score (IP 1) in group-II prior to
299 laser application (6.94 ± 2.1) is higher than the earlier mentioned study and this may be due to
300 the pre-operative oral ketorolac tromethamine administration in that study (3). Present data
301 supports the efficacy of a laser in controlling even the elevated intra-operative pain intensity
302 without pharmacological aid despite the higher pre- and intra-operative pain intensity.

303 In this study, patients administered with additional buccal nerve infiltration and intra-
304 ligamentary injections coupled with the IANB injection had a mean intra-operative pain score of
305 3.25 ± 2.20 which was significantly higher than the laser group (IP 2) despite the elevated pre-

306 operative pain levels observed in the laser group. Supplemental injections were required in 4
307 patients (8%) in the laser group-II which was similar to group-I. These numbers indicate the
308 efficacy of laser activation in controlling the intra-operative pain without the need for
309 additional or supplemental injections.

310 A 10-point VAS was employed as our previous studies with irreversible pulpitis (3, 5, 10,
311 11) followed this similar protocol, which allowed us to have standardised metrics for efficient
312 patient communication. Additionally, most of the patients encountered in the authors'
313 department have limited education which would greatly impair their interpretation of a pain
314 scale with more than 10-points. Telephonic recording of post-operative pain assessment was
315 adopted as post-treatment compliance of patients for recall visits is very poor once the pre-
316 operative symptoms subside.

317 Pulse rate and intra-operative pain changes were measured to provide an accurate and
318 informed metric tool relative to the expected change in these values, while performing the
319 treatment. The pulse rate increase from the basal level (IP 1) to just before laser application (IP
320 2) was 4.96 % and this was independent of the intra-operative pain intensity. This implies that
321 the pulse rate change was not a reliable tool for evaluating intra-operative pain experience.
322 Reduction percentage of intra-operative pain intensity after laser activation was 81.26 %, which
323 provides a valuable source of information in patient management.

324 Laser intensity of 1.5 watts in continuous wave mode for 60 to 180 secs was adopted in
325 the present study based on previous research (6, 7). In that research 1.5 watts of laser energy
326 for 1 min produced a reversible intra-dental nerve conduction block without contacting the

327 pulp tissue (6). They also indicated that total laser energy induced analgesia acts via
328 suppression of intra-dental nerve responses to mechanical and electrical stimulation (6).

329 The present study varies from that of Chan *et al.* (6) in that the laser energy here was
330 used to anesthetize irreversibly inflamed pulps and also with direct contact on the pulp tissue
331 that required an extended length of time of laser application. A wide range in time of laser
332 application was adopted in this study due to the lack of previous scientific evidence to know the
333 precise time that would be required. Diode laser application has been long associated with
334 painless treatment in minimally invasive soft tissue surgical procedures with minimum
335 collateral damage to either the soft tissue or the bone in different modes of direct contact
336 (12).The direct contact mode of diode lasers on soft tissues has been shown to produce tissue
337 vaporization and thermal necrosis.Therefore,the reduction in intra-operative pain observed in
338 the present study could not be linked to suppression of intra-dental nerve conduction block
339 (12).

340 Intra-pulp anesthetic injections achieve their anesthetic effect due to the physical
341 mechanism of back pressure, irrespective of the type of anesthetic agent, rather than by
342 pharmacological means (13). Laser assisted intra-pulp anesthesia in the present study could
343 also be due to the physical effects of tissue vaporization and thermal necrosis instead of an
344 alteration of any specific neurological conduction mechanism. No direct comparison of the
345 present results with other studies could be made as a literature search failed to identify any
346 similar attempts to assess lasers for irreversible pulpitis. Earlier studies on laser application for
347 the management of irreversible pulpitis to control intra- and post-operative pain have been

348 done using laser irradiation on the external tooth surface, either before or after root canal
349 treatment, but not directly on the pulp during the treatment procedure (7, 14, 15).

350 Supplemental anesthesia was required for 4 patients in laser group who had a mean
351 intra-operative pain score of 10 (severe) prior to laser activation and 6.5 (moderate) after laser
352 activation where the reduction achieved was not close to the reduction achieved for other
353 patients. One reason for this occurrence was that the length of the laser fiber tip was only 20
354 mm, which needed to be bent to enter the canal orifices. The cases requiring supplemental
355 anesthesia had root canal lengths of more than 22 mm which prevented the fiber tip from
356 directly contacting the entire pulpto achieve the anesthetic effect as explained previously. In
357 the future, laser fiber tip manufacturers should customize their tips with different lengths for
358 use in anesthetizing the pulp within the root canals.This further supports the earlier
359 explanation of a physical mechanism behind the laser assisted pulp anesthesia.

360 In this investigation, intra- and post-operative pain was assessed by an independent
361 endodontist whereas the laser activation and root canal treatment was done by the same
362 operator. This was the case as there were no precursor studies to refer to in order to know the
363 intensity, time of duration or mode of laser irradiation for achieving the pulp anesthesia. Hence,
364 it was preferred that the same clinician operate the laser to allow for real time monitoring of
365 patient discomfort during root canal treatment and altering of the above mentioned
366 parameters as and when required for each case. The present study also did not allow for a
367 direct placebo or sham laser application since the patients had acute irreversible pulpitis and an
368 earlier investigation (3) with similar conditions showed a single 2.5 ml of lignocaine IANB was

369 not sufficient to achieve complete pulp anesthesia to allow completion of the root canal
370 treatment. As a consequence, a placebo or sham laser group would have meant subjecting the
371 patients to unnecessary discomfort and also might have led to abandoning the root canal
372 treatment in the first appointment. This statement can be appreciated by observing that the
373 mean intra- (IP 1) and pre-operative pain values in group-II were almost identical.

374 The secondary objective of the study was to investigate post-operative pain following
375 laser application to help understand the adverse effects posed by this technique. Post-
376 operative pain scores at 24-hrs for laser group were significantly higher compared to group-I.
377 The post-operative pain incidence in the laser group was 47.9%, which was higher than the
378 earlier study (3) of 16.7%. However, as discussed above, this earlier study had pre-operative
379 oral analgesic administration to control post-treatment discomfort. However; the 24- and 48-
380 hrs post-operative pain intensity was similar to the earlier study (3). Another study (11) from
381 the authors' team that focused on anesthetizing teeth with acute irreversible pulpitis and
382 research published by Arias *et al.* 2013 (16) without pre-treatment analgesic administration,
383 have shown comparable post-operative pain incidences to the present study. Likewise, the
384 post-treatment pain intensity was also similar. Laser irradiation inside the root canal system has
385 been associated with minimal potential to cause damage to periodontal tissues or bone (17).
386 This implies that the post-treatment data with laser application did not cause any adverse post-
387 treatment effects when used to attain pulp anesthesia despite the significantly higher post-
388 operative pain intensity associated with the laser group. Arias *et al.* 2013 (16) reported that
389 spontaneously triggered post-operative pain was the most commonly reported type of
390 discomfort, which is in agreement with the current results. Occlusal contact was not relieved in

391 the present study in order to stimulate the worst-case scenario for evaluating post-operative
392 pain as the presence of occlusal contact has been associated with increased post-treatment
393 discomfort (10, 16). Despite this, the post-operative pain occurrence was similar to other
394 reports on pain following root canal treatment (16), thereby confirming the efficacy of laser
395 application.

396 In conclusion, laser activation for the control of intra-operative pain reduced the
397 requirement for supplemental pharmacological support. Further investigations in the authors'
398 department with a larger sample size for evaluating the efficacy of pre-operative oral analgesic
399 intake to control the post-operative pain in laser assisted pulp anesthesia for mandibular molar
400 teeth with acute irreversible pulpitis is currently progressing.

401 **Conclusions**

402 Laser irradiation applied directly on irreversibly inflamed pulp tissue for control of intra-
403 operative pain was effective, thereby negating the need for additional local anesthetics. Post-
404 operative pain evaluation showed laser activation was safe and did not cause any adverse
405 discomfort.

406

407

408 **Author Contributions**

409 Conceptualization, Anand Sherwood; Formal analysis, Anand Sherwood; Investigation, Subashri
410 V and Nivetha V; Methodology, Subashri V, Anand Sherwood, Paul Abbott and James Gutmann;
411 Project administration, Anand Sherwood; Supervision, Omar Farooq and Aarthi MV; Writing –
412 original draft, Anand Sherwood; Writing – review & editing, Paul Abbott and James Gutmann.

413

414 **Compliance with Ethical Standards**

415

416 **Conflict of Interest:** All authors declare that they have no conflict of interest.

417

418 **Funding:** The work received no external/internal funding of any nature.

419

420 **Ethical approval:** All procedures performed in studies involving human participants were in
421 accordance with the ethical standards of the institutional and/or national research committee
422 and with the 1964 Helsinki declaration and its later amendments or comparable ethical
423 standards."

424

425 **Informed consent:** Informed consent was obtained from all individual participants included in
426 the study.

427 **References**

- 428 1. Rosenberg PA. Clinical strategies for managing endodontic pain. *Endod Topics* 2002; 3:
429 78-92.
- 430 2. Abbott PV, Parirokh M. Strategies for managing pain during endodontic treatment. *Aust*
431 *Endod J* 2018; 44: 99-113.
- 432 3. Nivedha V, Sherwood AI, Abbott PV, et al. Pre-operative ketorolac efficacy with different
433 anesthetics, irrigants during single visit root canal treatment of mandibular molars with
434 acute irreversible pulpitis. *Aust Endod J* 2020; 46: 343-350.
- 435 4. Nagendrababu V, Pulikkotil SJ, Veettil SK, et al. Effect of nonsteroidal anti-inflammatory
436 drug as an oral premedication on the anesthetic success of inferior alveolar nerve block
437 in treatment of irreversible pulpitis: A systematic review with meta-analysis and trial
438 sequential analysis. *J Endod* 2018; 44: 914-922.
- 439 5. Nivedha V, Sherwood AI, Abbott PV, et al. The effect of pre-operative ketorolac
440 tromethamine administration during single visit root canal treatment of mandibular
441 molars with acute irreversible pulpitis on intra-/post-operative pain. *Sci Arch Dent Sci*
442 2021; 4(3): 3-14.
- 443 6. Chan A, Armati P, Moorthy AP. Pulsed Nd: YAG laser induces pulpal analgesia: a
444 randomized clinical trial. *J Dent Res* 2012; 91(7Suppl): 79S-84S.

- 445 7. Ghabraei S, Chiniforush N, Bolhari B, et al. The effect of photobiomodulation on the
446 depth of anesthesia during endodontic treatment of teeth with symptomatic irreversible
447 pulpitis (Double blind randomized clinical Trial). *J Lasers Med Sci* 2018; 9: 11-14.
- 448 8. Abbott PV. Examination and diagnosis of the pulp, root canal periapical/periradicular
449 conditions. In: Rotstein I, Ingle JI(eds) *Ingle's Endodontics*, 7th ed. PMPHUSA, 2019; NC,
450 US. pp. 215 – 225.
- 451 9. Nagendrababu V, Duncan HF, Bjørndal L, et al. PRIRATE 2020 guidelines for reporting
452 randomized trials in Endodontics: explanation and elaboration. *Int Endod J* 2020; 53:
453 774-803
- 454 10. Bamini L, Sherwood A, Arias A, et al. Influence of tooth factors and procedural errors on
455 the incidence and severity of post-endodontic pain: A prospective clinical study. *Dent J*
456 (Basel) 2020; 8: 73.
- 457 11. Evangelin J, Sherwood IA, Abbott PV, et al. Influence of different irrigants on substance P
458 and IL-8 expression for single visit root canal treatment in acute irreversible pulpitis.
459 *Aust Endod J* 2020; 46: 17-25.
- 460 12. Goharkhay K, Moritz A, Wilder-Smith P, et al. Effects on oral soft tissue produced by a
461 diode laser in vitro. *LasersSurgMed* 1999; 25:401-406.
- 462 13. Balasubramanian SK, Natanasabapathy V, Vinayachandran D. Clinical considerations of
463 intrapulpal anesthesia in pediatric dentistry. *Anesth Essays Res* 2017;11: 1-2.

464 14. Ramalho KM, de Souza LM, Tortamano IP et al. A randomized placebo-blind study of the
465 effect of low power laser on pain caused by irreversible pulpitis. *LasersMed Sci* 2016; 31:
466 1899-1905.

467 15. Naseri M, Asnaashari M, Moghaddas E, Vatankhah MR. Effect of low-level laser therapy
468 with different locations of irradiation on postoperative endodontic pain in patients with
469 symptomatic irreversible pulpitis: A double-blind randomized controlled trial. *JLasers*
470 *Med Sci* 2020; 11: 249-254.

471 16. Arias A, de la Macorra JC, Hidalgo JJ, Azabal M. Predictive models of pain following root
472 canal treatment: a prospective clinical study. *Int Endod J* 2013; 46: 784-793.

473 17. Strakas D, Franzen R, Kallis A. *et al.* A comparative study of temperature elevation on
474 human teeth root surfaces during Nd:YAG laser irradiation in root canals. *Lasers Med*
475 *Sci* 2013; 28: 1441–1444.

476

Table 1. Intra-operative scores before and after laser application in patients requiring and not requiring supplemental injection in group II.

		Mean intra-operative pain prior to laser activation \pm Standard deviation	Mean intra-operative pain experience after laser activation \pm Standard deviation	Number of patients
Supplemental local anesthetic requirement	Yes	10.00 \pm 0.00	6.50 \pm 4.12	4
	No	6.67 \pm 1.97	.8478	46
Total		6.94 \pm 2.10	1.30 \pm 2.04	50

Table 2. Post-operative pain incidence among the two genders in group II

	Post-operative pain		Total
	Yes	No	
Male	9 (42.9%)	12 (57.1%)	21
Female	14 (51.9%)	13 (48.1%)	27
Total	23 (47.9%)	25 (52.1%)	48

Table 3. Mean intra-operative pain scores in group I and group II (IP 2*).

		Mean \pm standard deviation	Number of patients
Local anesthesia groups	IANB ^o plus buccal infiltration and intra-ligamentary injections (Group I)	3.25 \pm 2.20	48
	IANB ^o followed by laser irradiation (Group II)	1.30 \pm 2.04	50
	Total	2.25 \pm 2.33	98

* - IP 2 is intra-operative pain score after laser irradiation.

^o - Inferior alveolar nerve block

Legends for figures

Figure 1. PRIRATE 2020 (9) flowchart illustrating the flow of participants.

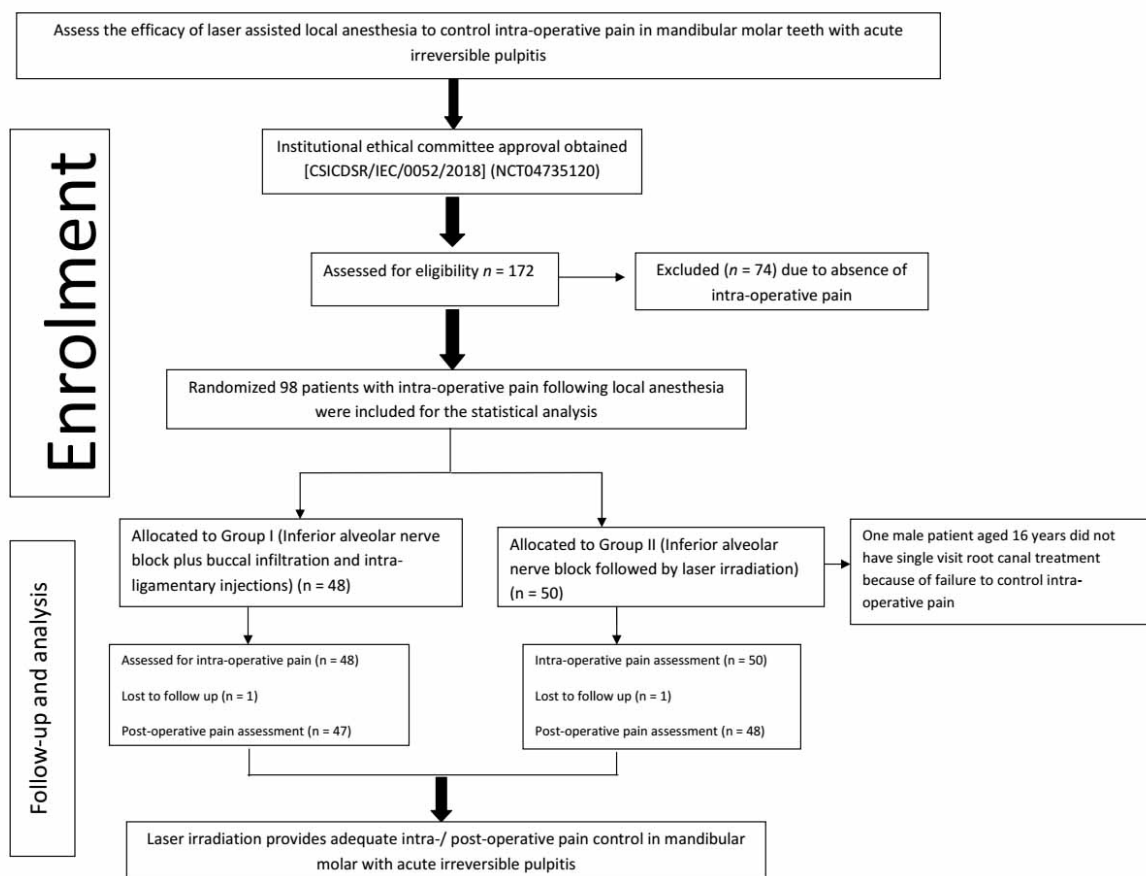


Figure 2. Mean intra-operative pain scores with error plots prior to and after laser irradiation in group-II.

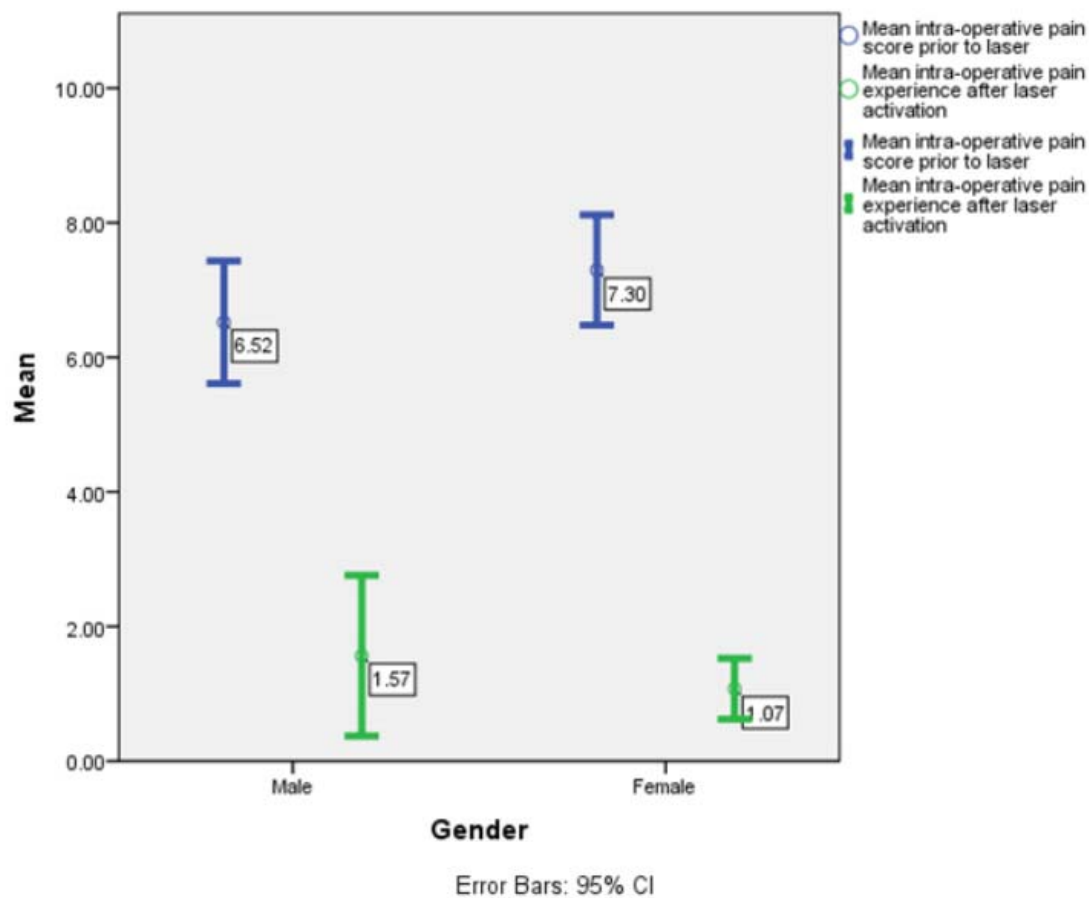


Figure 3. Post-operative pain triggers in patients with post-treatment discomfort in group-II.

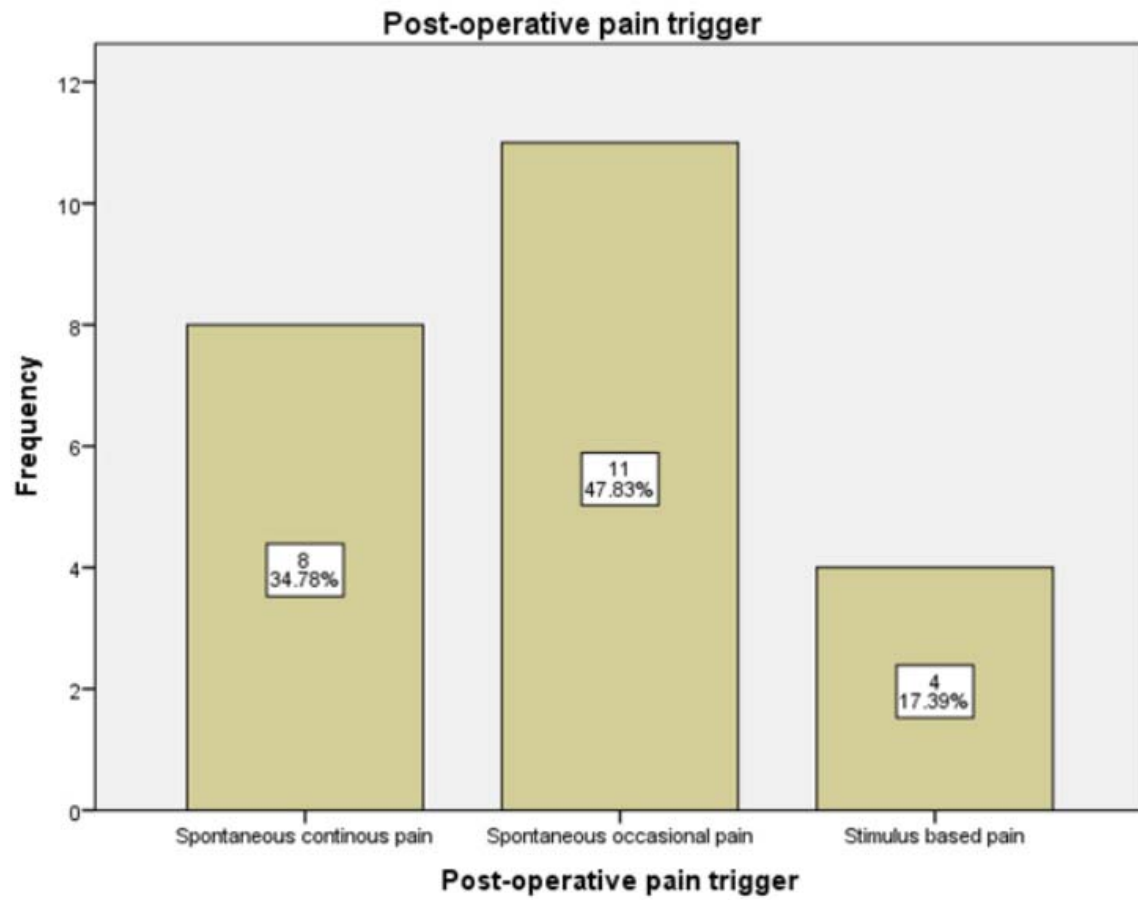


Figure 4. Post-operative pain score at 24 and 48 hrs for group I and II with error plots.

