

1 **ADVANCED AUTOLOGOUS LOWER DERMAL SLING TECHNIQUE FOR**
2 **IMMEDIATE BREAST RECONSTRUCTION SURGERY IN SMALL AND NON-**
3 **PTOTIC BREASTS**

4
5 **AUTHOR NAMES AND AFFILIATIONS**

6 Chaitanyanand B. Koppiker M.D.^{1*}, Aijaz Ul Noor Ph.D.¹, Santosh Dixit Ph.D.¹, Laleh
7 Busheri¹, Gautam Sharan M.D.², Upendra Dhar M.D.¹, Hari Kiran Allampati M.D.³ Smeeta
8 Nare¹, Nutan Gangurde¹.

9 ¹Orchids Breast Health Clinic, Prashanti Cancer Care Mission, 1&2, Kapilavastu, Senapati Bapat
10 Road, Pune, Maharashtra, Post code :411016, India.

11 ²Department of Radiation Oncology, Inlaks and Budhrani Hospital, Pune-411001, India,

12 ³Ruby Hall Clinic, Pune, Maharashtra, India, 411040

13
14 Email:

15 aeijazul@gmail.com; lalehbusheri@gmail.com; sgdixit@gmail.com;

16 dr.gautamsharan@gmail.com; upendradhar@hotmail.com; dr.harikiran89@gmail.com;

17 smeetanare@hotmail.com, dr.nutang@gmail.com

18

19

20 **The Article Type:** Original Article (Clinical Original)

21

22 ***CORRESPONDING AUTHOR**

23 Chaitanyanand B. Koppiker M.D.

24 Medical Director, Orchids Breast Health Clinic,

25 Prashanti Cancer Care Mission,

26 1-2, Kapilvastu, Senapati Bapat Road,

27 Pune, Maharashtra, Post code: 411016, India.

28 Phone: +91 98226 74040 (M)

29 Email : obs.koppiker@gmail.com

30 **ABSTRACT**

31 **Background:** Breast reconstruction with an autologous lower dermal sling (ALDS) is an
32 established one-stage procedure in patients with moderate to large ptotic breasts. However, this
33 technique is difficult to perform in small and non/minimally ptotic breasts. We describe our
34 experiences from a single institution about a novel Advanced Autologous Lower Dermal Sling
35 (A-ALDS) technique for reconstruction in small breasts.

36 **Methods:** We performed one stage nipple/skin sparing mastectomies in 61 patients with
37 immediate reconstruction either by conventional immediate breast reconstruction surgery or
38 A-ALDS technique.

39 **Results:** Mean age of study patients was 46.9 years. We observed significantly better cosmetic
40 score and lower immediate complication rate *vis-a-vis* skin necrosis, implant loss with the A-
41 ALDS technique (i.e., nil versus 3 in Conventional Immediate Breast Reconstruction Surgery -
42 IBRS). 40 patients completed 12 months follow-up. The PROMs- Patient Reported Outcomes
43 Measures (Breast-Q) revealed good to excellent scores for satisfaction with breast, cosmetic
44 outcome and psychosocial well-being in patients operated with both these techniques. However,
45 sexual well-being was significantly better in the A-ALDS group.

46 **Conclusion:** The A-ALDS is a novel, cost-effective and safe technique for immediate one stage
47 implant-based reconstruction for small breasts. It provides a dermal barrier flap and hence,
48 ensures less complications, excellent cosmetic results and patient satisfaction.

49

50

51

52 **Keywords:** Breast Cancer; Small Breast; Advanced-Autologous Lower Dermal

53 Sling; Immediate Breast Reconstruction Surgery; Patient Reported Outcomes

54 Measures.

55 **Abbreviations (According to Appearance in the Text)**

56 Autologous Lower Dermal Sling: ALDS

57 Immediate Breast Reconstruction Surgery: IBRS

58 Breast Cancer: BC

59 Infra-mammary Fold: IMF

60 Acellular Dermal Matrices: ADMs

61 Advanced-Autologous Lower Dermal Sling: A-ALDS

62 Patient Reported Outcome Measures: PROMs

63

64

65

66

67

68

69

70

71

72

73

74 INTRODUCTION

75 The well-established autologous lower dermal sling (ALDS) is an ideal technique for implant-
76 based immediate breast reconstruction surgery (IBRS) in breast cancer (BC) patients with
77 moderate-to-large sized breasts with significant ptosis (Grade 2+) in which the distance from the
78 nipple to the infra-mammary fold (IMF) may be significantly greater than 5 -7 cm. The ALDS
79 provides robust stability to the implant ensuring excellent contouring, projection and fullness of
80 the lower pole of the reconstructed breast with correction of ptosis. This approach reduces the
81 risk of a high riding implant, provides excellent cosmetic results and ensures good symmetry.
82 Therefore, ALDS is now considered as a safe and cost-effective single stage reconstructive
83 technique especially in moderate-to-large ptotic breasts [1-3].

84 However, implant-based breast reconstruction for small and non-ptotic breasts is a surgical
85 challenge due to non-availability of excess lower pole length that aids in the creation of an
86 appropriately sized dermal sling. Conventionally, breast reconstruction in such scenarios is
87 performed by placing the implant either in a complete or partial sub-muscular pocket. These
88 techniques have been shown to result in sub-optimal cosmetic outcomes that were attributed to
89 poor expansion and tightness of the inferior pole [4]. As a result, it is now a common practice
90 employed by several oncoplastic surgeons to use acellular dermal matrices (ADM)s that function
91 as a sling to cover the implant inferiorly and provide robust support to the inferior pole [4].

92 In developing countries such as in India, ADMs are not available and their high cost can prohibit
93 its use in breast reconstruction. Hence, in such low-resource settings, we have initially
94 approached reconstruction in minimally ptotic or non-ptotic small breasts by placing the implant
95 in a sub-muscular pocket that is formed by pectoralis major muscle above, the fascia or
96 superficial fibers of the serratus anterior muscle laterally and the fascia over rectus abdominis

97 muscle inferiorly. Later, we developed a technique of Advanced-Autologous Lower Dermal
98 Sling (A-ALDS) to provide a double layer of vascularized tissue cover over the implant
99 inferiorly. It has been previously reported in the ALDS procedure, that dermal sling provides an
100 advantage over ADMs as it acts as a vascularized flap eliminating the risk of implant exposure
101 even if superficial skin necrosis does occur [1-2]. Therefore, the ALDS technique has been
102 utilized routinely to improve breast reconstruction outcomes. Similarly, our modified A-ALDS
103 technique was able to maintain the natural breast shape, projection and symmetrization of the
104 reconstruction with respect to the opposite breast thereby, obviating the need for contralateral
105 surgery.

106 In this study, we report the application of this novel A-ALDS technique for reconstruction in
107 patients with small breasts. Furthermore, we present the post-surgical outcomes in our study
108 patients who have undergone either A-ALDS technique or conventional IBRS.

109

110 We present the following article/case in accordance with the STROBE reporting checklist.

111

112

113

114

115

116

117

118

119

120 MATERIAL AND METHODS

121 Study Design

122 This is a longitudinal cohort study involving a retrospective analysis of prospective data from a
123 single institution. This study was approved by an independent ethics committee associated with
124 the institution. Patients were considered eligible for analysis if they underwent unilateral and
125 bilateral mastectomies with implant-based IBRS (Immediate Breast Reconstruction Surgery) and
126 fulfilled the criteria laid down for a small breast. Small breast for the purpose of this study was
127 defined as the one with a cup size of B or smaller and / or mastectomy weight of less than 350gm
128 with either no or normal ptosis.

129 Written informed consent was obtained from all patients for collection of study-relevant medical
130 data associated with disease management and routine follow-up visits. The study recruitment
131 period was defined as the day informed consent was obtained from the patient till one year of
132 follow up. Study sample size represented all eligible cases during the study period from year
133 2016 until 2018. Data collection included demography, medical history, clinicopathological
134 characteristics, surgical notes, post-surgery evaluations and follow-up details for patient reported
135 outcome measures (PROMs) and aesthetic scores. To minimise bias in data collection, Standard
136 Operating Procedures (SOPs) were implemented by well-trained researchers.

137 During the study period, a total of 61 BC patients with small breasts underwent implant-based
138 IBRS at our breast unit. 3 patients underwent bilateral mastectomies. Only those patients with
139 small breasts who were recommended for mastectomy and opted for IBRS were included in the
140 study. The selection criteria for A-ALDS (Advanced-Autologous Lower Dermal Sling) or
141 conventional IBRS as an appropriate surgical technique were as follows: (a) Conventional IBRS
142 was performed when the tumor was located in the upper outer quadrant and lower quadrant close

143 to the skin, warranting skin removal with the tumor. (b) The A-ALDS procedure for IBRS was
144 applied to all other patients including those that had the presence of tumor in the lower pole but
145 at an optimal distance from skin. In such situations, the skin could be preserved to create the
146 desired dermal sling. The surgical margins especially – the anterior margins were evaluated by
147 frozen sections in selected cases and re-ascertained on the paraffin sections in all cases.

148 Out of these 61 patients, 40 completed one-year post-surgery follow-up (22 with conventional
149 IBRS and 18 with A-ALDS) and were analyzed for surgical outcomes and PROMs. These
150 patients underwent chemotherapy and/or radiation therapy treatment according to NCCN
151 guidelines under the supervision of a multidisciplinary clinical team.

152 **Conventional IBRS Technique**

153 Conventional IBRS (i.e. one stage sub muscular implant reconstruction) involves placement of
154 the breast implant in a sub muscular pocket. The mastectomy is performed preserving the skin
155 along with nipple areola complex in which the lower extent of mastectomy is the inframammary
156 fold (IMF). The conventional IBRS technique involves splitting pectoralis major muscle in the
157 middle along its fibers. This is in contrast to the usual practice of most plastic surgeons that
158 involves lifting the pectoralis major starting from its lateral edge and then dissecting beneath it to
159 create a sub-muscular pocket. Laterally, the dissection is carried under the fascia/superficial
160 fibers of serratus anterior, hence providing a continuous pocket laterally. The dissection then
161 continues under the fascia of lower thoracic and upper abdominal wall approximately 2 cm
162 below IMF. This procedure ensures the provision of an appropriate cover to the implant to
163 prevent high riding and imparts fullness to the lower quadrant of the reconstructed breast. In this
164 way, the implant is partially covered by muscle and partially by fascia. We have adopted a single
165 stage procedure by inserting a dual lumen expendable implant so as to create lower pole fullness.

166 **Advanced-Autologous Lower Dermal Sling (A-ALDS) Technique**

167 The A-ALDS procedure is described for implant-based reconstruction in patients with small non-
168 ptotic or minimally ptotic breasts where the distance of the lower segment of the breast is
169 inadequate to perform the regular ALDS technique.

170 The A-ALDS technique begins by first marking out the usual pre-operative landmarks on the
171 breast with appropriate measurements. The IMF is marked and the IMF-to-nipple distance is
172 ascertained (typically small; 5 to 7 cm). The desired dermal sling (breadth of 3 to 4 cm) is
173 marked out in a semi-circular fashion above the IMF on the lower pole of the breast. This area is
174 de-epithelialized to constitute the lower dermal sling. The mastectomy proceeds from above the
175 lower dermal sling and the flaps are raised in the appropriate subcutaneous plane maintaining the
176 sub-dermal blood supply of the flaps. At the areola, the plane becomes more superficial and then
177 dips into the nipple to core out the ducts as recommended [5]. The lower dermal sling is
178 dissected off the lower breast tissue in the correct plane up to the IMF. Then, mastectomy is
179 performed and the nipple is cored out. During this procedure, the lower dermal sling is then
180 advanced by mobilizing the skin and subcutaneous tissue above the fascia of the lower thoracic
181 and upper abdomen by 3 to 4 cm thereby, advancing the dermal sling to cover the implant. We
182 recommend that during this mobilization the perforators of medial and lateral thoracic region
183 should be maintained scrupulously as they contribute significantly to the vascularity of A-ALDS
184 flap. The advanced skin mobilized (from lower thoracic and upper abdomen) equals the breadth
185 of the dermal sling (i.e. 3 to 4 cm), maintains the required ideal length of the lower segment and
186 helps to symmetrize the reconstructed breast to the contralateral side. Finally, the IMF is
187 recreated by anchoring the mobilized skin (from the lower thoracic and upper abdominal wall)
188 with 3 sub-cutaneous sutures to the chest wall at the level of the original IMF.

189 After this step, a breast pocket is created by lifting up the pectoralis major muscle from the chest
190 wall and cutting its attachments inferiorly. The pocket is continued under the fascia and
191 superficial fibers of the serratus anterior muscles without detaching the pectoralis major muscle
192 at its lateral attachment providing a continuous uninterrupted pocket laterally. Medially, the
193 dissection is carried under the pectoralis major muscle up-to the medial perforators without
194 damaging them. An appropriate size and type of dual-lumen anatomical implant is placed in the
195 resultant submusculardermal pocket. To avoid excess tension inside the submuscular pocket, the
196 volume of the pocket is kept proportionate to the skin envelope and to implant dimension.
197 In the final surgical step, the inferior border of pectoralis major muscle and superficial fibers of
198 serratus anterior or its fascia muscle is sutured to the de-epithelialized A-ALDS generated
199 earlier. The suction drains are placed under skin flaps of the patient and the skin flap is sutured
200 down at the infra-mammary crease (Figure 1A a-e) (Online Resource 1-3).

201 **Study Assessments**

202 Surgical outcomes were assessed by a team of onco-surgeons for post-surgery outcomes. Early
203 complications such as hematoma, seroma, wound dehiscence and wound infection were
204 recorded. Complications were classified as ‘major’ when they required surgical intervention and
205 ‘minor’ when they were managed conservatively. Major immediate complications include
206 implant loss and skin dehiscence that required re-suturing. Minor complications include minor
207 skin/wound dehiscence, minor flap necrosis healing with secondary intention and
208 epidermolysis.

209 The late complications such as capsular contracture and late infections were also noted. The
210 capsular contracture was assessed using the modified Baker classification system [6]. While,
211 Baker 3 and 4 observations were considered as major complications, Baker 2 observations were

212 considered as minor. We also noted the time between completion of the surgery and start of the
213 adjuvant therapy to ascertain any delays in the adjuvant therapy.

214 The Patient reported Outcome Measures (PROMs) were used to evaluate patient satisfaction and
215 quality of life after IBRS. To assess PROMs, a standardized Breast-Q questionnaire was utilized.
216 The Breast-Q reconstruction module was divided into multiple independent scales. Higher scores
217 indicate greater patient satisfaction and functionality [7, 8]. PROMs patient interview was
218 conducted by a well-trained interviewer after obtaining informed consent.

219 Aesthetic outcomes were measured with 5 different variables that included breast reconstruction
220 volume, contour, implant placement, scarring, and appearance of inframammary fold [9]. Post-
221 operative cosmetic assessment was performed by the clinical team during visual inspection of the
222 patient in the sitting position. Photographic data were scored by 3 independent clinical observers
223 using the 3-point scale (Online Resource 4). Two of them were not directly involved with direct
224 patient care. Aesthetic scores of 5 different variables were pooled and analyzed for statistical
225 significance.

226 **Statistical Analysis**

227 Statistical analysis was performed using Student's *t*-test and a p-value of <0.05 was considered
228 significant.

229 **RESULTS**

230 **Representative Case Study**

231 A patient between 20-40 years age group with B-cup breasts and no ptosis presented with a
232 lump in the left breast. On radiological investigations, it showed multicentric tumors in the
233 upper outer quadrant and diffuse microcalcifications. She underwent nipple-areola-sparing
234 mastectomy followed by IBRS with A-ALDS technique. Post-surgery histo-pathological

235 examination revealed that the sentinel lymph nodes were free of tumor (0/3) and with clear
236 tumor margins. The intraoperative, pre- and post-surgery images for this patient are depicted in
237 Figure 1A, 1B, 1C and 1D respectively.

238

239 **Study Cohort Demography**

240 40 patients with small breasts who completed 12 months post-surgery follow-up were included
241 in the study. Of these, 22 patients underwent implant-based conventional IBRS and 18 patients
242 underwent surgeries with the A-ALDS technique. Out of 40, data of 39 patients was available.
243 Demographic distribution of patients and clinico-pathological characteristics are summarized
244 in Figure 2 and Table 1. None of the patients in our study cohort experienced any delays in
245 their adjuvant therapies.

246

247

Table 1: Demography and Clinico-Pathological Profile of Study Participants

Variables	Data Sources	Class intervals	Conventional IBRS n = 22* Number, (%)	IBRS with A-ALDS n = 18 Number, (%)
Age (Years)	Scheduled Interview (Post informed consent)	<=35	4 (18.1)	3 (16.7)
		36-50	7 (31.8)	9 (44.4)
		>=51	10 (45.4)	6 (33.3)
		Mean Age	45.6	48.2
Tumor Pathology	Clinico-Pathological Report (Histo-pathology)	IDC	16 (72.7)	9 (50.0)
		DCIS	2 (9.1)	2 (11.1)
		IDC + DCIS	2 (9.1)	7 (38.8)
		Others	1 (4.5)	-
ER	Clinico-Pathological Report (IHC)	Positive	18 (81.8)	15 (83.3)
PR	Clinico-Pathological Report (Histo-pathology)	Positive	6 (27.3)	13 (72.2)
Her2	Clinico-Pathological Report (Histo-pathology)	Positive	3 (13.6)	2 (11.1)

248

TNBC	Clinico-Pathological Report (Histo-pathology)	-----	2 (9.1)	2 (11.1)
Grade	Clinico-Pathological Report (Histo-pathology)	I	2 (9.1)	-
	Clinico-Pathological Report (Histo-pathology)	II	15 (68.2)	15 (83.3)
	Clinico-Pathological Report (Histo-pathology)	III	4 (18.2)	3 (16.7)
Stage	Pathology Lab Report (according to AJCC staging guidelines 7 th ed)	I	9 (40.9)	4 (22.2)
	Pathology Lab Report and according to AJCC staging guidelines 7 th ed	II	4 (18.2)	10 (55.5)
	Pathology Lab Report and according to AJCC staging guidelines 7 th ed	III	8 (36.4)	4 (22.2)
Neo – Adjuvant Therapy	Medical Oncologist consultation and records		4 (18.2)	4 (22.2)
Adjuvant Therapy	Medical Oncologist consultation and records		21 (95.5)	15 (83.3)
Radiation Therapy	Radiation Oncologist consultation and records		12 (54.5)	8 (44.4)

249 * Data available for 21 patients only.

250 **PROMs and Aesthetic Score**

251 PROMs data was collected from the study participants at 12 months post-surgery with the
252 Breast-Q questionnaire. Out of 40 study participants, 36 (90%) responded to the questionnaire.
253 PROMs data indicated that all study participants irrespective of the type of reconstruction,
254 reported good-to-excellent satisfaction for the breast cosmetic outcomes and psychosocial
255 well-being.

256 However, we found that the Breast-Q parameters scored higher for A-ALDS patients as
257 compared to conventional IBRS.

258 The sexual well-being scores were significantly higher for the A-ALDS patients (62.8 ± 21.9
259 versus 52.2 ± 28.4) in comparison to conventional IBRS procedure ($p = 0.0139$). In addition,
260 A-ALDS group scored significantly higher for aesthetic score over conventional IBRS group
261 (i.e., 6.7 ± 1.3 versus 4.6 ± 2.3 ; $p=0.0009$) (Table 2).

262

263

264 **Table 2: Inter-Group Comparison of PROMs (Conventional-IBRS versus A -ALDS) and**
 265 **Aesthetic Score**

S. No.	Variables	Conventional-IBRS	IBRS with A - ALDS	p-value	
1.	Breast-Q	Satisfaction with Breast	69.2 ± 22.6	69.4 ± 14.3	0.7271
2.		Satisfaction with Outcome	80.0 ± 24.2	86.9 ± 13.1	0.3017
3.		Psychosocial Well Being	71.2 ± 26.2	80.4 ± 21.6	0.2769
4.		Sexual Well Being	52.2 ± 28.4	62.8 ± 21.9	0.0139*
5.	Aesthetic Score	4.6 ± 2.3	6.7 ± 1.3	0.0009*	

266 (Data: Mean + S.D.; * Statistically Significant)

267 **Assessment of Post-IBRS Complications**

268 No major complications (immediate or /delayed) were observed in the patients that underwent
 269 A-ALDS (n=18) procedure. However, out of the 22 patients that underwent conventional IBRS,
 270 immediate major complications were observed in 3 patients (13.6 %) with implant loss and
 271 delayed major complications in 1 patient (4.5 %) with Grade III capsular contracture (Table
 272 3). No delay in time between completion of the surgery and start of the adjuvant therapy were
 273 observed in patients from both groups.

274 As described above, 18 patients with small breasts from our study cohort have successfully
 275 undergone the reconstruction with the novel A-ALDS technique without any major

276 complications. These observations indicate that the use of A-ALDS procedure during IBRS is a
277 safe and feasible technique.

278

279 **Table 3: Summary of Post-Operative Complications**

	Variables		Conventional - IBRS; (n = 22) Number, (%)	A-ALDS; (n = 18) Number, (%)
Major Complications	Immediate	Implant Loss	3 (13.6)	0 (0)
		Skin dehiscence requiring re-suture or skin graft or minor local flap	0 (0)	0 (0)
	Delayed	Capsular Contracture : Severe (Grade III)	1 (4.5)	0 (0)
		Total	4 (18.1)	0 (0)
Minor Complications		Capsular Contracture : Mild (Grade I / II)	2 (9.09)	1 (5.5)
		Minor skin / wound dehiscence (treated conservatively)	3 (13.6)	1 (5.5)
		Late infections (treated with antibiotics)	2 (9.09)	0 (0)
		Total	7 (31.78)	2 (11.0)

280

281

282 **DISCUSSION**

283 Breast reconstruction in patients with small-breasts is challenging because of insufficient tissue
284 access in the lower pole to create a dermal sling. In this study, we have described in detail a
285 novel A-ALDS technique, which represents an innovative modification to the routine lower
286 dermal sling procedure for application in the reconstruction of small, non-ptotic breasts. In our
287 study cohort, we have observed an early trend towards lower rates of capsular contracture
288 (Grade II and III) and implant loss in A-ALDS patients in comparison to conventional IBRS
289 patients.

290 A-ALDS provides a stable, double-layered vascularized tissue cover for the implant. This likely
291 allows effective in situ placement of the implant in the breast pocket with robust mechanical
292 stability and helps in symmetrization with the contralateral breast.

293 The A-ALDS was performed by advancing the de-epithelized dermal sling over the implant by
294 mobilizing the skin and subcutaneous tissue from the lower thoracic and upper abdominal wall.
295 This modification results in the recreation of a well-defined IMF to facilitate symmetry *vis-svis*
296 shape and size with contralateral breast. In our technique, the A-ALDS flap was sutured with
297 pectoralis major/serratus anterior muscle to provide desired expansion to the lower pole for
298 implant placement that provides mechanical stability to the implant. The A-ALDS flap allows
299 the expansion of the inferior pole of the pocket and prevents high riding of the implant. Hence,
300 this modification provides a good contour and natural shape and symmetry to the breast. It is
301 well reported that thoraco-epigastric flaps maintain vascularity from perforators of the
302 intercostal, lumbar, epigastric arcade and inferior epigastric arteries. As a result, these flaps
303 have been previously used in correcting mastectomy defects by small volume replacements
304 [10].

305 We now present evidence of successful use of A-ALDS flap in breast reconstruction without
306 detaching and advancing it by preserving the vascularity. In our cohort, A-ALDS patients
307 demonstrated significantly higher aesthetic scores (6.7 ± 1.3 versus 4.6 ± 2.3 , $p=0.009$)
308 compared with conventional IBRS after a 12 month follow-up.

309
310 In addition to optimal post-surgery outcomes, patient acceptance of the A-ALDS technique is
311 equally important. The PROMs (Breast-Q) data from our study indicates significantly higher
312 satisfaction with sexual well-being in patients who have undergone reconstruction with the A-
313 ALDS technique. Other parameters such as satisfaction with breast, satisfaction with outcome
314 and psycho-social well-being showed a positive trend in favor of A-ALDS-based
315 reconstruction.

316 Based on these observations, we hypothesize that use of A-ALDS flap with an implant may
317 provide a viable, vascularized tissue cover to the implant. This flap lowers the risk of implant
318 exposure, thereby, lowering the rates of implant loss and capsular contracture. This well
319 vascularized autologous flap is expected to render the tissue environment more favorable for
320 implant placement and improve wound healing, thereby reducing the risks of fibrosis, capsular
321 contracture, wound breakdown, infection and may reduce the implant related complication after
322 RT [11]. By extension, the higher complication rate in our study patients who have undergone
323 conventional IBRS may be attributed to the thin fascia covering the implant, which may
324 predispose the implant to exposure in case of infection or necrosis.

325 In low-resource settings such as India, ADMs are not yet available. This prompted us to
326 innovate the breast reconstruction technique for women with small breasts using the A-ALDS
327 technique. Indeed, our collective results indicating superior cosmetic scores, lower rates of

328 immediate complications and trend towards better patient acceptance after A-ALDS based
329 reconstruction are encouraging. It is conceivable that our novel A-ALDS technique may
330 provide a cost-effective alternative to ADM based IBRS. The economic advantage of this
331 ALDS technique is apparent as it can be performed in a single setting without compromising
332 the patient outcomes and obviating the need for contralateral procedure.

333 Our main aim was to report the surgical details of the innovative A-ALDS based IBRS
334 procedure in small or minimally ptotic breasts. We propose that the A-ALDS based IBRS
335 procedure may be routinely employed in the patients with small breasts that will ensure a good
336 cosmetic outcome with minimal early complications, no implant loss and lesser capsular
337 contracture rate with an overall positive impact on quality of life.

338 Despite the important findings, our study has few limitations. This study represents the post
339 IBRS follow-up data only for a period of 12 months. To substantiate the promising clinical and
340 PROMs observations, long-term follow-up i.e., 3 to 5 years post-surgery in the same cohort is
341 needed. Secondly, this study represents a single-institutional cohort in which all A-ALDS
342 procedures were performed by the same surgical team which may represent investigator bias.
343 To validate our observations and minimize bias, this study needs to be replicated in multi-
344 centric settings.

345

346 **CONCLUSION**

347 In conclusion, our study reports application of a novel A-ALDS technique for implant-based
348 breast reconstruction in small, non/minimally ptotic small breasts. Preliminary observations
349 from post-surgery evaluations and PROMs demonstrate that A-ALDS technique may
350 potentially reduce post-surgery complications, improve aesthetic outcomes and improve

351 overall patient satisfaction. This technique may serve as a cost-effective alternative to ADM-
352 based reconstruction in low resource settings. Long-term follow-up and study replication in
353 other breast surgery units will be necessary for further substantiating our early observations.

354

355 **DATA AVAILABILITY**

356 All data will be available and can be shared on request. Supplementary tables and figures are
357 provided in support of data presented in the manuscript.

358 **CONFLICTS OF INTEREST STATEMENT**

359 The author declares no competing interests.

360

361 **ACKNOWLEDGMENTS**

362 The study authors would like to thank all participants who consented to participate in this study.
363 We also acknowledge Bajaj Auto Ltd. for providing support to research activities at
364 PCCM (Grant #PCCM529). We express our appreciation to Dr. Madhura Kulkarni , Dr. Dhara
365 Patel and Dr.Sneha Joshi for their help in editing the manuscript. We are grateful to the MAPI
366 Research Trust for permission to use BREAST-Q (<http://www.mapitrust.org>). We would also
367 like to thank the management and staff of Ruby Hall Clinic, Pune where all surgeries were
368 performed.

369 **ETHICAL APPROVAL**

370 Study approval was granted by the Independent ethics committee of Prashanti Cancer Care
371 Mission. Independent Ethics Committee of Prashanti Cancer Care Mission (DCGI/CDSCO
372 Registration Number : ECR/298/Indt/MH/2018 (dated May 14 2018)

373

374 **CONSENT**

375 All subjects gave their consent for the use of their personal and medical information
376 including images in the publication of this study.

377 **FOOTNOTE**

378 A part of this work was presented as a poster at the Breast Cancer Coordinated Care conference
379 in Washington, DC on March 1-3, 2018.

380

381

382

383

384

385

386

387

388

389

390

391

392 **REFERENCES**

393 1. Dietz J, Lundgren P, Veeramani A, O'Rourke C, Bernard S, Djohan R, et al.

394 Autologous inferior dermal sling (autoderm) with concomitant skin-envelope

395 reduction mastectomy: an excellent surgical choice for women with macromastia and

396 clinically significant ptosis.

397

398 2. Ann Surg Oncol. 2012; 19(10):3282-8. King IC, Harvey JR, Bhaskar P. One-Stage

399 Breast Reconstruction Using the Inferior Dermal Flap, Implant, and Free Nipple

400 Graft. Aesthetic Plast. Surg. 2014; 38(2):358-64.

401 3. Roy PG. Modified Lower Pole Autologous Dermal Sling for Implant Reconstruction

402 in Women Undergoing Immediate Breast Reconstruction after Mastectomy. Int. J

403 Breast Cancer. 2016; 2016:9301061

404

405 4. Spear SL, Sher SR, Al-Attar A. Focus on technique: supporting the soft-tissue

406 envelope in breast reconstruction. Plast Reconstr Surg. 2012; 130(5 Suppl 2):89S–

407 94S

408

409 5. Rusby JE, Smith BL, Gui GP. Nipple-sparing mastectomy.Br J Surg. 2010 M;

410 97(3):305-16.

411 6. Spear SL, Baker JL Jr. Classification of capsular contracture after prosthetic breast

412 reconstruction. Plast Reconstr Surg. 1995; 96(5): 1119-24.

413 7. Shekhawat L, Busheri L, Dixit S, Patel C, Dhar U, Koppiker C. Patient -Reported
414 Outcomes Following Breast Reconstruction Surgery and Therapeutic Mammoplasty:
415 Prospective Evaluation 1 Year Post-Surgery with BREAST-Q Questionnaire; Indian J
416 Surg Oncol 2015; 28 (2): 121-27.

417 8. Pusic AL, Klassen AF, Scott AM, Klok JA, Cordeiro PG, Cano SJ. Development of a
418 new patient-reported outcome measure for breast surgery: the BREAST-Q. *Plast*
419 *Reconstr Surg*. 2009; 124(2):345-53.

420

421 9. Nguyen KT, Mioton LM, Smetona JT, Seth AK, Kim JY. Esthetic outcomes of
422 ADM- assisted expander-implant breast reconstruction. *Eplasty*. 2012; 12:e58.

423

424 10. Evan Matros, Joseph J. Disa. Uncommon flaps for chest wall reconstruction.
425 *Semin Plast Surg*.2011 25(1): 55–59.

426 11. Chang DW, Barnea Y, Robb GL. Effects of an autologous flap combined with an
427 implant for breast reconstruction: an evaluation of 1000 consecutive reconstructions
428 of previously irradiated breasts. *Plast Reconstr Surg*. 2008; 122(2):356–62.

429

430

431

432

433

434 **SUPPLEMENTARY MATERIAL**

435 **Supplementary Videos**

436 **Koppiker etal -A-ALDS Video 1.mp4 : Pre-Operative Marking and Creation of A-ALDS**

437 **Flap**

438 Pre-Operative markings and skin de-epithelisation to form A-ALDS flap.

439 **Koppiker etal -A-ALDS Video 2.mp4 : Mastectomy**

440 Mastectomy is carried out with the removal of breast tissue.

441 **Koppiker etal -A-ALDS Video 3.mp4 : Correction of Completely Vascularized Pocket**

442 **with A-ALDS Technique**

443 Implant is placed in sub-pectoral pocket and advancement of A-ALDS flap. Pectoralis major

444 and serratus anterior muscle are sutured to de-epithelialised A-ALDS to create a complete

445 vascularized cover.

446

447

448

449

450

451

452

453

454

455

456

457 **SUPPLEMENTARY TABLE**

458 Aesthetic 3-Point Outcome Score

Category	0	1	2
Volume	Marked discrepancy relative to the contralateral side	Mild differences in Volume relative to the Contralateral Side	Minimal Differences in volume relative to The Contralateral Side
Contour	Marked contour deformity or shape asymmetry	Mild differences in Contour deformity or Shape Asymmetry	Minimal Differences in contour deformity or Shape Asymmetry
Placement	Marked displacement of breast mound	Mild Displacement of breast Mound	Minimal Displacement of breast Mound
Scarring	Hypertrophic scars and evident contracture	Fair scarring (poor color match or wide scars without Hypertrophy Or contracture)	Thin scars
Infra-Mammary Fold	Poorly defined infra-Mammary fold	Defined but Asymmetrical infra-Mammary Fold	Symmetrical infra-Mammary Folds
Nguyen et al. <i>Eplasty</i> 2012; 5:486–492.			

459

460

461

462

Figure 1A

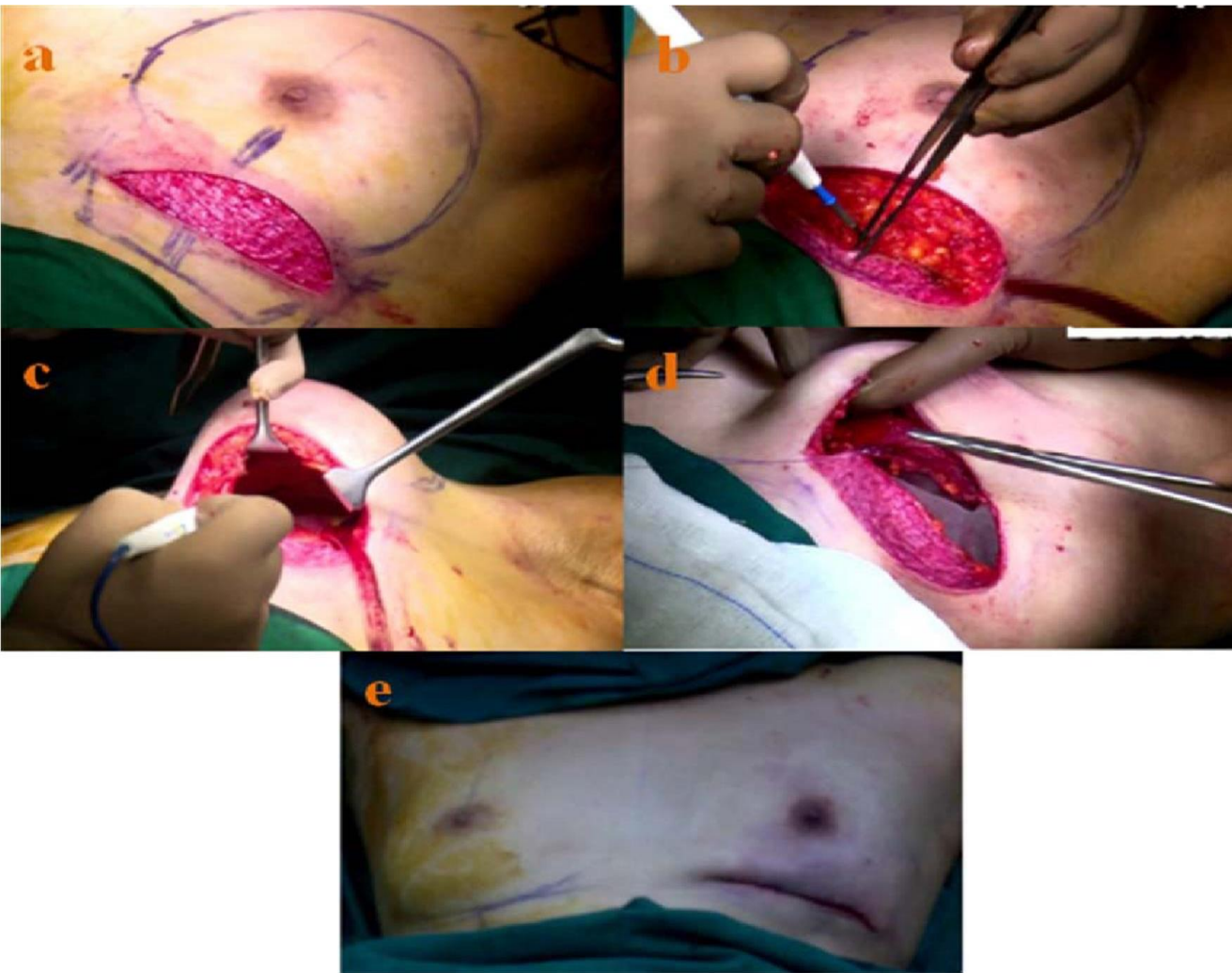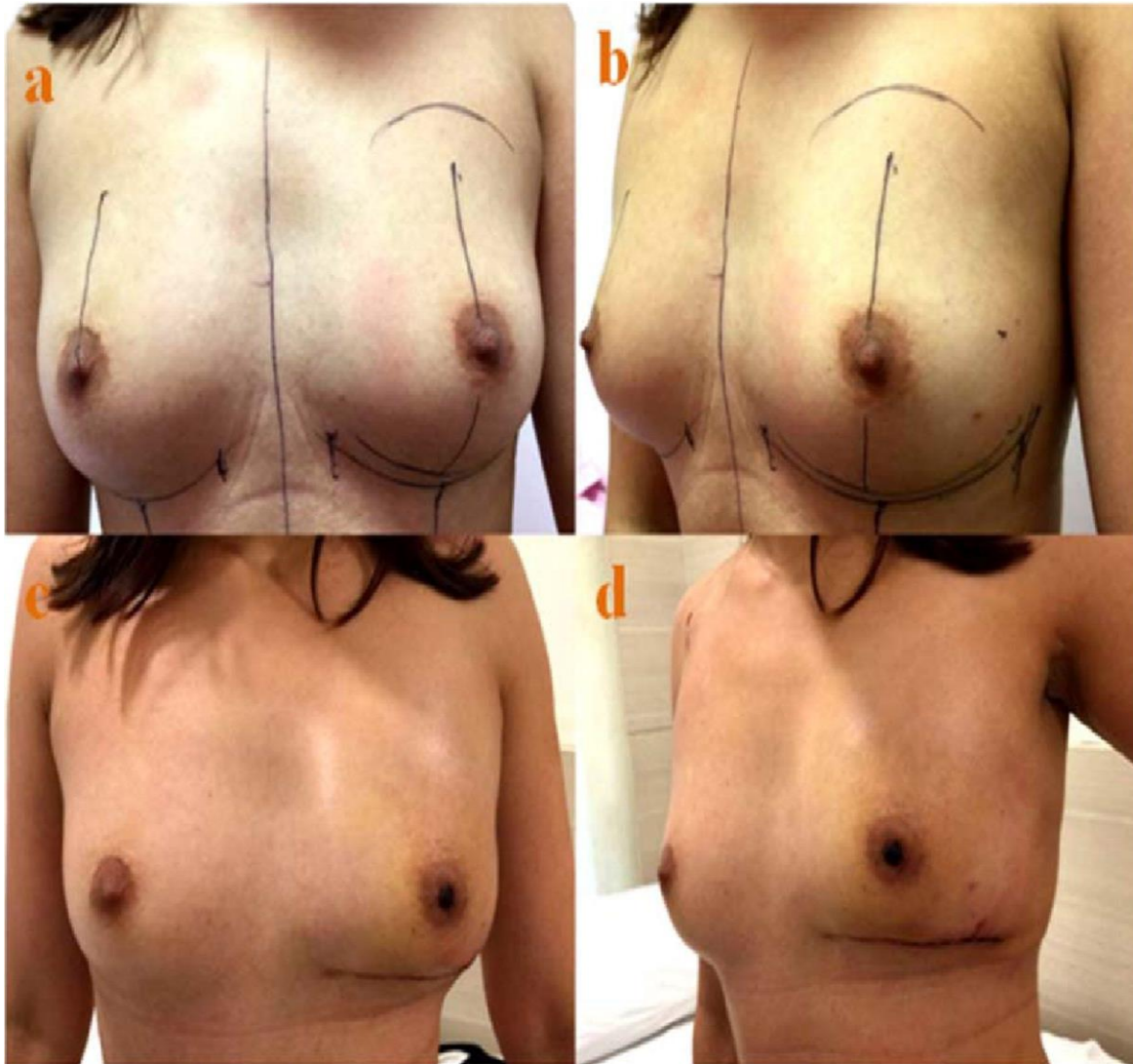


Figure 1: Representative Case Study for A-ALDS based IBRS

1A. Intraoperative Images

- a) De-epithelialization of lower dermal flap from IMF to 3 cm onto the breast
- b) Advancement of lower dermal flap to create of new-IMF by mobilizing skin from lower thoracic and upper abdominal wall
- c) Formation of subpectoral pocket
- d) Insertion of implant under pectoralis major muscle
- e) Completion of IBRS with A-ALDS procedure after skin suturing.

Figure 1B

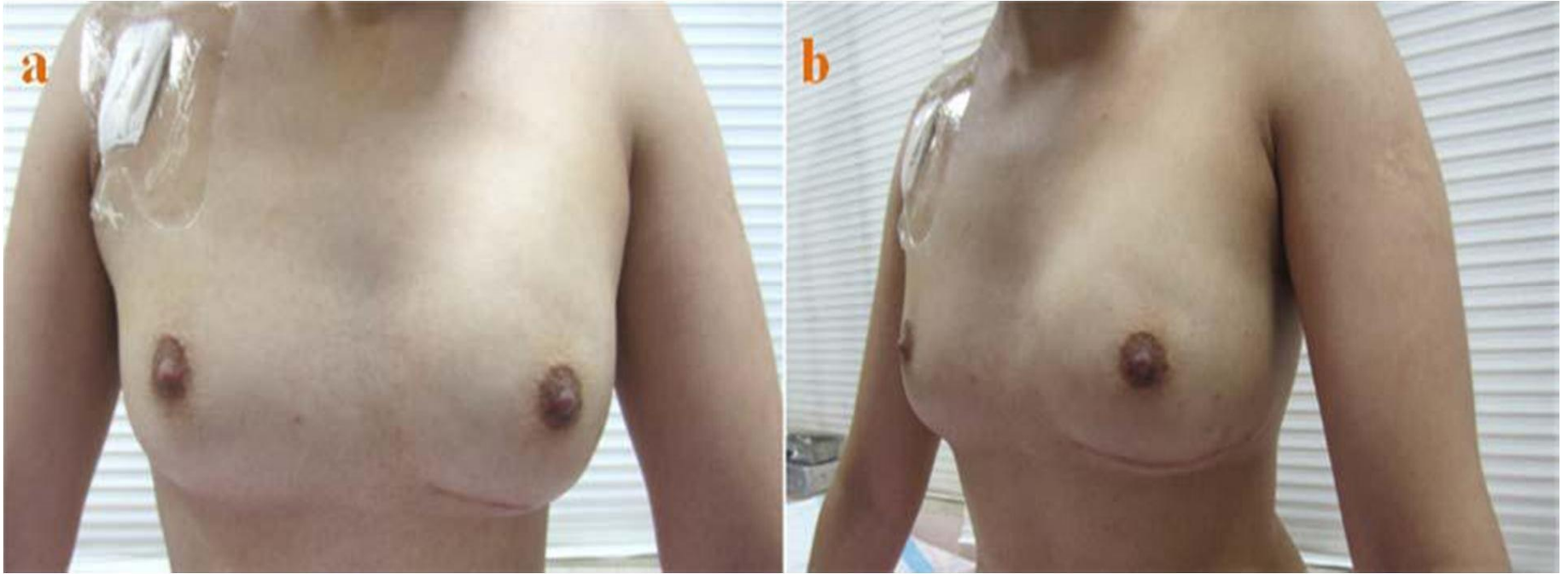

1B. Pre-operative and Post-operative Images

a, b) Pre-operative images

c, d) Post-operative images after 1 months of the surgery. Lower pole flattening seen in early phase.

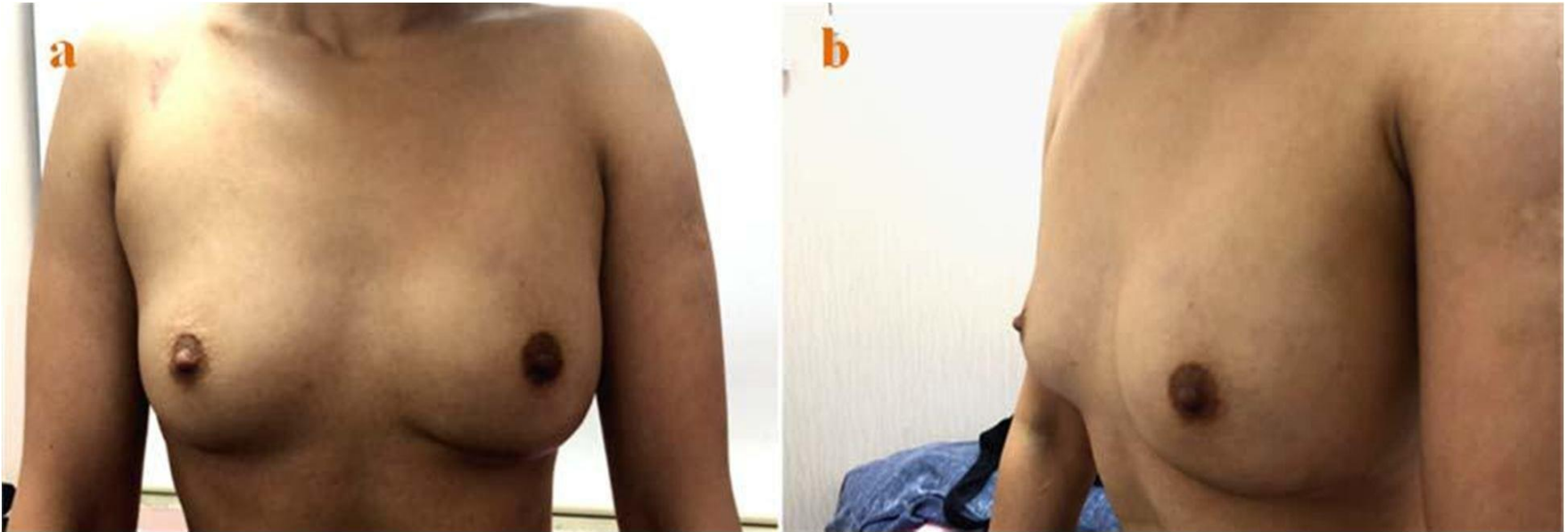Figure 1C



1C. Post-operative Image of the same patient after 3 months follow-up

a, b) Post-operative images after 3 months of the surgery and Lower pole fullness achieved.

Figure 1D



1D. Post-operative Image of the same patient after 1 year follow-up
a, b) Post-operative images after 1 year of the surgery.

Figure 2 : Study Flow Chart : Distribution of Study Participants

