

Title page

Manuscript type: Original article

Title: Evaluation of rapid antibody test and chest computed tomography results of COVID-19 patients: A retrospective study

Ali Ozturk¹, Taylan Bozok², Tugce Simsek Bozok³

¹Department of Medical Microbiology, Nigde Omer Halisdemir University Faculty of Medicine, Nigde, Turkey

²Department of Medical Microbiology, Nigde Omer Halisdemir University Training and Research Hospital, Nigde, Turkey

³Department of Infectious Diseases and Clinical Microbiology, Nigde Omer Halisdemir University Training and Research Hospital, Nigde, Turkey

Corresponding author:

Assistant Professor Dr. Ali Ozturk

Department of Medical Microbiology, Nigde Ömer Halisdemir University, Faculty of Medicine, 51240 Nigde, Turkey.

ORCID iD: 0000-0003-2428-1831

Email: ali.81ozturk@gmail.com

Abstract

Background: The coronavirus disease 2019 (COVID-19) continues to spread around the world. Therefore, rapid, simpler, and more accurate diagnostic tests are urgently needed to diagnose the Severe Acute Respiratory Syndrome Coronavirus 2 (SARS-CoV-2) infection. The purpose of this study was to evaluate the SARS-CoV-2 IgM/ IgG rapid antibody test results in symptomatic patients with COVID-19 and their chest computed tomography (CT) data.

Methods: A total of 320 patients admitted to our hospital for different durations due to COVID-19 were included in the study. Serum samples were obtained within 0 to 7 days from COVID-19 patients confirmed by RT-PCR and chest CT scan. According to the SARS-CoV-2 RT-PCR results, the patients included in the study were divided into two groups: PCR positive group (n=46), and PCR negative group (n=274).

Results: Of the 320 COVID-19 serum samples, IgM, IgG, and IgM/IgG were detected in 9.4%, 3.1%, and 17.8% within one week respectively. IgG/IgM antibodies were not detected in 69.7% of the patients. In the study, it was determined that 249 (77.8%) of 320 patients had positive chest CT scans. Four (5.6%) of 100 patients with negative chest CT scan had IgM positive and 2 (2.8%) had both IgM/ IgG positive. IgM was detected in 23 (9.2%), IgG in 1 (0.4%) and IgM/IgG in 35 (14%) of chest CT scan positive patients. The rate of CT findings in patients with antibody positivity (n=97) was found to be significantly higher than those with antibody negativity.

Conclusions: The results of the present study show the accurate and equivalent performance of serological antibody assays and chest CT in detecting SARS-CoV-2 0 to 7 days from the onset of COVID19 symptoms. When the RT-PCR is not available, we believe that the combination of immunochromatographic test and chest CT scan can increase diagnostic sensitivity for COVID-19.

Keywords: SARS-CoV-2; COVID-19; Rapid diagnosis; Chest CT; RT-PCR, lateral flow; Antibody, Sensitivity

INTRODUCTION

2019 Coronavirus Disease (COVID-19) originated in Hubei Province, China, in December 2019 (1). COVID-19 disease, caused by SARS-CoV-2 (Severe Acute Respiratory Syndrome Coronavirus-2), is an infectious disease that has started to spread rapidly and has turned into a pandemic within three months from its first detection (2). Since there is no specific treatment or vaccine for COVID-19, early diagnosis and subsequent isolation of infected patients are important for disease control. Today, the Reverse Transcription-Polymerase Chain Reaction (RT-PCR) test for SARS-CoV-2 is considered the gold standard for the diagnosis of COVID-19. However, since RT-PCR is time-consuming, and requires special equipment and trained laboratory technicians, it is not widely used in the clinical setting. Since the RT-PCR test is performed on the upper and lower respiratory tract samples, it increases the risk of exposure to viral droplets during the collection and RNA isolation process. Therefore, alternative diagnostic tests to RT-PCR are required for the clinical management of COVID-19. Detection of antibodies against SARS-CoV-2 can play a complementary role with the RT-PCR test in the diagnosis of COVID-19 and in evaluating the immune status of individuals. Also, serological data will enable the gathering of important epidemiological information about the spread of the epidemic, and its morbidity and mortality. Additionally, the detection of antibodies against SARS-CoV-2 will play an important role in determining vaccine development strategies (1, 3, 4).

As a routine imaging tool in the diagnosis of COVID-19, chest Computed Tomography (CT) scan is a relatively easy, fast, and non-invasive radiological diagnostic tool. Chest CT analysis plays an important role not only in early detection and diagnosis especially in false-negative RT-PCR tests but also in monitoring the clinical course and evaluating the severity of the disease (5, 6). It has been reported that the RT-PCR test is only 30-60% sensitive in the diagnosis of COVID-19, and is less sensitive than chest CT during the early course of the disease. For example, 5 suspected cases were shown to have ground-glass opacity and/ or mixed consolidation on chest CT scan, but the initial RT-PCR test was negative. A few days later, all 5 cases tested for the second or third examinations were confirmed as positive for SARS-CoV-2 (6, 7).

In cases where the RT-PCR test of symptomatic and/or asymptomatic cases is negative, serological tests and chest CT scanning can be considered as complementary tests for the RT-PCR technique. It may also be useful in the diagnosis of SARS-Cov-2 infection by providing

promising clinical findings. Findings to be obtained from antibody testing will bring benefits for epidemiological studies for the COVID-19 pandemic in our province. Thus, it will provide advantages such as increasing the reliability of test results and preventing epidemics. This study aimed to evaluate the SARS-CoV-2 IgM / IgG rapid antibody test results from serum samples taken from admitted patients with suspected COVID-19 and their chest CT data.

MATERIALS and METHODS

Patients and data sources

A total of 320 inpatient COVID-19 cases, admitted to Niğde Ömer Halisdemir University Training and Research Hospital between 11 March and 30 June 2020 were enrolled in this study. According to the SARS-CoV-2 RT-PCR results, the patients included in the study were divided into two groups: PCR positive group (n=46) and PCR negative group (274). Chest CT findings of patients enrolled in this study were evaluated by an Infection and Clinical Microbiologist to determine clinical features caused by COVID-19 (such as bilateral or multilobar involvement, ground-glass opacity, subpleural involvement, pleural effusion). Serum samples were obtained within 0 to 7 days from COVID-19 patients confirmed by RT-PCR and chest CT scan. The date of symptoms onset, clinical classification, RT-PCR testing results, hospitalization period, and the demographic information was obtained from the clinical records of our hospital. In the study, serum samples were taken from patients before the COVID-19 pandemic were used as negative controls to evaluate the analytical sensitivity and specificity of the antibody test.

Collection of serum samples

Blood samples taken from the patients (5-6 ml) were placed in tubes containing separator gel (SST) and centrifuged at 10.000 xg for 5 minutes. Patient sera were stored at -80°C until the day of the study. All risks related to the storage condition and transporting of the samples were applied following the conditions specified by the Turkish Republic Ministry of Health and Microbiology Laboratory guidelines (8).

Detection of SARS-CoV-2 IgM / IgG antibodies

Qualitative detection of antibodies was performed using the COVID-19 IgM / IgG rapid test kit developed for SARS-CoV-2 (colloidal gold) based on the Lateral flow method (Singclean[®], China) according to the manufacturer's instructions. Briefly, 10µL of blood or

serum was added to the sample pad of the antibody test. Two drops of sample buffer (phosphate buffer, NaCl, tween-20) were then added to the same sample pad, and the results were interpreted after a 10-minute incubation period. The presence of only the control line is negative, the presence of the control line and IgM line is IgM positive, the presence of the IgG line together with the control line is IgG positive, and the presence of IgM and IgG lines together with the control line are evaluated as both IgM and IgG positive.

Statistical analysis

SPSS 20.0 was used for statistical analysis. Chi-square test was used in statistical analysis. Pearson Correlation test was used to see the level of agreement between the rapid antibodies test and chest CT scan. Significance was set at a p value of less than 0.05.

Ethical approval

This study was reviewed and approved by the Ethics Committee of Nigde Omer Halisdemir University Faculty of Medicine (Approval no. 2020/21).

RESULTS

In this retrospective study, a total of 320 patients including 162 (50.6%) men and 158 (49.4%) women were included. The patients were between the ages of 18-90 (mean age 54.14). The clinical signs of COVID-19 patients are shown in Table 1. The most common symptoms in patients were; fever (75.3%), headache (70.6%), myalgia (67.5%), cough (61.9%), dyspnea (25%), loss of taste and smell (19.7%), and diarrhea (4.0%). RT-PCR results of 320 patients were determined as 46 (13.2%) positive and 274 (85.6%) negative.

Table 1: The demographic and clinical characteristics of the patients.

Parameter	Value (n /%)
The average age	54.14 (18-90 years old)
Gender	Male 162 (50.6%), Female 158 (49.4%)
Symptoms	
Fever	241 (75.3 %)
Headache	226 (70.6 %)
Myalgia	216 (67.5 %)
Cough	217 (61.9 %)
Dyspnea	80 (25 %)
Loss of smell and taste	63 (19.7 %)
Diarrhea	13 (4.0 %)
Ct range for RT-PCR	16-40

Ct: Threshold cycle, RT-PCR positive ($C_t \leq 38$), RT-PCR negative ($C_t \geq 38$).

Rapid IgM/ IgG antibody test

The 320 serum samples collected for the study were evaluated by rapid card test based on the lateral flow method of IgM/ IgG antibodies. The results of the antibody test against SARS-CoV-2 are shown in Table 2. In a total of 320 inpatients, IgM was detected in 30 (9.4%), IgG in 10 (3.1%), and both IgM and IgG were found positive in 57 (17.8%) of the serum samples included in the study. IgG/ IgM antibodies were not detected in 223 (69.7%) of the patient samples. The sensitivity and specificity of the test were 30.3% and 95%, respectively.

When the presence of antibodies according to the RT-PCR results were evaluated, one (2.2%) of 46 patients with positive RT-PCR results had IgG, seven (15.2%) IgM, and six (13.0%) had positive IgM and IgG. In patients with negative RT-PCR results (n = 274), IgG was detected in one patient (0.36%), IgM in 25 patients (9.1%), and IgM and IgG antibodies in 31 patients (11.3%).

Table 2: Detection of IgM / IgG antibody in serum samples of patients with COVID-19.

Presence of antibodies	Number of patients (n= 320)	Control group (n = 40)
IgM	30	0
IgG	10	2
Both IgM/ IgG	57	0
Sensitivity	30.3 %	-
Specificity	-	95 %

In the negative control patient group (n=40), only two serum samples were found IgG positive.

Chest CT findings

Chest CT scans of symptomatic patients were performed on the day of admission to the hospital. The percentage of findings that are compatible with the clinical features of COVID-19 in the chest CT scans of the patients is given in Figure 1. Mostly, ground-glass opacity (68.5%) findings were detected in the chest CT scans of the patients. When clinical findings consistent with COVID-19 were evaluated collectively, it was determined that 249 (77.8%) of 320 patients had positive and 71 patients (22.2%) had negative chest CT scans. The sensitivity rate of chest CT scan was calculated as 77.8% (249/320).

Figure 1. Distribution of chest CT findings of COVID-19 patients.

In the present study, the presence of antibodies was evaluated according to the chest CT scan results. Four (5.6%) of those with negative chest CT scans were IgM positive and two (2.8%) were positive for both IgM and IgG. In patients with positive chest CT scan 23 (9.2%) IgM, one (0.4%) IgG and 35 (14.0%) both IgM/IgG were positive.

Regarding chest CT findings according to RT-PCR results, it was found to be positive in 28 (61.0%) of the RT-PCR positive patients (n = 46). Whereas in patients with negative RT-PCR (n = 274) 130 patients (47.4%) had positive chest CT scans.

When the antibody test and chest CT scan results of the patients included in the study were evaluated together (Table 3), the rate of CT findings in patients with antibody positivity (n=97) was found to be significantly higher (87.6%) than those with antibody negativity (65.0%) ($p<0.0001$).

Table 3: Rapid antibody test and chest CT findings for patients with COVID-19.

			CT findings		Total
			Positive	Negative	
SARS-CoV-2 IgM/ IgG	Negative	n	145	78	223
		Within SARS-CoV-2 IgM/IgG (%)	65.0 %	35.0 %	100%
	Positive	n	85	12	97
		Within SARS-CoV-2 IgM/IgG (%)	87.6 %	12.4 %	100%
Total	n	249	71	320	
	Within SARS-CoV-2 IgM/IgG (%)	77.8 %	22.2 %	100%	

DISCUSSION

Early diagnosis of COVID-19 is very important to treat and control the disease. An accurate, fast, and cost-effective diagnostic method is required for the diagnosis of the disease during the pandemic process. Nowadays molecular methods, serological tests, and chest CT scans are used for this purpose (9, 10).

In the diagnosis of COVID-19, RT-PCR test is used as a gold standard to detect viral RNA in respiratory tract samples. However, the RT-PCR test leads to false-negative results due to problems in sample collection and/or detection. Also, it is a time-consuming and expensive diagnostic method (11, 12).

Serological testing is universally recognized as an accurate and appropriate diagnostic method for identifying asymptomatic and symptomatic persons, and monitoring the immune

status of people recovering from acute COVID-19 infection (13). Although several countries have purchased one or more of the rapid antibody tests, inconsistencies have been reported about the sensitivity and specificity rates of these tests in studies (14).

Compared to other diagnostic tests (for example, RT-PCR), chest CT imaging is a more reliable, practical, and fast method to diagnose and evaluate COVID-19, especially during the epidemic period (15). Studies have shown that the sensitivity of chest CT in symptomatic patients is high (74.3%-97%). The clinical performance of chest CT depends on factors such as patient population differences, disease severity, and accessibility to chest CT scans (16, 17, 18).

In our study, the antibody response in symptomatic COVID-19 patients was investigated with the rapid IgM/ IgG card test. The serological data obtained were evaluated with the chest CT scan data of the same patients. The rapid antibody test used in our study was found to be less sensitive (30.3%) for serum samples collected within 0 to 7 days from the onset of symptoms. Test performance features (sensitivity 95.7% and specificity 97.3%) provided by the manufacturer were found higher than those observed in our study. The difference in test performance is likely due to a variety of factors, such as quality and type of sample, sample collection time, antibody level, and sample processing techniques. The chest CT scan was positive in 249 of the symptomatic patients. The chest CT scan was positive in 249 of the symptomatic patients. The chest CT scans were found to be positive in 85% of the patients who were antibody positive and 65% in those who were antibody negative.

A study evaluating rapid antibody test and chest CT scan method was performed by Imai et al. They examined 139 serum samples collected from 112 patients with COVID-19. In the study, 90 COVID-19 serum specimens, IgM and IgG were detected in 27.8% and 3.3%, respectively (in total 31.1%) of the specimens collected within one week. The diagnostic sensitivity of chest CT scan was 74.3% (55/74) for the symptomatic patients.

In the current study, IgM, IgG, and both IgG/IgM were detected in 9.4%, 3.1%, and 17.8%, respectively (in total 30.3%) in the serum samples collected from symptomatic patients within one week. The sensitivity rate of chest CT scan was 77.8% (249/320) for the symptomatic patients.

Our study showed that with the rapid card test, SARS-CoV-2 IgM / IgG antibodies were found less frequently in RT-PCR positive and negative symptomatic patients at significant levels. On the other hand, chest CT scans of patients with positive and negative RT-PCR (320)

were found to be positive (249/320). Considering the results obtained from the rapid antibody test and chest CT scan, the chest CT screening test for the early diagnosis of COVID-19 in symptomatic patients stands out with a sensitivity rate of 77.8%. Also, specific radiological features of COVID-19 were not detected in 22.2% of symptomatic patients.

Our study has some limitations; only symptomatic patients were included in the study. Therefore, it is not known whether the antibody response is similar in asymptomatic individuals. Serum samples collected for antibody testing and chest CT scan data were obtained within one week from the onset of symptoms. Therefore, it is necessary to take samples/scans at different times to obtain clear information about the sensitivity of these tests. Besides, more detailed studies with different methods (such as ELISA) on consecutive samples are needed. Multi-center studies should be conducted to determine the usefulness of both tests for the diagnosis of COVID-19.

CONCLUSION

When the data obtained in our study were examined, the sensitivity of rapid antibody tests alone was not found to be sufficient in the diagnosis of COVID-19 within one week from the onset of COVID-19 symptoms. This study shows the accurate and equivalent performance of serological antibody assays and chest CT in diagnosing COVID-19 within 0 to 7 days from the onset of COVID-19 symptoms. Therefore, to properly manage the pandemic process, we believe that the combination of immunochromatographic (IC) test and chest CT scan can serve as a rapid diagnostic test of RT-PCR-negative suspected patients and screening of SARS CoV-2 carriers. These tests/methods cannot take the place of RT-PCR, but may increase diagnostic sensitivity for COVID-19.

Competing interests

The authors declare that there is no conflict of interests regarding the publication of this paper.

Funding: None

REFERENCES

1. Chen Y, Chan KH, Kang Y, Chen H, Luk HKH, Poon RWS, et al. A sensitive and specific antigen detection assay for Middle East respiratory syndrome coronavirus. *Emerg Microbes Infect.* 2015;4(4):e26. doi: 10.1038/emi.2015.26.

2. Amanat F, Stadlbauer D, Strohmeier S, Nguyen THO, Chromikova V, McMahon M, et al. A serological assay to detect SARS-CoV-2 seroconversion in humans. *Nat Med.* 2020; 26(7):1033-1036. doi: 10.1038/s41591-020-0913-5.
3. Xiang F, Wang X, He X, Peng Z, BohanYang, Zhang J, et al. Antibody detection and dynamic characteristics in patients with coronavirus disease 2019. *Clin Infect Dis.* 2020. 5;71(8):1930-1934. doi: 10.1093/cid/ciaa461.
4. Zhao J, Yuan Q, Wang H, Liu W, Liao X, Su Y, et al. Antibody responses to sars-cov-2 in patients with novel coronavirus disease 2019. *Clin Infect Dis.* 2020;71(16):2027-2034. doi: 10.1093/cid/ciaa344.
5. Long QX, Liu BZ, Deng HJ, Wu GC, Deng K, Chen YK, et al. Antibody responses to SARS-CoV-2 in patients with COVID-19. *Nat Med.* 2020;26(6):845-848. doi: 10.1038/s41591-020-0897-1.
6. Xie J, Ding C, Li J, Wang Y, Guo H, Lu Z, et al. Characteristics of patients with coronavirus disease (COVID-19) confirmed using an IgM-IgG antibody test. *J Med Virol.* 2020;92(10):2004-2010. doi: 10.1002/jmv.25930.
7. Wang W, Wang H, Deng Y, Song T, Lan J, Wu G, et al. Characterization of anti-MERS-CoV antibodies against various recombinant structural antigens of MERS-CoV in an imported case in China. *Emerg Microbes Infect.* 2016;5(11):e113. doi: 10.1038/emi.2016.114.
8. Republic of Turkey Ministry of Health. COVID-19 (SARS-CoV2 infection) guide. 2020. 1-31. <https://saglik.gov.tr/>.
9. Xiang F, Wang X, He X, Peng Z, Yang B, Zhang J, et al. Antibody detection and dynamic characteristics in patients with Coronavirus Disease 2019. *Clin Infect Dis.* 2020;71(8):1930-1934. doi: 10.1093/cid/ciaa461.
10. Vashist SK. In vitro diagnostic assays for COVID-19: Recent Advances and Emerging Trends. *Diagnostics (Basel)* 2020;10(4):202. doi: 10.3390/diagnostics10040202.
11. Chaimayo C, Kaewnaphan B, Tanlieng N, Athipanyasilp N, Sirijatuphat R, Chayakulkeeree M, et al. Rapid SARS-CoV-2 antigen detection assay in comparison with real-time RT-PCR assay for laboratory diagnosis of COVID-19 in Thailand. *Virol J* 2020 Nov 13;17(1):177. doi: 10.1186/s12985-020-01452-5.
12. Imai K, Tabata S, Ikeda M, Noguchi S, Kitagawa Y, Matuoka M, et al. Clinical evaluation of an immunochromatographic IgM/IgG antibody assay and chest computed tomography for the diagnosis of COVID-19. *J Clin Virol.* 2020;128:104393. doi: 10.1016/j.jcv.2020.104393.

13. Ortiz-Prado E, Simbaña-Rivera K, Gómez- Barreno L, Rubio-Neira M, Guaman LP, Kyriakidis NC, et al. Clinical, molecular, and epidemiological characterization of the SARS-CoV-2 virus and the Coronavirus Disease 2019 (COVID-19), a comprehensive literature review. *Diagn Microbiol Infect Dis.* 2020; 98(1): 115094. doi: 10.1016/j.diagmicrobio.2020.115094
14. Ong DSY, Man SJ, Lindeboom FA, Koeleman JGM. Comparison of diagnostic accuracies of rapid serological tests and ELISA to molecular diagnostics in patients with suspected coronavirus disease 2019 presenting to the hospital. *Clin Microbiol Infect.* 2020;26(8):1094.e7-1094.e10. doi: 10.1016/j.cmi.2020.05.028.
15. Mukhtar B, Mukhtar MO, Malik B. Radiological changes observed in Covid 19 pneumonia and utilization of CT scan as a screening tool along with a real-time reverse transcriptase-polymerase chain reaction (rRT-PCR) for effective diagnosis. *MSD* 2020;7(8):578-83. doi: 10.36472/msd.v7i8.411.
16. Power SP, Moloney F, Twomey M, James K, O'Connor OJ, Maher MM. Computed tomography and patient risk: Facts, perceptions and uncertainties. *World J Radiol.* 2016; 8(12): 902–915. doi: 10.4329/wjr.v8.i12.902.
17. Parekh M, Donuru A., Balasubramanya R., Kapur S. Review of the chest CT differential diagnosis of ground-glass opacities in the COVID Era. *Radiology.* 2020; 202504. doi: 10.1148/radiol.2020202504.
18. Ai T, Yang Z, Hou H, Zhan C, Chen C, Lv W, et al. Correlation of chest ct and RT-PCR testing for coronavirus disease 2019 (COVID-19) in China: A Report of 1014 Cases. *Radiology.* 2020;296(2):32-40. doi: 10.1148/radiol.2020200642.

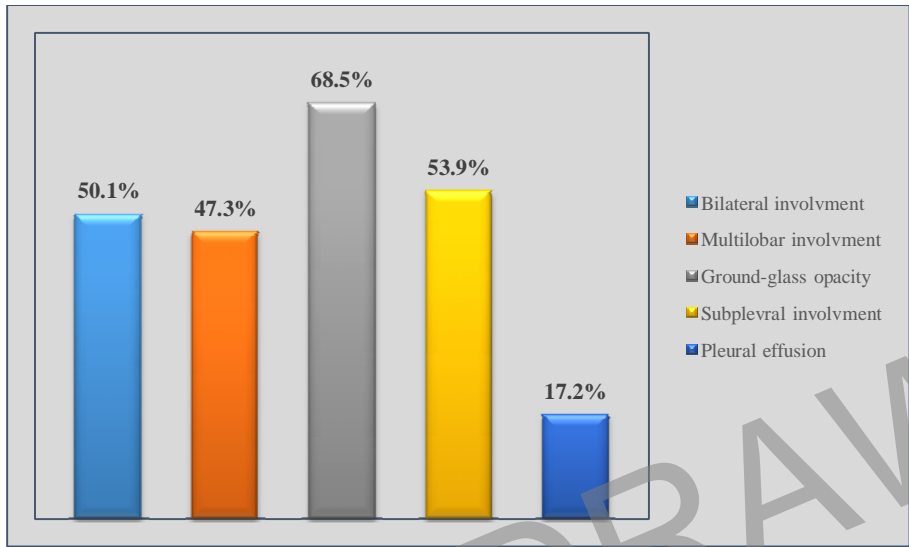


Fig. 1. Distribution of chest CT findings of COVID-19 patients.