

1 **Broad SARS-CoV-2 cell tropism and immunopathology in lung tissues from fatal**
2 **COVID-19**

3

4 Suzane Ramos da Silva*, Enguo Ju*, Wen Meng, Alberto E. Paniz Mondolfi, Sanja
5 Dacic, Anthony Green, Clare Bryce, Zachary Grimes, Mary Fowkes, Emilia M. Sordillo,
6 Carlos Cordon-Cardo, Haitao Guo, Shou-Jiang Gao

7

8 *Contributed equally

9 **Cancer Virology Program, UPMC Hillman Cancer Center and Department of**
10 **Microbiology and Molecular Genetics, University of Pittsburgh School of**
11 **Medicine, Pittsburgh** (S Ramos da Silva PhD, E G Ju PhD, W Meng PhD, Prof H T
12 Guo PhD, Prof S-J Gao, PhD); **Department of Pathology, Molecular and Cell-Based**
13 **Medicine, Icahn School of Medicine at Mount Sinai, New York** (Prof A E P Mondolfi
14 MD, PhD, Prof C Bryce MD, Z Grimes DO, Prof M Fowkes MD, PhD, Prof E M Sordillo
15 MD, PhD, Prof C Cordon-Cardo MD, PhD); **Department of Pathology, University of**
16 **Pittsburgh School of Medicine, Pittsburgh** (Prof S Dacic MD); **Tissue and Research**
17 **Pathology Core, UPMC Hillman Cancer Center, University of Pittsburgh School of**
18 **Medicine, Pittsburgh** (A Green HT).

19

20 Correspondence to: Prof Shou-Jiang Dr. Gao at UPMC Hillman Cancer Center, 5117
21 Centre Avenue, Pittsburgh, PA 15213, United States gaos8@upmc.edu

22 **Summary**

23 **Background** Severe Acute Respiratory Syndrome Coronavirus-2 (SARS-CoV-2)
24 infection in patients with Coronavirus Disease 2019 (COVID-19) prominently manifests
25 with pulmonary symptoms histologically reflected by diffuse alveolar damage (DAD),
26 excess inflammation, pneumocyte hyperplasia and proliferation, and formation of
27 platelet aggregates or thromboemboli. However, the mechanisms mediating these
28 processes remain unclear.

29 **Methods** We performed multicolor staining for viral proteins, and lineage cell markers to
30 identify SARS-CoV-2 tropism and to define the lung pathobiology in postmortem tissues
31 from five patients with fatal SARS-CoV-2 infections.

32 **Findings** The lung parenchyma showed severe DAD with thromboemboli in all cases.
33 SARS-CoV-2 infection was found in an extensive range of cells including alveolar
34 epithelial type II/pneumocyte type II (AT2) cells (HT2-280), ciliated cells (tyr- α -tubulin),
35 goblet cells (MUC5AC), club-like cells (MUC5B) and endothelial cells (CD31 and CD34).
36 Greater than 90% of infiltrating immune cells were positive for viral proteins including
37 macrophages and monocytes (CD68 and CD163), neutrophils (ELA-2), natural killer
38 (NK) cells (CD56), B-cells (CD19 and CD20), and T-cells (CD3 ϵ). Most but not all
39 infected cells were positive for the viral entry receptor angiotensin-converting enzyme-2
40 (ACE2). The numbers of infected and ACE2-positive cells correlated with the extent of
41 tissue damage. The infected tissues exhibited low numbers of B-cells and abundant
42 CD3 ϵ ⁺ T-cells consisting of mainly T helper cells (CD4), few cytotoxic T cells (CTL,
43 CD8), and no T regulatory cell (FOXP3). Antigen presenting molecule HLA-DR of B and
44 T cells was abundant in all cases. Robust interleukin-6 (IL-6) expression was present in

45 most uninfected and infected cells, with higher expression levels observed in cases with
46 more tissue damage.

47 **Interpretation** In lung tissues from severely affected COVID-19 patients, there is
48 evidence for broad SARS-CoV-2 cell tropisms, activation of immune cells, and
49 clearance of immunosuppressive cells, which could contribute to severe tissue damage,
50 thromboemboli, excess inflammation and compromised adaptive immune responses.

51

52 **Funding** This work used the UPMC Hillman Cancer Center and Tissue and Research
53 Pathology/Pitt Biospecimen Core shared resource, which is supported in part by award
54 P30CA047904 from the National Cancer Institute, and by UPMC Hillman Cancer Center
55 Startup Fund and Pittsburgh Foundation Endowed Chair in Drug Development for
56 Immunotherapy to S.-J. Gao.

57

58 **Keywords**

59 SARS-CoV-2; COVID-19; cell tropism; diffuse alveolar damage; thromboemboli;
60 interleukin-6; inflammation; immunosuppression; immunofluorescence assay;
61 immunohistochemistry

62 **HIGHLIGHTS**

63 We provide an atlas of lung immunopathology of fatal SARS-CoV-2 infections, revealing:

- 64 • Unexpected broad cell tropism and infection of parenchymal, endothelial and
65 immune cells by SARS-CoV-2, which are associated with massive tissue
66 damage and thromboemboli;
- 67 • Clearance of immunosuppressive T-regulatory cells, and suppression of B cells
68 and cytotoxic T cells;
- 69 • Extensive infiltration and activation of immune cells;
- 70 • Pronounced IL-6 expression in all types of infected and uninfected cells.

71 **Research in context**

72

73 **Evidence before this study**

74 Pulmonary symptoms reflected by diffuse alveolar damage (DAD), excess inflammation,
75 pneumocyte hyperplasia and proliferation, formation of platelet aggregates, and
76 thromboemboli are the pathological features of COVID-19. However, the mechanisms
77 mediating these processes have not been elucidated. We searched PubMed up to
78 September 15, 2020 using the keywords “coronavirus disease 2019”, “COVID-19”,
79 “SARS-CoV-2”, “cell tropism”, “cell markers”, “inflammation”, “interleukin 6”, “immune
80 response”, “immune suppression”, “immunofluorescence” and “immunohistochemistry”,
81 with no language restrictions. Single cell RNA sequencing (scRNA-seq) has revealed
82 extensive expression of SARS-CoV-2 receptor angiotensin-converting enzyme-2 (ACE2)
83 in a large variety of cell types. However, only low levels of SARS-CoV-2 infection have
84 been detected in macrophages, neutrophils, type II pneumocytes (AT2), and goblet,
85 club, ciliated and endothelial cells by scRNA-seq and immunohistochemistry. COVID-19
86 blood samples contain high levels of inflammatory cytokines including interleukin-6 (IL-
87 6), high levels of monocytes and neutrophils, and depletion of lymphocytes. There is no
88 information on the cell types infected by SARS-CoV-2 and extent of infection, the
89 precise producing cells of inflammatory cytokines, and the status of immune cells in
90 lungs from fatal COVID-19 patients.

91 **Added value of this study**

92 By multicolor staining for viral proteins and lineage markers in lung tissues from five
93 fatal COVID-19 patients, we reveal SARS-CoV-2 infection in an extensive range of cells
94 including type II pneumocytes (HT2-280), and ciliated (tyr- α -tubulin), goblet (MUC5AC),

95 club-like (MUC5B) and endothelial cells (CD31 and CD34), which is correlated with the
96 extent of DAD and thromboemboli. SARS-CoV-2 infection is found in greater than 90%
97 of infiltrating immune cells, including macrophages and monocytes (CD68 and CD163),
98 neutrophils (ELA-2), natural killer cells (CD56), B-cells (CD19 and CD20), and T-cells
99 (CD3 ϵ). Most but not all infected cells were positive for ACE2. There are abundant
100 macrophages, monocytes, neutrophils and natural killer cells but low numbers of B-cells
101 and abundant CD3 ϵ ⁺ T-cells consisting of mainly T helper cells (CD4), few cytotoxic T
102 cells (CTL, CD8), and no T regulatory cell (FOXP3). Antigen presenting molecule HLA-
103 DR of B and T cells was abundant in all cases. Robust IL-6 expression was present in
104 most uninfected and infected cells, with higher expression levels observed in cases with
105 more tissue damage.

106 **Implications of all the available evidence**

107 In lung tissues from severely affected COVID-19 patients, there is evidence for broad
108 SARS-CoV-2 cell tropisms, hyperactive immune cells, and clearance of immune cells
109 including immunosuppressive cells, which could contribute to severe tissue damage,
110 thromboemboli, excess inflammation and compromised adaptive immune responses.
111 These results have implications for development of treatments.

112

113 **Introduction**

114 Coronavirus Disease 2019 (COVID-19) is a complex disease caused by Severe
115 Acute Respiratory Syndrome Coronavirus-2 (SARS-CoV-2) infection.^{1,2} Multiple organs
116 are affected, and severe lung damage is a prominent finding in fatal cases.³⁻⁶ Although
117 dysregulated immune responses and excess inflammation are commonly observed in
118 the lung tissues from these patients, the precise mechanism underlying the pulmonary
119 pathology remains unclear.⁴

120 Single cell RNA sequencing (scRNA-seq) analysis of lung tissues from healthy
121 subjects have revealed that many cell types express SARS-CoV-2 entry receptor and
122 cofactors including angiotensin-converting enzyme-2 (ACE2), transmembrane serine
123 protease 2 (TMPRSS2), and furin, that are involved in viral entry, suggesting
124 susceptibility of these cells to infection.⁷⁻¹⁰ Furthermore, scRNA-seq analysis of
125 bronchoalveolar lavage fluid (BALF), blood, oropharyngeal or lung tissues from COVID-
126 19 patients has identified different types of SARS-CoV-2-infected cells, including
127 macrophages, neutrophils, type II pneumocytes (AT2), and ciliated and endothelial
128 cells.¹¹⁻¹⁴ However, in general, these studies detected very low numbers of infected
129 cells, which harbored low counts of viral genomes and transcripts.¹¹⁻¹⁶ The reason for
130 the discrepancy between the high numbers of cells expressing viral entry
131 receptors/cofactors and the low numbers of infected cells detected even in COVID-19
132 patients with severe pulmonary disease remains unclear. It has been reported that the
133 expression of ACE2, TMPRSS2 and furin is upregulated in macrophages, neutrophils,
134 AT2 and ciliated cells in COVID-19 patients compared to healthy controls, and that type
135 1 interferons (IFNs) induce the expression of ACE2 in epithelial cells, hence increasing

136 their susceptibility to infection.^{17,18} However, a recent study showed that type 1 IFNs
137 only induced the expression of an ACE variant but not the ACE2 involved in viral
138 entry.¹⁹ Furthermore, although immunohistochemistry (IHC) staining of lung tissues with
139 antibodies detected SARS-CoV-2 spike (S1) protein or nucleocapsid (NC) protein in
140 macrophages (cluster of differentiation 68⁺, CD68⁺ and CD183⁺), and AT2, ciliated,
141 goblet, club and endothelial progenitor cells, the infected cells were often observed at
142 low numbers, and the exact identity of many infected cells remain unknown.²⁰⁻²⁴
143 Questions remain regarding the SARS-CoV-2 targeted cell types, the percentages of
144 the cells that are infected, and whether the extent of infection is correlated with the
145 expression of viral entry factors and disease status.

146 Interleukin-6 (IL-6) is one of the most abundant cytokines detected in COVID-19
147 patients.²⁵ The expression level of IL-6 has been correlated with patient prognosis.²⁶⁻²⁸
148 Treatment with IL-6 antagonists improved the survival and shortened the recovery
149 time.²⁹⁻³³ However, the cell types responsible for increased IL-6 expression in the lung
150 are poorly defined, and understanding the relationship among IL-6 expression, the
151 extent of SARS-CoV-2 infection, and disease severity is incomplete.

152 In this study, we analyzed the expression of SARS-CoV-2 S1 and NC proteins in
153 postmortem lung tissues from five severe COVID-19 patients with various degrees of
154 lung damage. We performed multicolor immunofluorescence staining (IF) for the SARS-
155 CoV-2 proteins, ACE2 protein as well as for lineage-restricted cell markers. We found
156 broad and extensive SARS-CoV-2 infection in the lungs of these patients, and more
157 infected cells were observed in more severe cases. Infected immune cell types were
158 comprised of monocytes and macrophages (CD68⁺ or CD163⁺), neutrophils (ELA-2⁺),

159 and natural killer (NK) (CD56⁺), B (CD20⁺), and T (CD3ε⁺, CD4⁺ and CD8⁺) cells,
160 including activated B and T (HLA-DR⁺) cells with many having near 100% of infection in
161 severe cases. To our knowledge, this is the first direct visualization by IHC and IF of
162 SARS-CoV-2 infection of neutrophils and different T cell subtypes. We simultaneously
163 detected SARS-CoV-2 infection and ACE2 expression in AT2 pneumocytes, and club-
164 like, goblet and endothelial cells. Finally, we found wide spread IL-6 expression in lung
165 parenchyma involving most of the cells and cell types regardless of individual cell
166 infection status.

167

168 **Methods**

169 **COVID-19 lung tissue samples**

170 Anonymized postmortem specimens were collected from five adults (4 male and
171 1 female) with fatal SARS-CoV-2 infection by the Autopsy Service of the Department of
172 Pathology, Molecular and Cell-based Medicine at the Icahn School of Medicine at
173 Mount Sinai. All 5 patients had been admitted because of symptomatic COVID-19 and a
174 positive nasopharyngeal swab test for SARS-CoV-2 by real-time reverse-transcription
175 polymerase-chain-reaction amplification (RT-PCR, cobas® 6800 system,
176 RocheDiagnostics). Other clinical-pathologic findings are summarized in table S1. All
177 autopsies were performed with written consent from the legal next-of-kin, and
178 specimens were obtained per the Autopsy Service protocol.

179 Specimens obtained at autopsy do not meet the definition of a living individual
180 per Federal Regulations 45 CFR 46.102, and as such, research using specimens
181 obtained at autopsy does not meet the requirements for Institutional Review Board

182 review or oversight under the Icahn School of Medicine Program for the Protection of
183 Human Subjects. In addition, the Institutional Review Board of the University of
184 Pittsburgh determined that the study is not research involving human subjects as
185 defined by DHHS and FDA regulations and waived of ethical oversight
186 (STUDY20050085).

187

188 **Hematoxylin-eosin (H&E) staining, immunohistochemistry (IHC), and**
189 **immunofluorescence assay (IF)**

190 Postmortem biopsies were fixed with 10% neutral buffered formalin and
191 embedded in paraffin. Slides were stained with H&E for histological analyses. For IHC
192 single staining (CD3, CD4, CD8, CD45, CD19, CD20 and FOXP3), the slides were
193 deparaffinized at 60°C for 30 min and rehydrated using a standard histology protocol of
194 3 changes of xylene of 5 min each followed by 3 changes of ethanol 100%, 2 of ethanol
195 95% and 1 ethanol 70% for 1 min each, then rinsed in distilled water. Antigen retrieval
196 was performed using citrate buffer (#S1699, Agilent Dako) in Decloaking chamber at
197 123°C for 2 min. The slides were stained using an Autostainer Plus (Agilent Dako)
198 platform with TBS-T rinse buffer (#S3306, Agilent Dako). The IHC slides were treated
199 with 3% hydrogen peroxide for 10 min. The primary antibodies were applied at room
200 temperature for 30 min, followed by 30 min of secondary antibody Envision + Dual Link
201 (# K4061, Agilent Dako) HRP polymer at room temperature. Slides were exposed to 3,3,
202 Diaminobenzidine+ (# K3468, Agilent Dako) for 5 min, and counterstained with
203 Hematoxylin (#K8018, Agilent Dako). For IF, slides were deparaffinized at 95°C for 10
204 min, followed by 3 washes of xylene for 5 min. Dehydration was performed with step-

205 wise 10 min incubation of ethanol 100%, 95% and 75%, followed by water. Antigen
206 retrieval used citrate buffer pH 6.0 on microwave for 3 min at maximum potency,
207 followed by 15 min with 30% potency, and cooled down for 30 min at room temperature.
208 Slides were treated for 1 h with 5% bovine serum albumin (BSA) solution. Primary
209 antibodies were incubated overnight at 4°C, and secondary antibodies were incubated
210 for 1 h at room temperature. Slides were treated with Vector TrueVIEW™
211 autofluorescence quenching (#SP-8400, Vector Laboratories) for 5 min followed by
212 incubation with 4',6-diamidino-2-phenylindole (DAPI) for 10 min. Table S2 summarizes
213 all antibodies and dilutions used in the study.

214

215 **Results**

216 All five cases showed various combinations of DAD, pulmonary thromboemboli
217 and pulmonary consolidation (table S1, figure 1A and S1A). Case 4 had the most
218 extensive and severe pathologic changes, including early exudative phase of DAD,
219 vascular congestion and rare hyaline membranes. Air-spaces filled with blood were
220 noted in cases 1, 2 and 4. The least dramatic changes were found in cases 2 and 3;
221 both had incidental anthracosis. These findings are in agreement with previous
222 descriptions of lung pathology in COVID-19 cases.^{6,21,34}

223 Evidence of SARS-CoV-2 infection was detected by IHC with antibodies against
224 the S1 protein receptor binding domain (RBD) and NC protein. All 5 cases were positive
225 for SARS-CoV-2 proteins (figure 1B and S1B) with the widest distribution of infected
226 cells observed in tissues from case 4 followed by cases 1 and 5. The fewest infected
227 cells were observed in lung tissues from cases 2 and 3. Tissue damage was

228 widespread in all cases. Case 5 had the most structurally preserved tissue specimen
229 with infected cells present in patches, rather than throughout the lung specimen.
230 Consistent with the detection of viral proteins, in all cases the ACE2 protein, the main
231 receptor for SARS-CoV-2^{35,36}, was widely detected in different cell types including
232 immune cells comprised of monocytes, macrophages, neutrophils and lymphocytes
233 (figure 1C and S1C). The extent of ACE2 protein expression correlated with that of
234 SARS-CoV-2 infection with cases 2 and 3 having the lowest numbers of cells
235 expressing ACE2 protein (figure S1C).

236 Infiltration of immune cells is a common sequel to infection. We identified
237 immune cells by staining for different cell markers by IHC. Cells positive for CD45
238 (leukocyte common antigen, LCA), a marker for most hematopoietic cells, was highly
239 abundant in all cases (figure 1D and S2C). Abundant infiltrating monocytes and
240 macrophages were detected in all cases using CD68 as a monocyte, pan-macrophage
241 or M1 marker, and CD163 as a M2 cell marker. CD68⁺ cells were more abundant than
242 CD163⁺ cells (figure 1D and S2A).

243 We identified B cells by staining for CD19 and CD20. Although there was a
244 paucity of CD19⁺ cells, lung tissues from cases 1 and 2 showed pockets of infiltrating
245 CD20⁺ cells, which appeared to be surrounding venous structures (figure 1D and S2B).
246 Infiltration by T cell receptor (TCR) CD3ε⁺ cells, predominantly T CD4⁺ helper, and
247 fewer T CD8⁺ cytotoxic cells, was detected in all cases (figure 1D and S2C). Interesting,
248 all cases were negative for FOXP3, a marker for natural T regulatory (Treg) cells (figure
249 1D and S2C).

250 Since ACE2 protein expression was correlated with SARS-CoV-2 infection (figure
251 1B-C, and S1B-C), we performed dual IF staining for ACE2 and SARS-CoV-2 S1
252 protein (figure 2A and S3). Most infected cells expressed ACE2 protein but we also
253 observed some ACE2-negative infected cells, which could be due to low expression
254 level of ACE2 protein outside the detection range of the assay, downregulation of ACE2
255 protein expression at some stage(s) of SARS-CoV-2 infection, virus cell-to-cell spread,
256 or presence of an alternative SARS-CoV-2 receptor. Consistent with our IHC findings,
257 lung tissue specimens displaying a broader range of SARS-CoV-2-infected cell types,
258 also had more ACE2-positive cells (figure S3). Cases 2 and 3 had the lowest numbers
259 of ACE2-positive cells and the least infected cells.

260 Since we observed extensive damage to lung tissues (figure 1A and S1A), we
261 performed triple-color staining for SARS-CoV-2 and ACE2 proteins in lung parenchymal
262 cells including AT2 cells, ciliated cells (tyr- α -tubulin), goblet cells (MUC5AC), and club-
263 like cells (MUC5B) in order to evaluate these cell types for viral infection (figure 2B-E
264 and S4A-D). AT2 cells, which have been reported to be a major target of SARS-CoV-2
265 infection in lung tissues¹⁷, were shown both to express ACE2, and to be infected by
266 SARS-CoV-2 (figure 2B and S4A). In sections of lung tissues from cases 2 and 3, AT2
267 cells were noted to have intact cell membranes, and less extensive infection by SARS-
268 CoV-2. In contrast, in case 4, more extensive SARS-CoV-2 infection of AT2 cells was
269 observed, along with ruptured cell membranes, possibly related to viral shedding (figure
270 S4A).

271 Tyr- α -tubulin was used as a microtubule marker for identifying ciliated cells
272 among others. SARS-CoV-2 extensively infected cells expressing tyr- α -tubulin,

273 including ciliated cells identified by their morphology, in lung tissues from all cases
274 (figure 2C and S4B).

275 The predominant mucins expressed in the lung are MUC5AC, mainly found in
276 goblet cells, and MUC5B, mostly expressed in club-like cells. Both MUC5AC⁺ and
277 MUC5B⁺ cells were infected by SARS-CoV-2 and expressed ACE2 (figure 2D-E and
278 S4C-D). MUC5B⁺ cells were more abundant than MUC5AC⁺ cells. Previous studies
279 have shown SARS-CoV-2 infection of small number of vascular endothelial cells in lung
280 tissues from COVID-19 patients.³⁷ We observed extensive SARS-CoV-2 infection and
281 damage in CD34⁺ or CD31⁺ endothelial cells (figure 2F-G and S5A-B), which might be
282 the cause of widespread microhemorrhages and infarction observed in these tissues.

283 Since we detected vast infiltrations by innate immune response cells, we
284 examined SARS-CoV-2 infection in these cells. Monocytes and macrophages (CD68⁺ or
285 CD163⁺) were widely infected by SARS-CoV-2 (figure 3A, B and E, and S6A-B).
286 Neutrophils, positive for elastase-2 (ELA-2⁺) protein, were extensively infected by
287 SARS-CoV-2 (figure 3C and E, and S6C). The extent of neutrophil infection was
288 positively correlated with ACE2 protein expression in all cases except for tissues from
289 case 5, for which 96% of cells expressed ACE2, but only 19% had detectable SARS-
290 CoV-2 infection (figure 3E). We detected SARS-CoV-2 infection in NK cells (CD56⁺)
291 (figure 3D and S6D); however the percentages of infected cells were much smaller than
292 other cell types examined, ranging from 0 to 40% (figure 3E).

293 Among the adaptive immune cells, B cells (CD20⁺) were found in low numbers in
294 the lung specimens, but ACE2 protein expression and SARS-CoV-2 infection were
295 positively correlated in these cells (figure 4A and F, and S7). Different types of T-cells

296 expressing CD4 (figure 4B and F, and S8A), CD8 (figure 4C and F, and S8B) and CD3ε
297 (figure 4D and F, and S8C) all co-stained with SARS-CoV-2 NC protein. In addition,
298 HLA-DR, a marker of activated B and T cells, co-stained with SARS-CoV-2 NC protein
299 (figure 4E and F, and S8D). Interestingly, CD4⁺, CD8⁺ or CD3ε⁺ T cells presented either
300 as a membrane-associated pattern or as a dot-like organization pattern, possibly as the
301 result of membrane rupture following SARS-CoV-2 infection (figure S8E).

302 IL6 is one of the most abundant cytokines detected in COVID-19 patients and its
303 level is correlated with prognosis.²⁵⁻²⁸ In lung tissues from all 5 cases, we found
304 expression of IL-6 in almost all cells examined, with or without SARS-CoV-2 infection
305 (figure 5A-B and S9A-B). In general, the expression of IL6 was positively correlated with
306 the number of infected cells (figure S9A).

307

308 **Discussion**

309 Respiratory symptoms are a prominent complaint during most SARS-CoV-2
310 infections, and progressive respiratory dysfunction is a major feature of severe COVID-
311 19.^{1,2,6,38} The results of our study present a direct visualization of the multiple cell types
312 infected by SARS-CoV-2 from patients who died of COVID-19, and offer insight into the
313 pathogenesis of the overwhelming damage found in lung tissues in fatal COVID-19
314 cases.

315 The expression of viral S1 or NC protein, as demonstrated by IHC and IF,
316 indicated widespread SARS-CoV-2 infection in lung tissues, including multiple lung
317 parenchymal cell types and multiple cell types involved in the immune response. These
318 SARS-CoV-2 proteins were most abundant in specimens with the most histologic

319 evidence of tissue damage. As expected, the extent of infection was positively
320 correlated with the expression level of ACE2 protein. Notably, we also found SARS-
321 CoV-2 infection in ACE2-negative cells, supporting a role for other possible receptors
322 for viral entry into ACE-negative cells.

323 It is important to note that there may be multiple factors that might influence
324 ACE2 expression during SARS-CoV-2 infection and should be considered as
325 confounders. For example, ACE2 expression can be stimulated by IFNs.^{17,18}
326 Furthermore, ACE2 may have a role in protection against severe acute lung failure, as
327 has been reported in severe COVID-19 patients.³⁹

328 We obtained direct evidence for widespread expression of ACE2 and extensive
329 infection by SARS-CoV-2 among different cell types using multicolor IF staining for
330 SARS-CoV-2 and ACE2 proteins in different pulmonary parenchymal and immune cells.
331 Among lung parenchymal cells that were both ACE2-positive and SARS-CoV-2-infected
332 included AT2 (HT2-280), ciliated (Tyr- α -tubulin), goblet (MUC5AC), club-like (MUC5B)
333 and vascular endothelial cells (CD31⁺ or CD34⁺). Our findings are consistent with recent
334 studies showing SARS-CoV-2 infection of ciliated, goblet and club cells by RNA-*in situ*
335 hybridization (ISH);⁴⁰ and infection of pneumocytes, ciliated, secretory and
336 lymphomononuclear cells by IHC^{23,41} in lung tissues from COVID-19 patients. In *ex-vivo*
337 culture, SARS-CoV-2 has been found to infect type I pneumocytes, ciliated, goblet and
338 club cells as well as conjunctival mucosa.²²

339 We detected ACE2 protein expression in different immune cells including CD68⁺
340 and CD163⁺ monocytes and macrophages, ELA-2⁺ neutrophils, CD56⁺ NK cells, and B-
341 and T-cells; these findings are consistent with previous reports based on scRNA-seq

342 studies.⁷⁻¹⁰ ACE2 expression detected by flow cytometry in T cells from lung tissues
343 from COVID-19 patients has been reported by others.⁴² Notably, we found rates of
344 SARS-CoV-2 infection approaching 100% for most types of immune cells, in contrast to
345 a much lower infection rate in NK cells (figure 3E and 4F). Although previous studies
346 have reported detection of SARS-CoV-2 proteins in macrophages by IHC,^{20,43} to our
347 knowledge, our study is the first to demonstrate and quantify SARS-CoV-2 infection in
348 different types of T cells and also in neutrophils. Our observation of SARS-CoV-2
349 infection of neutrophils was in contrast to the results of a recent study, which failed to
350 detect any infected neutrophils.⁴²

351 We simultaneously identified SARS-CoV-2-infected and ACE2-expressing cells
352 in different parenchymal and immune cells in lung tissues from COVID-19 patients by
353 multicolor staining. These observations are significant because infiltration and infection
354 of immune cells such as macrophages are suggested as critical steps in the spread of
355 SARS-CoV-2 infection to other organs^{44,45} and in the initiation of uncontrolled
356 inflammatory responses.⁴⁶ Furthermore, we have observed SARS-CoV-2 infection and
357 damage of vascular endothelial cells together with the vast inflammatory infiltrations.
358 These evidences of endothelitis and direct viral injury suggest that endothelial cell
359 dysfunction plays an important role in the genesis of thromboembolic events in SARS-
360 CoV-2 infection.

361 SARS-CoV-2 infection has been proposed to cause compromised immune
362 response by dysregulating the recruitment of immune cells.⁴⁷⁻⁴⁹ It has been reported
363 that decreased levels of CD4⁺ and CD8⁺ T cells were associated with worsening
364 COVID-19 outcomes,^{48,50-52} and there was evidence of activation of CD8⁺ T and NK

365 cells as well as exhaustion of T cells in the lung tissues from COVID-19 patients,⁵³⁻⁵⁶ all
366 of which could contribute to the increased proinflammatory or anti-inflammatory
367 cytokines. In the lung tissues examined in this study, we noted a low level of CD20⁺ B-
368 cells, and a lower level of CD8⁺ T as compared to CD4⁺ T cells. These results
369 suggested a general immunosuppression in the lungs of COVID-19 patients. Most of the
370 inflammatory infiltrates were characterized as CD68⁺, CD163⁺ and CD45⁺ cells. By
371 contrast, we did not detect any FOXP3⁺ Treg cells, potentially supporting the T cell
372 exhaustion theory,⁵⁴⁻⁵⁶ and the lack of Treg cells as a mechanism leading to failed
373 control of inflammatory cells and the excess inflammation observed in COVID-19
374 patients.

375 The inflammatory cytokine IL-6 is highly expressed in COVID-19 patients, and
376 elevated IL-6 levels have been associated with poor prognosis.²⁵⁻²⁸ However, the
377 source of IL-6 in COVID-19 patients remains unclear. We detected a broad, increased
378 IL-6 expression in all cell types and in lung specimens from all the cases we examined,
379 and IL-6 expression could be correlated with the detection of SARS-CoV-2 proteins, as
380 well as with the degree of tissue damage. Of note, our findings are consistent with
381 previous studies reporting that patients with a high level of IL-6 and a poor prognosis
382 also had decreased CD8⁺ T, NK and Treg cells.^{53,54,57}

383 In summary, we performed a systematic analysis of SARS-CoV-2 infection in the
384 postmortem lung tissues from patients with fatal COVID-19, providing an atlas of lung
385 immunopathology of the disease. We found a broad tropism of SARS-CoV-2 infection in
386 pulmonary parenchymal and immune cells. Finally, we observed evidence of activation
387 of immune cells, exhaustion of B- and T-cells, and complete depletion of immune

388 suppressive Treg cells, potentially contributing to the failure to modulate immune cell
389 activation and response as well as inflammation. Further studies are required to
390 delineate the mechanisms of SARS-CoV-2-triggered chemoattraction and immune
391 exhaustion in the lungs of COVID-19 patients.

392

393 **Contributors**

394 SJG conceived and designed the study. SRDS, EGJ and WM designed and performed
395 the experiments. AEP, CB, ZG, MF, EMS and CCC collected clinical specimens and
396 data. SD examined immunohistochemistry results. AG carried out part of
397 immunohistochemistry. SRDS, EGJ, WM, HG and SJG contributed to data
398 interpretation. SRDS and SJG wrote the first draft of the manuscript. All authors critically
399 reviewed the manuscript, and approved the final manuscript for submission.

400

401 **Declaration of interests**

402 We declare no competing interests.

403

404 **Acknowledgments**

405 We thank Drs. Yuan Chang and Patrick Moore for their insightful comments and
406 suggestions, Elaine V. Byrnes and Paul Knizner in the Pitt Biospecimen Core for the
407 technical support. This work used the UPMC Hillman Cancer Center and Tissue and
408 Research Pathology/Pitt Biospecimen Core shared resource, which is supported in part
409 by award P30CA047904. This study was supported by UPMC Hillman Cancer Center

- 410 Startup Fund and Pittsburgh Foundation Endowed Chair in Drug Development for
- 411 Immunotherapy to S.-J. Gao.

412 **FIGURE LEGENDS**

413 **Figure 1: Representative hematoxylin-eosin (H&E) and immunohistochemistry**
414 **(IHC) staining images of SARS-CoV-2 proteins and markers of immune cells in**
415 **lung tissues from two COVID-19 patients**

416 Shown are H&E images illustrating significant areas of lung tissues (Panel A, case 2 in
417 left images and case 4 in right images). An image of case 2 showing lung parenchyma
418 with hemorrhagic infarct in top image (100x). A Langhans giant cell is visible in bottom
419 image (asterisk, 600x). An image of case 4 with an early exudative phase of DAD,
420 vascular congestion and rare hyaline membranes in top image (black arrow, 100x), and
421 infiltrations of lymphocytes (white arrow) and macrophages (red arrow) in bottom image
422 (600x). Shown are IHC detection of SARS-CoV-2 infection using antibody against spike
423 protein (receptor binding domain, RBD) and NC protein (100x) (Panel B, case 2 in left
424 images and case 4 in right images). A macrophage infected by SARS-CoV-2 is visible in
425 case 2 bottom image (black arrow, 600x). Case 2 has less positive cells compared to
426 case 4 for both viral proteins. Shown are IHC detection of ACE2 protein expression in
427 lung tissues (Panel C, case 2 in left images and case 4 in right images). Immune cells
428 identified in case 2 in bottom image are a monocyte (black arrowhead), a macrophage
429 (black arrow) and a neutrophil (red arrowhead), all expressing ACE2 protein (600x).
430 Shown are IHC detection of markers of immune cells in a lung tissue from a COVID-19
431 patient (case 3) consisting of monocytes and macrophages (CD68⁺ and CD163⁺), B
432 cells (CD19⁺ and CD20⁺), different markers of T cells including T cell receptor (CD3ε⁺),
433 T regulatory cell (FOXP3), helper T cell (CD4⁺), cytotoxic T cell (CD8⁺), and lymphocyte
434 common antigen (CD45⁺) (100x, Panel D).

435

436 **Figure 2: Representative images of multicolor immunofluorescence staining of**

437 **ACE2, SARS-CoV-2 proteins and cellular markers in lung tissues from COVID-19**

438 **patients**

439 Shown are ACE2 protein (pseudo color red) and SARS-CoV-2 S1 protein (RBD, pseudo

440 color green) in case 4 (Panel A); Alveolar epithelial type II / pneumocytes type II cells

441 (AT2) (pseudo color green), ACE2 (pseudo color red) and SARS-CoV-2 S1 protein

442 (RBD, pseudo color white) in case 5 (Panel B); Tyr- α -tubulin (pseudo color red) and

443 SARS-CoV-2 NC protein (pseudo color green) in case 5 (Panel C); MUC5AC (goblet

444 cells, pseudo color green), ACE2 (pseudo color red) and SARS-CoV-2 S1 protein (RBD,

445 pseudo color white) in case 4 (Panel D); MUC5B (club-like cells, pseudo color green),

446 ACE2 (red) and SARS-CoV-2 S1 protein (RBD, pseudo color white) in case 4 (Panel E);

447 CD34 (pseudo color green), ACE2 (red) and SARS-CoV-2 NC protein (pseudo color

448 white) in case 5 (Panel F); and CD31 (pseudo color red) and SARS-CoV-2 NC protein

449 (pseudo color green) in case 1. Nuclei were stained with DAPI (pseudo color blue)

450 (Panel G).

451

452 **Figure 3: Representative images of multicolor immunofluorescence staining of**

453 **ACE2, SARS-CoV-2 S1 protein (RBD) and markers of innate immune response**

454 **cells in lung tissues from COVID-19 patients**

455 Shown are CD68, a monocytic lineage marker (pseudo color green), ACE2 (pseudo

456 color red) and S1 protein (pseudo color white) in case 4 (Panel A); CD163, a

457 macrophage M2 marker (pseudo color green), ACE2 (pseudo color red) and S1 protein

458 (pseudo color white) in case 5 (Panel B); Elastase 2 (ELA-2), a neutrophil marker
459 (pseudo color green), ACE2 (pseudo color red) and S1 protein (pseudo color white) in
460 case 4 (Panel C); CD56, a NK cell marker (pseudo color red) and S1 protein (pseudo
461 color green) in case 5 (Panel D). Nuclei were stained with DAPI (pseudo color blue);
462 and quantification of CD68⁺, CD163⁺, ELA-2⁺ and CD56⁺ cells in five different fields in
463 each lung sample from all COVID-19 cases (figure S6). S1-positive and/or ACE2⁺ cells
464 were counted in the same fields and shown as percentages of positive cells (Panel E).

465

466 **Figure 4: Representative images of multicolor immunofluorescence staining of**
467 **ACE2, SARS-CoV-2 NC protein, and markers of B or T cells in lung tissues from**
468 **COVID-19 patients**

469 Shown are CD20, a B cell marker (pseudo color green), ACE2 (pseudo color red) and
470 NC protein (pseudo color white) in case 5 (Panel A); CD4, a T helper cell marker
471 (pseudo color green), ACE2 (pseudo color red) and NC protein (pseudo color white) in
472 case 1 (Panel B); CD8, a cytotoxic T cell marker (pseudo color green), ACE2 (pseudo
473 color red) and NC protein (pseudo color white) in case 1 (Panel C); CD3ε, a T cell
474 receptor marker (pseudo color green), ACE2 (pseudo color red) and NC protein
475 (pseudo color white) in case 1 (Panel D); HLA-DR, a B and T cell activation marker
476 (pseudo color green), ACE2 (pseudo color red) and NC protein (pseudo color white) in
477 case 2 (Panel E); and Quantification of CD20⁺, CD4⁺, CD8⁺, CD3ε⁺ and HLA-DR⁺ cells
478 in five different fields in each lung sample from all COVID-19 cases (figure S7 and 8)
479 (Panel F). NC-positive and/or ACE2⁺ cells were counted in the same fields and shown
480 as percentages of positive cells.

481

482 **Figure 5: Representative images of multicolor immunofluorescence staining of IL-**
483 **6, SARS-CoV-2 S1 protein (RBD), and cellular markers in lung tissues from**
484 **COVID-19 patients**

485 Shown are IL-6 (pseudo color red) and S1 protein (pseudo color green) in case 4 (Panel
486 A); and IL-6 (pseudo color green), and cellular markers CD20 (pseudo color red), CD68
487 (pseudo color red) or CD163 (pseudo color red) in case 1 (Panel B). Nuclei were
488 stained with DAPI (pseudo color blue).

489 References

- 490 1. Huang C, Wang Y, Li X, et al. Clinical features of patients infected with 2019 novel
491 coronavirus in Wuhan, China. *Lancet* 2020; **395**: 497-506.
- 492 2. Zhou P, Yang XL, Wang XG, et al. A pneumonia outbreak associated with a new
493 coronavirus of probable bat origin. *Nature* 2020; **579**: 270-3.
- 494 3. Bryce C, Grimes Z, Pujadas E, et al. Pathophysiology of SARS-CoV-2: targeting of
495 endothelial cells renders a complex disease with thrombotic microangiopathy and
496 aberrant immune response. The Mount Sinai COVID-19 autopsy experience.
497 *medRxiv* 2020.
- 498 4. Mehta P, McAuley DF, Brown M, et al. COVID-19: consider cytokine storm
499 syndromes and immunosuppression. *Lancet* 2020; **395**: 1033-4.
- 500 5. Menter T, Haslbauer JD, Nienhold R, et al. Postmortem examination of COVID-19
501 patients reveals diffuse alveolar damage with severe capillary congestion and
502 variegated findings in lungs and other organs suggesting vascular dysfunction.
503 *Histopathology* 2020.
- 504 6. Xu Z, Shi L, Wang Y, et al. Pathological findings of COVID-19 associated with
505 acute respiratory distress syndrome. *Lancet Respir Med* 2020; **8**: 420-2.
- 506 7. Muus C, Luecken MD, Eraslan G, et al. Integrated analyses of single-cell atlases
507 reveal age, gender, and smoking status associations with cell type-specific
508 expression of mediators of SARS-CoV-2 viral entry and highlights inflammatory
509 programs in putative target cells. *bioRxiv* 2020.
- 510 8. Qi F, Qian S, Zhang S, Zhang Z. Single cell RNA sequencing of 13 human tissues
511 identify cell types and receptors of human coronaviruses. *Biochem Biophys Res
512 Commun* 2020; **526**: 135-40.
- 513 9. Singh M, Bansal V, Feschotte C. A single-cell RNA expression map of human
514 coronavirus entry factors. *bioRxiv* 2020.
- 515 10. Travaglini KJ, Nabhan AN, Penland L, et al. A molecular cell atlas of the human
516 lung from single cell RNA sequencing. *bioRxiv* 2020.
- 517 11. Bost P, Giladi A, Liu Y, et al. Host-Viral Infection Maps Reveal Signatures of
518 Severe COVID-19 Patients. *Cell* 2020; **181**: 1475-88 e12.
- 519 12. He J, Cai S, Feng H, et al. Single-cell analysis reveals bronchoalveolar epithelial
520 dysfunction in COVID-19 patients. *Protein Cell* 2020.
- 521 13. Liao M, Liu Y, Yuan J, et al. Single-cell landscape of bronchoalveolar immune cells
522 in patients with COVID-19. *Nat Med* 2020; **26**: 842-4.
- 523 14. Chua RL, Lukassen S, Trump S, et al. COVID-19 severity correlates with airway
524 epithelium-immune cell interactions identified by single-cell analysis. *Nat
525 Biotechnol* 2020; **38**: 970-9.
- 526 15. Moustafa A, Aziz RK. Traces of SARS-CoV-2 RNA in the Blood of COVID-19
527 Patients. *medRxiv* 2020.
- 528 16. Xiong Y, Liu Y, Cao L, et al. Transcriptomic characteristics of bronchoalveolar
529 lavage fluid and peripheral blood mononuclear cells in COVID-19 patients. *Emerg
530 Microbes Infect* 2020; **9**: 761-70.
- 531 17. Ziegler CGK, Allon SJ, Nyquist SK, et al. SARS-CoV-2 Receptor ACE2 Is an
532 Interferon-Stimulated Gene in Human Airway Epithelial Cells and Is Detected in
533 Specific Cell Subsets across Tissues. *Cell* 2020; **181**: 1016-35 e19.

- 534 18. Zhuang MW, Cheng Y, Zhang J, et al. Increasing host cellular receptor-
535 angiotensin-converting enzyme 2 expression by coronavirus may facilitate 2019-
536 nCoV (or SARS-CoV-2) infection. *J Med Virol* 2020; Jun 4:10.1002/jmv.26139. doi:
537 10.1002/jmv.26139. Online ahead of print.
- 538 19. Onabajo OO, Banday AR, Yan W, et al. Interferons and viruses induce a novel
539 primate-specific isoform dACE2 and not the SARS-CoV-2 receptor ACE2. *bioRxiv*
540 2020.
- 541 20. Adachi T, Chong JM, Nakajima N, et al. Clinicopathologic and
542 Immunohistochemical Findings from Autopsy of Patient with COVID-19, Japan.
543 *Emerg Infect Dis* 2020; **26**.
- 544 21. Best Rocha A, Stroberg E, Barton LM, et al. Detection of SARS-CoV-2 in formalin-
545 fixed paraffin-embedded tissue sections using commercially available reagents.
546 *Lab Invest* 2020.
- 547 22. Hui KPY, Cheung MC, Perera R, et al. Tropism, replication competence, and
548 innate immune responses of the coronavirus SARS-CoV-2 in human respiratory
549 tract and conjunctiva: an analysis in ex-vivo and in-vitro cultures. *Lancet Respir*
550 *Med* 2020; **8**: 687-95.
- 551 23. Schaefer IM, Padera RF, Solomon IH, et al. In situ detection of SARS-CoV-2 in
552 lungs and airways of patients with COVID-19. *Mod Pathol* 2020.
- 553 24. Yao XH, He ZC, Li TY, et al. Pathological evidence for residual SARS-CoV-2 in
554 pulmonary tissues of a ready-for-discharge patient. *Cell Res* 2020; **30**: 541-3.
- 555 25. Han H, Ma Q, Li C, et al. Profiling serum cytokines in COVID-19 patients reveals
556 IL-6 and IL-10 are disease severity predictors. *Emerg Microbes Infect* 2020; **9**:
557 1123-30.
- 558 26. Herold T, Jurinovic V, Arnreich C, et al. Elevated levels of IL-6 and CRP predict the
559 need for mechanical ventilation in COVID-19. *J Allergy Clin Immunol* 2020; **146**:
560 128-36 e4.
- 561 27. Aziz M, Fatima R, Assaly R. Elevated interleukin-6 and severe COVID-19: A meta-
562 analysis. *J Med Virol* 2020.
- 563 28. Ulhaq ZS, Soraya GV. Interleukin-6 as a potential biomarker of COVID-19
564 progression. *Med Mal Infect* 2020; **50**: 382-3.
- 565 29. Campochiaro C, Della-Torre E, Cavalli G, et al. Efficacy and safety of tocilizumab
566 in severe COVID-19 patients: a single-centre retrospective cohort study. *Eur J*
567 *Intern Med* 2020; **76**: 43-9.
- 568 30. Eimer J, Vesterbacka J, Svensson AK, et al. Tocilizumab shortens time on
569 mechanical ventilation and length of hospital stay in patients with severe COVID-
570 19: a retrospective cohort study. *J Intern Med* 2020.
- 571 31. Guaraldi G, Meschiari M, Cozzi-Lepri A, et al. Tocilizumab in patients with severe
572 COVID-19: a retrospective cohort study. *Lancet Rheumatol* 2020; **2**: e474-e84.
- 573 32. Kewan T, Covut F, Al-Jaghbeer MJ, Rose L, Gopalakrishna KV, Akbik B.
574 Tocilizumab for treatment of patients with severe COVID-19: A retrospective cohort
575 study. *EClinicalMedicine* 2020; **24**: 100418.
- 576 33. Luo P, Liu Y, Qiu L, Liu X, Liu D, Li J. Tocilizumab treatment in COVID-19: A single
577 center experience *J Med Virol* 2020; **92**: 814-8.

- 578 34. Carsana L, Sonzogni A, Nasr A, et al. Pulmonary post-mortem findings in a series
579 of COVID-19 cases from northern Italy: a two-centre descriptive study. *Lancet*
580 *Infect Dis* 2020.
- 581 35. Hoffmann M, Kleine-Weber H, Schroeder S, et al. SARS-CoV-2 Cell Entry
582 Depends on ACE2 and TMPRSS2 and Is Blocked by a Clinically Proven Protease
583 Inhibitor. *Cell* 2020; **181**: 271-80 e8.
- 584 36. Shang J, Wan Y, Luo C, et al. Cell entry mechanisms of SARS-CoV-2. *Proc Natl*
585 *Acad Sci U S A* 2020; **117**: 11727-34.
- 586 37. Carnevale S, Beretta P, Morbini P. Direct endothelial damage and vasculitis due to
587 SARS-CoV-2 in small bowel submucosa of COVID-19 patient with diarrhea.
588 *Journal of Medical Virology* 2020; **2020 Jun 3:10.1002/jmv.26119**. doi:
589 **10.1002/jmv.26119**.
- 590 38. Yang X, Yu Y, Xu J, et al. Clinical course and outcomes of critically ill patients with
591 SARS-CoV-2 pneumonia in Wuhan, China: a single-centered, retrospective,
592 observational study. *Lancet Respir Med* 2020; **8**: 475-81.
- 593 39. Imai Y, Kuba K, Rao S, et al. Angiotensin-converting enzyme 2 protects from
594 severe acute lung failure. *Nature* 2005; **436**: 112-6.
- 595 40. Hou YJ, Okuda K, Edwards CE, et al. SARS-CoV-2 Reverse Genetics Reveals a
596 Variable Infection Gradient in the Respiratory Tract. *Cell* 2020; **182**: 429-46 e14.
- 597 41. Pontelli MC, Castro IA, Martins RB, et al. Infection of human lymphomononuclear
598 cells by SARS-CoV-2. *bioRxiv* 2020.
- 599 42. Wang C, Xie J, Zhao L, et al. Alveolar macrophage dysfunction and cytokine storm
600 in the pathogenesis of two severe COVID-19 patients. *EBioMedicine* 2020; **57**:
601 102833.
- 602 43. Martines RB, Ritter JM, Matkovic E, et al. Pathology and Pathogenesis of SARS-
603 CoV-2 Associated with Fatal Coronavirus Disease, United States. *Emerg Infect Dis*
604 2020; **26**: 2005-15.
- 605 44. Middleton EA, He XY, Denorme F, et al. Neutrophil Extracellular Traps (NETs)
606 Contribute to Immunothrombosis in COVID-19 Acute Respiratory Distress
607 Syndrome. *Blood* 2020.
- 608 45. Tomar B, Anders HJ, Desai J, Mulay SR. Neutrophils and Neutrophil Extracellular
609 Traps Drive Necroinflammation in COVID-19. *Cells* 2020; **9**.
- 610 46. Park MD. Macrophages: a Trojan horse in COVID-19? *Nat Rev Immunol* 2020; **20**:
611 351.
- 612 47. Mathew D, Giles JR, Baxter AE, et al. Deep immune profiling of COVID-19 patients
613 reveals distinct immunotypes with therapeutic implications. *Science* 2020.
- 614 48. Qin C, Zhou L, Hu Z, et al. Dysregulation of Immune Response in Patients With
615 Coronavirus 2019 (COVID-19) in Wuhan, China. *Clin Infect Dis* 2020; **71**: 762-8.
- 616 49. Wilk AJ, Rustagi A, Zhao NQ, et al. A single-cell atlas of the peripheral immune
617 response in patients with severe COVID-19. *Nat Med* 2020; **26**: 1070-6.
- 618 50. Chen J, Qi T, Liu L, et al. Clinical progression of patients with COVID-19 in
619 Shanghai, China. *J Infect* 2020; **80**: e1-e6.
- 620 51. Liu Z, Long W, Tu M, et al. Lymphocyte subset (CD4+, CD8+) counts reflect the
621 severity of infection and predict the clinical outcomes in patients with COVID-19. *J*
622 *Infect* 2020; **81**: 318-56.

- 623 52. Chen N, Zhou M, Dong X, et al. Epidemiological and clinical characteristics of 99
624 cases of 2019 novel coronavirus pneumonia in Wuhan, China: a descriptive study.
625 *Lancet* 2020; **395**: 507-13.
- 626 53. De Biasi S, Meschiari M, Gibellini L, et al. Marked T cell activation, senescence,
627 exhaustion and skewing towards TH17 in patients with COVID-19 pneumonia. *Nat*
628 *Commun* 2020; **11**: 3434.
- 629 54. Diao B, Wang C, Tan Y, et al. Reduction and Functional Exhaustion of T Cells in
630 Patients With Coronavirus Disease 2019 (COVID-19). *Front Immunol* 2020; **11**:
631 827.
- 632 55. Jiang Y, Wei X, Guan J, et al. COVID-19 pneumonia: CD8(+) T and NK cells are
633 decreased in number but compensatory increased in cytotoxic potential. *Clin*
634 *Immunol* 2020; **218**: 108516.
- 635 56. Zheng M, Gao Y, Wang G, et al. Functional exhaustion of antiviral lymphocytes in
636 COVID-19 patients. *Cell Mol Immunol* 2020; **17**: 533-5.
- 637 57. Mahmoudi S, Rezaei M, Mansouri N, Marjani M, Mansouri D. Immunologic
638 Features in Coronavirus Disease 2019: Functional Exhaustion of T Cells and
639 Cytokine Storm. *J Clin Immunol* 2020.

640

Figure 1

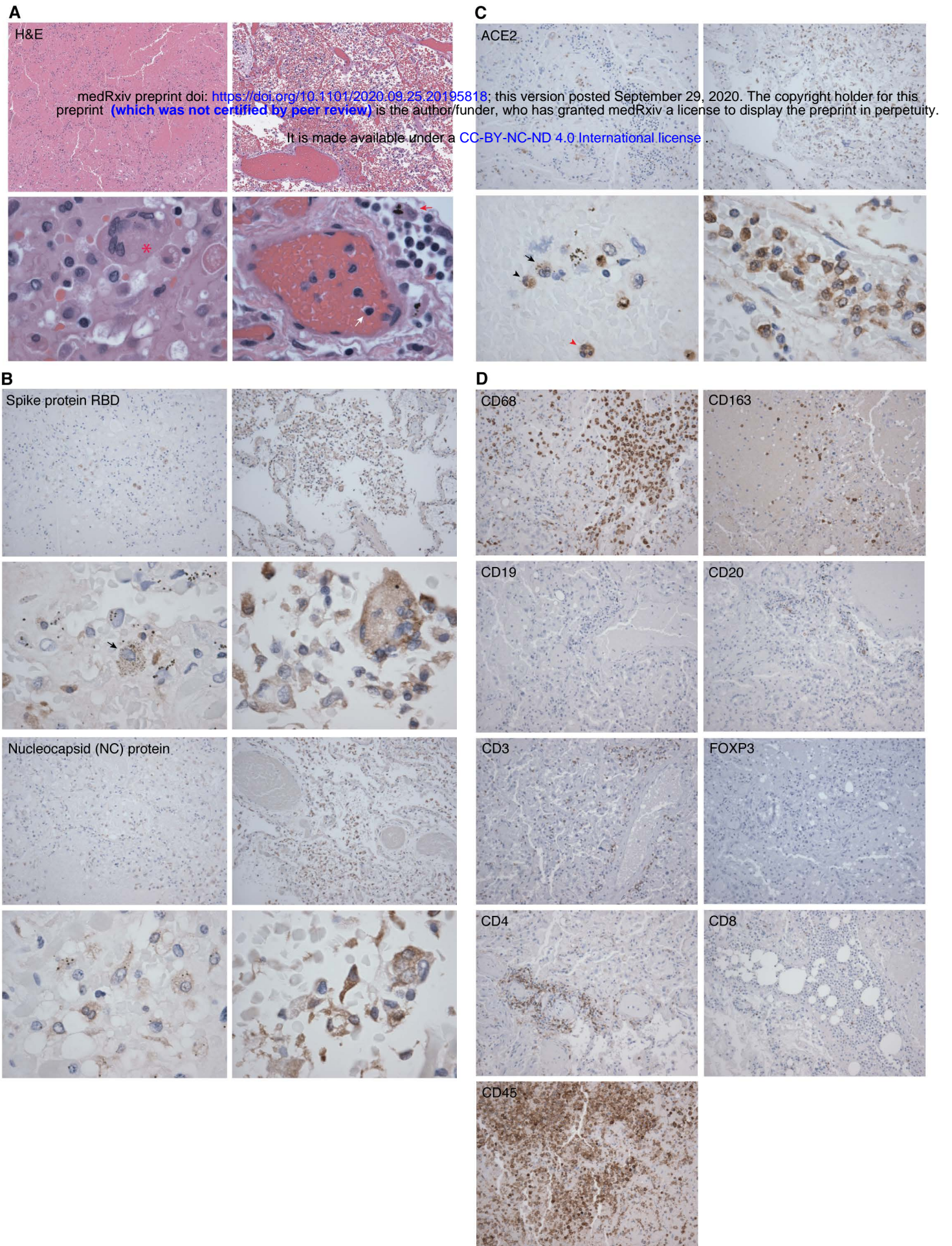
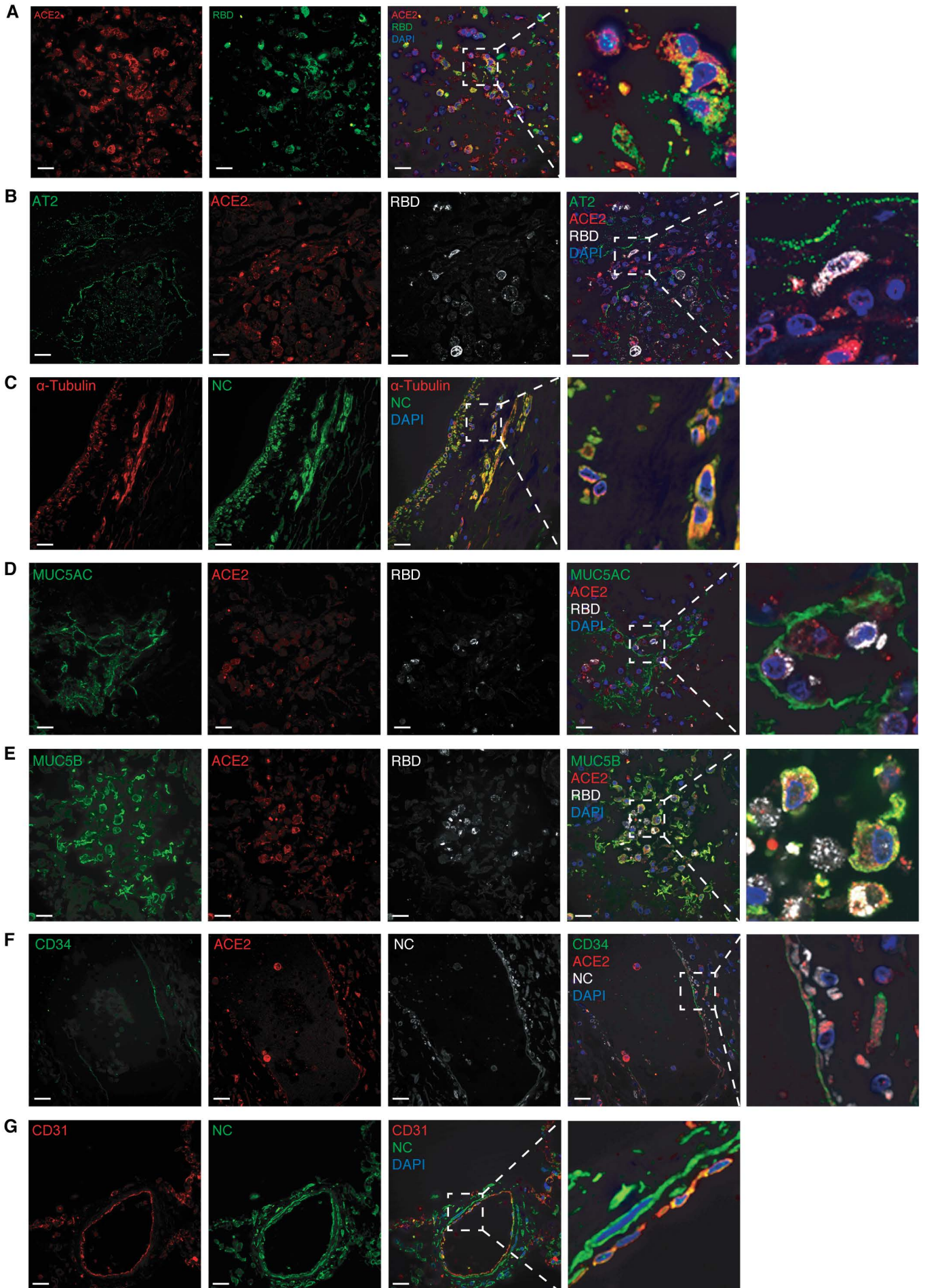


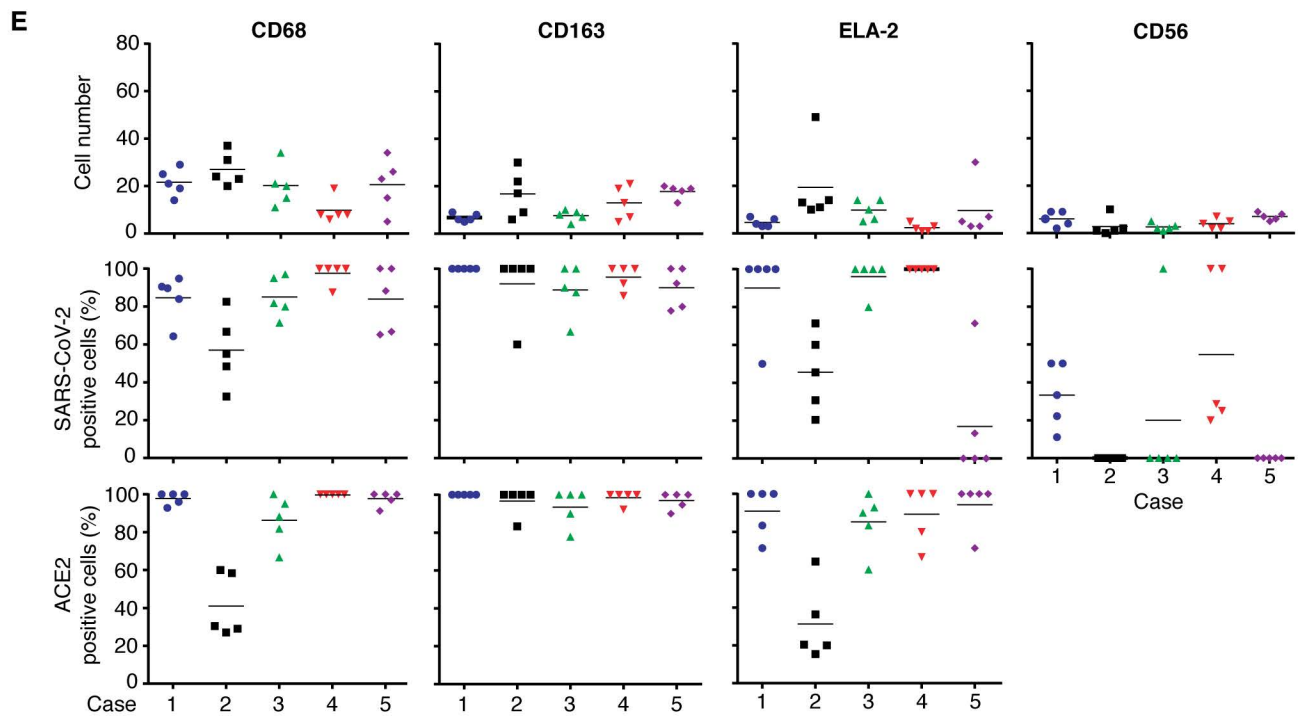
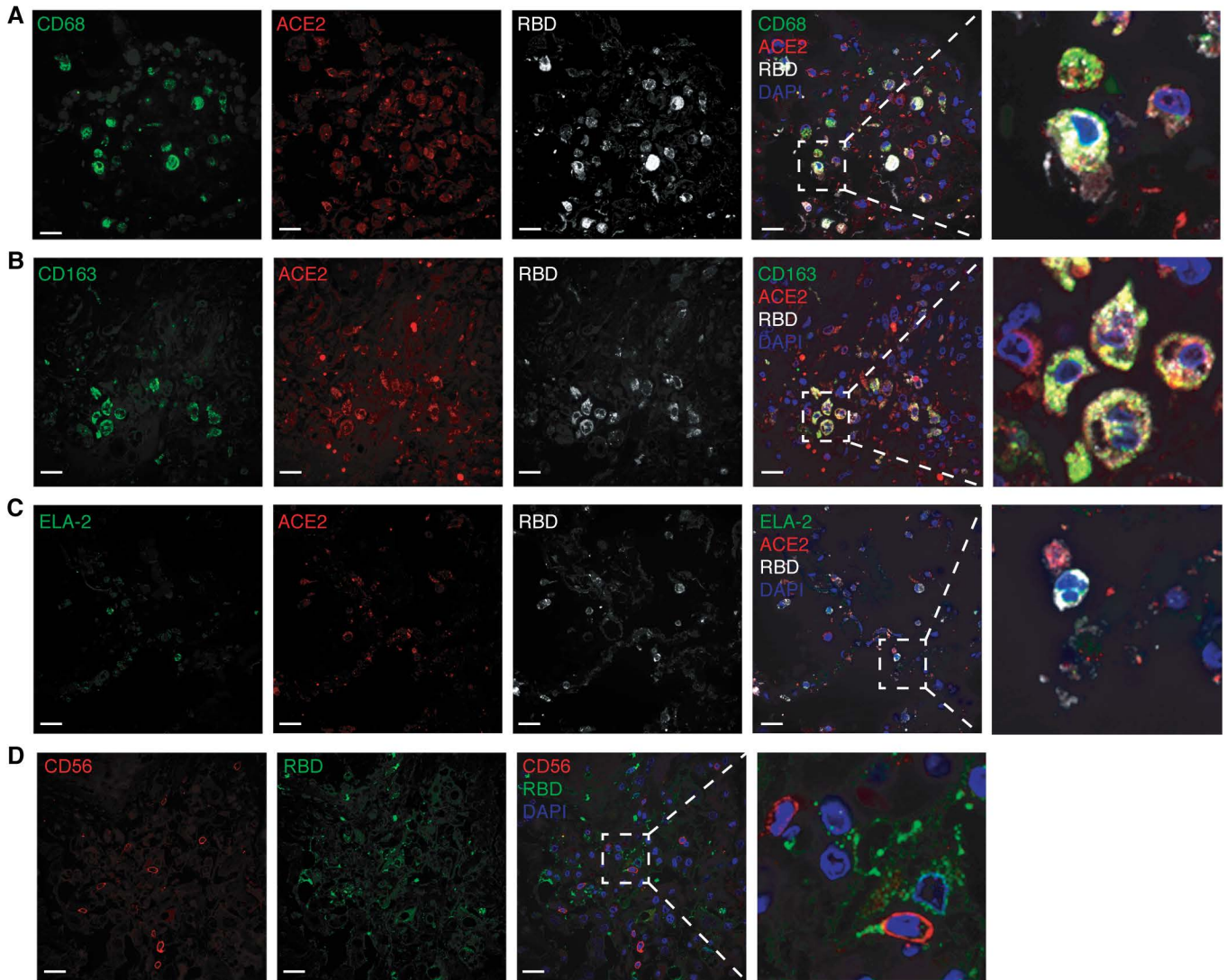
Figure 2

It is made available under a [CC-BY-NC-ND 4.0 International license](https://creativecommons.org/licenses/by-nc-nd/4.0/).



It is made available under a [CC-BY-NC-ND 4.0 International license](https://creativecommons.org/licenses/by-nc-nd/4.0/).

Figure 3



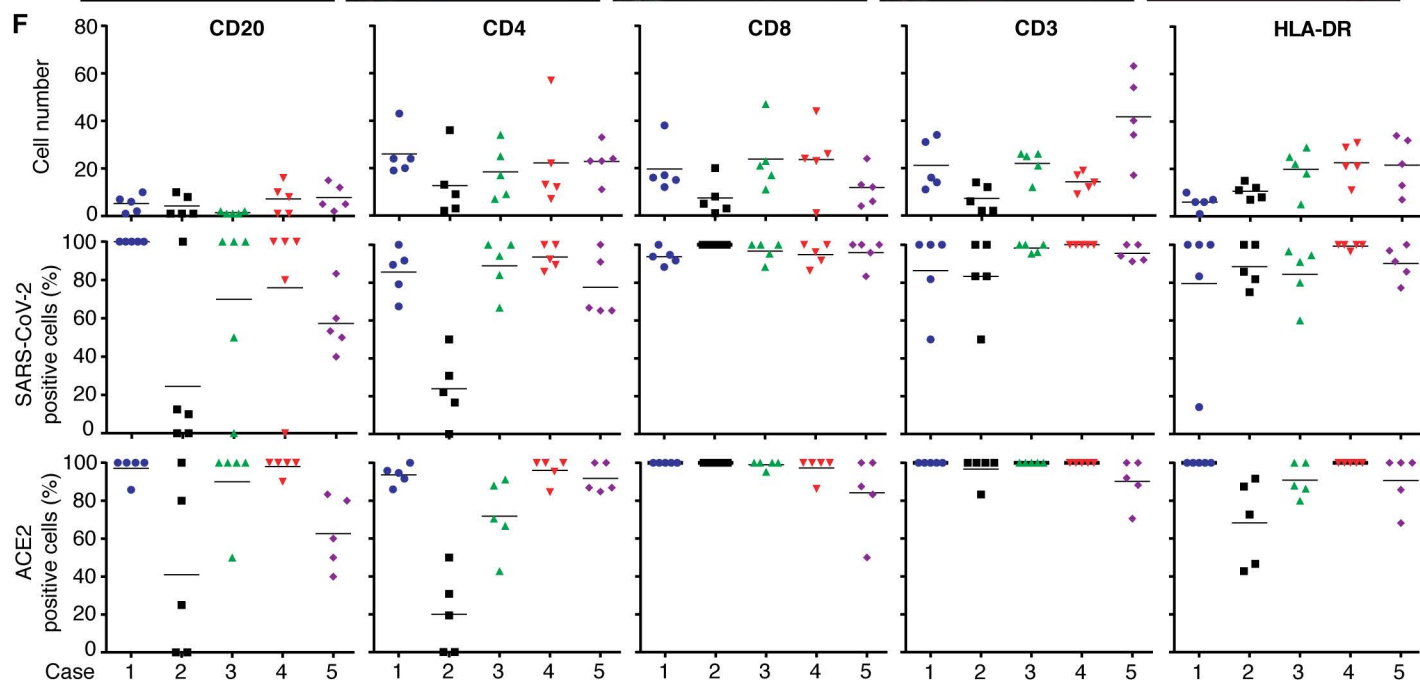
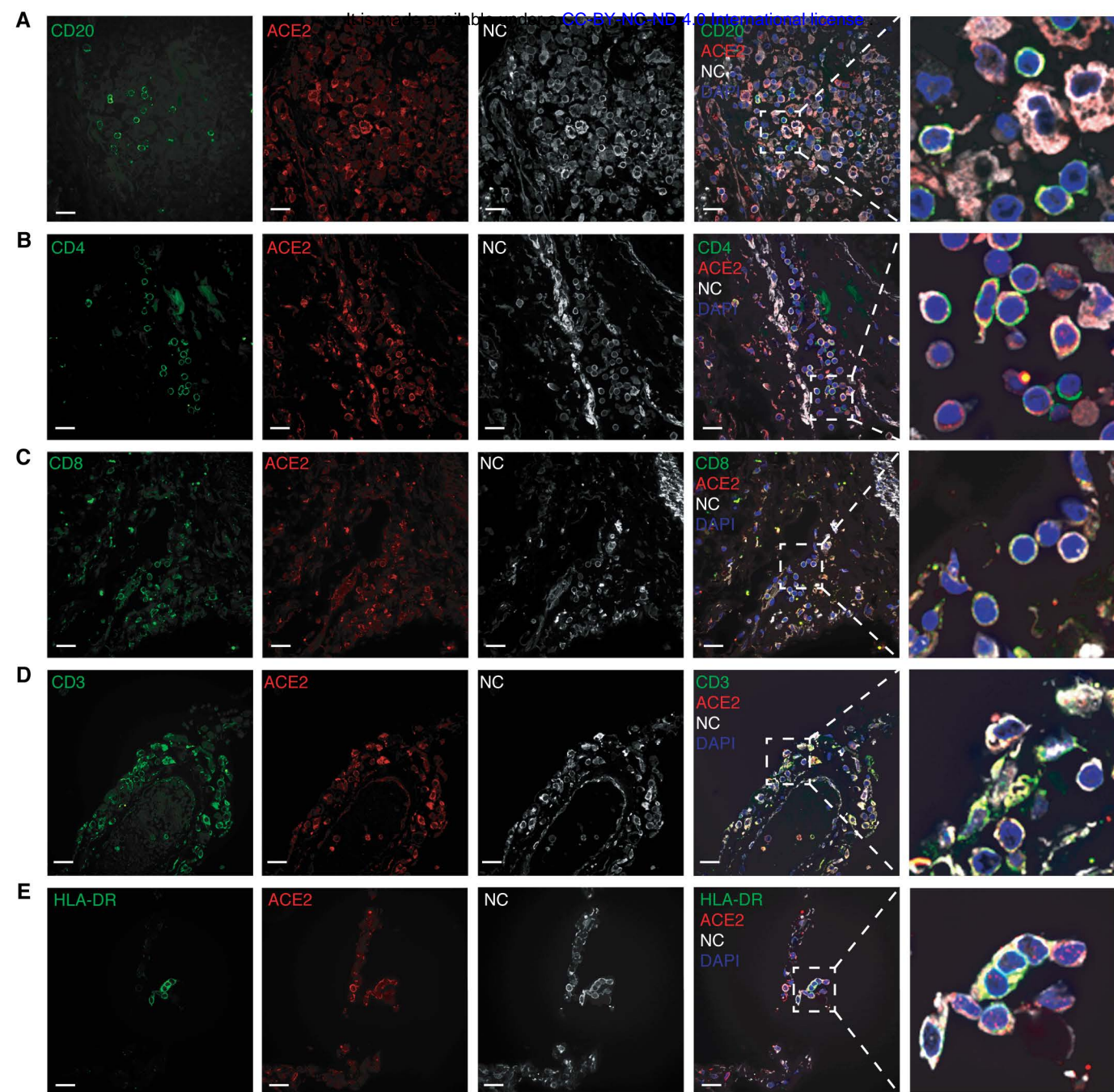


Figure 5

