

Steroid-responsive severe encephalopathy in SARS-CoV-2 infection

Andrea Pilotto^{1,2} MD, Silvia Odolini³ MD, Stefano Masciocchi S¹ MD, Agnese Comelli³ MD, Irene Volonghi¹ MD, Stefano Gazzina⁴ MD, Sara Nocivelli¹ Psy, Alessandro Pezzini¹ MD, Emanuele Focà³ MD, Arnaldo Caruso⁵ MD, Matilde Leonardi⁷ MD, Maria Pia Pasolini⁴ MD, Roberto Gasparotti R⁶ MD, Francesco Castelli F³ MD PhD, Alessandro Padovani¹ MD PhD

¹Neurology Unit, Department of Clinical and Experimental Sciences, University of Brescia, Italy

² Parkinson's Disease Rehabilitation Centre, FERB ONLUS – S. Isidoro Hospital, Trescore Balneario (BG), Italy

³ University Division of Infectious and Tropical Diseases, University of Brescia and ASST Spedali Civili Hospital, Brescia, Italy.

⁴Neurophysiology Unit, ASST Spedali Civili of Brescia, Italy

⁵Microbiology Unit, Department of Molecular and Translational Medicine, University of Brescia and ASST Spedali Civili Hospital, Brescia, Italy.

⁶Neuroradiology Unit, Department of Molecular and Translational Medicine, University of Brescia and ASST Spedali Civili Hospital, Brescia, Italy

⁷Neurology, Public Health, Disability Unit - IRCCS Neurology Institute Besta, Milan, Italy

Corresponding author:

Andrea Pilotto

Neurology Unit, Department of Clinical and Experimental Sciences

University of Brescia

P.zale Spedali Civili, 1 - 25123 Brescia, Italy

Ph. +39-0303995632 Fax +39-0303995027

Email: pilottoandreae@gmail.com

Running Head: Steroid-responsive encephalopathy in COVID-19

Keywords: Encephalopathy, Encephalitis, Akinetic Mutism, Neurology, COVID-19

Word count: 1262 words **Abstract:** 95

References: 20 **Figures:** 2 **Colour figures:** 1

Abstract:

SARS-CoV-2 infection has the potential for targeting central nervous system and several neurological symptoms have been described in patients with severe respiratory distress. Here we described the case of an otherwise healthy 60-year old subject with SARS-CoV-2 infection but only mild respiratory abnormalities who developed severe progressive encephalopathy associated with mild pleocytosis and hyperproteinorrachia. MRI was negative whereas EEG showed theta waves on the anterior brain regions. Serum and CSF analyses excluded other known infectious or autoimmune disorders. The patient dramatically improved after high-doses steroid treatment suggesting an inflammatory-mediated brain involvement related to SARS-CoV-2 infection.

Introduction

Coronavirus disease 2019 (SARS-CoV-2) is characterized by respiratory tract symptoms with possible severe outcome mostly related to pneumonia and acute respiratory distress syndrome¹. Data regarding specific neurological involvement due to SARS-CoV-2 (COVID-19) infections are lacking. Neurological symptoms including headache and delirium have been described in epidemiological studies up to 30% of patients². Although previous coronavirus infections have been associated to involvement of central nervous-system (CNS)³, the neurotropism of COVID-19 is still theme of debate⁴⁻⁶.

The present report describes a case of severe encephalopathy in a patient with COVID-19. During his hospitalization, he never developed severe acute respiratory syndrome (SARS) but mild respiratory symptoms. The patient provided an informed written consent for the report and the diagnostic /therapeutic procedures were conducted in accordance with institutional and international guidelines for protection of human subjects.

Case description

An otherwise healthy 60-year-old man presented to the Emergency Department for a severe alteration of consciousness. According to the relatives, the symptoms started five days earlier with the development of progressive irritability, confusion and asthenia followed two days later by fever, cough and cognitive fluctuations. At admission, his vital parameters were within the normal ranges and his body temperature was 36,8 °C. Oxygen saturation was within normal limits with a slight reduction of the arterial partial pressure of oxygen (SpO₂ 73 mmHg).

The patient displayed an akinetic mutism with a wakeful state of profound apathy; he was able to follow the examiner with the eyes but unable to carry out even simple orders. Beside positive palmomental and glabella reflexes with moderate nuchal rigidity, the neurological examination was normal.

Blood analyses revealed normal blood cell counts, increased D-dimer (968 ng/mL) but normal levels of CRP, fibrinogen and ferritin. Chest x-ray showed moderate bilateral interstitial pneumonia.

Based on the history, the radiological findings and COVID-19 outbreak in the region, a real-time reverse transcriptase-polymerase chain reaction assays (RT-PCR) on nasopharyngeal swab was performed and confirmed a SARS-CoV-2 infection. Antiviral therapy with Lopinavir/Ritonavir 400/100 mg BID and hydroxychloroquine 200 mg BID was started.

A brain CT scan was unremarkable, and the patient was hospitalized. At admission, a lumbar puncture was performed, and CSF showed inflammatory findings with mild lymphocytic pleocytosis (18/uL) and moderate increase of CSF protein (696 mg/dL). The analysis of neurotropic viruses (HSV-1, HSV-2, HSV-6, HSV-8, EBV, VZV and Adenovirus) was negative. CSF RT-PCR for SARS-CoV-2 was also negative. An electroencephalography (EEG) exhibited a generalized slowing, more prominent on the anterior regions with decreased reactivity to acoustic stimuli (Figure 1). The same day an empirical treatment of ampicillin and acyclovir was introduced. The day after, a Brain Magnetic Resonance imaging (MRI) with Gadolinium did not reveal significant alterations or contrast-enhanced areas within brain and/or meninges (Figure 1). Three days after admission, given the persistence of clinical symptoms, a high intravenous steroid treatment was started (methylprednisolone 1 g/day for five days). CSF analyses, carried out one day after steroids administration, showed lymphocytic pleocytosis (18/uL), hyperproteinorrachia (1272 mg/dL) and normal Link index without oligoclonal bands. CSF RT-PCR for SARS-CoV-2 was still negative. The clinical response to steroid therapy was quite impressive. The day after the first infusion, the clinical conditions of the patient improved, and he became alert; he was able to execute simple tasks proposed by examiner and to repeat single words. The following days, the patient was able to talk

and to answer to simple questions. Once the five days-high dose steroid therapy ended, he displayed only mild disinhibition and still fluctuating alertness.

A follow-up MRI nine days after admission was normal while serial EEG revealed improvement and normalization of anterior regions slowness (Figure 1, D). A wide immunological screening of immune-mediated encephalitis (NMDAR, LGI1, CASPR2, GABA_AR, GABA_BR and AMPAR, Ri, Yo, Ma2, Hu, Amphiphysin) was negative as well as anti-MOG antibodies (Supplementary details). Ten days after the admission, there was an improvement of CSF protein (914 mg/dL) but still lymphocytic pleocytosis (38 cells/uL). Oral prednisone was thus started with progressive tapering. At discharge, eleven days after admission, the patients presented with normal neurological examination.

Discussion

The potential neurotropism of COVID-19 with direct or autoimmune-mediated response is still debated^{4-6,7}. We here described a case of steroid-responsive encephalopathy in a patient with confirmed COVID-19 infection.

After the first reports describing severe pneumonia cases in Wuhan, China, COVID-19 rapidly spread worldwide with critical challenges for the health care systems all over the world^{8,9}. The World Health Organization has thus declared COVID-19 a public health emergency of international concern, with a global estimate of 1.153.287 cases and 61.663 deaths on the 4th of April. Brescia, situated in Lombardy region, northern Italy was one of the province more affected by COVID-19 accounting for more the 9,000 cases on the 4th of April 2020.

Epidemiological studies showed that COVID-19 disease presents in the large majority of cases with fever and upper respiratory symptoms². Recently, a study posted in medRxiv⁴ and still unpublished has reported neurological manifestations in COVID-19 in the outbreak in China in up to 36.4% of patients hospitalized, including alteration of consciousness, headache, dizziness and delirium⁶.

Neurological manifestations were also reported in previous epidemiological studies on larger samples². The CNS-potential diffusivity by blood or nasal-pharyngeal route, supported by in vitro models as already described for similar viral agents, is still questioned for COVID-19. Further support for the hypothesis of nasal-pharyngeal route is provided by clinical observations of frequent and persistent anosmia/dysgeusia in COVID-19 infected subjects.

Several authors reported neurological symptoms in severe cases, supporting the concept that CNS symptoms might be secondary to severe respiratory failure⁷.

Another important aspect is the hyperinflammation state secondary to COVID-19 infection, with massive release of cytokines and chemokines that could alter the permeability of blood-brain barrier (BBB). This phenomenon could indeed cause the activation of the neuroinflammation cascade⁵.

Hypothetically, COVID-19 could also induce, by molecular mimicry related mechanisms, the production of antibodies against neural or glial cells, as demonstrated for HSV-1, EBV or Japanese encephalitis¹⁰⁻¹².

The here described COVID-19 case is of particular interest, as the patients presented with severe encephalopathy with only mild respiratory alterations. Meningeal signs at presentation were suggestive for meningoencephalitis and the patient started combined antibiotic and antiviral treatment, according to current guidelines for CNS-infections¹³. Lack of presence of COVID-19 in two different CSF samples analyses could not definitely exclude the diffusion into the CNS, as viruses could enter in CSF and be cleared from it by the time of illness onset, such as in the case of West-Nile virus¹⁴. In our case, the blood brain barrier alterations supported by CSF analyses argue for a potential CNS invasion via blood route of COVID-19³. Of interest, peculiar akinetic mutism presentation has been associated with cases of Epstein-Barr encephalitis¹⁵. However, the normal MRI findings, with no meningeal enhancement or brain alterations, and the response to steroid treatment support other alternative pathophysiological mechanisms. In this case, we excluded the most common causes of autoimmune encephalitis, akinetic mutism and psychosis so far¹⁶⁻¹⁸.

Another possible explanation of transitory akinetic mutism would be an abnormal neuroinflammation response induced by COVID-19¹⁹, already associated with akinetic mutism in adult onset Still syndrome²⁰. This hypothesis better fit with the short time relationship with COVID-19 infection and with the prompt response to steroid treatment.

Conclusions

The case highlighted that COVID-19 may cause severe neurological alterations independently from respiratory function. Despite the unclear pathophysiology, the impressive response to steroid treatment pointed out a possible autoimmune or hyperinflammatory-mediated mechanism but did not exclude a direct CNS-diffusion of COVID-19. The report highlighted the importance for larger studies evaluating neurological manifestations of COVID-19 in order to find out the best management strategies of this growing disease worldwide.

Acknowledgement

We thank the patient for the participation of the case description and follow-up.

Author contribution

Andrea Pilotto: study concept and design, acquisition of data, analysis and interpretation of data, drafting/revising the manuscript for content.

Silvia Odolini: acquisition of data, revising the manuscript for content.

Stefano Masciocchi: acquisition of data, revising the manuscript for content.

Agnese Comelli: acquisition of data, revising the manuscript for content.

Irene Volonghi: acquisition of data, revising the manuscript for content.

Stefano Gazzina: acquisition of data, revising the manuscript for content.

Sara Nocivelli: acquisition of data, revising the manuscript for content.

Alessandro Pezzini: acquisition of data, revising the manuscript for content.

Emanuele Focà: acquisition of data, revising the manuscript for content.

Arnaldo Caruso: acquisition of data, revising the manuscript for content.

Matilde Leonardi: revising the manuscript for content.

Maria pia Pasolini: acquisition of data, revising the manuscript for content.

Roberto Gasparotti: acquisition of data, revising the manuscript for content.

Francesco Castelli: acquisition of data, revising the manuscript for content.

Alessandro Padovani: study concept and design, acquisition of data, revising the manuscript for content.

Potential Conflict of interest

The authors do not report any conflict of interest potentially related to the content of the submitted manuscript.

References

- ¹ Zhou F, Yu T, Du R et al. Clinical course and risk factors for mortality of adult inpatients with COVID-19 in Wuhan, China: a retrospective cohort study. *Lancet* 2020 395(10229):1054-1062 doi: 10.1016/S0140-6736(20)30566-3.
- ² Guan WJ, Ni ZY, Hu Y et al. China Medical Treatment Expert Group for Covid-19. Clinical Characteristics of Coronavirus Disease 2019 in China. *N Engl J Med* 2020 E-published doi: 10.1056/NEJMoa2002032.
- ³ Desforges M, Le Coupanec A, Dubeau P et al. Human Coronaviruses and Other Respiratory Viruses: Underestimated Opportunistic Pathogens of the Central Nervous System? *Viruses*. 2019;12(1). doi: 10.3390/v12010014.
- ⁴ Baig AM, Khaleeq A, Ali U, Syeda H. Evidence of the COVID-19 Virus Targeting the CNS: Tissue Distribution, Host-Virus Interaction, and Proposed Neurotropic Mechanisms. *ACS Chem Neurosci*. 2020 ;11(7):995-998.
- ⁵ Li YC, Bai WZ, Hashikawa T. The neuroinvasive potential of SARS-CoV2 may play a role in the respiratory failure of COVID-19 patients. *J Med Virol*. 2020
- ⁶ Mao L, Wang M, Chen S et al. Neurological Manifestations of Hospitalized Patients with COVID-19 in Wuhan, China: a retrospective case series study. *medRxiv*, 2020.02.22.20026500(accessed on 2020-02-28).

⁷ Zhou L, Zhang M, Gao J, Wang J. Sars-Cov-2: Underestimated damage to nervous system. *Travel Med Infect Dis*. 2020:101642.

⁸ The Lancet Infectious Disease COVID-19, a pandemic or not? *Lancet Infect Dis* ;20(4):383
doi: 10.1016/S1473-3099(20)30180-8.

⁹ Kupferschmidt K, Cohen J. Can China's COVID-19 strategy work elsewhere?
Science. 2020;6;367(6482):1061-1062. doi: 10.1126/science.367.6482.1061.

¹⁰ Dorcet G, Benaiteau M, Bost C et al. Two Cases of Late-Onset Anti-NMDAr Auto-Immune
Encephalitis After Herpes Simplex Virus 1 Encephalitis. *Front Neurol* 2020;11:38.

¹¹ Armangué T, Spatola M, Vlăgea A et al. Spanish Herpes Simplex Encephalitis Study Group.
Frequency, symptoms, risk factors, and outcomes of autoimmune encephalitis after herpes simplex
encephalitis: a prospective observational study and retrospective analysis. *Lancet
Neurol*. 2018;17(9):760-772.

¹² Ma J, Han W, Jiang L. Japanese encephalitis-induced anti-N-methyl-d-aspartate receptor
encephalitis: A hospital-based prospective study. *Brain Dev* 2020;42(2):179-184.

¹³ Sigfrid L, Perfect C, Rojek A et al. A systematic review of clinical guidelines on the management
of acute, community-acquired CNS infections. *BMC Med* 2019;17(1):170. doi: 10.1186/s12916-
019-1387-5.

¹⁴ Sejvar JJ. West Nile Virus Infection. *Microbiol Spectr* 2016;4(3). doi: 10.1128/microbiolspec.
EI10-0021-2016.

¹⁵ Rodrigo-Armenteros P, Kapetanovic-García S, Antón-Méndez L et al. Akinetic mutism and
status epilepticus due to Epstein Barr virus encephalitis. *Clin Neurol Neurosurg* 2019;185:105492.

¹⁶ Dale RC, Church AJ, Surtees RA et al. Encephalitis lethargica syndrome: 20 new cases and
evidence of basal ganglia autoimmunity. *Brain* 2004;127:21-33.

¹⁷ Pollak TA, Lennox BR, Müller S et al. Autoimmune psychosis: an international consensus on an
approach to the diagnosis and management of psychosis of suspected autoimmune origin.
Lancet Psychiatry 2020;7(1):93-108. doi: 10.1016/S2215-0366(19)30290-1.

¹⁸ Linnoila JJ, Rosenfeld MR, Dalmau J. Neuronal surface antibody mediated autoimmune encephalitis. *Semin Neurol.* 2014 Sep;34(4):458-66.

¹⁹ Mehta P, McAuley DF, Brown M, Sanchez E, Tattersall RS, Manson JJ; HLH Across Speciality Collaboration, UK. COVID-19: consider cytokine storm syndromes and immunosuppression. *Lancet.* 2020 Mar 16. doi: 10.1016/S0140-6736(20)30628-0.

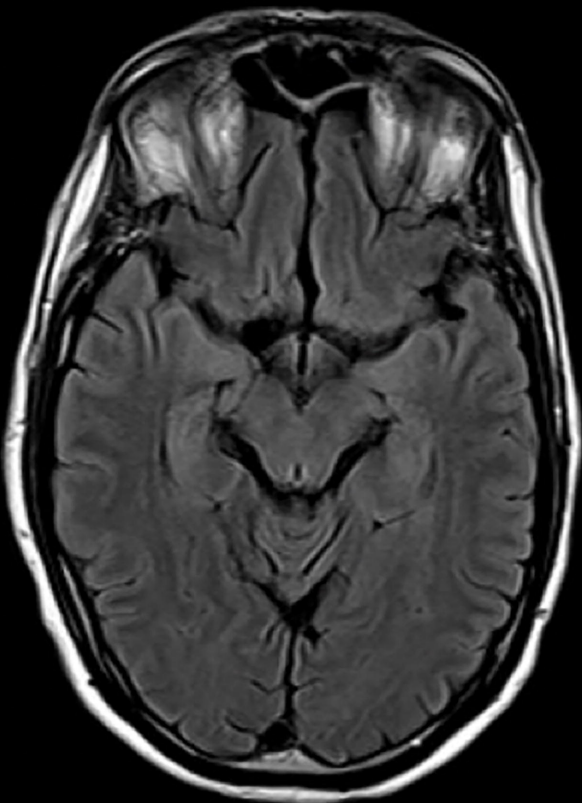
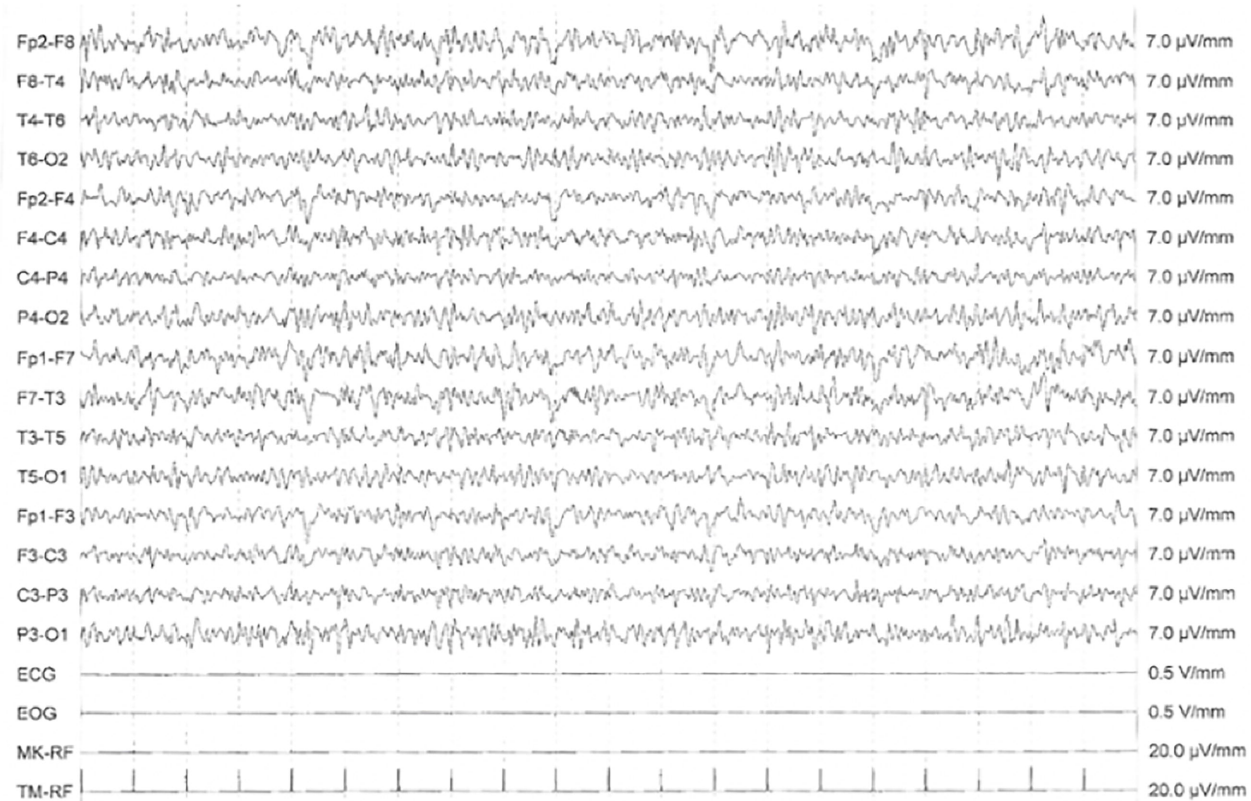
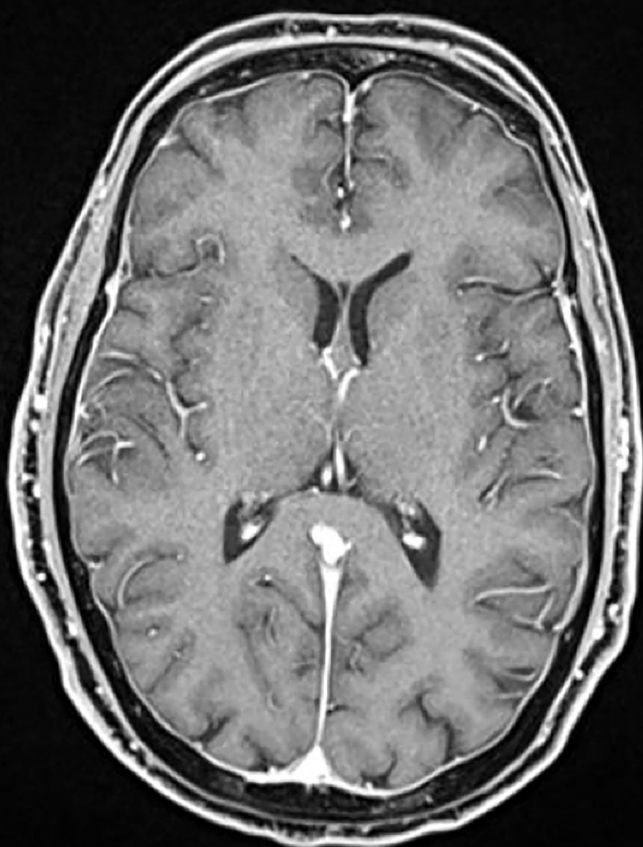
²⁰ Cohen, NT, Kolb N, Nannapaneni S, Login IS Adult-Onset Still's Disease with Parkinsonian Features *Neurol. Bull.* 4: 24-28, 2012

Figure legends

Figure 1. Magnetic Resonance Imaging and Electroencephalography (EEG) findings.

Box A/C normal MRI findings on T2 (A) and T1 with Gadolinium (C). EEG alterations at admission during the akinetic mutism state (B) and complete resolution of alterations after 5 days of high-dose Steroid treatment (D).

Figure 2 Clinical features, treatment and respiratory/inflammatory profile during the disease course.

A**B****C****D**