

Alterations in Brain Morphology by MRI in Adults with Neurofibromatosis 1

Authors: Su Wang, MSc¹; Victor-Felix Mautner, MD, PhD²; Ralph Buchert, MD, PhD³; Stephane Flibotte, PhD⁴, Per Suppa, Biomedical Engineer⁵; Jan M. Friedman, MD, PhD*¹; Manraj K. S. Heran, MD*⁶

Running head: Alterations in Brain Morphology in Adults with NF1

Affiliations:

¹Department of Medical Genetics, University of British Columbia, Children's & Women's Hospital, 4480 Oak Street, Vancouver, Canada.

²Department of Neurology, University Hospital Hamburg-Eppendorf, Hamburg, Germany.

³Department of Nuclear Medicine, University Hospital Hamburg-Eppendorf, Hamburg, Germany.

⁴UBC-LSI Bioinformatics Core Facility, University of British Columbia, Vancouver, British Columbia, Canada.

⁵Department of Nuclear Medicine, Charité - Universitätsmedizin Berlin, Corporate Member of Freie Universität Berlin, Humboldt-Universität zu Berlin, and Berlin Institute of Health, Berlin, Germany.

⁶Diagnostic and Therapeutic Neuroradiology, University of British Columbia, Vancouver, Canada.

*These authors contributed equally to the manuscript.

Corresponding Author:

Jan M. Friedman:

4500 Oak St

Vancouver, BC

V6H 3N1

(604) 875-2000 ext. 5623

jan.friedman@ubc.ca

Submission type: Research article

Title head character count: 73

Running head character count: 50

Word count of abstract: 197

Word count of introduction: 332

Word count of discussion: 851

Word count of paper: 3121

Number of tables: 4

Number of figures: 4

Number of color figures: 4

ABSTRACT

Objective:

To characterize alterations in brain morphology by MRI in adults with neurofibromatosis 1 (NF1).

Methods:

Planar (2D) MRI measurements of 29 intracranial structures were compared in 389 adults with NF1 and 112 age- and sex-matched unaffected control subjects. The 2D measurements were correlated to volumetric (3D) brain measurements for 99 of the adults with NF1.

A subset of adults with NF1 ($n = 70$) was also assessed for clinical severity of NF1 features and neurological problems and received psychometric testing for attention deficits and IQ. Correlation analyses were performed between principal components of the intracranial measurements and clinical and psychometric features of these patients.

Results:

Four of nine corpus callosum measurements were significantly greater in adults with NF1 than in sex- and age-matched controls. All seven brainstem measurements were significantly greater in adults with NF1 than in controls. Increased corpus callosum and brainstem 2D morphology were correlated with increased total white matter volume among the NF1 patients. No robust correlations were observed between the 2D size of these structures and clinical or neuropsychometric assessments.

Interpretation:

Our findings are consistent with the hypothesis that dysregulation of brain myelin production is an important manifestation of NF1 in adults.

INTRODUCTION

Neurofibromatosis 1 (NF1), an autosomal dominant disease caused by mutations of the *NF1* gene, affects approximately 1 in 3000 live births¹⁻³. NF1 causes a wide range of clinical features: neurofibromas, café-au-lait macules, macrocephaly, learning disabilities, and attention deficits⁴⁻¹⁵. Associated gliomas, malignant peripheral nerve sheath tumours, skeletal dysplasias, and cardiovascular disease may cause serious disability or death in affected children or young adults. The *NF1* gene encodes neurofibromin, which is a negative regulator of the RAS cellular proliferation pathway¹⁶. Loss of NF1 function results in increased Schwann cell proliferation, a primary feature of NF1 pathology¹⁶.

Many studies have used magnetic resonance imaging (MRI) to study brain morphology in children and adults with NF1. NF1 neuroimaging studies have been especially focused on unidentified bright objects, optic nerve/chiasmatic expansions, and tumours of the peripheral nerves or central nervous system^{17, 18}. Most people with NF1 do not develop brain tumours but may exhibit other, more subtle alterations of brain morphology on MRI examination, including increases in total white matter volume, total brain volume, corpus callosum (CC) area, CC length, and optic nerve tortuosity (ONT)^{6, 7, 9, 10, 19-28}. The clinical implications, if any, of these findings are unclear, given the small number and young age of individuals with NF1 in most reported studies¹⁰.

Previous research has attempted to correlate brain morphological differences with cognitive or behavioural abnormalities in children with NF1, but inconsistent results have been observed^{10, 24, 29, 30}. To date, there have been no large-scale MRI studies of brain morphological differences and their possible relationship to cognitive or behavioural abnormalities in adults with NF1.

We characterized 2D brain morphological differences in adults with NF1 within three regions of interest: the CC, brainstem, and optic nerves and ocular globes. We correlated the 2D measurements for the CC and brainstem with 3D volumetric measurements in NF1 to assess the role of different brain composition in the structural changes. Finally, we examined the associations of these 2D brain morphological changes with neuropsychometric findings among adults with NF1.

METHODS

Participants

Between 2003 and 2015, all patients seen in the NF Outpatient Department of the University Hospital Hamburg-Eppendorf in Hamburg, Germany, were offered brain MRI to monitor their intracranial tumour burden. Head MRI was obtained on 434 adults with NF1; each patient was imaged an average of three times. Participants were excluded from the current study if they had optic gliomas or brain tumors. Sex and age were recorded at the time of each examination.

Unaffected control individuals, who had undergone head MRI for other reasons at Vancouver General Hospital, Vancouver, Canada, were age- (within 24 months) and sex-matched to 25% of randomly selected adults with NF1. Affected and unaffected participants were excluded if no image was available that permitted clearly defined morphological measurements. In total, 389 adults with NF1 and 112 unaffected controls were included in the morphological analysis. In cases where multiple MRI scans were obtained for one individual, the latest MRI scan was used for brain morphological measurements.

A subset of adults with NF1 ($n = 70$) received clinical evaluations for NF1 severity, neurological severity, attention deficit hyperactivity disorder (ADHD) severity, and neuropsychometric evaluations for attention deficiencies and intelligence quotient (IQ).

Standard Protocol Approvals, Registrations, and Patient Consent

The ethical committees of the Medical Chamber in Hamburg and the Research Ethics Board of the University of British Columbia approved the study. Written consent was obtained from all study participants before the study began. All data were de-identified before analysis.

Morphological Measurements

Head MRI exams were conducted in a 1.5 or 3.0 Tesla scanner. Multiple coronal, axial, and/or sagittal T1, T2, and FLAIR images were obtained. OsiriX Lite³¹ software was used to obtain measurements in NF1 patients, and IMPAX PACS (Agfa, Ridgefield Park, NJ) software was used for this purpose in unaffected controls. Image slices were ≤ 5.5 mm thick for adults with NF1 and ≤ 6 mm thick for unaffected populations. In total, 29 measurements were obtained for each MRI set for each participant.

Eight measurements were obtained for the CC: area, length, height, genu width, anterior body width, mid-body width, posterior body width, and splenium width (Figure 1A). CC height was measured as maximum height of CC perpendicular to a line drawn at base of the CC.

Seven measurements were obtained for each of the ocular globes: anterior to posterior (AP) length, diameter, anterior to diameter (AD) length, anterior to interzygomatic line (AIZ) length, posterior to interzygomatic line (PIZ) length, optic nerve displacement (OND), and optic nerve path (ONP) (Figure 2A). AP and diameter measurements were obtained at maximum length/width. AD was measured as maximum length perpendicular to diameter. AIZ and PIZ was measured as maximum length perpendicular to interzygomatic line.

Seven measurements were obtained for the brainstem: midbrain width, midbrain AP length, pons AP length, left and right middle cerebellar peduncle (MCP) lengths, medulla oblongata width, and medulla oblongata AP length (Figure 3A). Midbrain width, pons AP, left and right MCP, and medulla oblongata width were measured as maximum length/width. Midbrain AP and medulla oblongata AP length were measured as maximum length perpendicular to midbrain width and medulla oblongata width, respectively.

CC bulbosity was calculated by dividing the splenium width by the posterior body width. Ocular globe elongation was calculated by dividing AD length by AP length. Globe protrusion was calculated by dividing AIZ by the sum of AIZ and PIZ. Optic nerve tortuosity (ONT) was calculated by dividing ONP by OND.

Brain volumes were measured according to methods described in our companion paper²⁸.

Clinical and Neuropsychometric Assessments

Clinical NF1 Severity

Clinical severity for adults with NF1 (n = 70) was categorised into four grades by Dr. Victor Mautner using a modified Riccardi scale^{32, 33}. Intellectual and psychological functions were excluded from the NF1 clinical severity rating to avoid confounding between learning disability and medical severity.

Clinical Neurological Severity

Clinical neurological severity for adults with NF1 (n = 70) was categorised by Dr. Victor Mautner into one of four grades. Grade 1 encompasses no deficits. Grade 2 includes discrete neurological deficits only: muscle hypotonia, sensation deficits, balance problems, or speech problems. Grade 3 includes neurological dysfunction: paresis, ataxia, significant ocular motor deficits, or substantial pain. Grade 4 encompasses neurological deficits that seriously compromise health: intractable pain, paralysis, or drug-resistant seizures.

Clinical Attention deficit hyperactivity disorder (ADHD) Severity

Clinical ADHD severity for adults with NF1 (n = 50) was categorized into three grades using the established criteria in DSM-IV³⁴. Grade 1 encompasses no clinical diagnosis. Grade 2 is subclinical attention deficit with no ADHD diagnosis. Grade 3 includes those with a diagnosis of either Attention Deficit Disorder (ADD) or ADHD.

Intelligence quotient (IQ)

Full-scale, verbal, and performance IQ were obtained for 61 adults with NF1 using the Wechsler Adult Intelligence Scale-Revised (WAIS-R)³⁵. WAIS-R test scores were standardized according to age and sex.

Attention Deficit Measurement

Attention deficit measurements for adults with NF1 (n = 68) were obtained using the Visual Test of Variables of Attention, version 7.0.3 or 8.0³⁶. Measurements were obtained for variability of response time (consistency), response time, commission error (impulsivity), errors of omission (inattention), post-commission response times, and multiple and anticipatory responses. An Attention Comparison Score was calculated for each patient. All test scores were standardized according to age and sex.

Statistical Analysis

All data were analysed using R Studio 3.4.1³⁷. A False Discovery Rate (FDR) adjusted significance level of $p < 0.05$ was used throughout to account for multiple comparisons³⁸.

Demographic Analysis

Mean age was compared between adults with NF1 and unaffected controls using the Student-T test after demonstrating satisfactory dataset normality and variance using the Shapiro-Wilk test and Fisher's F test, respectively. Sex ratios were compared between adults with NF1 and unaffected controls using the χ^2 test.

Brain Morphological Analysis

Means of the 26 different brain morphological measurements were compared between adults with NF1 and unaffected controls. Student-T tests were used for normally distributed data. Non-normal distributions were compared using Mann-Whitney U tests. CC bulbosity means were compared between males and females for both adults with NF1 and unaffected adults using two-way ANOVA test. Dataset normality and variance were determined using the Shapiro-Wilk test and Fisher's F test respectively. Significance (p-value) was adjusted using FDR to account for 26 comparisons.

Brain Morphological – Volumetric Correlation Analysis

Brain morphological – volumetric correlation analysis was only conducted for adults with complete 2D CC or brainstem measurements and 3D volumetric measurements. Principal component analysis (PCA) was calculated for CC and brainstem separately. PCs were included based on a combination of eigenvalue (greater than 1) and minimum combined amount of variance it accounts for (70%). Pearson correlation was conducted, and p values were adjusted using FDR to account for multiple comparisons.

Brain Morphology – Neuropsychometric Correlation Analysis

Brain morphology measurements for the CC, ocular globes, and brainstem were independently grouped using PCA to maximize the number of subjects included in the PCA. PCs for the correlation analysis were selected based on same threshold as above described. Clinical NF1 severity, clinical neurological severity, and clinical ADHD diagnosis data were analysed as ordinal data. Attention Comparison Score was analysed as a continuous measurement of attention deficit. Total IQ scores from WAIS-R were analysed as a continuous measurement. PCs from the three brain structures were independently compared to the neuropsychometric measurements using Pearson correlation for continuous data and Spearman's Rank-Order correlation for ordinal data. No significance testing was conducted on the correlation matrix due to insufficient sample size.

Data Availability

Anonymous data are available for appropriate research purposes through V.F. Mautner, MD.

RESULTS

Demographics

This study included 494 participants: 389 adults with NF1 and 112 age- (within 24 months) and sex-matched unaffected controls. There were no statistically significant differences in age or sex ratio distribution between adults with NF1 and unaffected controls overall or in the subgroups in whom the three brain structures (CC, ocular globes, and brainstem) were measured by MRI (Table 1).

Brain Morphology Comparison Between NF1 Patients and Controls

Four of eight corpus callosum measurements (midsagittal length, height, anterior body width, mid body width) were significantly greater and one (genu width) was significantly shorter in adults with NF1 than in unaffected control participants (Figure 1B, C). CC length, posterior body width, splenium width, and CC bulbosity did not differ between the two groups. The statistical significance was determined after adjustment for multiple comparisons.

Of the five measurements made for each ocular globe, only the AP lengths were significantly reduced in both eyes in adults with NF1 compared to unaffected controls (Figure 2B). Optic nerve tortuosity was greater among adults with NF1 than among unaffected individuals. This difference was small and reached statistical significance only on the left side.

The brainstems of individuals with NF1 were significantly larger than expected in all seven sites measured (midbrain width, midbrain AP length, pons AP length, left and right MCP lengths, medulla oblongata width, and medulla oblongata AP length) (Figure 3E).

Brain Morphology – White Matter Composition Correlation in Patients with NF1

2D morphological measurements do not distinguish between grey or white matter composition of the structures measured. In order to determine whether the increased CC and brainstem measurements we observed were related to altered myelination (white matter), we correlated 2D brain morphological measurements with 3D brain volumetric measurements in individuals with NF1. Principal component analysis was used to identify combinations of CC or brainstem 2D measurements that distinguished NF1 patients. Ninety-nine adults with NF1 (47 females and 52 males) had complete 2D and 3D measurements available for the CC. The first principal component (PC1) reflects a combination of CC area and mid-body measurements so that a larger PC1 indicates greater CC area and mid-body width. Larger PC2 indicates shorter and flatter CC. Larger PC3 indicates less bulbous CC posterior body. Larger PC4 indicates male. Overall, we found that larger 2D corpus callosum measurements most strongly correlated with increased total brain volume and increased corpus callosum white matter volume (Figure 4A).

There were 55 individuals with NF1 (25 females and 30 males) who had complete 2D and 3D measurements for the brainstem. The top three PCs based on 2D brainstem measurements were selected for correlation analysis. Larger PC1 indicates smaller pons and MCP, larger PC2 indicates older age, and larger PC3 indicates female. We found that larger 2D pons and MCO measurements most strongly correlate with increased total brain volume and total white matter volume (Figure 4B).

These results suggest that the greater than expected 2D corpus callosum and brainstem measurements reflect increased total white matter volume, and, by extension, myelination.

Morphology - Neuropsychometric Correlations

Twenty-nine adults with NF1 had complete datasets for the clinical and neuropsychometric assessments as well as for the CC measurements analysed. The top three PCs were selected for the CC. None of the CC PCs was strongly correlated with any of the five clinical assessments or neuropsychometric measurements (Table 2).

Twenty-six adults with NF1 had complete datasets for the clinical and neuropsychometric assessments and brainstem measurements analysed. The top three PCs were selected for the brainstem. PC1 was correlated with both decreased neurological severity ($r_s = -0.51$) and negative clinical ADD/ADHD diagnosis ($r_s = -0.49$). The three largest weights for PC1 were the right MCP length (-0.42), left MCP length (-0.41), and the pons AP length (-0.40). Thus, a smaller PC1 value indicates an overall thicker middle brainstem. Clinical severity was correlated with decreased clinical ADD/ADHD diagnosis ($r_s = -0.56$), and neurological severity was correlated with decreased IQ ($r_s = -0.38$) (Table 3).

Forty-four adults with NF1 had complete datasets for the clinical and neuropsychometric assessments and ocular globe measurements analysed. The top five PCs were selected for the ocular globes. None of the variables was strongly correlated with the others (Table 4).

DISCUSSION

We conducted the first large-scale MRI study of brain morphological differences and their relationship to cognitive or behavioural abnormalities in adults with NF1. We found that adults with NF1 have apparent enlargement of the corpus callosum and brainstem in comparison to unaffected adults. These 2D morphological enlargements are correlated to increased total white matter volume. In our companion study focused on brain volume, we also found an increase in total and regional white matter in the brains of adults with NF1 compared to control adults²⁸. In the current study, we did not find any obvious correlation between the brain morphological changes we observed and the clinical or neuropsychometric assessments in these individuals.

In the present study, we observed increased CC area, height, and anterior body and mid-body widths among adults with NF1. Our findings are consistent with those of previous studies in

children and smaller groups of adults with NF1^{23,25}. Also, previous brain MRI studies in people with NF1 have found evidence of increased total white matter volume, increased brain volume, and megalencephaly^{6,7,9,10,19-22}. Similarly, we found strong correlation between 2D CC size and total and CC white matter volume.

Loss of function mutations of *NF1* cause dysregulation of proliferation in Schwann cells, which are responsible for the myelination of axons in the peripheral nervous system¹⁶. In the brain, white matter is mainly comprised of myelinated axons³⁹. It is hypothesized that the increases in total white matter volume, total brain volume, and megalencephaly that occur in NF1 are related to the dysregulation of oligodendrocytes, the myelin-producing cells in the central nervous system^{23,40}. If this interpretation is correct, enlargement of the CC, a structure largely composed of white matter, might be expected in people with NF1. The decrease in genu width and increase in the anterior and mid-body widths raises the possibility that the CC shape is also changed. Enlargement of the CC height and area without significant alteration of the length is consistent with a change in CC shape and volume.

The enlargement of the brainstem that we observed among adults with NF1 is a novel finding. The brainstem consists of both grey and white matter, with the MCP (which was clearly enlarged among adults with NF1) comprised mostly of white matter^{41,42}. This is further evident by the strong correlation we found between increased brainstem 2D morphology measurements (specifically pons and MCP) and increased total white matter volume. Thus, the brainstem enlargement we observed is also consistent with dysregulated myelin proliferation in individuals with NF1.

Both age and sex are known to affect CC size, ocular globe size and position, and brainstem size⁴³⁻⁴⁷. We carefully matched unaffected individuals by age and sex to avoid confounding by these factors in our analysis. However, the adult NF1 group was recruited from Hamburg, Germany, while the unaffected comparison group was obtained in Vancouver, Canada. Different MR imaging procedures and measurement software were used for the NF1 group and the unaffected comparison control group. The different imaging procedures resulted in an inability to detect differences between the two groups smaller than 0.05 cm, but all statistically significant differences in brain morphological measurements observed between NF1 and control subjects were greater than 0.05 cm.

Another limitation of our study is the lack of dedicated orbital MRIs. The asymmetry in the ONT we observed probably does not represent a true anatomical difference and may be a result of measurement error, as previous studies have not found ONT asymmetry^{26,27}. The current study is less accurate than Ji et al.'s (2013), as we only measured ONT in one axial plane while Ji and associates used dedicated 3-dimensional magnetization-prepared rapid gradient echo sequences with 1 mm slices²⁷.

Our correlation analyses between structures measured on MRI and clinical/neuropsychometric assessments are limited by small sample sizes as only a subset of the adults with NF1 had

psychometric testing. Some previous studies have found that increased CC volume or CC index correlated with decreased academic achievement and IQ in children with NF1^{10, 24}. In contrast, Kayl et al. (2000b) found that among children with NF1, smaller splenium size was correlated with increased attention problems as reported by teachers²⁹. Furthermore, a more recent study using diffusion tensor imaging to examine myelination of white matter specifically failed to find a significant relationship between total CC area and IQ scores in children with NF1³⁰. We did not find any robust correlations between the brain morphology and neuropsychometric measurements in adults with NF1.

Clinically, 2D MRI is used more often than 3D MRI. We conducted the largest study of 2D brain morphology in adults with NF1 reported to date to characterize the brain morphology alterations. The enlargement of the CC and brainstem and correlation to increased total white matter volume that we observed in adults with NF1 lends support to the hypothesis that neurofibromin haploinsufficiency causes dysregulation of myelin production in the brain. The relationship of this overgrowth of myelinated brain structures to the frequent occurrence of central nervous system gliomas and of benign and malignant peripheral nerve sheath tumours in individuals with NF1 is unknown but merits further study.

ACKNOWLEDGEMENT:

We would like to thank Sofia Granstroem who analysed the neuropsychometric data. We are grateful to the Bundesverband Neurofibromatose organization for funding this project.

AUTHOR CONTRIBUTIONS:

SW contributed to design of the study, collected all 2D MRI morphological data, analyzed all data, and drafted and revised manuscript. VFM contributed to conception and design of the study, recruited patients, played a major role in the acquisition of MRI and neuropsychometric data, and revised the manuscript for intellectual content. RB contributed to the acquisition and analysis of volumetric MRI data, and revised manuscript for intellectual content. SF advised on key statistical analyses and revised the manuscript for intellectual content. PS conducted the volumetric MRI analyses and revised the manuscript for intellectual content. JMF contributed to conception and design of the study and revised the manuscript for intellectual content. MKSH contributed to design of the study, guided morphological data collection, and revised the manuscript for intellectual content. JMF and MKSH contributed equally to the manuscript.

CONFLICTS OF INTEREST:

All authors report no disclosures or conflicts of interest.

REFERENCES:

1. Xu GF, O'Connell P, Viskochil D, et al. The neurofibromatosis type 1 gene encodes a protein related to GAP. *Cell*. 1990 Aug 10;62(3):599-608.
2. Ballester R, Marchuk D, Boguski M, et al. The NF1 locus encodes a protein functionally related to mammalian GAP and yeast IRA proteins. *Cell*. 1990 Nov 16;63(4):851-9.
3. Friedman JM. Epidemiology of neurofibromatosis type 1. *Am J Med Genet*. 1999 Mar 26;89(1):1-6.
4. Friedman JM. Neurofibromatosis 1. In: Adam MP, Ardinger HH, Pagon RA, Wallace SE, Bean LJH, Stephens K, et al., editors. *GeneReviews*((R)). Seattle (WA)1993.
5. North K. Neurofibromatosis type 1. *Am J Med Genet*. 2000 Summer;97(2):119-27.
6. Cutting LE, Cooper KL, Koth CW, et al. Megalencephaly in NF1: predominantly white matter contribution and mitigation by ADHD. *Neurology*. 2002 Nov 12;59(9):1388-94.
7. Greenwood RS, Tupler LA, Whitt JK, et al. Brain morphometry, T2-weighted hyperintensities, and IQ in children with neurofibromatosis type 1. *Arch Neurol*. 2005 Dec;62(12):1904-8.
8. Kayl AE, Moore BD, 3rd. Behavioral phenotype of neurofibromatosis, type 1. *Ment Retard Dev Disabil Res Rev*. 2000;6(2):117-24.
9. Cutting LE, Koth CW, Burnette CP, Abrams MT, Kaufmann WE, Denckla MB. Relationship of cognitive functioning, whole brain volumes, and T2-weighted hyperintensities in neurofibromatosis-1. *J Child Neurol*. 2000 Mar;15(3):157-60.
10. Moore BD, 3rd, Slopis JM, Jackson EF, De Winter AE, Leeds NE. Brain volume in children with neurofibromatosis type 1: relation to neuropsychological status. *Neurology*. 2000 Feb 22;54(4):914-20.
11. Moore BD. Potential influences on mathematical difficulties in children and adolescents with neurofibromatosis, type 1. *Dev Disabil Res Rev*. 2009;15(1):45-51.
12. Rosser TL, Packer RJ. Neurocognitive dysfunction in children with neurofibromatosis type 1. *Curr Neurol Neurosci Rep*. 2003 Mar;3(2):129-36.
13. Pride NA, Korgaonkar MS, Barton B, Payne JM, Vucic S, North KN. The genetic and neuroanatomical basis of social dysfunction: lessons from neurofibromatosis type 1. *Hum Brain Mapp*. 2014 May;35(5):2372-82.
14. Koth CW, Cutting LE, Denckla MB. The association of neurofibromatosis type 1 and attention deficit hyperactivity disorder. *Child Neuropsychol*. 2000 Sep;6(3):185-94.
15. Mautner VF, Kluwe L, Thakker SD, Lark RA. Treatment of ADHD in neurofibromatosis type 1. *Dev Med Child Neurol*. 2002 Mar;44(3):164-70.
16. Johnson MR, DeClue JE, Felzmann S, et al. Neurofibromin can inhibit Ras-dependent growth by a mechanism independent of its GTPase-accelerating function. *Mol Cell Biol*. 1994 Jan;14(1):641-5.
17. Sellmer L, Farschtschi S, Marangoni M, et al. Non-optic glioma in adults and children with neurofibromatosis 1. *Orphanet J Rare Dis*. 2017 Feb 15;12(1):34.
18. Sellmer L, Farschtschi S, Marangoni M, et al. Serial MRIs provide novel insight into natural history of optic pathway gliomas in patients with neurofibromatosis 1. *Orphanet J Rare Dis*. 2018 Apr 23;13(1):62.
19. Sevick RJ, Barkovich AJ, Edwards MS, Koch T, Berg B, Lempert T. Evolution of white matter lesions in neurofibromatosis type 1: MR findings. *AJR Am J Roentgenol*. 1992 Jul;159(1):171-5.
20. Steen RG, Taylor JS, Langston JW, et al. Prospective evaluation of the brain in asymptomatic children with neurofibromatosis type 1: relationship of macrocephaly to T1 relaxation changes and structural brain abnormalities. *AJNR American journal of neuroradiology*. 2001 May;22(5):810-7.
21. Karlsgodt KH, Rosser T, Lutkenhoff ES, Cannon TD, Silva A, Bearden CE. Alterations in white matter microstructure in neurofibromatosis-1. *PLoS One*. 2012;7(10):e47854.

22. Said SM, Yeh TL, Greenwood RS, Whitt JK, Tupler LA, Krishnan KR. MRI morphometric analysis and neuropsychological function in patients with neurofibromatosis. *Neuroreport*. 1996 Aug 12;7(12):1941-4.
23. Dubovsky EC, Booth TN, Vezina G, Samango-Sprouse CA, Palmer KM, Brasseux CO. MR imaging of the corpus callosum in pediatric patients with neurofibromatosis type 1. *AJNR American journal of neuroradiology*. 2001 Jan;22(1):190-5.
24. Pride N, Payne JM, Webster R, Shores EA, Rae C, North KN. Corpus callosum morphology and its relationship to cognitive function in neurofibromatosis type 1. *J Child Neurol*. 2010 Jul;25(7):834-41.
25. Wignall EL, Griffiths PD, Papadakis NG, et al. Corpus callosum morphology and microstructure assessed using structural MR imaging and diffusion tensor imaging: initial findings in adults with neurofibromatosis type 1. *AJNR American journal of neuroradiology*. 2010 May;31(5):856-61.
26. DiMario FJ, Jr., Ramsby G, Greenstein R, Langshur S, Dunham B. Neurofibromatosis type 1: magnetic resonance imaging findings. *J Child Neurol*. 1993 Jan;8(1):32-9.
27. Ji J, Shimony J, Gao F, McKinstry RC, Gutmann DH. Optic nerve tortuosity in children with neurofibromatosis type 1. *Pediatr Radiol*. 2013 Oct;43(10):1336-43.
28. Wang S, Friedman JM, Buchert R, Mautner VF. Brain Volume Alterations in Adults with NF1 Characterized Using MRI. *bioRxiv*. 2021.
29. Kayl AE, Moore BD, 3rd, Slopis JM, Jackson EF, Leeds NE. Quantitative morphology of the corpus callosum in children with neurofibromatosis and attention-deficit hyperactivity disorder. *J Child Neurol*. 2000 Feb;15(2):90-6.
30. Aydin S, Kurtcan S, Alkan A, et al. Relationship between the corpus callosum and neurocognitive disabilities in children with NF-1: diffusion tensor imaging features. *Clinical Imaging*. 2016 2016/11/01;40(6):1092-5.
31. Rosset A, Spadola L, Ratib O. OsiriX: An open-source software for navigating in multidimensional DICOM images. *J Digit Imaging*; 2004.
32. Riccardi V. The multiple forms of neurofibromatosis. *Pediatr Rev*. 1982;3:293-8.
33. Riccardi VM. Neurofibromatosis: clinical heterogeneity. *Current problems in cancer*. 1982;7(2):1-34.
34. American Academy of Family Physicians., American Psychiatric Association. Work Group on DSM-IV-PC. Diagnostic and statistical manual of mental disorders, fourth edition : primary care version. 1st ed. Washington, DC: American Psychiatric Association; 1995.
35. Wechsler D. WAIS-R Manual: Wechsler Adult Intelligence Scale-revised: Psychological Corporation; 1981.
36. Greenberg LM. The Test of Variables of Attention. 8.0 ed. Los Alamitos: The TOVA Company; 2011.
37. Team R. RStudio: Integrated Development for R. 3.6.1 ed. Boston, MA.: RStudio, Inc.; 2016.
38. Benjamini Y, Hochberg Y. Controlling the False Discovery Rate: A Practical and Powerful Approach to Multiple Testing. *Journal of the Royal Statistical Society Series B (Methodological)*. 1995;57(1):289-300.
39. van der Knaap MS, Valk J. Myelin and White Matter. In: van der Knaap MS, Valk J, editors. *Magnetic Resonance of Myelin, Myelination, and Myelin Disorders*. Berlin, Heidelberg: Springer Berlin Heidelberg; 1995. p. 1-17.
40. Gutmann DH, Parada LF, Silva AJ, Ratner N. Neurofibromatosis type 1: modeling CNS dysfunction. *J Neurosci*. 2012 Oct 10;32(41):14087-93.
41. Purger D, Gibson EM, Monje M. Myelin plasticity in the central nervous system. *Neuropharmacology*. 2016 Nov;110(Pt B):563-73.
42. Ford AA, Colon-Perez L, Triplett WT, Gullett JM, Mareci TH, Fitzgerald DB. Imaging white matter in human brainstem. *Front Hum Neurosci*. 2013;7:400.
43. Doraiswamy PM, Figiel GS, Husain MM, et al. Aging of the human corpus callosum: magnetic resonance imaging in normal volunteers. *J Neuropsychiatry Clin Neurosci*. 1991 Fall;3(4):392-7.

44. Prendergast DM, Ardekani B, Ikuta T, et al. Age and sex effects on corpus callosum morphology across the lifespan. *Hum Brain Mapp.* 2015 Jul;36(7):2691-702.
45. Igbinedion B, Ogbeide O. Measurement of normal ocular volume by the use of computed tomography. *Nigerian Journal of Clinical Practice.* 2013 July 1, 2013;16(3):315-9.
46. Ahmadi H, Shams PN, Davies NP, Joshi N, Kelly MH. Age-related changes in the normal sagittal relationship between globe and orbit. *Journal of Plastic, Reconstructive & Aesthetic Surgery.* 2007 2007/03/01/;60(3):246-50.
47. Xie Y, Chen YA, De Bellis MD. The relationship of age, gender, and IQ with the brainstem and thalamus in healthy children and adolescents: a magnetic resonance imaging volumetric study. *J Child Neurol.* 2012 Mar;27(3):325-31.

FIGURE LEGEND:

Figure 1: Corpus callosum measurements and averages for adults with NF1 and unaffected control participants. (A) Representative MRI image showing T1-weighted midline sagittal view of a male in his 30's with NF1. (B) Average CC midsagittal area. (C) Average CC measurements. Coloured lines and area outlined in (A) show where structures indicated by the same colour in (B) or (C) are measured. Error bars indicating one standard deviation and asterisks indicating FDR-adjusted statistical significance are shown in (B) and (C). $p < 0.001 = ***$. Abbreviations used in figure: Genu = genu width, Ant-body = anterior body width, Mid-body = mid-body width, Post-body = posterior body width, and Splenium = splenium width.

Figure 2: Ocular globe measurements and averages for adults with NF1 and unaffected control participants. (A) Representative MRI image showing T2-weighted axial view of a male in his 20's with NF1. (B) Select average ocular globe measurements. Unique measurements are shown on one side but were obtained on both left and right side. Coloured lines in (A) show where structures indicated by the same colour in (B) are measured. Error bars indicating one standard deviation and asterisks indicating FDR-adjusted statistical significance are shown in (B). $p < 0.5 = *$; $p < 0.001 = ***$. Abbreviations used in the figure: L = left, R = right, AP = anterior to posterior length, AD = anterior to diameter length, AIZ = anterior to interzygomatic line length, IZ = interzygomatic line, PIZ = posterior to interzygomatic line length, OND = optic nerve displacement, and ONP = optic nerve path.

Figure 3: Location of brainstem measurements shown on representative sagittal (A), axial (B), (C), and (D) images, and average measurements (E) for adults with NF1 and unaffected control participants. (A-D) Representative MRI images showing T1-weighted midline sagittal and T2-weighted axial views of a male 20's with NF1. (E) Average brainstem measurements. The labeled lines in (A) show position of the midbrain (B), the pons and the middle cerebellar peduncle (C), and the medulla oblongata (D). Coloured lines in (B-D) show where structures indicated by the same colour in (E) are measured. Error bars indicating one standard deviation and asterisks indicating FDR-adjusted statistical significance are shown in (E). $p < 0.001 = ***$. Abbreviations used in the figure: L = left, R = right, AP = anterior to posterior length, and MCP = middle cerebellar peduncle.

Figure 4: Correlation matrix of principal components of 2D brain morphological measurements with 3D brain volumetric measurements of the corpus callosum (A) and brainstem (B) in adults with NF1. The color scale represents the degree of correlation from strongly negative (-1, red) to strongly positive (1, blue). The size of the circles also indicates the strength of the correlation, with values closer to -1 or 1 larger than those that are closer to 0. Asterisks indicate FDR-adjusted statistical significance. $p < 0.05 = *$, $p < 0.01 = **$, $p < 0.001 = ***$. Abbreviations: eTIV = total brain volume, GM = grey matter volume, WM = white matter volume, WMCC = corpus callosum white matter volume, WMBS = brainstem white matter volume, and PC = principal component.

Table 1: Participant demographics for adults with NF1 and matched unaffected controls.

	ADULTS WITH NF1	UNAFFECTED CONTROLS
ALL SUBJECTS		
N	389	112
Mean Age (SD)	37.4 (13.5)	39.4 (13.1)
Age Range	18.1 - 72.9	19.4 - 73.3
Female: Male (Female Percentage)	218:171 (56.0%)	63:49 (56.2%)
SUBJECTS WITH MRI MEASUREMENTS OF CORPUS CALLOSUM		
N	226	57
Mean Age (SD)	37.1 (13.6)	38.0 (13.2)
Age Range	18.2 - 72.9	19.4 - 64.7
Female: Male (Female Percentage)	126:100 (55.7%)	31:26 (54.4%)
SUBJECTS WITH MRI MEASUREMENTS OF OCULAR GLOBES		
N	386	96
Mean Age (SD)	37.4 (13.5)	39.6 (13.7)
Age Range	18.1 - 72.9	19.4 - 73.3
Female: Male (Female Percentage)	214:172 (55.4%)	56:40 (58.3%)
SUBJECTS WITH MRI MEASUREMENTS OF BRAIN STEM		
N	375	96
Mean Age (SD)	37.2 (13.3)	39.5 (13.1)
Age Range	18.1 - 72.9	19.4 - 73.3
Female: Male (Female Percentage)	209:166 (55.7%)	56:40 (58.3%)

The demographics are analysed in total and in measurement groups. No comparisons between adults with NF1 and unaffected controls were significantly different.

Table 2: Correlation values and p-values of corpus callosum measurements with clinical and neuropsychometric assessments in adults with NF1.

CORRELATION MATRIX								
	Clin. Sev.	Neuro. Sev.	ADD/ADHD	IQ	ACS	PC1	PC2	PC3
Clin. Sev.		<i>0.14</i>	<i>-0.49</i>	<i>-0.29</i>	<i>-0.17</i>	<i>0.38</i>	<i>-0.05</i>	<i>-0.02</i>
Neuro. Sev.			<i>0.55</i>	<i>0.20</i>	<i>-0.41</i>	<i>0.19</i>	<i>-0.05</i>	<i>0.17</i>
ADD/ADHD				<i>0.26</i>	<i>-0.17</i>	<i>0.01</i>	<i>-0.20</i>	<i>-0.06</i>
IQ					<i>0.10</i>	<i>-0.01</i>	<i>-0.41</i>	<i>0.33</i>
ACS						<i>-0.22</i>	<i>0.23</i>	<i>0.08</i>
PC1							<i>-0.20</i>	<i>-0.03</i>
PC2								<i>-0.09</i>

Top three corpus callosum PCs are correlated to neuropsychometric measurements (clinical severity, clinical neurological severity, clinical ADD/ADHD diagnosis, IQ, and Attention Comparison Score). The correlation matrix combines the Pearson correlation and Spearman correlation (italicized) results. Abbreviations used in the table: Clin. Sev. = clinical NF1 severity, Neuro. Sev. = clinical neurological severity, ADD/ADHD = clinical Attention deficit hyperactivity disorder severity, IQ = intelligence quotient, ACS = Attention Comparison Score, and PC = principal component.

Table 3: Correlation values and p-values of brainstem measurements with clinical and neuropsychometric assessments in adults with NF1.

CORRELATION MATRIX								
	Clin. Sev.	Neuro. Sev.	ADD/ADHD	IQ	ACS	PC1	PC2	PC3
Clin. Sev.		<i>-0.06</i>	<i>-0.56</i>	<i>-0.24</i>	<i>-0.13</i>	<i>0.21</i>	<i>-0.17</i>	<i>0.21</i>
Neuro. Sev.			<i>0.43</i>	<i>-0.38</i>	<i>-0.21</i>	<i>-0.51</i>	<i>-0.16</i>	<i>-0.20</i>
ADD/ADHD				<i>0.24</i>	<i>-0.06</i>	<i>-0.49</i>	<i>0.32</i>	<i>-0.31</i>
IQ					<i>0.35</i>	<i>-0.17</i>	<i>0.33</i>	<i>0.17</i>
ACS						<i>0.05</i>	<i>0.27</i>	<i>0.30</i>
PC1							<i>0.01</i>	<i>0.18</i>
PC2								<i>0.22</i>

Top three brainstem PCs are correlated to neuropsychometric measurements (clinical severity, clinical neurological severity, clinical ADD/ADHD diagnosis, IQ, and Attention Comparison Score). The correlation matrix combines the Pearson correlation and Spearman correlation (italicized) results. Abbreviations used in the table: Clin. Sev. = clinical NF1 severity, Neuro. Sev. = clinical neurological severity, ADD/ADHD = clinical Attention deficit hyperactivity disorder severity, IQ = intelligence quotient, ACS = Attention Comparison Score, and PC = principal component.

Table 4: Correlation values and p-values of ocular globe measurements with clinical and neuropsychometric assessments in adults with NF1.

CORRELATION MATRIX										
	Clin. Sev.	Neuro. Sev.	ADD/ADHD	IQ	ACS	PC1	PC2	PC3	PC4	PC5
Clin. Sev.		<i>0.23</i>	<i>-0.21</i>	<i>-0.21</i>	<i>-0.21</i>	<i>-0.36</i>	<i>0.01</i>	<i>0.04</i>	<i>-0.40</i>	<i>-0.20</i>
Neuro. Sev.			<i>0.49</i>	<i>-0.34</i>	<i>-0.13</i>	<i>-0.25</i>	<i>0.20</i>	<i>-0.08</i>	<i>0.23</i>	<i>0.11</i>
ADD/ADHD				<i>0.04</i>	<i>-0.03</i>	<i>0.13</i>	<i>0.36</i>	<i>-0.18</i>	<i>0.10</i>	<i>0.26</i>
IQ					<i>0.16</i>	<i>0.50</i>	<i>-0.11</i>	<i>-0.01</i>	<i>-0.02</i>	<i>-0.36</i>
ACS						<i>-0.10</i>	<i>-0.18</i>	<i>-0.07</i>	<i>0.09</i>	<i>0.01</i>
PC1							<i>0.12</i>	<i>0.06</i>	<i>0.08</i>	<i>-0.05</i>
PC2								<i>0.06</i>	<i>-0.04</i>	<i>0.04</i>
PC3									<i>-0.05</i>	<i>0.04</i>
PC4										<i>0.00</i>

Top five corpus callosum PCs are correlated to neuropsychometric measurements (clinical severity, clinical neurological severity, clinical ADD/ADHD diagnosis, IQ, and Attention Comparison Score). The correlation matrix combines the Pearson correlation and Spearman correlation (italicized) results. Abbreviations used in the table: Clin. Sev. = clinical NF1 severity, Neuro. Sev. = clinical neurological severity, ADD/ADHD = clinical Attention deficit hyperactivity disorder severity, IQ = intelligence quotient, ACS = Attention Comparison Score, and PC = principal component.

Figure 1:

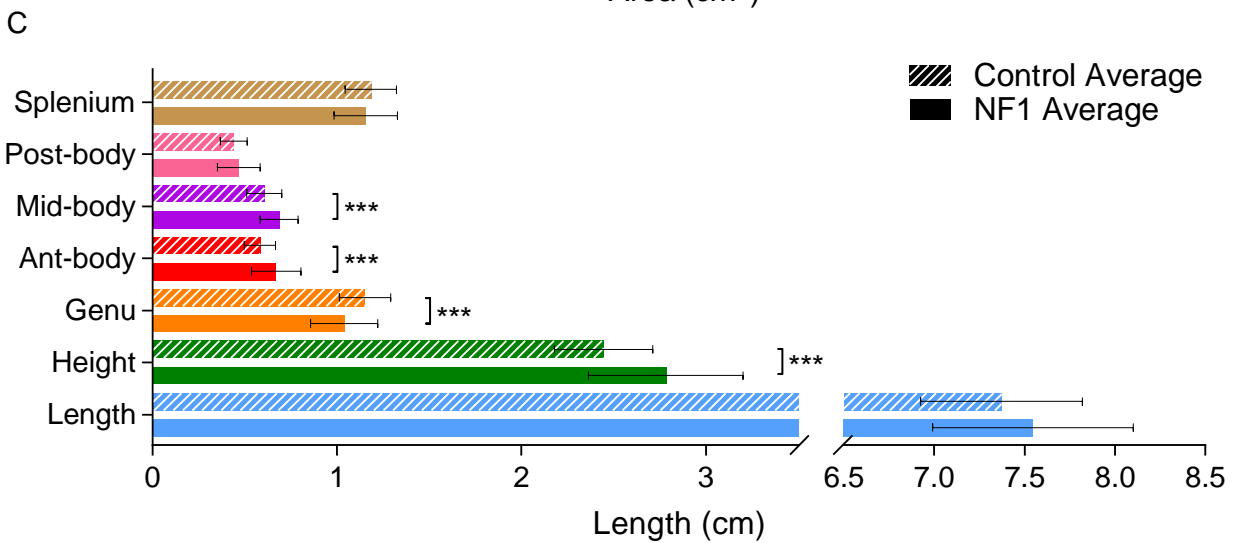
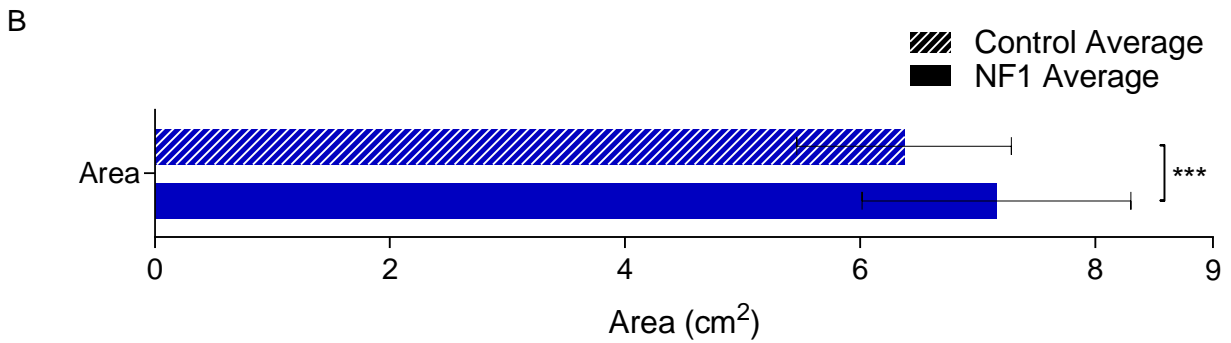
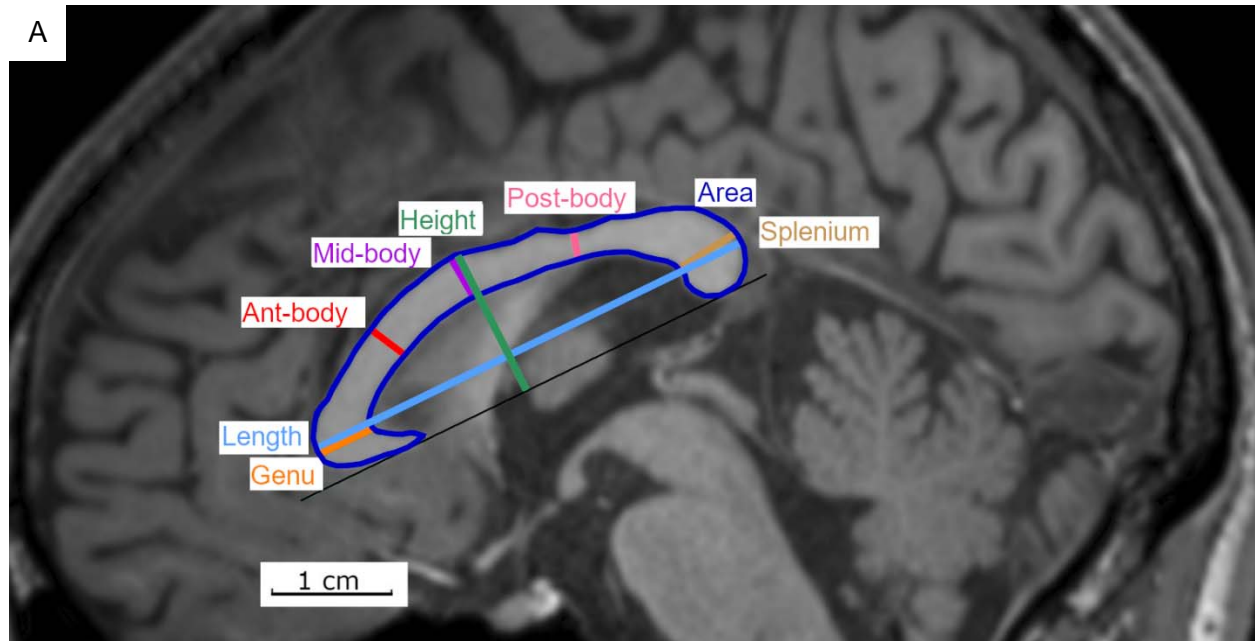


Figure 2:

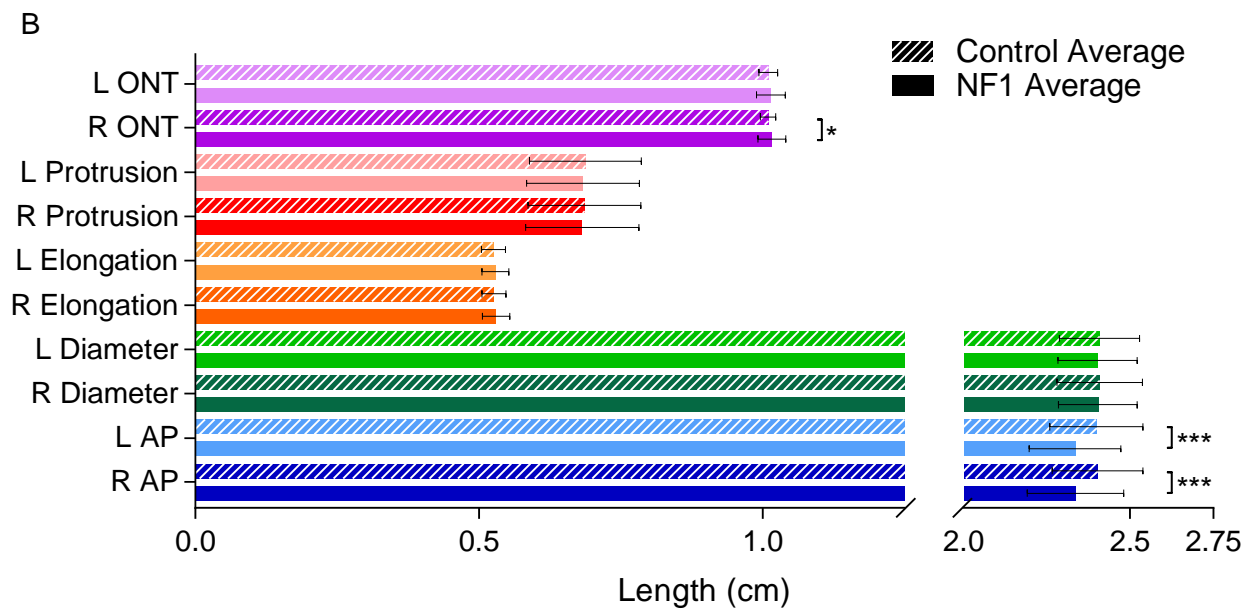
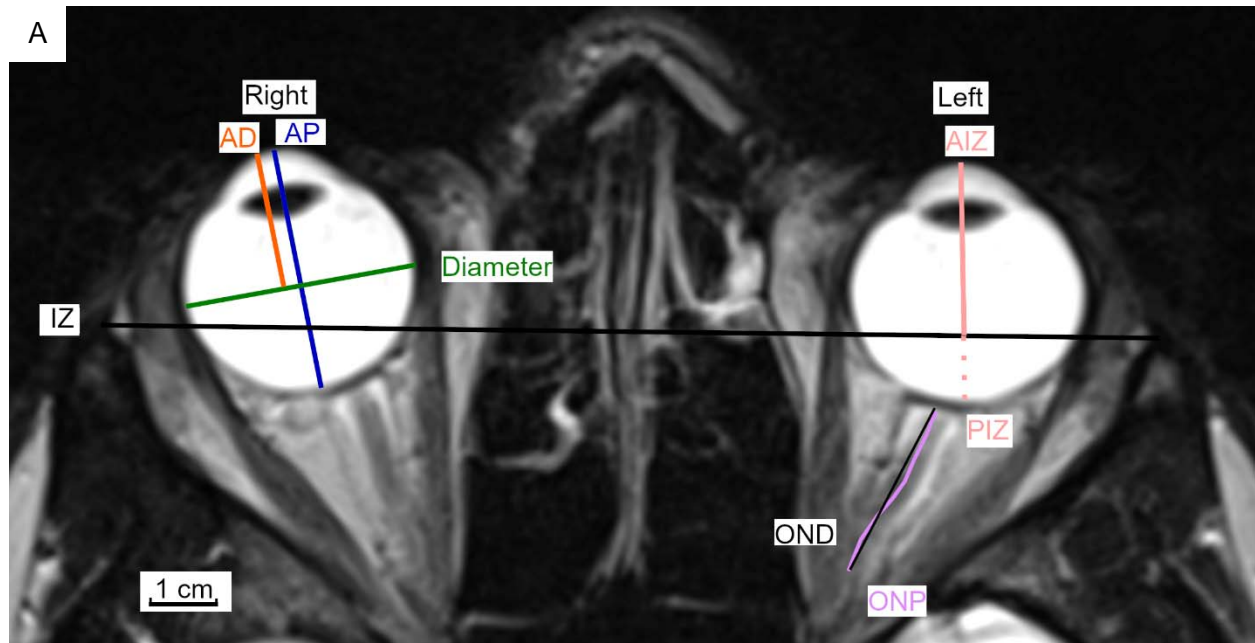


Figure 3:

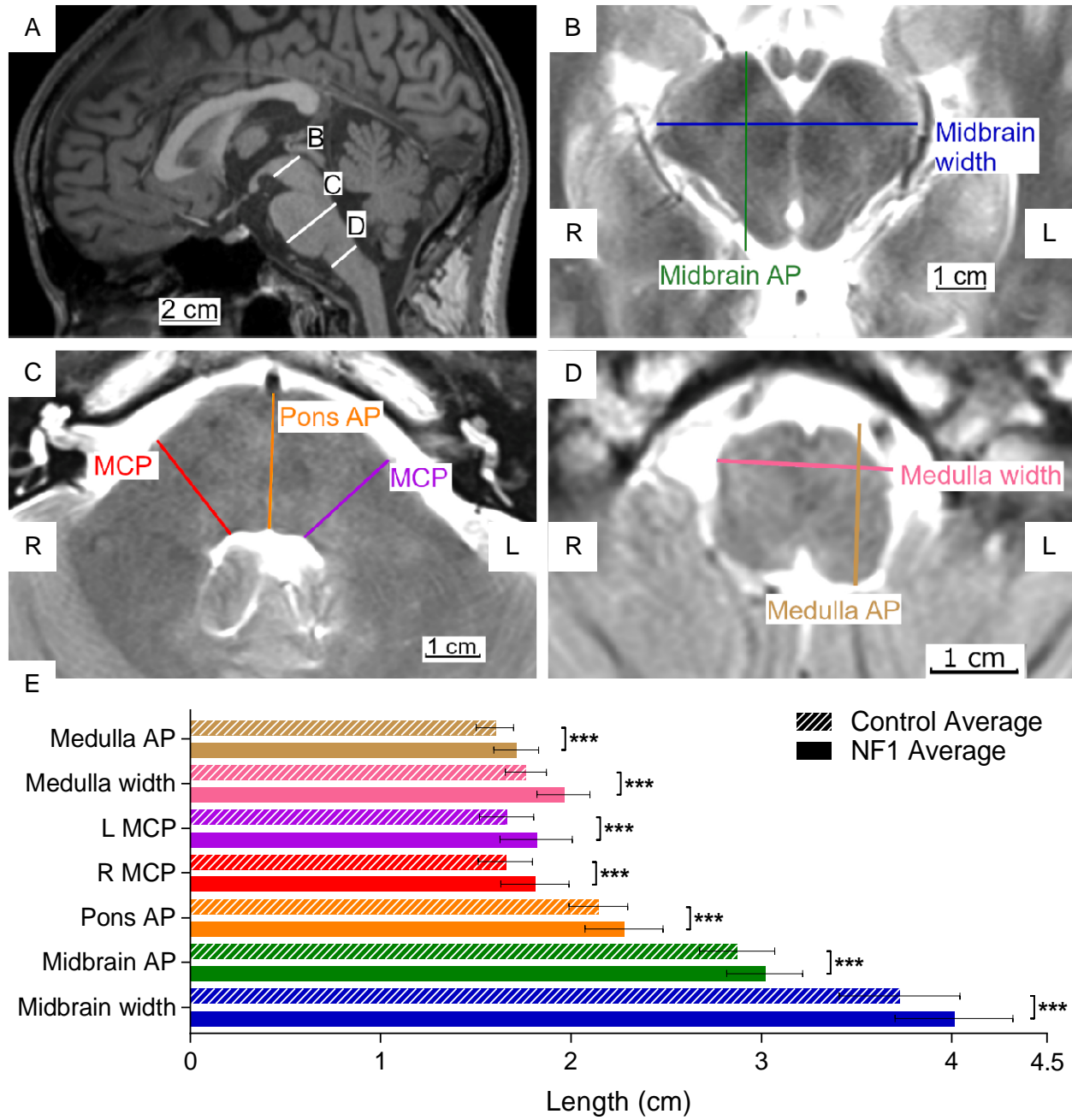


Figure 4:

