

1 **Investigation of the causative pathogen in the 2023 conjunctivitis outbreak of Nepal using**  
2 **unbiased metagenomic next generation sequencing**

3 Eliya Shrestha<sup>1¶</sup>, Nishan Katuwal<sup>2,3,4¶</sup>, Ranju Kharel Sitaula<sup>5</sup>, Harimaya Gurung<sup>1</sup>, Aastha  
4 Shrestha<sup>3,4</sup>, Pratap Karki<sup>5</sup>, Rajeev Shrestha<sup>2,3,4,5\*</sup>

5 1 Himalaya Eye Hospital, Pokhara, Nepal

6 2 Molecular and Genome Sequencing Research Lab, Dhulikhel Hospital Kathmandu University  
7 Hospital, Dhulikhel, Nepal

8 3 Center for Infectious Disease Research and Surveillance, Dhulikhel Hospital Kathmandu Uni-  
9 versity Hospital, Dhulikhel, Nepal

10 4 Research and Development Division, Dhulikhel Hospital Kathmandu University Hospital,  
11 Dhulikhel, Nepal

12 5 B.P. Koirala Lions Center for Ophthalmic Studies, Tribhuvan University, Kathmandu, Nepal

13 6 Department of Pharmacology, Kathmandu University School of Medical Sciences, Dhulikhel,  
14 Nepal

15

16 ¶: equal contribution

17 **\*Corresponding Author:**

18 Prof. Dr. Rajeev Shrestha

19 email: [rajeev.shrestha@kusms.edu.np](mailto:rajeev.shrestha@kusms.edu.np)

20

21 **Word Count : 1726**

22 **Abstract Word Count: 161**

23 **Figures: 4**

24 **Tables: 1**

25

26

27

28 **Abstract**

29 In mid-2023, Nepal experienced a significant outbreak of conjunctivitis, affecting over 60% of  
30 outpatients in eye hospitals and prompting school closures. The outbreak, peaking in August,  
31 predominantly impacted children and individuals with compromised immunity. Clinical  
32 manifestations included sudden-onset redness, foreign body sensation, watery discharge, and  
33 occasional lid swelling. A majority of cases exhibited acute hemorrhagic conjunctivitis, with  
34 management involving ocular lubricants, personal hygiene, and topical antibiotics. This study  
35 details the genomic epidemiology and clinical characteristics of conjunctivitis cases during the  
36 outbreak. To understand the causative agents, conjunctival swabs from patients were evaluated  
37 using unbiased metagenomic next-generation sequencing (mNGS) in Illumina iSeq100 at  
38 Dhulikhel Hospital Kathmandu University Hospital. This case series revealed the presence of  
39 Enterovirus C (coxsackievirus strain A24) as the major pathogen responsible for the outbreak.  
40 This case series contributes valuable insights into the genomic diversity of conjunctivitis-  
41 associated viruses, highlighting the potential of mNGS in enhancing diagnostic capabilities and  
42 guiding public health responses.

43 **Keywords:** conjunctivitis, Enterovirus, metagenomic next generation sequencing, Nepal

44

45

46

47

48

## 49 **Background**

50 Conjunctivitis is the inflammation of the conjunctival tissue of the eye along with engorgement  
51 of the blood vessels, ocular discharge and pain. [1,2] The causes of conjunctivitis have been  
52 known to be of viral, allergic and bacterial of origin; and could be infectious or non-infectious.  
53 [2] Viral conjunctivitis, also known as Pink Eye or Eye Flue, constitute of 75% of the cases can  
54 produces red, irritated eye with watery discharge, with occasional presence of preauricular  
55 adenopathy. [3,4] Around 90% of all viral conjunctivitis is caused by adenovirus. [5] Bacterial  
56 conjunctivitis, on the other hand, has similar presentation to viral but is less common and has  
57 more mucopurulent drainage. [3,6] The bacterial conjunctivitis is mostly caused by  
58 *Staphylococcus spp.*, *Haemophilus influenza*, *Streptococcus spp*, *Moraxella catarrhalis* and other  
59 gram-negative bacteria. [7]

60 Infective conjunctivitis can be transmitted by direct contact, abnormal proliferation of  
61 conjunctival flora, contaminated fingers or discharge. [2,8,9] It has been found that children are  
62 most susceptible to viral infections while adults tend to get more bacterial infections. [2] In terms  
63 of chronicity, conjunctivitis can be divided into acute with rapid onset and duration of four weeks  
64 or less, subacute, and chronic with duration longer than four weeks. [10] In severe conjunctivitis,  
65 the individuals are extremely symptomatic with abundance of mucopurulent discharge.[5] Some  
66 conjunctivitis cases developed keratitis and take a longer time to heal and develop long term  
67 visual complications like corneal scarring.

68 The resolution of conjunctivitis can usually take up to 3 weeks. [1,5] In case of viral  
69 conjunctivitis, the treatment is aimed at symptomatic relief instead of eradication of the infection  
70 with frequent use of preservative-free artificial tears for lubrication, dilatation of allergens and  
71 flushing the ocular surface clean from many inflammatory mediators. [2] In bacterial

72 conjunctivitis, topical antibiotic drops used and, in some instances, steroids and non-steroidal  
73 anti-inflammatory drugs are given judiciously. [19] Prescribing unnecessary antibiotics for  
74 treatment of viral conjunctivitis is one of the major costs of any healthcare system and can add  
75 on to the global problem on antibiotic resistance. [2,11] Conjunctivitis can have a considerable  
76 economic and societal impact, due to the costs of visits to the ophthalmologists, cost of  
77 diagnostic tests, treatment, and time lost from work or school.

78 Diagnosis of conjunctivitis is usually clinical and laboratory testing is typically not indicated  
79 unless the symptoms are not resolving and infection last longer than 4 weeks. [2] [12] In case of  
80 clinical manifestation of adenoviral conjunctivitis, cell culture has been proved to be gold  
81 standard. [13] Recently, molecular tests have been used for diagnosis with considerable  
82 specificity and sensitivity. [13,14] Next generation sequencing approaches, on the other hand,  
83 have revealed diverse microbiome profile with some techniques being able of profiling to species  
84 level and is inherently unbiased and hypothesis-free. [15-18]

85 Since July 2023, Nepal had an epidemic outbreak of conjunctivitis cases across the country. The  
86 surge was so high that more than 60% of the OPD patients in various eye hospitals of Nepal were  
87 filled with conjunctivitis cases and schools were shut down to prevent the community  
88 transmission. The cases mainly presented as pink eye and viral origin was the top suspicion.[20]  
89 This rapid outbreak mostly affected children and people with low immunity.

90

## 91 **Methods**

92 Himalaya Eye Hospital, Pokhara, Nepal experienced a conjunctivitis outbreak from mid-July  
93 until September 2023. The conjunctival swabs were collected from the subjects (2-55 years)

94 visiting HEH, as part of routine diagnosis, at the first day of ocular examination. These swabs  
95 were aliquoted in RNA/DNA Shield and transported (n=25) in cold chain to DHKUH. At  
96 DHKUH, the swabs were extracted for DNA and RNA (Zymo Quick DNA/RNA Pathogen  
97 Miniprep Kit, Cat: R0142) followed by subsequent DNA and RNA library preparation (New  
98 England Biolabs) for metagenomic next generation sequencing. The respective libraries were  
99 pooled and quality checked by Agilent Tapestation and then loaded in Illumina iSeq100, with 4  
100 million reads at 2x150 bp length. Additional process controls (extraction and library preparation)  
101 and sample controls (normal flora) were included for background model. The downstream  
102 metagenomic investigation was done by CZID (Illumina mNGS Pipeline v8.2), according to the  
103 read scores and Z-score for the genus compared with the non-AES and no-template controls.

104

## 105 **Results**

106 During the outbreak season from July to September 2023, 49,544 subjects visited Himalayan Eye  
107 Hospital with conjunctivitis diagnosed (clinically) in 14,926 subjects (30.1%). The detailed case  
108 distribution during this period has been presented in Table 1.

109

110

111 **Table 1:** Case distribution during the conjunctivitis outbreak from July-September 2023, in  
112 Himalaya Eye Hospital, Pokhara

113

114

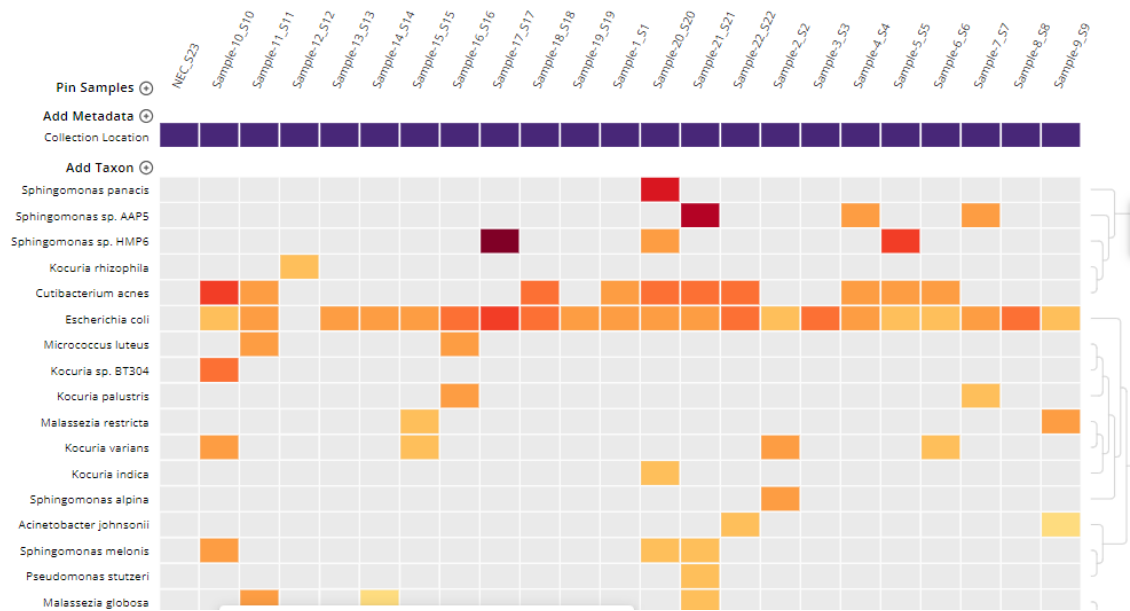
SN	Time Period	Total number of patients	Total number of conjunctivitis cases	Male conjunctivitis cases/Total male patients	Female conjunctivitis cases/Total female patients
1	15 July to 31 July 2023	11,140	580 (5.2%)	323/4,793	257/6,347
2	1 August to 31 August 2023	24,922	12,561 (50.4%)	6,727/12,146	5,825/12,770
3	1 September to 30 September 2023	13,482	1,785 (13.2%)	911/6,051	874/7,430

115

116 The majority of the cases presented with sudden onset of foreign body sensation with redness in  
 117 one eye followed by involvement of the other eye in 1-2 days. There was presence of watery  
 118 discharge, minimal pain, occasional lid swelling but prominent redness in some part of  
 119 conjunctiva suggestive of acute hemorrhagic conjunctivitis. The management were done with the  
 120 use of ocular lubricants, care of personal hygiene and topical antibiotics as per need.

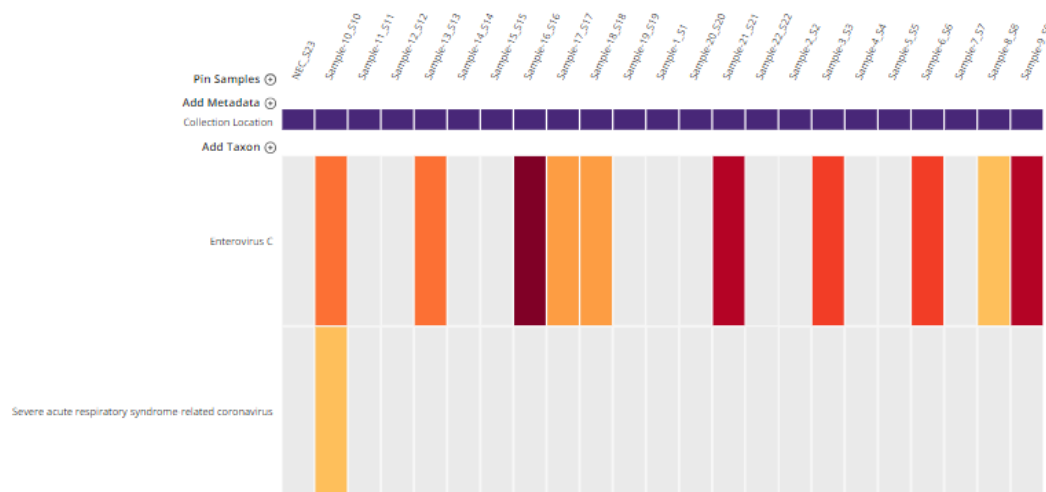
121 Among the conjunctival swabs received at DHKUH, samples from 22 subjects were evaluated at  
 122 DHKUH using unbiased metagenomic next generation sequencing.

123



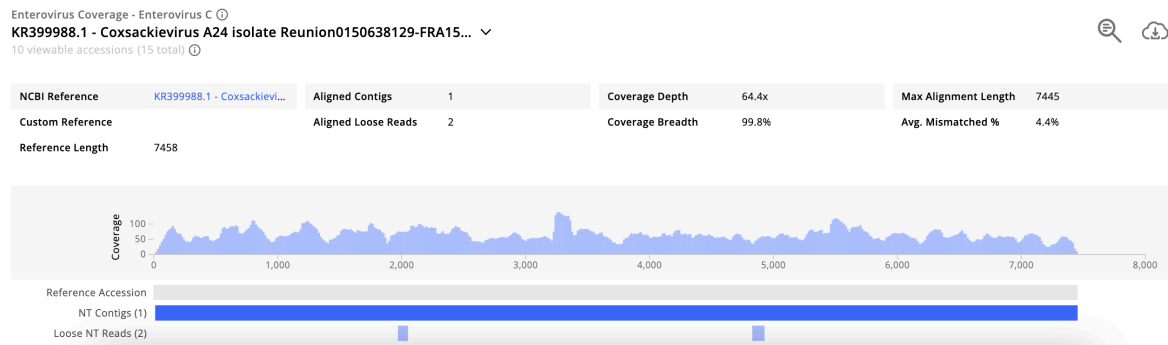
124 **Figure 1:** Heatmap of libraries for S1 to S22: The organisms (at the genus level) that were seen  
 125 in the samples are shown on x axis, while the names of the samples are on the y axis. NEC in the  
 126 figure stands from Negative Extraction Control, while NLC (Negative Library Control) did not  
 127 enough reads to be seen in the heatmap. This heatmap used the background model from  
 128 conjunctival samples of healthy controls with threshold of NT rPM (nucleotide reads per million)  
 129  $\geq 10$  and NT L (alignment length in basepairs: length of the aligned sequence)  $\geq 50$

130



131 **Figure 2:** Heatmap of top hits, of viral origin, from sequencing of libraries for S1 to S22. This  
 132 heatmap used the background model from eye samples of healthy controls with the threshold of  
 133 NT rPM (nucleotide reads per million)  $\geq 10$  and NT L (alignment length in basepairs: length of  
 134 the aligned sequence)  $\geq 50$ .

135 As seen in figure 1, most of the samples had *Cutibacterium acnes* and *Escherichia coli*. We have  
136 also found this organism as part of healthy conjunctival flora, as per our previous studies  
137 (unpublished data). Other organisms observed that could likely cause conjunctivitis, were  
138 *Micrococcus luteus* and *Sphingomonas spp.* Enterovirus C (coxsackievirus strain A24) was seen  
139 in total of 11 samples (Figure 2), while four samples (S3, S9, S16, S21) had coverage width  
140 >95% for A24 strain, as seen in figure 3.



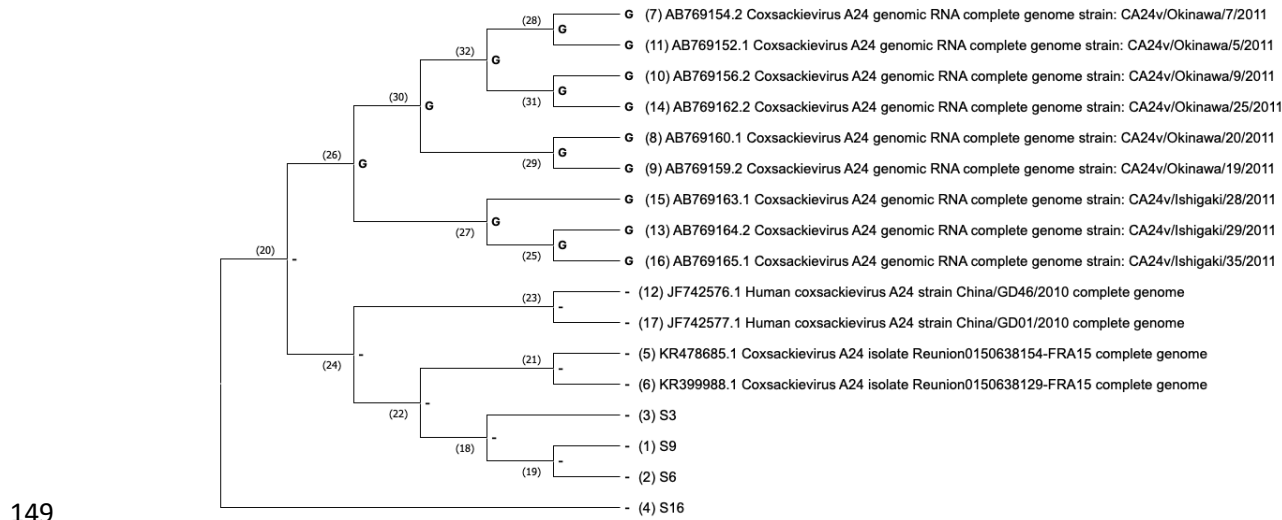
141

142

**Figure 3:** Coverage visualisation of sample S16 for Enterovirus C.

143 The phylogenetic analysis of the consensus Enterovirus C genomes showed variation from other  
144 reported ocular infections associated coxsackievirus (from studies in China, Japan and France).  
145 Additionally, samples S3, S6 and S9 slightly had some common genomic regions with  
146 coxsackieviruses isolates from France. The phylogeny was made using maximum likelihood  
147 statistical method (Mega X), Tamura-Nei model with nearest neighbor interchange as the  
148 maximum likelihood heuristic method.





150 **Figure 4:** Phylogenetic analysis of four high coverage samples (S3, S6, S9, S16) against other  
151 coxsackievirus genomes, from NCBI, reported to have caused ocular infections.

152

## 153 Discussion

154 The recent outbreak of conjunctivitis started in mid-July, peaked in August with half of the cases  
155 visiting the hospital, suffering from conjunctivitis. [20] This prevalence then decreased in  
156 September 2023.

157 The major pathogen causing the mass outbreak of conjunctivitis in 2023 was found to be  
158 *Enterovirus C* (coxsackievirus strain A24). Enterovirus family is one of the most common causes  
159 of viral conjunctivitis.[25] However, this particular strain A24, first observed in 1970, is known  
160 to cause highly contagious conjunctivitis and has a short incubation period of 12 hours to 3 days.  
161 [26, 27] This might be the reason behind sudden spike of cases in Nepal as this same strain has  
162 previously been reported to cause several outbreaks throughout the world, with one study  
163 revealing import of the virus from Asia. [28, 29]

164 *Cutibacterium acnes*, which is a normal flora and an opportunistic infectant was seen.[21] The  
165 samples also had *E. coli*, which is known to cause eye infections such as conjunctivitis. Two  
166 samples (S11 and S16) had hits for *Micrococcus luteus*, known to cause keratitis, which needs to  
167 be further confirmed through polymerase chain reaction (PCR). [23] Few samples also had  
168 *Sphingomonas spp* in them. Studies have shown that certain *Sphingomonas spp.* cause eye  
169 infections.[24] Interestingly, one of the subjects also showed SARSCOV2 in the conjunctival  
170 swab. Though some studies have found evidences of SARSCOV2 positive conjunctivitis, this  
171 could be remnants of respiratory COVID infection in the subject because this particular hit had  
172 only few reads. [31]

173 Our findings correlated to results of PCR tests from National Public Health Laboratory (NPHL),  
174 which found enterovirus in eight of ten samples collected from a hospital in Lalitpur, Nepal.[30]  
175 However, the sub type and strain was not identified or reported in their analysis. The unbiased  
176 mNGS approach, in our investigation, was able to find numerous possible organisms, of viral or  
177 bacterial origin, in a single evaluation, including the strain. The targeted molecular approaches  
178 such as PCR, on the other hand, require prior information of genetic material and  
179 microbiological methods are only able to identify the presumed cause of ocular infection in about  
180 40% cases. [32] Furthermore, the sequencing approach also visualizes the variability of the  
181 microbiome. [32, 33] As seen, we were able to identify the diverse organisms observed and  
182 additionally identified the sub-type and strain of Enterovirus C, the coxsackievirus A24.  
183 These A24 strains of ENV-C were, in general, genomically different from other reported ocular  
184 infections associated coxsackievirus (from studies in China, Japan and France). [34-36]  
185 However, samples S3, S6 and S9 slightly had some common genomic regions with  
186 coxsackieviruses from a study in France. [34] This particular study also reported these viruses

187 being involved in a major conjunctivitis outbreak in Reunion region of France in 2015, with red  
188 eye being the most common symptom, similar to our investigation. [34]

189 Thus, our investigation depicted the strain of enterovirus (A24) responsible for conjunctivitis  
190 outbreak in Nepal and supported the use of unbiased mNGS approach for deeper investigation of  
191 ocular infections, for instance in identification of viruses to strain level.

192

## 193 **Declarations**

### 194 **Ethics approval and consent to participate**

195 This study was ethically cleared from IRC-KUSMS. This study directly did not contact the  
196 human subjects and investigated stored conjunctival samples and secondary clinical and  
197 demographic metadata.

### 198 **Consent for publication**

199 Not Applicable.

### 200 **Availability of data and materials**

201 All data generated or analyzed during this study are included in this article.

### 202 **Competing interests**

203 The authors declare that they have no competing interests.

### 204 **Authors' contributions**

205 Conceptualization: Rajeev Shrestha, Ranju Kharel, Eliya Shrestha; Methodology: Rajeev  
206 Shrestha and Nishan Katuwal; Investigation: Nishan Katuwal and Aastha Shrestha; Resources:

207 Rajeev Shrestha, Nishan Katuwal; Data curation: Eliya Shrestha and Nishan Katuwal; Writing-  
208 original draft preparation: Eliya Shrestha and Nishan Katuwal; Writing-review and editing: all  
209 authors; Supervision: Rajeev Shrestha; Project administration: Rajeev Shrestha. All authors have  
210 read and agreed to the published version of the manuscript.

211

## 212 **Acknowledgments**

213 We gratefully acknowledge the participants and research staffs from Himalaya Eye Hospital and  
214 Dhulikhel Hospital Kathmandu University Hospital.

215

216

217

218

219

220

221

222

223

224

225

226 **References**

- 227 1. Azari AA, Arabi A. Conjunctivitis: A Systematic Review. *J Ophthalmic Vis Res.* 2020 Aug  
228 6;15(3):372-395. doi: 10.18502/jovr.v15i3.7456. PMID: 32864068; PMCID: PMC7431717.
- 229 2. Solano D, Fu L, Czyz CN. Viral Conjunctivitis. [Updated 2023 Apr 20]. In: StatPearls  
230 [Internet]. Treasure Island (FL): StatPearls Publishing; 2023 Jan-. Available from:  
231 <https://www.ncbi.nlm.nih.gov/books/NBK470271/>
- 232 3. Infections of the Eye Thomas W. Hejkal, in *xPharm: The Comprehensive Pharmacology*  
233 *Reference*, 2007
- 234 4. Udeh BL, Schneider JE, Ohsfeldt RL. Cost effectiveness of a point-of-care test for adenoviral  
235 conjunctivitis. *Am J Med Sci.* 2008 Sep;336(3):254-64.
- 236 5. Azari AA, Barney NP. Conjunctivitis: a systematic review of diagnosis and treatment. *JAMA.*  
237 2013 Oct 23;310(16):1721-9.
- 238 6. Epling J. Bacterial conjunctivitis. *BMJ Clin Evid* 2012;2012:0704.
- 239 7. Hovding G. Acute bacterial conjunctivitis. *Acta Ophthalmol* 2008;86:5–17.
- 240 8. Shields T, Sloane PD. A comparison of eye problems in primary care and ophthalmology  
241 practices. *Fam Med* 1991;23:544–546.
- 242 9. Gallenga PE, Lobefalo L, Colangelo L, Della Loggia G, Orzalesi N, Velati P, et al. Topical  
243 lomefloxacin 0.3% twice daily versus tobramycin 0.3% in acute bacterial conjunctivitis: a  
244 multicenter double-blind phase III study. *Ophthalmologica* 1999;213:250–257
- 245 10. Ryder EC, Benson S. Conjunctivitis. In: StatPearls. Treasure Island (FL): StatPearls  
246 Publishing LLC; 2020.
- 247 11. Rietveld RP, ter Riet G, Bindels PJ, Schellevis FG, van Weert HC. Do general practitioners  
248 adhere to the guideline on infectious conjunctivitis? Results of the Second Dutch National  
249 Survey of General Practice. *BMC Fam Pract.* 2007 Sep 16;8:54.
- 250 12. Sethuraman U, Kamat D. The red eye: evaluation and management. *Clin Pediatr (Phila).*  
251 2009 Jul;48(6):588-600
- 252 13. Elnifro EM, Cooper RJ, Klapper PE, Yeo AC, Tullo AB. Multiplex polymerase chain reaction  
253 for diagnosis of viral and chlamydial keratoconjunctivitis. *Invest Ophthalmol Vis Sci.* 2000  
254 Jun;41(7):1818-22.)
- 255 14. Kam KY, Ong HS, Bunce C, Ogunbowale L, Verma S. Sensitivity and specificity of the  
256 AdenoPlus point-of-care system in detecting adenovirus in conjunctivitis patients at an  
257 ophthalmic emergency department: a diagnostic accuracy study. *Br J Ophthalmol.* 2015  
258 Sep;99(9):1186-9.)
- 259 15. Doan T., Wilson M.R., Crawford E.D. Illuminating uveitis: metagenomic deep sequencing  
260 identifies common and rare pathogens. *Genome Med.* 2016;8:90.
- 261 16. Metagenomics in ophthalmology: Hypothesis or real prospective?
- 262 17. Kang Y, Lin S, Ma X, Che Y, Chen Y, Wan T, et al. Strain heterogeneity, cooccurrence  
263 network, taxonomic composition and functional profile of the healthy ocular surface  
264 microbiome. *Eye Vis.* (2021) 8:6. 10.1186/s40662-021-00228-4;
- 265 18. Deng Y, Wen X, Hu X, Zou Y, Zhao C, Chen X, et al. Geographic difference shaped human  
266 ocular surface metagenome of Young Han Chinese From Beijing, Wenzhou, and Guangzhou  
267 Cities. *Invest Ophthalmol Vis Sci.* (2020) 61:47. 10.1167/iovs.61.2.47
- 268 19. (Rathi VM, Murthy SI. Allergic conjunctivitis. *Commun Eye Health* 2017;30:S7–S10.
- 269 20. (<https://kathmandupost.com/health/2023/08/07/number-of-viral-conjunctivitis-patients-rise>)

- 270 21. Mayslich C, Grange PA, Dupin N. Cutibacterium acnes as an Opportunistic Pathogen: An  
271 Update of Its Virulence-Associated Factors. *Microorganisms*. 2021 Feb 2;9(2):303. doi:  
272 10.3390/microorganisms9020303. PMID: 33540667; PMCID: PMC7913060.
- 273 22. Nunes PHS, Valiatti TB, Santos ACM, Nascimento JADS, Santos-Neto JF, Rocchetti TT, Yu  
274 MCZ, Hofling-Lima AL, Gomes TAT. Evaluation of the Pathogenic Potential of Escherichia coli  
275 Strains Isolated from Eye Infections. *Microorganisms*. 2022 May 25;10(6):1084. doi:  
276 10.3390/microorganisms10061084. PMID: 35744602; PMCID: PMC9229993.
- 277 23. Taneja M, Rathi VM, Bagga B, Murthy SI, Ashar J, Reddy AK, Vaddavalli PK. Micrococcus  
278 keratitis following microkeratome-assisted laser in situ keratomileusis. *Oman J Ophthalmol*.  
279 2019 Oct 11;12(3):203-205. doi: 10.4103/ojo.OJO\_54\_2017. PMID: 31903000; PMCID:  
280 PMC6826603.
- 281 24. Agarwal R, Gagrani M, Mahajan A, Sharma N. Fulminant Sphingomonas paucimobilis  
282 keratitis: case study and review of literature. *BMJ Case Rep*. 2019 Dec 3;12(12):e231642. doi:  
283 10.1136/bcr-2019-231642. PMID: 31801779; PMCID: PMC7001691.
- 284 25. Muto T, Imaizumi S, Kamoi K. Viral Conjunctivitis. *Viruses*. 2023 Mar 4;15(3):676. doi:  
285 10.3390/v15030676. PMID: 36992385; PMCID: PMC10057170.
- 286 26. Mirkovic RR, Schmidt NJ, Yin-Murphy M, Melnick JL. Enterovirus etiology of the 1970  
287 Singapore epidemic of acute conjunctivitis. *Intervirology*. 1974;4(2):119-27. PMID: 4217326
- 288 27. Heymann DL. Control of communicable diseases manual. 19th Edition. Washington, DC:  
289 American Public Health Association;2008. p.746.
- 290 28. Lévêque N, Huguet P, Norder H, Chomel JJ. Les Enterovirus responsables de conjonctivite  
291 aiguë hémorragique [Enteroviruses responsible for acute hemorrhagic conjunctivitis]. *Med Mal*  
292 *Infect*. 2010 Apr;40(4):212-8. French. doi: 10.1016/j.medmal.2009.09.006. PMID: 19836177.
- 293 29. Dussart P. Outbreak of Acute Hemorrhagic Conjunctivitis in French Guiana and West Indies  
294 Caused by Coxsackievirus A24 Variant: Phylogenetic Analysis Reveals Asian Import. *Journal of*  
295 *Medical Virology*. 2003. 75:559–565)
- 296 30. [https://reliefweb.int/report/nepal/focused-covid-19-media-monitoring-nepal-august-11-2023-](https://reliefweb.int/report/nepal/focused-covid-19-media-monitoring-nepal-august-11-2023-enne)  
297 [enne](https://reliefweb.int/report/nepal/focused-covid-19-media-monitoring-nepal-august-11-2023-enne) )
- 298 31. Schrage N, Blomet J, Holzer F, Tromme A, Ectors F, Desmecht D. Eye Infection with SARS-  
299 CoV-2 as a Route to Systemic Immunization? *Viruses*. 2022 Jun 30;14(7):1447. doi:  
300 10.3390/v14071447. PMID: 35891426; PMCID: PMC9318776.
- 301 32. Borroni D, Romano V, Kaye SB, Somerville T, Napoli L, Fasolo A, Gallon P, Ponzin D,  
302 Esposito A, Ferrari S. Metagenomics in ophthalmology: current findings and future perspectives.  
303 *BMJ Open Ophthalmol*. 2019 Jun 4;4(1):e000248. doi: 10.1136/bmjophth-2018-000248.  
304 Erratum in: *BMJ Open Ophthalmol*. 2019 Jun 27;4(1):e000248corr1. PMID: 31276030; PMCID:  
305 PMC6557081.
- 306 33. Jing D, Jiang X, Ren X, Su J, Huang C, Yang J, Hao R, Li X. Metagenomic nanopore  
307 sequencing of ocular microbiome in patients with meibomian gland dysfunction. *Front Med*  
308 (Lausanne). 2022 Nov 9;9:1045990. doi: 10.3389/fmed.2022.1045990. PMID: 36438054;  
309 PMCID: PMC9682043.
- 310 34. Marguerite N, Brottet E, Pagès F, Jaffar-Bandjee MC, Schuffenecker I, Josset L, Vilain P,  
311 Filleul L. A major outbreak of conjunctivitis caused by coxsackievirus A24, Réunion, January to  
312 April 2015. *Euro Surveill*. 2016 Jun 30;21(26). doi: 10.2807/1560-7917.ES.2016.21.26.30271.  
313 PMID: 27387200.

- 314 35. Nidaira M, Kuba Y, Saitoh M, Taira K, Maeshiro N, Mahoe Y, Kyan H, Takara T, Okano S,  
315 Kudaka J, Yoshida H, Oishi K, Kimura H. Molecular evolution of VP3, VP1, 3C(pro) and  
316 3D(pol) coding regions in coxsackievirus group A type 24 variant isolates from acute  
317 hemorrhagic conjunctivitis in 2011 in Okinawa, Japan. *Microbiol Immunol.* 2014 Apr;58(4):227-  
318 38. doi: 10.1111/1348-0421.12141. PMID: 24517637.
- 319 36. Wu,D., Zheng,H.Y., Li,H., Guo,X., Liu,L., Zeng,H.R. and Mo,Y.L., Molecular characteriza-  
320 tion of a coxsackievirus A24 variant that caused acute haemorrhagic conjunctivitis in Guang-  
321 dong, China 2010. Unpublished.