

1 Fungal pleural infection due to *Microascus gracilis* with pulmonary aspergillosis after COVID-19 pneumonia

2 Zhi-Min Hu¹ | Li-Na Mao² | Ti-Ying Deng³ | Bin-Tao Su¹ | Yi Yang⁴ | Bi-Lin Dong⁵ | Qing Xu² | Shuo Yang²

3 ¹ Department of Laboratory Medicine, Wuhan No.1 Hospital, Wuhan, China

4 ² Department of Pulmonary and Critical Care Medicine, Wuhan No.1 Hospital, Wuhan, China

5 ³ Department of Pharmacy, Wuhan No.1 Hospital, Wuhan, China

6 ⁴ Department of Radiology, Wuhan No.1 Hospital, Wuhan, China

7 ⁵ Hubei Key Laboratory for Infectious and Immune of Dermatitis, Wuhan, China

8 **Correspondence:** Shuo Yang, Department of Pulmonary and Critical Care Medicine, Wuhan No.1 Hospital, Wuhan 430022, China.

9 Email:244135490@qq.com

10

11 Abstract

12 **Background:** *Scopulariopsis/Microascus* is a rare but devastating pathogen due to its intrinsic resistance to nearly all available antifungal agents. *Microascus gracilis*, an ascomycetous mould
13 in the order *Microascales*, family *Microascaceae*, has recently emerged as a significant invasive pathogen causing opportunistic infections.

14 **Objectives and Methods:** We present a case of pleural infection caused by *M. gracilis* with pulmonary aspergillosis in an immunocompromised man after COVID-19 pneumonia. To further
15 understand the characteristics of the pathogen isolated from the patient, we identified the strain through mycological characteristics, matrix-assisted laser desorption/ionization (MALDI)
16 time-of-flight (TOF) mass spectrometry (MALDI-TOF MS) and internal transcribed spacer (ITS)-based sequencing, and performed *in vitro* drug susceptibility testing against common antifungal
17 agents. Moreover, we assessed lymphocyte subsets and programmed cell death protein 1 (PD-1) expression in peripheral blood and pleural effusion to monitor the efficacy of therapy with
18 thymosin- α -1 and intravenous immunoglobulin.

19 **Results:** Filamentous fungi isolated from pleural fluid were identified as *M. gracilis* based on classical morphology, mass spectrometry and molecular biology methods. The susceptibility results
20 *in vitro* revealed that multiple antifungal agents were inactive against the strain. Adjuvant immunomodulatory treatment successfully increased the levels of CD3+ T and CD4+ T cells while
21 decreasing the levels of CD3+PD-1+ and CD4+PD-1+ T cells in both peripheral blood and pleural effusion.

22 **Conclusions:** The immunocompromised host with opportunistic *M. gracilis* infection, rapid and accurate recognition through direct microscopic testing with calcofluor white and MOLDI-TOF
23 MS, is the key to achieving a definite diagnosis, and a combination of antifungal therapy with immunomodulatory therapy is vital for improving survival.

24

25 KEYWORDS

26 *Microascus gracilis*, *Scopulariopsis*, *Microascus*, Pleural effusion, COVID-19, Pneumonia

27

28 1 | INTRODUCTION

29

30 Pleural infection is a millennium-spanning condition that has been shown to be challenging to treat over many years.¹ Fungi are uncommon causes of pleural infection and
31 represent 3% of isolated pathogens,² but there should be a strong suspicion of underlying dormant fungal infection for differential diagnosis when episodes of pleural
32 effusions are encountered. Fungal infections tend to occur in patients with underlying immunocompromising conditions, and the most common isolated are *Candida* spp.³ As
33 already well documented in medical articles, both immunocompromised and immunocompetent hosts are at an increased risk for developing fungal infections, most
34 commonly *Candida* spp. and *Aspergillus* spp., but other opportunistic filamentous fungi have been emerging in recent years.⁴ In particular, even though infections of the
35 genera *Scopulariopsis*/*Microascus* are very rare, as already reviewed, they are associated with high morbidity and mortality in the clinical setting due to delayed diagnosis
36 and intrinsic resistance to currently available antifungal agents.⁴ These fungi are commonly isolated from soil, air, decaying organic material, dung, insects and moist indoor
37 environments.⁴⁻¹⁰ *M. gracilis*, the species of the genus *Microascus*, was first isolated in 1962 from food in Japan by Inagaki.¹¹ In the past, it was known as *Scopulariopsis*
38 *gracilis*, which has been recategorized and designated *M. gracilis*.¹⁰ Due to the increase in predisposing factors in parallel with medical technological advances, the number of
39 cases caused by these organisms has been on the rise.

40

41 2 | CASE REPORT

42

43 An old male presented to the hospital with cough and yellow phlegm lasting for one week followed by fever and progressive dyspnoea that developed 2 days prior to
44 admission. In December 2022, coronavirus disease 2019 (COVID-19) was diagnosed by RT-PCR for severe acute respiratory syndrome coronavirus (SARS-CoV-2) and
45 recovered with therapeutic strategies for COVID-19 pneumonia. Two month after discharge, the patient was diagnosed with nephrotic syndrome and received treatment with
46 an immunosuppressive regimen of prednisone and cyclophosphamide. The patient reported a history of hypertension for almost 10 years, and his blood pressure was
47 controlled well by using amlodipine and metoprolol. The patient's underlying conditions included chronic obstructive pulmonary disease (COPD), interstitial pneumonia, and
48 steroid-induced diabetes. On physical examination, he was revealed to be sick with wheezing and subcostal retraction requiring supplemental oxygen delivered by standard
49 nasal cannula. There was no clinical evidence of onychomycosis or paronychia. At presentation, his body temperature was 37.6 °C, his blood pressure was 142/88 mmHg,
50 and his pulse was 92 bpm. His blood work showed an elevated leukocyte count of 13.43×10^9 cells/L, haemoglobin 137 g/L, platelets 131×10^9 /L, high sensitivity c-reactive
51 protein (hsCRP) 11.1 mg/L, erythrocyte sedimentation rate (ESR) 19 mmHg, (1,3)-beta-d-glucan (G test) 100.65 pg/mL, and IL-6 11.94 pg/mL. Serologies for the

52 galactomannan antigen test (GM test), syphilis, acquired immunodeficiency syndrome, and hepatitis A–E were negative. Blood and urine cultures were sterile. Chest
53 computed tomography (CT) examination showed a new right-sided pneumothorax, and ground-glass opacities (GGOs) were diffusely distributed in both lungs, especially in
54 the middle and lower lobes of the right lung (Figure 1A).

55 The timeline of diagnosis and targeted therapy is shown in Table 1. On Day 1, thoracentesis was performed, and the chest tube drainage system was maintained in an
56 upright position below the patient's chest to facilitate drainage. After that, the patient had recurrent infections in the lungs, and *Acinetobacter baumannii* and *Aspergillus*
57 *fumigatus* were detected in sputum. Pulmonary symptoms were usually reduced or alleviated by empirical broad-spectrum antibiotics, including ceftriaxone/tazobactam,
58 levofloxacin, fluconazole (FLZ) and voriconazole (VRC), for approximately 3 weeks. On Day 32, *Enterococcus faecalis* was incubated in the pleural fluid, and
59 anti-biotherapy was adjusted to vancomycin for 3 weeks. The signs and symptoms of spontaneous hydropneumothorax were improved. On Day 65, the pathogen causing
60 pleural reinfection was *Streptococcus sanguinis*, and the therapeutic agent was switched to ceftriaxone/tazobactam for 2 weeks. On Day 73, the symptoms of pneumonia and
61 empyema were alleviated, and he was discharged home with intercostal drainage (ICD) *in situ*. Eight days later, he was readmitted because of worsening of dyspnoea, cough
62 and wheezing, and no fever. According to the patient's recollection, the chest drain was unsecure for fixation and accidental removal in house. His blood work showed a low
63 absolute lymphocyte count 320/L. Abnormal laboratory findings included elevated hsCRP 189.3 mg/L and peripheral blood cytomegalovirus 1070 copies/ml. Repeated CT
64 revealed a drainage tube, a cavity with an air-crescent sign and reduced hydropneumothorax in the right pleural cavity (Figure 1B). *Klebsiella pneumoniae* was detected in
65 sputum, and anti-biotherapy was switched to latamoxef and valganciclovir for two weeks. After unplanned extubation, the new pleural catheter was reintubated away from
66 the original region (Figures 2A). The culture from the removed chest tube was positive for mould growth. From Day 89 to Day 93, multiple cultures of pleural fluid from the
67 new tube were positive for the same mould. Calcofluor white staining revealed many pigmented, septate fungal hyphae (Figures 2B) of the pleural fluid and septate fungal
68 hyphae of BALF. In addition, the sample was separately inoculated onto Sabouraud's dextrose agar (SDA) at 35 °C. The T-spot test and MTB/RIF GeneXpert detection
69 assays were negative. Both G and GM tests were negative in serum and pleural fluid. However, the antifungal strategy of caspofungin (CAS, 50 mg/day) and posaconazole
70 (POS, 0.3 g/day) was initiated despite the discouraging result of *in vitro* susceptibilities, and improvement of pleural effusion was achieved after 5 weeks of treatment. No
71 adverse events were reported. On Day 95, intermittent fever was observed after the administration of the combined antifungal therapy. The serum and pleural fluid GM tests
72 were still negative, and blood cultures were all sterile. A quantitative real-time PCR assay was developed to measure the human cytomegalovirus (HCMV) DNA load in
73 peripheral blood, which was 2589 copies/ml. The BALF collected for metagenomics next generation sequencing (mNGS) showed high sequence numbers and relative
74 abundance of *Pneumocystis jirovecii*, *Aspergillus fumigatus*, HCMV and EBV. The BALF GM antigen test was positive. With regard to the patient's immunological and
75 infectious condition, clindamycin 1.2 g/day, thymosin- α -1 4.8 mg/week and intravenous immunoglobulin 400 mg/kg/week were added. On Day 119, the symptoms of the

76 lungs and pleural infection were relieved, the chest tube was removed, and the culture of the pleural catheter, pleural effusion and sputum were all negative. On Day 146, the
77 nucleic acid of cytomegalovirus was normal, and the high level of CRP and persistent low level of absolute lymphocyte count were relieved. A chest CT scan showed that
78 bilateral lung infection and pneumothorax were partly absorbed, lung tissue compression was less than 3%, and pleural effusion was reduced. The patient was discharged with
79 no chief complaints and switched to terbinafine (TEB) 250 mg/day combined with POS 0.3 g/day for 4 weeks. After 3 months of follow-up, the patient had no obvious
80 discomfort.

81

82 **3 | MATERIALS AND METHODS**

83 The authors confirm that the ethical policies of the journal, as noted on the journal's author guidelines page, have been adhered to and that appropriate ethical review
84 committee approval has been received.

85

86 **3.1 | Fungal pathogen identification**

87 Microbiological tests were implemented with pleural fluid, puncture drainage tubes and bronchoalveolar lavage fluid (BALF). The isolates obtained were identified by
88 examination of micromorphological and macromorphological characteristics. After pretreatment with 70% formic acid and α -cyano-4-hydroxycinnamic acid (HCCA,
89 Sigma–Aldrich). The strains were identified by matrix-assisted laser desorption/ionization (MALDI) time-of-flight (TOF) mass spectrometry (MALDI-TOF MS, Zybion
90 EXQ2000, Zhongyuan Huiji Biotechnology Co. Ltd.) according to the standard operation protocol.¹² Mycelia were mechanically disrupted by liquid nitrogen grinding,
91 followed by genomic DNA extraction using QIAGEN's DNeasy® Plant Kit.¹³ The internal transcribed spacer region (ITS) was amplified with the primer pair ITS1
92 (5'-TCCGTAGGTGAACCTGCGG-3') and ITS4 (5'-TCCTCCGCTTATTGATATGC-3'). DNA sequences were analysed using NCBI BLAST
93 (<https://blast.ncbi.nlm.nih.gov/Blast.cgi>).

94

95 **3.2 | Antifungal susceptibility testing**

96 *In vitro* susceptibility was tested according to the guidelines presented in document M38-A₂ of the Clinical and Laboratory Standards Institute (CLSI).¹⁴ The minimum
97 inhibitory concentration (MIC) was determined visually as the concentration that resulted in 100% inhibition. The minimal effective concentration (MEC) endpoint was taken
98 as the lowest concentration at which the visual growth pattern change from granular to filamentous growth was detected, microscopically seen as restricted hyphal

99 growth.^{14,15}

100

101 **3.3 | Flow cytometry analysis**

102 To monitor lymphocyte subsets and programmed cell death protein 1 (PD-1) expression in peripheral blood and pleural effusion to evaluate the efficacy of therapy with
103 thymosin- α -1 and intravenous immunoglobulin, simultaneous identification and enumeration of T lymphocytes in whole blood and multicolour flow cytometric analysis of
104 lymphocyte subsets as well as CD4+ and CD8+ T-cell subset ratios were determined using an automated AQUIOS cytometer (Beckman Coulter), as per the manufacturer's
105 instructions for use. Each site had an instrument and all needed reagents. Ten millilitres of pleural fluid was passed through a 40 μ m filter, and the cellular pellet was spun
106 down. Then, red blood cells (RBCs) were lysed using a soft RBC lysing solution (Beckman Coulter). Cellular viability was then assessed using fluorescent reactive dye.¹⁶

107

108 **3.4 | Literature review**

109 We performed a literature search of *Scopulariopsis* or *Microascus* pleural infection and *Scopulariopsis gracilis* or *Microascus gracilis* infection published from 1962 to 2023
110 via the PubMed database (<https://pubmed.ncbi.nlm.nih.gov/>). In addition, the references cited in these reports have been reviewed to identify additional cases that were not
111 found in the PubMed database. The review included an assessment of all demographic features, including year/nation, age/gender, underlying disease, transplant type,
112 systemic antifungal agents before infection, involved sites, identified fungal organisms, treatment and therapeutic outcomes. Only those cases that met the criteria for “proven
113 invasive fungal disease” caused by moulds as described by the consensus group of the European Organization for Research and Treatment of Cancer/Invasive Fungal
114 Infections Cooperative Group and the National Institute of Allergy and Infectious Diseases Mycoses Study Group (EORTC/MSG) were included in this evaluation.¹⁷

115

116 **4 | RESULTS**

117 **4.1 *M. gracilis* and *A. fumigatus* were identified according to classical morphology, mass spectrometry and molecular biology methods.**

118 Colonies grown on SDA were first visible on Day 2 of incubation and developed into small mould colonies over the next few days (Figure 2C). The colonies were initially
119 pale but developed a velvety and olivaceous grey colour after 2 weeks. Lacto-phenol cotton blue mounts of the colonies showed conidiophores mostly irregularly branched,
120 usually consisting of clusters of 2 to 3 annellides borne on short branches. Annellides lageniform or somewhat cylindrical with a slightly swollen base. Conidia subspherical
121 to ellipsoidal, with truncate base and rounded or pointed apex, arranged in long chains (Figure 2D). *M. gracilis* and *A. fumigatus* were identified by mycological

122 characteristics, MALDI-TOF MS (Figure 2E) and ITS-based sequencing (accession no. OR131328).

123

124 **4.2 *M. gracilis* manifests as a multidrug-resistant strain**

125 The results revealed that multiple antifungal agents were inactive against *M. gracilis*, with MIC values of 4 µg/ml for amphotericin B (AMB), 8 µg/ml for VRC, > 8 µg/ml for
126 POS, >16 µg/ml for itraconazole (ITC), >64 µg/ml for 5-flucytosine (5-FC), >256 µg/ml for FLZ, and minimal effective concentration (MEC) values all > 8 µg/ml for
127 echinocandins. The susceptibility profiles of *A. fumigatus* showed POS 0.06 µg/ml, ITC 0.12 µg/ml, VRC 1 µg/ml, AmB 4 µg/ml, 5-FC >64 µg/ml and echinocandins all 8
128 µg/ml.

129

130 **4.3 Adjuvant immunomodulatory treatment successfully increased the levels of CD3+ T and CD4+ T cells while decreasing the levels of CD3+PD-1+ T and 131 CD4+PD-1+ T cells**

132 The inflammatory indicators, lymphocyte subsets and PD-1 expression in peripheral blood and pleural effusion were evaluated before and after adjuvant immunomodulatory
133 treatment with thymosin- α -1 and intravenous immunoglobulin. The levels of CD3+ T cells and CD4+ T cells were alleviated (Figure 3), while CD3+PD-1+ T cells and
134 CD4+PD-1+ T cells were all decreased significantly both in blood (Figure 4) and pleural effusion (Figure 5) after the immunomodulatory agents were administered. Other
135 abnormal biochemical biomarkers, such as hsCRP and IL-6 in peripheral blood and LDH, ADA, IL-1 β and IL-6 in pleural diffusion, all declined substantially. (Table 2)

136

137 **4.4 Literature review**

138 A review of the English literature since 1962 identified 5 cases reported as proven pleural *Scopulariopsis/Microascus* infections.¹⁸⁻²² The reported cases listed in Table 3 had a
139 median age of 52.8 years (range 27-70 years) and represented 6 males. Of these cases, 2 were from the USA, and 1 each was from Belgium, India, France and China. Of these
140 patients, 80% had solid organ transplant (SOT), and all were associated with lung transplantation. Sixty percent of patients were treated with azole antifungal prophylaxis.
141 Because of the isolate morphologically identified as *M.cinereus* was found after sequencing to be from *M. gracilis*.^{4,10} The most commonly identified species was *M. gracilis*
142 (3/6, 50%), followed by *S. brumptii* (2/6, 33.3%) and *S. acremonium* (1/6, 16.7%). Combined therapies were performed when diagnostic clues were found, but the therapeutic
143 outcomes were worse, as 83.3% of patients died.

144 To date, only six proven cases of *M. gracilis* infections have been reported, including two cases of disseminated infection,^{20,22} two cases of invasive bronchopulmonary

145 infection,^{23,24} and each case of primary subcutaneous infection²⁵ and keratitis.²⁶ A total of 83.3% of cases were underlying diseases that compromised the immune system
146 locally or systemically. A total of 66.7% of patients also received azole antifungal prophylaxis. In addition, 66.7% were cured successfully, while the salvage treatment for
147 two disseminated patients failed.

148

149 **5 | DISCUSSION**

150 *M. gracilis*, the teleomorph of *Scopulariopsis/Microascus spp.*, is a rare opportunistic fungus associated with human disease and is commonly found in soil, decaying organic
151 matter and in-house environments.^{4,7,8,10,22-26} There is a paucity of information available concerning clinical infections caused by *M. gracilis*. Among the ninety-seven clinical
152 strains morphologically identified as *Scopulariopsis/Microascus spp.*, *M. gracilis* was the second most commonly isolated species and was most frequently isolated from
153 BALF and sputum samples.⁸ Most of them, according to the clinical features, were determined to have fungal colonization.⁸ The diagnosis of *Scopulariopsis/Microascus*
154 infections is challenging because of the delay in microbiological study completion.⁴ Precise and timely identification of these pathogens to species can be extremely
155 important when recovered from high-risk patients. However, morphological conclusion requires sporulating culture, which considerably delays the diagnosis, while the
156 developed DNA-based assays for identification are rapid and reliable.²⁷ Typically, the isolate morphologically identified as *M. cinereus* was found after sequencing to be from
157 *M. gracilis*.²⁰ Our strain accurately identified by morphological features, mass spectrometry and ITS-based sequencing is the seventh invasive *M. gracilis* infection, as well as
158 the sixth pleural infection caused by *Scopulariopsis/Microascus spp.*. Notably, in comparison to DNA-based assays, mass spectrometry analysis based on the updated
159 database offers a cost/time-saving and accurate clinical working protocol for identifying both the genus and species levels of the *Scopulariopsis/Microascus* genera.

160 The development of spontaneous hydropneumothorax is a complication of post-COVID-19 pneumonia due to rupture of the small airway.²⁸ A history of recent COVID-19
161 infection is a risk factor for pleuropulmonary infections, particularly in patients with comorbidities, structural defects such as bronchopleural fistula, and immunosuppressive
162 therapies.²⁹ The presence of *M. gracilis* may represent colonization or may cause localized infections at the usual residential location of the superficial tissue or the lungs.^{22,30}
163 As the most representative aetiologic agent in *Scopulariopsis/Microascus spp.* infection of the pleura in extremely limited data, *M. gracilis* occurs less frequently but causes
164 refractory and fatal disseminated infections. Opportunistic infections of this extremely rare fungus have been reported mostly in immunocompromised patients, with most
165 severe infections occurring in solid organ transplant patients, particularly lung transplant patients.^{18,20-24} We suspected that treatment with corticosteroids for nephrotic
166 syndrome might have transiently suppressed immunity, resulting in opportunistic infection. Prognosis is poor, and mortality is high in immunosuppressed patients.^{8,31}
167 Furthermore, it is worth mentioning that more than 60% of patients acquired the infection when they were under antifungal prophylaxis with azole agents. The selective
168 pressure of antifungal prophylaxis may also contribute to the appearance of rarely invasive fungal infections, caused by moulds that are often intrinsically resistant to some

169 classes of antifungals, which have been described as opportunistic pathogens in patients with a variety of underlying diseases.³²⁻³⁴ *Pneumocystis* pneumonia most often occurs
170 in immunocompromised hosts, with intensified or prolonged immunosuppression, notably with corticosteroids and subsequent cytomegalovirus (CMV) infections.³⁵
171 Coinfection with CMV may contribute to further immune dysregulation in haematopoietic cell transplant (HCT) and solid organ transplant (SOT) recipients.³⁶ A total of
172 42.9% of SOT patients had a proven CMV infection that occurred in concurrent infection with *Scopulariopsis/Microascus* spp.,^{18,23,37,38} possibly because CMV can affect
173 several components of the defence system and, therefore, could enhance the pathogenicity of other infectious agents.^{18,23,39} It is worth noting that our patient experienced a
174 persistent low absolute lymphocyte count. Based on the analysis of lymphocyte subsets in peripheral blood and pleural effusion through flow cytometry assays, the number of
175 T lymphocytes was significantly decreased, and T-cell exhaustion occurred. The host cannot control infections effectively because of T-cell exhaustion.⁴⁰ PD-1 together with
176 programmed death-ligand 1 (PD-L1) is a key biomarker of lymphocyte depletion,⁴¹ and upregulation of PD-1 in exhausted T cells as an immunosuppressive receptor was
177 observed during the progression of symptomatic stages of infections, which contributes to the evolution of the severe form of the symptoms. Prognosis largely depends on the
178 immune status of the patient, and immune reconstitution is considered essential when combating invasive fungal infections.⁸ In conclusion, elevated PD-1 levels in CD4+ T
179 cells were associated with the inhibition of cell proliferation and decreased effector functions;⁴² in contrast, blocking or downregulating PD-1 reversed exhausted T cells, and
180 immunosuppressive status resulted in recovery and enhancement of host innate immunity.

181 The potential origin of infection is vastly diverse. Outbreaks of fungal keratitis and invasive disease due to contaminated grafts used to store the issued corneoscleral
182 button,²⁶ soil contamination^{43,44} or inhaled pollution,⁴⁵ respectively, have been described in immunocompetent hosts. In addition to the severe immunocompromised host
183 susceptible to invasion of the opportunistic *Scopulariopsis/Microascus*, especially in those patients who had undergone solid organ transplants, transmission of the fungus
184 from the donor was possible,^{4,21} and the fungus might have been accessed into the pleural space during prehospital placement of thoracostomy tubes²¹ or introduced into the
185 skin and then into the vessels through trauma at a catheter site.⁴⁶ Our patient was another case of catheter-related pleural infection contaminated by the indoor environment.
186 To minimize the fungal equivalent and avoid persistent infection, the contaminated catheter should be removed immediately. The delayed diagnosis and the high rates of
187 resistance of *Scopulariopsis/Microascus* to practically all current antifungals^{8,31,47,48} are responsible for the high mortality associated with disseminated infections.^{18,20,21,22} A
188 spread of pulmonary *Scopulariopsis/Microascus* to the pleura is unlikely in the present case because only pleuritis was detected without apparent pulmonary
189 *Scopulariopsis/Microascus*.

190 Currently, fungal empyema therapy is not protocolized, and combinations that include available agents can be used due to the variable penetration of systemically
191 administered antifungals into the pleural cavity.⁴⁹ First-line treatment for systemic fungal infections, AMB and VRC, and other antifungal agents are ineffective against
192 *Scopulariopsis/Microascus* spp. *in vitro*. The lack of correlation between *in vitro* and *in vivo* studies and the intrinsic resistance of fungal pathogens to many of the available

193 antifungals limits successful therapeutic options.⁵⁰ Susceptibility testing using CLSI or EUCAST methodologies usually shows high MIC values for all currently approved
194 antifungal agents.^{8,47} No cut-off values have been determined, as there are insufficient data to correlate MIC values and clinical outcomes.⁵¹ Nevertheless, *in vitro* synergy has
195 been demonstrated with combinations of POS and TEB, POS and caspofungin (CAS), AMB and CAS, and three drugs in combination.^{30,52} L-AMB (3–10 mg/kg/day) and
196 VRC,^{52,53} VRC alone (i.v. and then oral step-down therapy), and lipid formulations of AMB with other antifungal agents can be moderately recommended.⁵² VRC with an
197 echinocandin and TEB is marginally recommended.^{20,52} Limited literature on *M. gracilis* indicates higher MICs *in vitro*,^{20,22,23,25,30,48} approximately 85.7% of the isolates had
198 high concentrations for AmB, CAS, VOR and POS, except one case had relatively low concentrations for AMB,²² CAS,⁴⁸ VOR and POS,²³ respectively. All strains had high
199 MIC values for FLZ, ITC, and 5-FC. The MEC values of micafungin were 0.25²³ and 1 µg/ml,²² and the MIC of isavuconazole was established at 2 µg/ml.^{22,54} It is worth
200 mentioning that the value of TEB fluctuated obviously from 1 to 16 µg/ml. The fractional inhibitory concentration indices (FICIs) range of CAS, POS, and TRB combination
201 against *M. gracilis* was from 0.321 to 0.320, which appear to be promising, with a synergistic effect on *M. gracilis*.³⁰ The MIC, POS, and TRB combination in invasive
202 infections warranted to be an effective therapy in clinical practice.^{23,24} The other therapeutic strategies include nebulized micafungin for the treatment of
203 *Scopulariopsis/Microascus* tracheobronchitis,⁵⁵ combination of treatment for *Scopulariopsis/Microascus* pneumonia, which included surgery, triple combination of antifungal
204 drugs, and granulocyte-colony stimulating factor.⁵⁶ Moreover, an investigational antifungal within the orotomide class that is currently in late-stage clinical development,
205 olorofim (formerly F901318), demonstrated good *in vitro* activity against the majority of *Scopulariopsis/Microascus* isolates tested, with an MIC₉₀ value of 0.125 mg/L and a
206 modal MIC of 0.03 mg/L.⁵⁷ Surgical debridement (where feasible) and reversal of the host's innate immunodeficiency are critical to survival and are strongly recommended.⁵²
207 Particularly, for immunocompromised patients, intravenous immunoglobulin was essential to reverse the immunological crisis and was obtained with highly effective clinical
208 outcomes.²³ Although there is limited information about thymosin α1 (Tα1) as adjuvant immunomodulatory therapy, either used alone or combined with other treatments, the
209 favourable combination of Tα1 with an anti-PD-1 antibody has already been postulated experimentally. Tα1 may be a treatment option for invasive fungal infection in
210 immunocompromised hosts, but efficacy and safety data remain limited. Our immunocompetent patient was initially treated with CAS combined with POS; when the
211 symptoms and critical biological index were relieved, the POS and TRB combination started as a sequential therapy until he was cured. Moreover, a combination of
212 antifungal therapy with immunomodulatory therapy was shown to be an effective intervention.

213 In summary, the patient's underlying comorbidities, history of recent COVID-19 infection, immunosuppressive therapy, antifungal prophylaxis with azole drugs,
214 cytomegaloviremia, lymphocyte depletion and indwelling catheter may have played a role in the pleural seeding of *M. gracilis*. Fortunately, our patient was beneficial for
215 successful management in a multimodal manner, including reversal or revocation of underlying predisposing factors, early administration of suitable antifungal agents, and
216 adjuvant immunomodulatory treatment in which his condition did not progress into disseminated *Scopulariopsis/Microascus*. Although infection with *M. gracilis* is

217 uncommon and rarely pathogenic in the pleural cavity, clinicians and microbiologists should be aware of the potential of *M. gracilis* infection in immunocompromised
218 individuals at risk of opportunistic infections. Early and definitive diagnosis thorough direct microscopic testing with calcofluor white, as well as MOLDI-TOF MS, which
219 has been suggested as a valuable tool for identification at the genus and the species level, is the key to rapidly recognize this rare pathogenic fungus. Achieving an accurate
220 diagnosis along with appropriate antifungal management is vital for improving survival.

221

222 **AUTHOR CONTRIBUTIONS**

223 **Zhi-Min Hu:** Investigation; methodology; formal analysis; writing–review and editing; writing – original draft; resources; visualization; data curation. **Li-Na Mao:** collected
224 and interpreted the clinical data and wrote the manuscript. **Ti-Ying Deng:** Investigation; formal analysis; resources. **Bin-Tao Su:** revised the manuscript critically for
225 important content. **Yi Yang:** carried out the radiological examination. **Bi-Lin Dong:** carried out the microbiological examination and nucleotide sequencing. **Qing Xu:**
226 Investigation; formal analysis. **Shuo Yang:** Methodology; supervision; project administration; writing – review and editing. All the authors have read and approved the final
227 manuscript.

228

229 **ACKNOWLEDGEMENTS**

230 This work was supported by the Wuhan Health Scientific Research Key Project (No.WX18A06), and the Wuhan Health Scientific Research Program(No.WH21C21).

231

232 **CONFLICT OF INTEREST STATEMENT**

233 No potential conflict of interest was reported by the authors.

234

235 **REFERENCES**

- 236 1. Sundaralingam A, Banka R, Rahman NM. Management of pleural infection. *Pulm Ther.* 2021;7(1):59-74.
237 2. Hassan M, Cargill T, Harriss E, et al. The microbiology of pleural infection in adults: a systematic review. *Eur Respir J.* 2019;54(3):1900542.
238 3. Hassan M, Patel S, Sadaka AS, et al. Recent insights into the management of pleural infection. *Int J Gen Med.* 2021;14:3415-3429.

- 239 4. Pérez-Cantero A, Guarro J. Current knowledge on the etiology and epidemiology of *Scopulariopsis* infections. *Med Mycol.* 2020;58(2):145-155.
- 240 5. Barron GL, Cain RF, Gilman JC. The genus *Microascus*. *Can.J.Botany.* 1961;39:1609–1631.
- 241 6. Samson RA, Houbraken J, Thrane U, Frisvad JC, Andersen B. Food and Indoor Fungi. Westerdijk Laboratory Manual series: 2, second edition. 2 ed. Utre
242 cht: Westerdijk Fungal Biodiversity Institute. 2019;481 p. (Westerdijk Laboratory Manual series).
- 243 7. Woudenberg JHC, Meijer M, Houbraken J, Samson RA. *Scopulariopsis* and *scopulariopsis*-like species from indoor environments. *Stud Mycol.* 2017;88:1-35.
244
- 245 8. Sandoval-Denis M, Sutton DA, Fothergill AW, et al. *Scopulariopsis*, a poorly known opportunistic fungus: spectrum of species in clinical samples and in v
246 itro responses to antifungal drugs. *J Clin Microbiol.* 2013;51(12):3937-3943.
- 247 9. Iwen PC, Schutte SD, Florescu DF, Noel-Hurst RK, Sigler L. Invasive *Scopulariopsis brevicaulis* infection in an immunocompromised patient and review o
248 f prior cases caused by *Scopulariopsis* and *Microascus* species. *Med Mycol.* 2012;50(6):561-569.
- 249 10. Sandoval-Denis M, Gené J, Sutton DA, et al. Redefining *microascus*, *Scopulariopsis* and allied genera. *Persoonia.* 2016;36:1–36,
- 250 11. Inagaki N. On some fungi isolated from foods (I). *Trans Mycol Soc Japan.*1962;4(1):1–5.
- 251 12. Wei L, Shao J, Song Y, et al. Performance of matrix-assisted laser desorption Ionization-time of flight mass spectrometry for identification of *Scedosporium*,
252 *Acremonium*-like, *Scopulariopsis*, and *Microascus* specie. *Front Microbiol.* 2022;13:841286.
- 253 13. Bellemare A, John T, Marqueteau S. Fungal genomic DNA extraction methods for rapid genotyping and genome sequencing. *Methods Mol Biol.* 2018;1775:
254 11-20.
- 255 14. Rex JH, Alexander BD, Andes D, et al. Reference Method for Broth Dilution Antifungal Susceptibility Testing of Filamentous Fungi, Approved Standard. 2
256 nd ed. M38-A2 National Committee for Clinical Laboratory Standards; 2008.
- 257 15. Clinical and Laboratory Standards Institute. Performance Standards for Antifungal Susceptibility Testing of Filamentous Fungi. 2nd ed. CLSI supplement M6
258 1. Wayne,PA:Clinical and Laboratory Standards Institute; 2020.
- 259 16. Juan C. Nieto, Carlos Zamora, José M. Porcel, et al. Migrated T lymphocytes into malignant pleural effusions: an indicator of good prognosis in lung ade
260 nocarcinoma patients. *Sci Rep.* 2019;9:2996.
- 261 17. De Pauw B, Walsh TJ, Donnelly JP, et al. Revised definitions of invasive fungal disease from the European Organization for Research and Treatment of C
262 ancer/Invasive Fungal Infections Cooperative Group and the National Institute of Allergy and Infectious Diseases Mycoses Study Group (EORTC/MSG) Con

- 263 sensus Group. *Clin Infect Dis*. 2008;46:1813-1821.
- 264 18. Wuyts WA, Molzahn H, Maertens J et al. Fatal *Scopulariopsis* infection in a lung transplant recipient: a case report. *J Heart Lung Transplant*. 2005;24:230
265 1–2304.
- 266 19. Shankar EM, Vignesh R, Barton RC, et al. Hydrothorax in association with *Scopulariopsis brumptii* in an AIDS patient in Chennai, India. *Trans R Soc Tr*
267 *op Med Hyg*. 2007;101(12):1270-1272. doi:10.1016/j.trstmh.2007.09.008.
- 268 20. Miossec C, Morio F, Lepoivre T et al. Fatal invasive infection with fungemia due to *Microascus cirrosus* after heart and lung transplantation in a patient
269 with cystic fibrosis. *J Clin Microbiol*. 2011;49:2743–2747.
- 270 21. Shaver CM, Castilho JL, Cohen DN, et al. Fatal *Scopulariopsis* infection in a lung transplant recipient: lessons of organ procurement. *Am J Transplant*. 20
271 14;14:2893–2897.
- 272 22. Ding Y, Steed LL, Batalis N. First reported case of disseminated *Microascus gracilis* infection in a lung transplant patient. *IDCases*. 2020; 22:e00984.
- 273 23. Huang L, Chen W, Guo L, et al. *Scopulariopsis/Microascus* isolation in lung transplant recipients: a report of three cases and a review of the literature. *M*
274 *ycoses*. 2019;62(10):883-892.
- 275 24. Gao B, Guo L, Zhao L, et al. Case Report of a Successfully Treated *Scopulariopsis* Infection in a Bilateral Lung Transplant Recipient. *Exp Clin Transpla*
276 *nt*. 2023;21(3):275-278.
- 277 25. Mhmoud NA, Siddig EE, Nyuykonge B, Bakhiet SM, van de Sande WWJ, Fahal AH. Mycetoma caused by *Microascus gracilis*: a novel agent of human
278 eumycetoma in Sudan. *Trans R Soc Trop Med Hyg*. 2021;115:426–430.
- 279 26. Wilde C, Messina M, Moshiri T, Snape SE, Maharajan S. Interface *Scopulariopsis gracilis* fungal keratitis following Descemet's stripping automated endoth
280 elial keratoplasty (DSAEK) with a contaminated graft. *Int Ophthalmol*. 2018;38(5):2211-2217.
- 281 27. Kordalewska M, Jagielski T, Brillowska-Dąbrowska A. Rapid assays for specific detection of fungi of *Scopulariopsis* and *Microascus* genera and *Scopulario*
282 *psis brevicaulis* species. *Mycopathologia*. 2016;181(7-8):465-74.
- 283 28. Kumar R, Mishra N. Lung decortication for spontaneous hydropneumothorax in post COVID patients: A case series. *Perioper Care Oper Room Manag*. 20
284 22;29:100279.
- 285 29. Patel VM, Patel SV, Singletary K, Pacheco L. Recurrent hydropneumothorax after COVID-19. *Cureus*. 2023;15(3):e36208.
- 286 30. Yao L, Wan Z, Li R, Yu J. In vitro triple combination of antifungal drugs against clinical *Scopulariopsis* and *Microascus* species. *Antimicrob Agents Chem*

- 287 *other*. 2015;59:5040–5043.
- 288 31. Paredes K, Capilla J, Mayayo E, Guarro J. Virulence and resistance to antifungal therapies of *Scopulariopsis* species. *Antimicrob Agents Chemother*. 2016;6
289 0(4):2063-2068.
- 290 32. Lamoth F, Chung SJ, Damonti L, Alexander BD. Changing epidemiology of invasive mold infections in patients receiving azole prophylaxis. *Clin Infect Dis*
291 *s*. 2017;64:1619–1621.
- 292 33. Jenks J, Reed SL, Seidel D, et al. Rare mold infections caused by *Mucorales*, *Lomentospora prolificans* and *Fusarium*, San Diego: the role of antifungal c
293 ombination therapy. *Int J Antimicrob Agents*. 2018;52:706-712.
- 294 34. Stemler J, Salmanton - García J, Seidel D, et al. Risk factors and mortality in invasive *Rasamsonia spp.* infection: analysis of cases in the FungiScope(R)
295 registry and from the literature. *Mycoses*. 2020;63:265-274.
- 296 35. Apostolopoulou A, Fishman JA. The pathogenesis and diagnosis of *Pneumocystis jiroveci* pneumonia. *J Fungi (Basel)*. 2022;8(11):1167.doi:10.3390/jof811116
297 7.
- 298 36. Gea-Banacloche, J.,Komanduri, K., Carpenter, P., et al. National institutes of health hematopoietic cell transplantation late effects initiative: the immune dysr
299 egulation and pathobiology working group report. *Biol Blood Marrow Transplant*. 2017;23(6),870–881.
- 300 37. Swick BL, Reddy SC, Friedrichs A, Stone MS. Disseminated *Scopulariopsis*–culture is required to distinguish from other disseminated mould infections. *J*
301 *Cutan Pathol*. 2010;37(6):687-691.
- 302 38. Helander L, Stark M. Fatal *Scopulariopsis brumptii* in a pediatric immunocompromised host. *Fetal Pediatr Pathol*. 2017;36(1):82-86.doi:10.1080/15513815.2
303 016.1267283.
- 304 39. Singh N. Interactions between viruses in transplant recipients. *Clin Infect Dis*. 2005;40(3):430-436.
- 305 40. E. J. Wherry. T cell exhaustion. *Nature Immunology*. 2011;12(12):492-499.
- 306 41. Sakuishi K, Apetoh L, Sullivan JM, et al. Targeting Tim-3 and PD-1 pathways to reverse T cell exhaustion and restore anti-tumor immunity. *J Exp Med*.
307 2010;207(10):2187-2194.
- 308 42. Zheng M, Gao Y, Wang G, et al. Functional exhaustion of antiviral lymphocytes in COVID-19 patients. *Cell Mol Immunol*. 2020;17(5):533-535.
- 309 43. Sellami A, Boudaya S, Makni F, et al. Disseminated infection by *Scopulariopsis brevicaulis*. *J Mycol Med*. 2003;13:203-206.
- 310 44. Chen-Scarabelli C, Scarabelli TM. Fungal Endocarditis due to *Scopulariopsis*. *Ann Intern Med*. 2003;139(9):W77.doi:10.7326/0003-4819-139-9-200311040-000

- 311 22-w1.
- 312 45. Celard M, Dannaoui E, Piens MA, et al. Early *Microascus cinereus* endocarditis of a prosthetic valve implanted after *Staphylococcus aureus* endocarditis of
313 the native valve. *Clin Infect Dis*. 1999;29:691–692.
- 314 46. Steinbach WJ, Schell WA, Miller JL, Perfect JR, Martin PL. *Scopulariopsis brevicaulis* infection in a pediatric stem-cell transplant patient treated with vor
315 iconazole and caspofungin and a review of *Scopulariopsis* infections in immunocompromised patients. *J Infect*. 2004;48:112–116.
- 316 47. Aguilar C, Pujol I, Guarro J. In vitro antifungal susceptibilities of *Scopulariopsis* isolates. *Antimicrob Agents Chemother*. 1999;43:1520–1522.
- 317 48. Skóra M, Bulanda M, Jagielski T. In vitro activities of a wide panel of antifungal drugs against various *Scopulariopsis* and *Microascus* species. *Antimicrob*
318 *Agents Chemother*. 2015;59:5827–5829.
- 319 49. Matsuda T, Koreeda Y, Mataka H, et al. A case of *Aspergillus* empyema successfully treated with combination therapy of voriconazole and micafungin: exc
320 ellent penetration of voriconazole and micafungin into pleural fluid. *Intern Med*. 2010;49(12):1163-1169
- 321 50. Salmanton-García J, Koehler P, Kindo A, et al. Needles in a haystack: extremely rare invasive fungal infections reported in FungiScope®-global registry fo
322 r emerging fungal infections. *J Infect*. 2020;81:802–815.
- 323 51. Cuenca-Estrella M, Gomez-Lopez A, Buitrago MJ, et al. In vitro activities of 10 combinations of antifungal agents against the multiresistant pathogen *Scop*
324 *ulariopsis brevicaulis*. *Antimicrob Agents Chemother* 2006;50:2248–2250.
- 325 52. Bupha-Intr O, Butters C, Reynolds G, et al. Consensus guidelines for the diagnosis and management of invasive fungal disease due to moulds other than
326 *Aspergillus* in the haematology/oncology setting, 2021. *Intern Med J*. 2021;51(Suppl 7):177-219.
- 327 53. Kurata K, Nishimura S, Ichikawa H, Sakai R, Mizutani Y, Takenaka K, et al. Invasive *Scopulariopsis alboflavescens* infection in patient with acute myeloi
328 d leukemia. *Int J Hematol* 2018;108:658-664.
- 329 54. Arroyo MA, Walls TB, Relich RF, Davis TE, Schmitt BH. The brief case: *Scopulariopsis* endocarditis-a case of mistaken Takayasu’s arteritis. *J Clin Micro*
330 *biol*. 2017;55:2567-2572.
- 331 55. Los-Arcos I, Berastegui C, Martín-Gómez MT, et al. Nebulized micafungin treatment for *Scopulariopsis/Microascus* tracheobronchitis in lung transplant reci
332 pients. *Antimicrob Agents Chemother*. 2021;65(6):e02174-20.
- 333 56. Ustun C, Huls G, Stewart M, Marr KA. Resistant *Microascus cirrosus* pneumonia can be treated with a combination of surgery, multiple anti-fungal agents
334 and a growth factor. *Mycopathologia*. 2006,162(4):299-302.

335 57. Wiederhold NP, Patterson HP, Sanders CJ, Cañete-Gibas C. Dihydroorotate dehydrogenase inhibitor olorofim has potent *in vitro* activity against *Microascus/*
336 *Scopulariopsis*, *Rasamsonia*, *Penicillium* and *Talaromyces* species. *Mycoses*. 2023;66(3):242-248.

337

338

339

340

341 **FIGURE 1** Chest computed tomography showed a new pneumothorax on the right lung, and ground-glass opacities were diffusely distributed in both lungs (A); a
342 drainage tube, a cavity with an air-crescent sign and reduced hydropneumothorax in the right pleural cavity (B)

343

344 **FIGURE 2** The image showed the new intercostal catheter on the right-sided chest(A). Calcofluor white staining showed the pigmented, septate fungal hyphae of pleural
345 effusion, ×400 (B). The picture displays *Microascus gracilis* on Sabouraud's dextrose agar after 5 days of incubation at 35 °C (C). Microscopic examination showing hyaline
346 septate hyphae with bottle-shaped conidiogenous cells along with obovate-shaped, smooth conidia arranged in short chains, lactophenol cotton-blue staining, ×400 (D). The
347 characteristic spectrometry of *M. gracilis* identified by MOLDI-TOF MS (E).

348

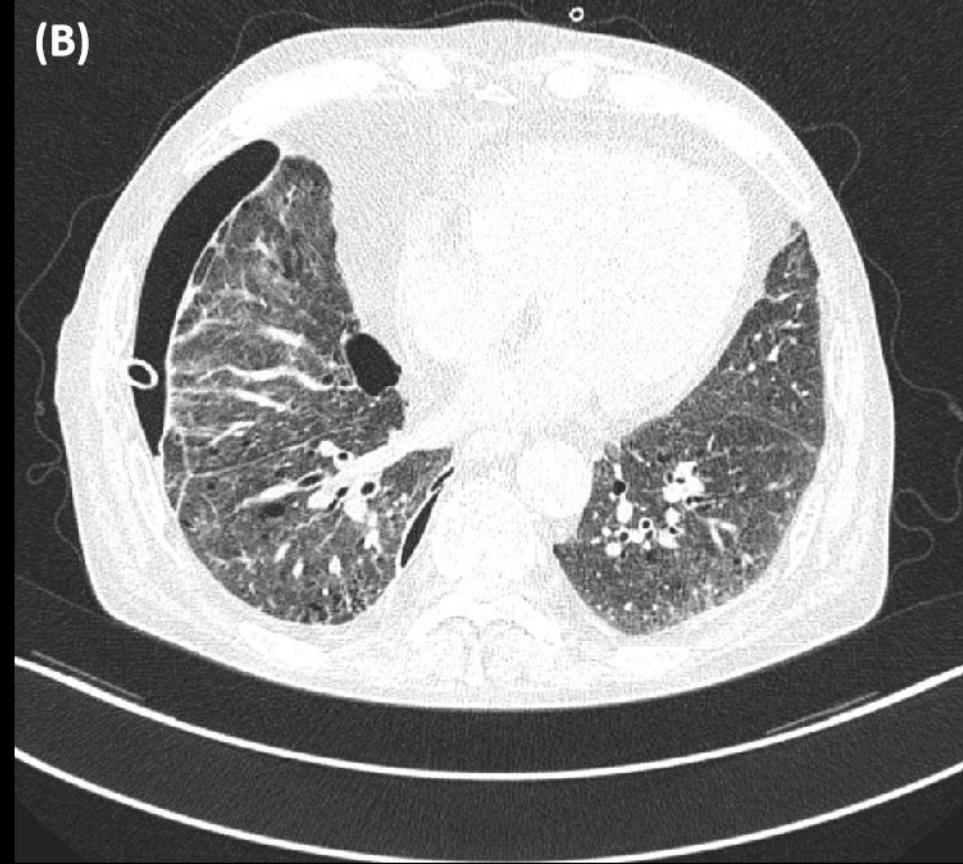
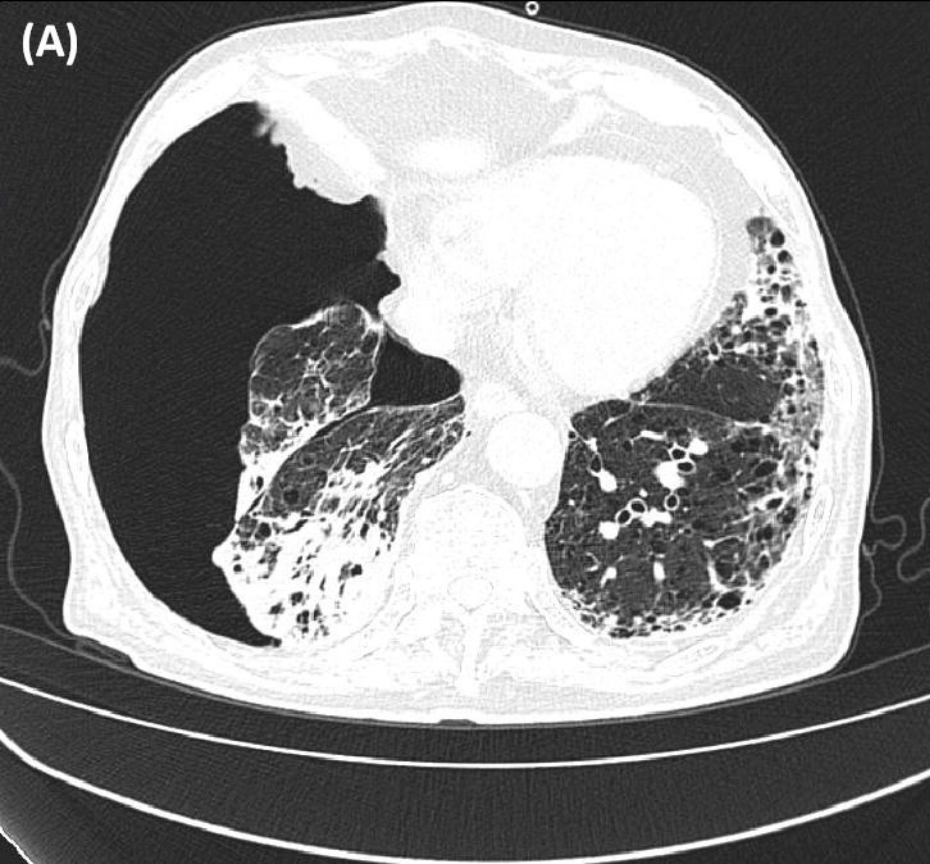
349 **FIGURE 3** Flow cytometry results displayed the level of CD3+ T cells and CD4+ T cells were alleviated in peripheral blood after the immunomodulatory agents
350 administered.

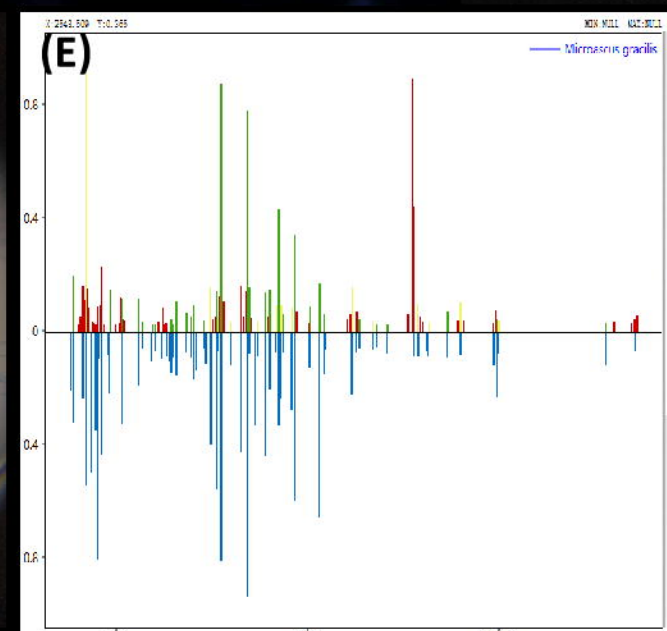
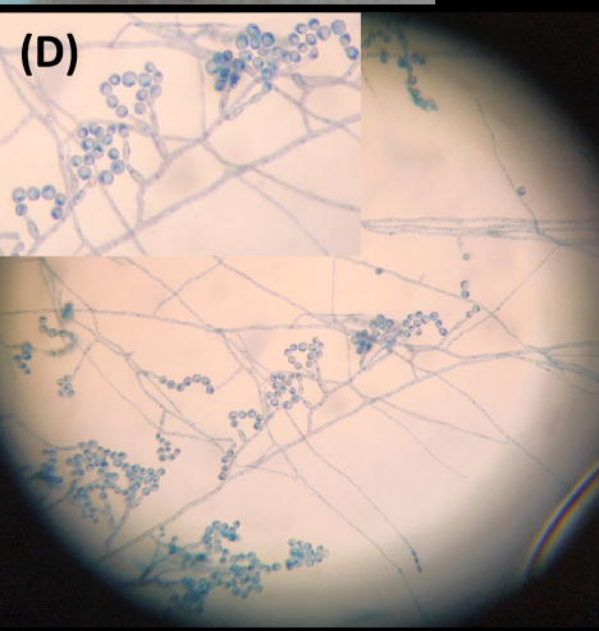
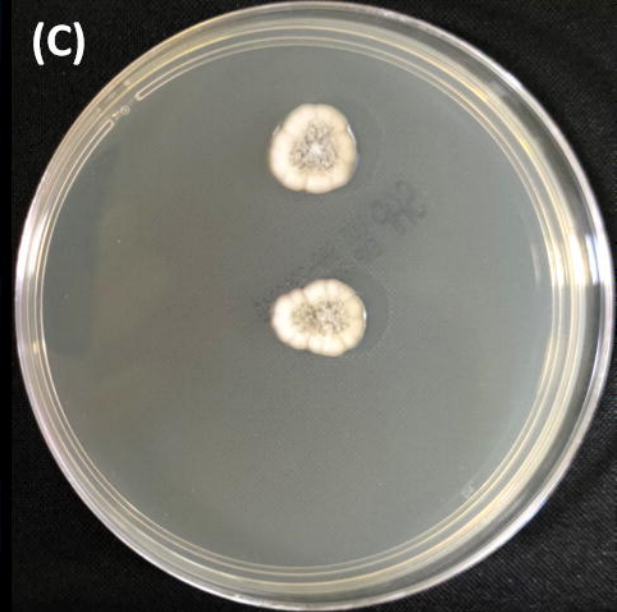
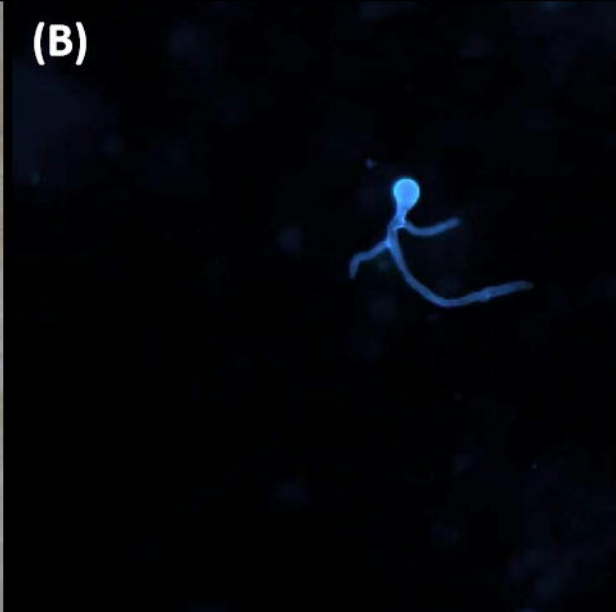
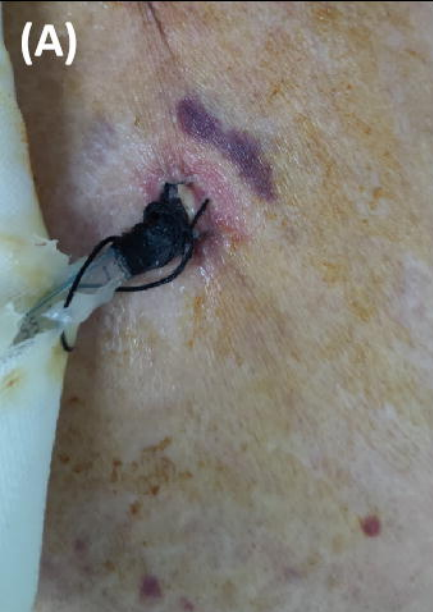351

352 **FIGURE 4** Flow cytometry results reveals the level of CD3+PD-1+ T cells and CD4+PD-1+ T cells were all decreased significantly in peripheral blood after the
353 immunomodulatory agents administered.

354

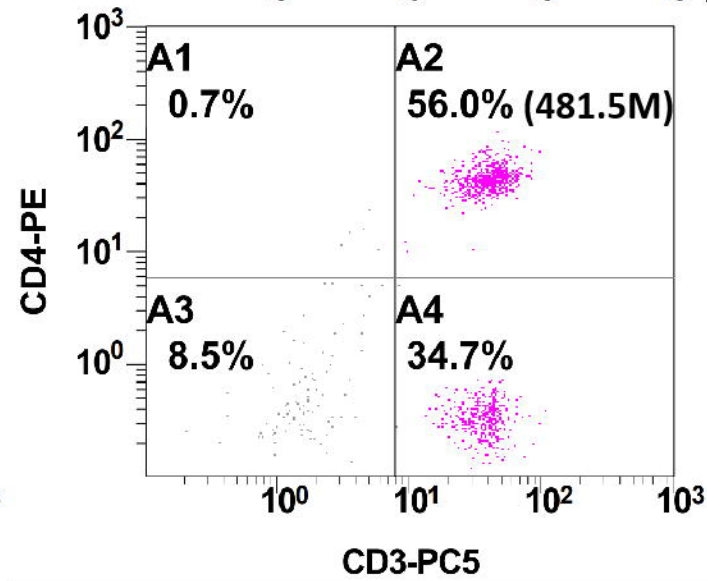
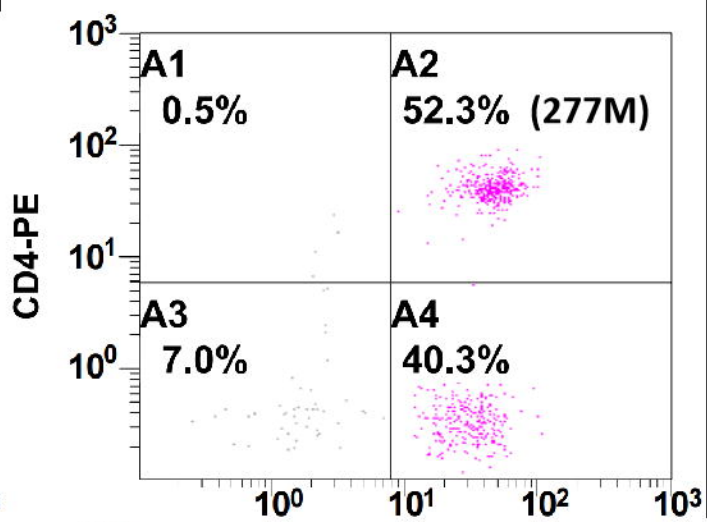
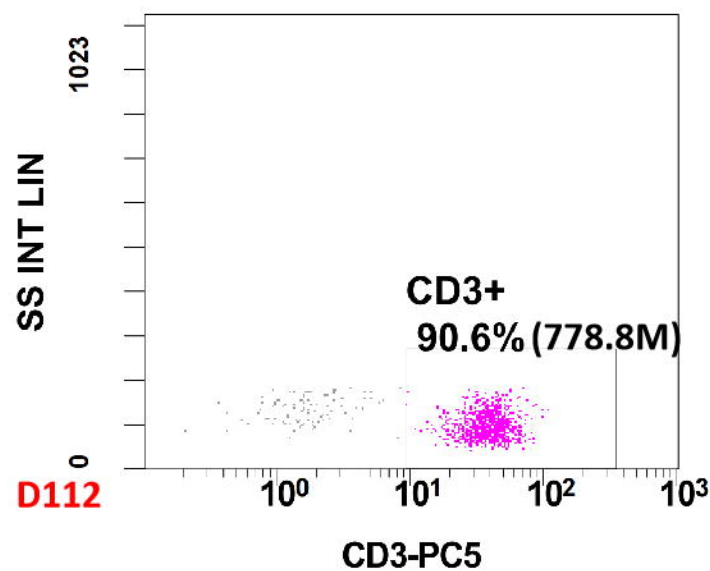
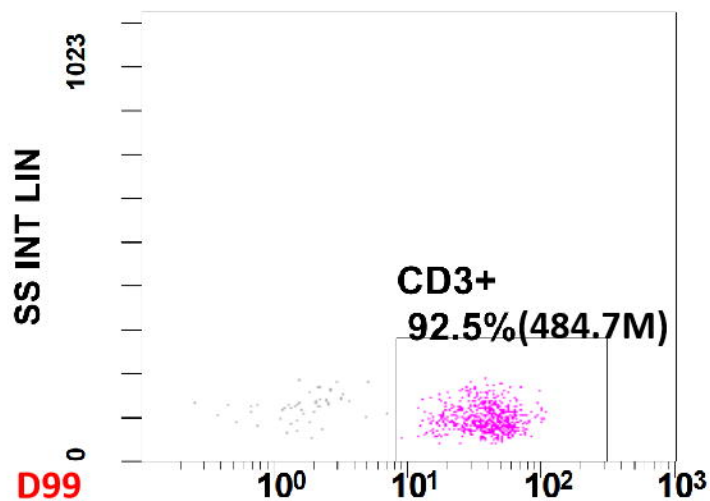
355 **FIGURE 5** Flow cytometry results reveals the level of CD3+PD-1+ T cells and CD4+PD-1+ T cells were all decreased significantly in pleural effusion after the
356 immunomodulatory agents administered.

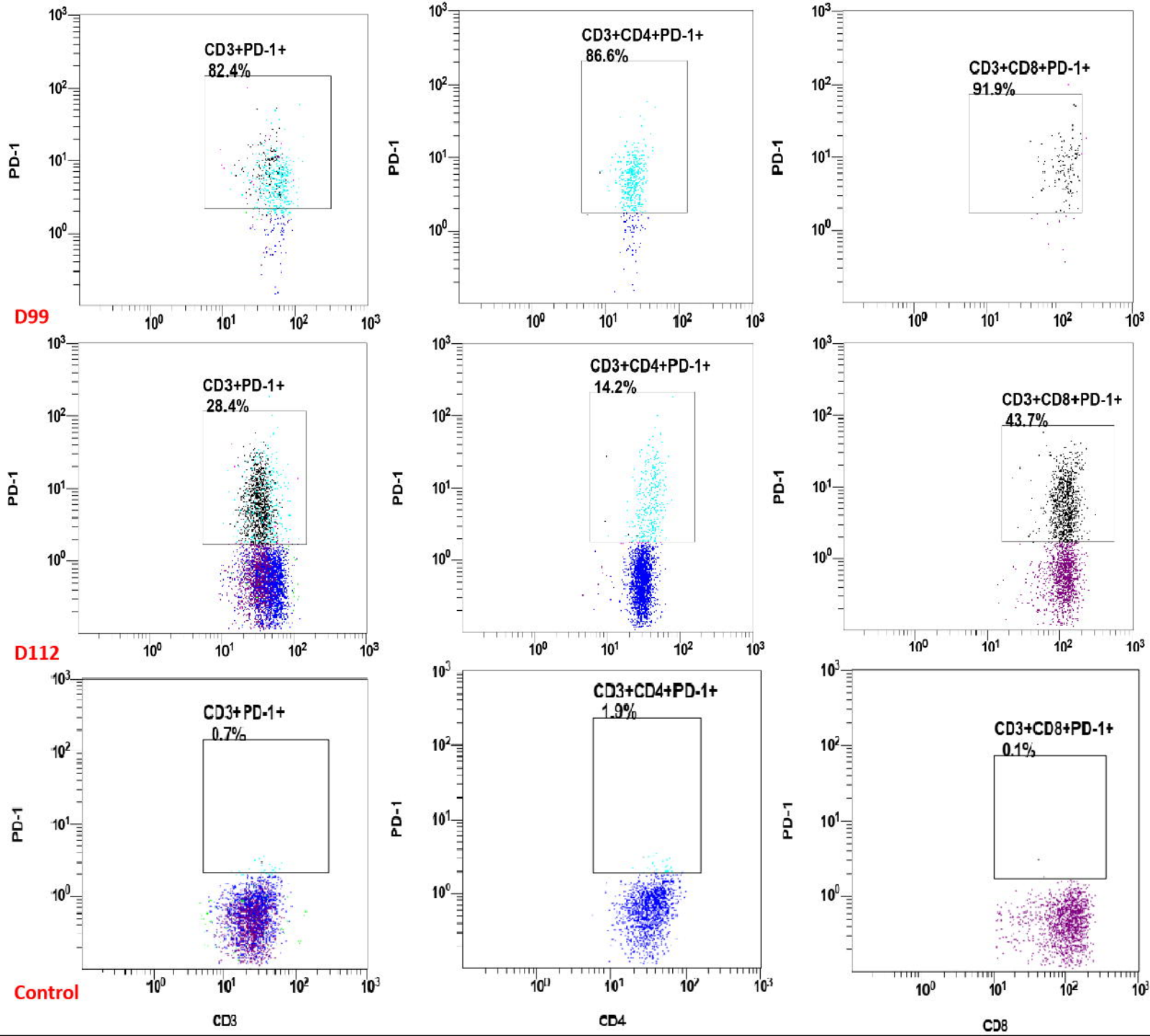




Seq ID	Start	End	Score	Species	Support
1	2984.567	1253	359408	3	466
2	3043.404	1266	286418	2	532
3	3095.842	2115	1481954	12	590
4	3300.269	1768	1179633	8	478
5	3353.365	1756	1598522	7	646
6	3369.651	6568	8817295	62	523
7	3385.164	2278	2501588	13	359
8	3407.045	1717	1227645	7	478
9	3595.101	1401	579368	4	475
10	3674.655	1403	753917	4	665
11	3689.662	2149	2049525	12	662
12	3846.615	1466	837967	5	598
13	3860.224	1645	1253200	7	617
14	4079.175	1523	950247	6	600
15	418.782	1449	934189	5	550
16	462.947	1170	429129	2	411
17	4464.275	1462	917926	5	457
18	4967.589	1447	1053664	5	720

Species	Score	Support
1 Microascus gracilis	9.510	★ ★ ★
2 Microascus cirrosus	5.882	★
3 Microascus cirrosus	5.617	★
4 Penicillium citreonigrum	5.515	★
5 Scedosporium apiospermum	5.470	★
6 Aspergillus niger	5.296	★
7 Scedosporium apiospermum	5.206	★
8 Scedosporium apiospermum	5.164	★
9 Aspergillus tubingensis	5.002	★
10 Shevanelia a gae	4.990	★





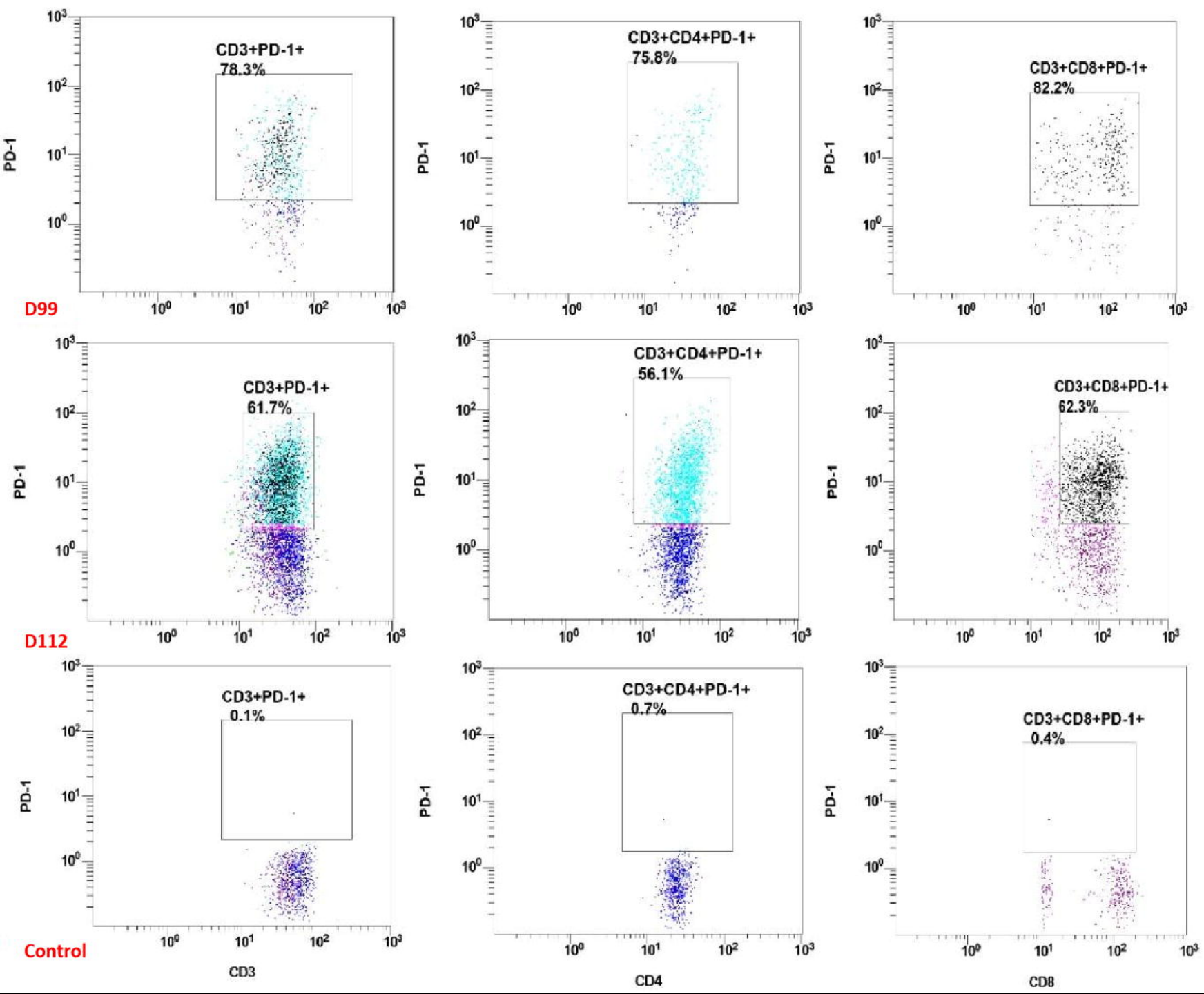


TABLE 1 Timeline of events

Time	Clinical features	Biology results	Therapy strategies
D1	Progressive dyspnoea	Neutrophilia, abnormal chest CT scan	Chest tube insertion
D6	Fever	<i>Acinetobacter baumannii</i> detected in sputum, High level of CRP, SAA, IL-6 and (1,3)-beta-d-glucan, low absolute lymphocyte count	Cefoperazone-sulbactam 9 g/day IV and prophylactic therapy fluconazole 0.2 g/day p.o.
D10	Pneumonia and cough	<i>Aspergillus fumigate</i> detected twice in sputum	Levofloxacin 0.4 g/day and cefoperazone-sulbactam 9 g/day IV combined antifungal therapy (voriconazole 0.4 g/day p.o.)
D32	Pleurisy	<i>Enterococcus faecalis</i> detected in pleural fluid, High level of CRP and IL-6, low absolute lymphocyte count	Switched to vancomycin 2 g/day IV
D65	Increased pleural effusions	<i>Streptococcus sanguinis</i> detected in pleural fluid	Adjusted to cefoperazone-sulbactam 9 g/day IV
D73	Outpatient	Negative sputum and pleural fluid	
D81	Readmitted due to worsening of the dyspnoea	High level of CRP and glycaemia, abnormal chest CT scan	
D87	Extubation and indwelling a new pleural catheter, cough	Cytomegaloviremia and persistent low level of absolute lymphocyte count; <i>Klebsiella pneumoniae</i> detected in sputum	Switched to latamoxef 4 g/day and valganciclovir 1.8 g/day p.o.
D89	Pleural effusion appeared grossly turbid and yellowish	Filamentous fungi detected in pleural fluid, <i>Microascus gracilis</i> cultured in chest tube and pleural fluid	Switched antifungal therapy (caspofungin 50 mg/day IV and posaconazole 0.3 g/day p.o.)
D99	Relieve respiratory symptoms	BALF mNGS detected <i>Pneumocystis jirovecii</i> , <i>Aspergillus fumigate</i> , HCMV and EBV; peripheral blood HCMV DNA positive; BALF GM test positive	Adding clindamycin 1.2 g/day IV, thymosin- α -1 4.8 mg/week and intravenous immunoglobulin 400 mg/kg/week
D119	Remove chest tube	Chest tube, pleural fluid and sputum culture were negative	Switched antifungal therapy (terbinafine 250 mg/day p.o. and posaconazole 0.3 g/day p.o. for 4 weeks)
D133	Outpatient	HCMV DNA negative, high level of CRP and persistent low level of absolute lymphocyte count relieved	Regular follow-up visits

Abbreviations: D day, CRP C-reactive protein, SAA Serum amyloid A, IV intravenous, p.o per os, CT computed tomographic, BALF bronchoalveolar lavage fluid, mNGS metagenomics next generation sequencing, HCMV human cytomegalovirus, EBV Epstein-Barr virus, GM galactomannan

TABLE 2 Comparison of abnormal biochemical and immunological indicators before and after the administration of immunomodulatory regimens

Time	Peripheral blood						Pleural effusion							
	CD3+T ($\times 10^6/L$)	CD4+T ($\times 10^6/L$)	CD3+PD-1+ (%)	CD4+PD-1+ (%)	hsCRP (mg/L)	IL-6 (pg/mL)	CD3+T (n)	CD4+T (n)	CD3+PD-1+ (%)	CD4+PD-1+ (%)	IL-6 (pg/mL)	IL-1 β (pg/mL)	LDH (U/L)	ADA (U/L)
D99	484.7	277	82.4	86.6	130	76.91	737	355	78.3	75.8	>5000	389	1207	22.4
D112	778.8	481.5	28.4	14.2	7.0	36.02	4866	2818	61.7	56.1	510	73.6	192	2.5

TABLE 3 Demographic features of reported cases with indicated pleural infection by *Scopulariopsis*/*Microascus* species

Reference	Diagnosis year/nation	Age/gender	Underlying disease	Transplant type	Systemic antifungal agents before infection	Involved sites	Infection species	Treatment	Outcome
19	2005/ Belgium	63/M	COPD	SOT (single-lung)	AMB	Heart, thyroid gland, stomach, kidneys, lungs	<i>S. acremonium</i>	VOR/CAS	Expired (1 day)
20	2007/ India	27/M	AIDS	—	None	Pleural fluid	<i>S. brumptii</i>	—	Expired cardiovascular dysfunctions (14 days)
21	2009/ France	36/M	CF/RF/DM	SOT (heart and lungs)	FCZ	Pleural fluid, intrapericardial fluid, blood clots, bronchial secretions	<i>M. gracilis</i> (<i>M. cirrosus</i>)	VOR/CAS	Expired <u>multiorgan</u> failure (9 days)
22	2014/ USA	56/M	IPF/DM	SOT (lungs)	ITC	Pulmonary pleura, pleural fluid, skin, ribs, sternum	<i>S. brumptii</i>	MIC/VOR/Am B/TER	Expired Sepsis (48 days)
23	2020/ USA	65/M	IPF/PH/DM/ HTN/CAD/ HLD	SOT (lungs)	AmB/VOR	Lung, pleura, heart, brain, potential eyes	<i>M. gracilis</i>	AmB/MIC/ISO/ TER	Expired (18 days)
This case	2023/ China	>65/M	NS/ILD/DM	—	VOR	Pleural fluid	<i>M. gracilis</i>	CAS/POS/TEB	Cured

Abbreviations: M, male; COPD, chronic obstructive pulmonary disease; SOT, solid organ transplant; AmB, amphotericin; VOR, voriconazole; CAS, caspofungin; AIDS, acquired immune deficiency syndrome; CF, cystic fibrosis; RF, renal failure; DM, diabetes mellitus; FCZ, fluconazole; IPF, idiopathic pulmonary fibrosis; ITC, itraconazole; MIC, micafungin; TER, terbinafine; PH, pulmonary hypertension; IITN, hypertension; CAD, coronary artery disease; HLD, hyperlipidaemia; ISO, isavuconazole; NS, nephrotic syndrome; ILD, interstitial lung disease; POS, posaconazole.