

1 **Effect of mRNA vaccination on pulmonary sequelae after mild COVID-19**

2 **Gagiannis D, MD¹, Hackenbroch C, MD^{2,3}, Zech F, PhD (OrCID: 0000-0002-1668-8060)⁴, Kirchhoff F, PhD (OrCID:**
3 **0000-0002-7052-2360)⁴, Bloch W, MD⁵, Junghans K⁶, Steinestel K, MD, PhD (OrCID: 0000-0002-6549-9848)⁶**

4 ¹Department of Pulmonology, Bundeswehrkrankenhaus Ulm, 89081 Ulm, Oberer Eselsberg 40, Germany;

5 ²Department of Radiology, Bundeswehrkrankenhaus Ulm, 89081 Ulm, Oberer Eselsberg 40, Germany;

6 ³Department of Radiology, Ulm University Medical Center, 89081 Ulm, Albert-Einstein-Allee 23, Germany;

7 ⁴Institute of Molecular Virology, Ulm University Medical Center, 89081 Ulm, Meyerhofstrasse 1, Germany,

8 ⁵Department of Molecular and Cellular Sport Medicine, German Sport University Cologne, 50933 Cologne, Am

9 Sportpark Müngersdorf 6, Germany; ⁶Institute of Pathology and Molecular Pathology, Bundeswehrkrankenhaus
10 Ulm, 89081 Ulm, Oberer Eselsberg 40, Germany

11 **Corresponding author:**

12 **Konrad Steinestel, MD PhD**

13 Institute of Pathology and Molecular Pathology

14 Bundeswehrkrankenhaus Ulm

15 Oberer Eselsberg 40

16 89081 Ulm, Germany

17 T: 0049 731 1710 2400

18 F: 0049 731 1710 2403

19 konradsteinestel@bundeswehr.org

20

21 **Funding:** This work was in part supported by the German Registry of COVID-19 Autopsies
22 (www.DeRegCOVID.ukaachen.de), funded by the Federal Ministry of Health (ZMVI1-2520COR201), and the
23 Federal Ministry of Education and Research within the framework of the network of university medicine
24 (NATON, No. 01KX2121)

25 **Declaration of interest:** DG and KS were speakers for Boehringer-Ingelheim. All other authors declare no conflict
26 of interest.

27

28

29

30

31

32

33

34

35

36

37

38

39

40 **NOTE: This preprint reports new research that has not been certified by peer review and should not be used to guide clinical practice.**

41

42 **ABSTRACT**

43 **Background:** Previous studies indicate a protective role for SARS-CoV-2 vaccination against development of
44 pulmonary post-acute sequelae of COVID (PASC). We compared clinical, imaging, histopathology and
45 ultrastructural features of pulmonary PASC with and without prior vaccination in a consecutive cohort of 54
46 unvaccinated, 17 partially vaccinated and 28 fully vaccinated patients who presented with dyspnea on exertion
47 after mild COVID-19 (without hospitalization).

48 **Methods:** Patients underwent full clinical evaluation including autoantibody (ANA/ENA) serology, high-
49 resolution computed tomography (HRCT), bronchioloalveolar lavage fluid (BAL) analysis and transbronchial
50 biopsy followed by histopathological and ultrastructural analysis and SARS-CoV-2 immunohistochemistry.

51 **Results:** While vaccinated patients were younger ($p=0.0056$), included more active smokers ($p=0.0135$) and a
52 longer interval since infection (35 vs. 17 weeks, $p=0.0002$), dyspnea on exertion and impaired lung function were
53 not different between vaccinated and unvaccinated patients. Ground glass opacities in HRCT and centrilobular
54 fibrosis were more frequent in unvaccinated patients ($p=0.0154$ and $p=0.0353$), but presence of autoantibodies,
55 BAL lymphocytosis and bronchiolitis were common findings in all groups. While vaccination against SARS-CoV-2
56 is associated with a longer time span between infection and consultation along with a reduced frequency of
57 ground glass opacities and centrilobular fibrosis, impaired lung function, bronchiolitis and presence of
58 autoantibodies are comparable between vaccinated and unvaccinated patients. Residual virus was not detected
59 in lung tissue in all but 1 patient.

60 **Conclusion:** While differences between the investigated groups with regard to age, smoking status and SARS-
61 CoV-2 variants have to be taken into account, a proposed protective role of SARS-CoV-2 vaccination against
62 pulmonary PASC is so far not fully explained by clinical and histopathology findings.

63
64 **KEY MESSAGES**

65 The role of SARS-CoV-2 vaccination in the protection against pulmonary post-acute sequelae of COVID-19 (PASC)
66 is unclear. Using a multidimensional approach integrating clinical, serological, imaging and histopathology data
67 as well as ultrastructural analyses, we show here that previous vaccination has no impact on lung function,
68 bronchiolitis or the detection of autoantibodies or residual virus in a previously healthy cohort of 99 PASC
69 patients after mild COVID-19. While a higher frequency of ground glass opacities in unvaccinated patients might
70 be due to the longer interval between infection and consultation, the observed fibrotic remodeling should
71 prompt further investigation of a possible pro-fibrotic role of SARS-CoV-2 infection in the lung.

72
73 **RUNNING TITLE**

74 SARS-CoV-2 vaccination and pulmonary post-acute sequelae of COVID-19 (PASC)

75
76 **KEYWORDS**

77 COVID-19, SARS-CoV-2, PASC, lung pathology, longCOVID, postCOVID, vaccination

78

79 INTRODUCTION

80 Following SARS-CoV-2 infection, up to 15% of non-hospitalized patients develop post-infectious sequelae of
81 COVID-19 (PASC) [1-3]. Lung manifestations of PASC include shortness of breath, chest pain and imaging
82 abnormalities such as ground glass opacities (GGO) and subpleural bands [4]. Evaluation of PASC can be
83 hampered by preexisting lung disease or severe COVID-19 with scarring or post-ventilation change [5]. In a
84 prospective cohort of 51 previously healthy pulmonary PASC patients after mild COVID-19, we have previously
85 shown pulmonary function impairment in a subset of patients, including a reduction in maximal expiratory flow
86 at 50% of FVC (MEF50) and a reduction in FEV1 together with CD4+T cell-mediated bronchiolitis, indicating
87 obstructive change [6, 7]. To our best knowledge, this was the first study to use verifiable tissue-based criteria
88 to assess lung involvement in PASC in previously healthy patients after mild COVID-19. In several large cohort
89 studies, a reduction in both frequency and symptom severity of pulmonary PASC upon mRNA vaccination against
90 SARS-CoV-2 has been described [8-10]. However, since most of these reports are based on self-reported
91 symptoms or electronic medical records, the aim of the present study was to evaluate the effect of previous
92 vaccination on defined clinical, imaging and histopathological characteristics of pulmonary PASC.

93 METHODS

94 Patients and diagnostic work-up

95 We consecutively included n=99 patients with a history of RT-PCR-confirmed SARS-CoV-2 infection and persistent
96 pulmonary symptoms in the present study. 54 patients were unvaccinated, 17 patients were partially vaccinated
97 (1 to 2 doses) and 28 patients were fully vaccinated (3 or more doses) at the time of SARS-CoV-2 infection. All
98 vaccinations were performed using the BNT126b2 mRNA vaccine (BioNTech/Pfizer). The baseline diagnostic
99 workup included clinical history including current and previous medication and allergies, physical examination
100 and spirometry. ANA/ANCA/ENA screening (serology) was performed as previously described [11]. After
101 multidisciplinary discussion, bronchoscopy with transbronchial biopsy for the assessment of possible PASC-ILD
102 was performed in all patients that formed the definite cohort. Patients had given written informed consent to
103 routine diagnostic procedures (serology, bronchoscopy, imaging) as well as to the scientific use of data and tissue
104 samples in the present study. This project was approved by the local ethics committee of the University of Ulm
105 (ref. no. 129-20) and conducted in accordance with the Declaration of Helsinki.

106 Imaging

107 Imaging of the lung was performed on a 3rd generation DECT Scanner (Siemens Somatom Force, Siemens
108 Healthineers, Forchheim, Germany). A non-contrast multislice spiral CT in full-dose technique (Qual. Ref. kV: Sn
109 100, Qual. Ref. mAs: 600, ref. CTDI 1.06 mGy) with a collimation of 192 x 0.6 mm and using a tin prefilter at 100
110 resp. 150 kV was obtained. Rotation time 0.25 sec, scan time 1.25 sec. Examination was performed in inspiration.
111 Reconstruction in bone, soft tissue and lung window.

112 Histology and SARS-CoV-2 detection

113 Lung tissue specimens were obtained as transbronchial biopsies and stained with haematoxylin-eosin (HE),
114 Elastica-van-Gieson (EvG) and Masson-Goldner (MG). Slides were reviewed with special emphasis on possible

115 post-viral change (alveolitis, peribronchiolitis, airway smooth muscle hypertrophy, goblet cell hyperplasia, airway
116 squamous epithelial metaplasia, and fibrosis)[12]. We performed immunohistochemistry for Spike and
117 Nucleocapsid proteins of SARS-CoV-2 using the following antibodies: anti-SARS-CoV-2 spike antibody, clone 1A9,
118 mouse monoclonal, 1:400 (GeneTex, Irvine, CA, USA); anti-SARS-CoV-2 nucleocapsid antibody, rabbit
119 monoclonal, 1:20000 (SinoBiological, Beijing, China). Tissue-based RT-PCR in a subset of cases was performed as
120 previously described [7].

121 **Electron microscopy**

122 Lung tissue was immersion-fixed with 4% paraformaldehyde in 0.1M PBS, pH 7.4. After several washing steps in
123 0.1M PBS, tissue was osmicated with 1% OsO₄ in 0.1 M cacodylate and dehydrated in increasing ethanol
124 concentrations. Epon infiltration and flat embedding were performed following standard procedures. Methylene
125 blue was used to stain semithin sections of 0.5 µm. Seventy to ninety-nanometer-thick sections were cut with an
126 Ultracut UCT ultramicrotome (Fa. Reichert) and stained with 1% aqueous uranyl acetate and lead citrate.
127 Samples were studied with a Zeiss EM 109 electron microscope (Fa. Zeiss) coupled to a TRS USB (2048x2048,
128 v.596.0/466.0) camera system with ImageSP ver.1.2.6.11 (x64) software.

129 **BAL analysis and legendplex immunoassay**

130 The Legendplex ELISA was performed according to the manufacturer's instructions. In brief, 25 µl of the collected
131 BAL was centrifuged (4000 rpm, 5 min) and incubated for 2 h at room temperature with antibody-coated beads,
132 followed by washing and incubation with the detection antibodies. After incubation with the staining reagent,
133 the beads were analyzed in a high-throughput sampler via flow cytometry (FACSCanto II, BD Biosciences).
134 Absolute quantification was performed using a standard and the Bio-legend Legendplex v8.0 software.

135 **Statistical Methods**

136 Descriptive statistical methods were used to summarize the data (**Table 1**). Medians and interquartile ranges
137 were used to announce results. Absolute numbers and percentages were employed to represent categorial
138 variables. Student's t-test/ANOVA with multiple comparison post-test was used for the comparison of continuous
139 variables, while Chi-Square-Test/Fisher's test was used for categorial variables. All statistical analyses were
140 conducted using GraphPad PRISM 10.1.0 (GraphPad Software Inc., San Diego, CA, USA). A p-value <0.05 was
141 regarded as statistically significant.

142 **RESULTS**

143 **Diagnostic workup, clinical data and results from lung function tests**

144 The diagnostic work-up of suspected PASC-ILD patients who presented to our outpatient clinic at the
145 Bundeswehrkrankenhaus (army hospital) Ulm is summarized in **Fig. 1 A**, while **Tab. 1** and **Fig. 1 C** summarize
146 clinical, serological, imaging and histopathology data for the complete cohort. 51/54 patients from the
147 unvaccinated cohort have been published previously [7]. No patient had been hospitalized for COVID-19, 61/99
148 patients were soldiers (61.6%). Vaccinated patients were significantly younger ($p=0.0056$), active smokers
149 ($p=0.0135$) and sought consultation after a longer time span following acute SARS-CoV-2 infection ($p=0.0002$,

150 **Fig. 1 B).** Of note, while the recruitment period for unvaccinated patients was 11/2020-04/2021, the recruitment
151 period for vaccinated patients was 10/2021-04/2023, implying a different spectrum of SARS-CoV-2 viral variants.
152 The most frequent pathological result from pulmonary function test were impaired MEF50 in 37%, 53% and 50%
153 and and FEV1 ($\leq 80\%$) in 19%, 24% and 21% of patients in the vaccinated, partially vaccinated and fully vaccinated
154 groups, respectively ($p > 0.05$). Median oxygen pulse (VO_2/HF) was significantly lower in the fully vaccinated
155 compared to the unvaccinated group ($p = 0.034$). With respect other lung function tests, there was no significant
156 difference between the groups according to vaccination status (**Fig. 2 A**). Furthermore, there was no significant
157 association between the time since COVID and the number of lymphocytes in BAL or oxygen pulse in any of the
158 investigated groups, although there was a borderline correlation between oxygen pulse and time since COVID in
159 unvaccinated patients ($p = 0.0605$, **Fig. 2 B**)

160 **Serology and imaging**

161 Autoantibodies (serology; ANA titer $\geq 1:320$ and/or positive immunoblot for Scl-70, PCNA, PM-Scl, dsDNA, SS-B,
162 Histone) were detected in 37, 59 and 56% of unvaccinated, partially vaccinated and fully vaccinated PASC
163 patients. There was no difference in the frequency of autoantibodies, the inflammatory infiltrate in BAL samples
164 (both $p > 0.05$) or BAL cytokine profile between vaccinated and unvaccinated patients. In HRCT imaging, ground
165 glass opacities (GGO) were significantly more frequent in the unvaccinated compared to the vaccinated groups
166 ($p = 0.0154$) (**Fig. 2 C**), while noduli were observed more often in vaccinated patients ($p = 0.0495$).

167 **Histopathologic findings and tissue-based SARS-CoV-2 detection**

168 Histopathologic evaluation of transbronchial biopsies from PASC patients showed increased peribronchiolar and
169 interstitial lymphocytosis and alveolar fibrin deposition irrespective of vaccination status (**Fig. 2 C**). Organizing
170 pneumonia was rare in all groups (1 unvaccinated, 2 partially vaccinated and 1 unvaccinated patient), while
171 lymphoid follicles were more frequent in unvaccinated patients without reaching statistical significance. Of note,
172 centrilobular fibrosis was significantly increased in unvaccinated compared to vaccinated patients as assessed by
173 Masson-Goldner staining/ light microscopy ($p = 0.0353$). This could be confirmed by ultrastructural analyses
174 (transmission electron microscopy), where all investigated cases in the unvaccinated cohort showed marked
175 collagen deposition ($p = 0.0021$). Immunohistochemistry for SARS-CoV-2 N and S proteins was negative in all tissue
176 samples but one previously published case in the unvaccinated cohort was positive for E gene in RT-PCR which
177 could be confirmed by SARS-CoV-2 S FISH analysis of the alveolar epithelium [7].

178 **DISCUSSION**

179 We report on histopathological, serological, clinical and imaging characteristics of 99 pulmonary PASC patients
180 with and without previous vaccination from the postCOVID outpatient clinic of the Bundeswehrkrankenhaus
181 (army hospital) Ulm to assess whether previous vaccination has an impact on verifiable and tissue-based criteria
182 of PASC severity.

183 In comparison to most published PASC cohorts, our patient cohort was younger and had less preexisting medical
184 conditions, both possibly due to the high proportion of active soldiers in the study and reflecting data from other
185 studies involving military personnel [13]. All patients presented with dyspnea on exertion irrespective of

186 vaccination status, but the time span between infection and presentation was significantly longer in vaccinated
187 patients. While this might reflect less symptomatic disease, it has to be taken into account that while the
188 unvaccinated cohort was in most part recruited during the SARS-CoV2 delta wave, infections in the vaccinated
189 cohort occurred during spread of the Omicron variant. Moreover, media coverage in 2020/21 might have
190 contributed to a higher level of alertedness in affected patients which resulted in earlier consultation.

191 With respect to lung function, there were no significant differences between vaccinated and unvaccinated
192 patients. In line with previous results from comparable cohorts, reduced FEV1 and MEF50 were the most
193 prevalent finding [7, 14]. While there was a significant lower oxygen pulse in fully vaccinated compared to
194 unvaccinated patients, we would ascribe this finding to the higher number of active smokers in this group. Of
195 note, there was a strong trend towards higher oxygen pulse in unvaccinated patients with increasing interval
196 since infection that could not be observed in the vaccinated groups. The relevance of this finding is unclear, but
197 it might be speculated that this trend is due to the shorter time interval since infection and more nuanced
198 differences in VO_2/HF among the unvaccinated cohort.

199 While we would question the higher frequency of nodular changes in HRCT in the vaccinated group due to the
200 low absolute number of observations, imaging showed significantly higher frequency of GGOs in unvaccinated
201 PASC patients. This might be due to alveolar fibrin deposition which we have previously reported as an almost
202 ubiquitous finding in lung histopathology of both acute COVID-19 and PASC [7, 15]. It is well conceivable that
203 the shorter time span between infection and imaging in the unvaccinated group contributed to that finding, with
204 temporal resolution of alveolar fibrin in the other groups.

205 Among all patients, (peri)bronchiolar chronic inflammation and alveolar fibrin deposition were common findings
206 in histopathology. Organizing pneumonia as another possible correlate for GGOs was a rare finding in
207 histopathology of lung tissue samples among all groups, while fibrotic change was more frequent among
208 unvaccinated patients. This finding, which could be confirmed by electron microscopy, is of relevance since we
209 have previously demonstrated elevated levels of IF- 1β in BAL fluid, ultrastructural fibrosis and accumulation of
210 pro-fibrotic macrophages in PASC [7]. Moreover, we and others have shown that SARS-CoV-2 has the ability to
211 induce lung fibrosis [15, 16]. While the impact of severe COVID-19 pneumonia or invasive ventilation on fibrotic
212 remodeling is well-demonstrated, further research is warranted to understand possible pro-fibrotic signaling
213 during and after a mild course of COVID-19 [17].

214 With respect to the pathophysiology of pulmonary PASC, autoimmunity and viral persistence have been
215 discussed as possible contributors [18, 19]. While we detected autoantibodies in a large fraction of PASC patients,
216 their presence did neither correlate with vaccination status nor with the severity of symptoms, why we conclude
217 that if PASC is linked to the presence of autoantibodies, vaccination is unlikely to prevent their formation.
218 Because the presence of autoantibodies is associated with severe course of acute COVID-19 and has been
219 discussed as a hallmark of extrafollicular B cell activation upon contact with SARS-CoV-2 however, we still think
220 that the role of autoimmunity in both acute COVID-19 and PASC should be further investigated including research
221 on lung tissue samples [20, 21]. With respect to possible viral reservoirs, there were no detectable viral proteins
222 in lung tissue samples from all 99 investigated patients, irrespective of vaccination status. In one patient, viral
223 mRNA could be detected by RT-PCR. We conclude persistence of virus/viral particles is not necessary for PASC,

224 in line with the situation in acute COVID-19, where organization and long-term outcomes occur independent
225 from the presence of virus [15].

226 There are clear limitations to our study. First, these are real-world cohorts that bear significant differences with
227 respect to age, smoking status and viral variants between the vaccinated and unvaccinated cohorts. Still, since
228 symptom severity and viral variants would have favoured the vaccinated cohort, we think that our findings
229 contribute important evidence for the assessment of a possible role of vaccination in the prevention of
230 postCOVID. Second, since a significant proportion of investigated patients are active soldiers, the meaning for
231 the general population might be limited. With respect to that, we think that young age and the absence of
232 relevant pulmonary pathology is a unique opportunity to investigate the pathology of PASC and the role of
233 vaccination in that setting. Third, the value of transbronchial biopsies for the assessment of interstitial lung
234 disease is limited, however most studies that combine lung function tests with analyses on peripheral blood lack
235 such opportunity for multidimensional characterization of a condition that affects lung tissue.

236 Taken together, our data shows impairment of lung function (MEF50/FEV1), presence of autoantibodies and BAL
237 lymphocytosis along with centrilobular inflammation in PASC patients irrespective of vaccination status. While
238 GGO and centrilobular fibrosis seem to occur more frequently in unvaccinated patients, this difference might as
239 well be due to the longer time interval between infection and consultation in vaccinated patients. While our data
240 supports research effort with the respect of inflammasome and autoimmunity in the general pathogenesis of
241 pulmonary PASC, it does not support a protective role of mRNA vaccination against the development of
242 bronchiolitis and obstruction as possible contributors to the clinical presentation of PASC.

243

244 **ACKNOWLEDGEMENTS**

245 The authors would like to thank all patients for their consent to the use of data and images in the present study.

246

247 **AUTHOR CONTRIBUTIONS**

248 Study concept: DG and KS. Data collection: DG, CH, FZ, FK, KJ, KS. Sample collection: DG, CH, KS. Initial draft of
249 manuscript: KS. Critical revision and approval of final version: all authors.

250

251 **REFERENCES**

- 252 1. Xie, Y., B. Bowe, and Z. Al-Aly, *Burdens of post-acute sequelae of COVID-19 by severity of acute*
253 *infection, demographics and health status*. Nature communications, 2021. **12**(1): p. 1-12.
- 254 2. Lerner, A.M., et al., *Toward understanding COVID-19 recovery: National Institutes of Health*
255 *workshop on postacute COVID-19*. Annals of internal medicine, 2021. **174**(7): p. 999-1003.
- 256 3. Havervall, S., et al., *Symptoms and functional impairment assessed 8 months after mild COVID-*
257 *19 among health care workers*. Jama, 2021. **325**(19): p. 2015-2016.
- 258 4. Solomon, J.J., et al., *CT of postacute lung complications of COVID-19*. Radiology, 2021.
- 259 5. Ayoubkhani, D., et al., *Post-covid syndrome in individuals admitted to hospital with covid-19:*
260 *retrospective cohort study*. BMJ (Clinical research ed.), 2021. **372**: p. n693.
- 261 6. Pickens, C.I. and B.D. Singer, *Finding Facts in Postacute Sequelae of COVID-19: Clinical,*
262 *Radiographic, and Histopathologic Markers of Disease*. American Journal of Respiratory and
263 *Critical Care Medicine*, 2023. **208**(5): p. 521-523.

- 264 7. Gagiannis, D., et al., *Clinical, Imaging, and Histopathological Features of Pulmonary Sequelae*
265 *after Mild COVID-19*. American Journal of Respiratory and Critical Care Medicine, 2023. **208**(5):
266 p. 618-621.
- 267 8. Kuodi, P., et al., *Association between BNT162b2 vaccination and reported incidence of post-*
268 *COVID-19 symptoms: cross-sectional study 2020-21, Israel*. npj Vaccines, 2022. **7**(1): p. 101.
- 269 9. Al-Aly, Z., B. Bowe, and Y. Xie, *Long COVID after breakthrough SARS-CoV-2 infection*. Nature
270 medicine, 2022. **28**(7): p. 1461-1467.
- 271 10. Nehme, M., et al., *Prevalence of post-coronavirus disease condition 12 weeks after Omicron*
272 *infection compared with negative controls and association with vaccination status*. Clinical
273 Infectious Diseases, 2023. **76**(9): p. 1567-1575.
- 274 11. Gagiannis, D., et al., *Clinical, Serological, and Histopathological Similarities Between Severe*
275 *COVID-19 and Acute Exacerbation of Connective Tissue Disease-Associated Interstitial Lung*
276 *Disease (CTD-ILD)*. Frontiers in immunology, 2020. **11**: p. 2600.
- 277 12. Garcia, G.L., et al., *Distinct chronic post-viral lung diseases upon infection with influenza or*
278 *parainfluenza viruses differentially impact superinfection outcome*. The American Journal of
279 Pathology, 2020. **190**(3): p. 543-553.
- 280 13. Adam, T., et al., *Return to flying duties of German military pilots after recovery from COVID-19*.
281 BMJ Mil Health, 2022.
- 282 14. Komici, K., et al., *Clinical characteristics, exercise capacity and pulmonary function in post-*
283 *COVID-19 competitive athletes*. Journal of Clinical Medicine, 2021. **10**(14): p. 3053.
- 284 15. Gagiannis, D., et al., *Antemortem vs postmortem histopathologic and ultrastructural findings*
285 *in paired transbronchial biopsy specimens and lung autopsy samples from three patients with*
286 *confirmed SARS-CoV-2*. American Journal of Clinical Pathology, 2022. **157**(1): p. 54-63.
- 287 16. Kamp, J.C., et al., *Time-dependent molecular motifs of pulmonary fibrogenesis in COVID-19*.
288 International Journal of Molecular Sciences, 2022. **23**(3): p. 1583.
- 289 17. Duong-Quy, S., et al., *Post-COVID-19 Pulmonary Fibrosis: Facts—Challenges and Futures: A*
290 *Narrative Review*. Pulmonary Therapy, 2023: p. 1-13.
- 291 18. Son, K., et al., *Circulating anti-nuclear autoantibodies in COVID-19 survivors predict long-COVID*
292 *symptoms*. European Respiratory Journal, 2022.
- 293 19. Merad, M., et al., *The immunology and immunopathology of COVID-19*. Science, 2022.
294 **375**(6585): p. 1122-1127.
- 295 20. Gagiannis, D., et al., *Clinical, serological, and histopathological similarities between severe*
296 *COVID-19 and acute exacerbation of connective tissue disease-associated interstitial lung*
297 *disease (CTD-ILD)*. Frontiers in immunology, 2020. **11**: p. 587517.
- 298 21. Woodruff, M.C., et al., *Extrafollicular B cell responses correlate with neutralizing antibodies*
299 *and morbidity in COVID-19*. Nature immunology, 2020: p. 1-11.

300

301

302

303

304

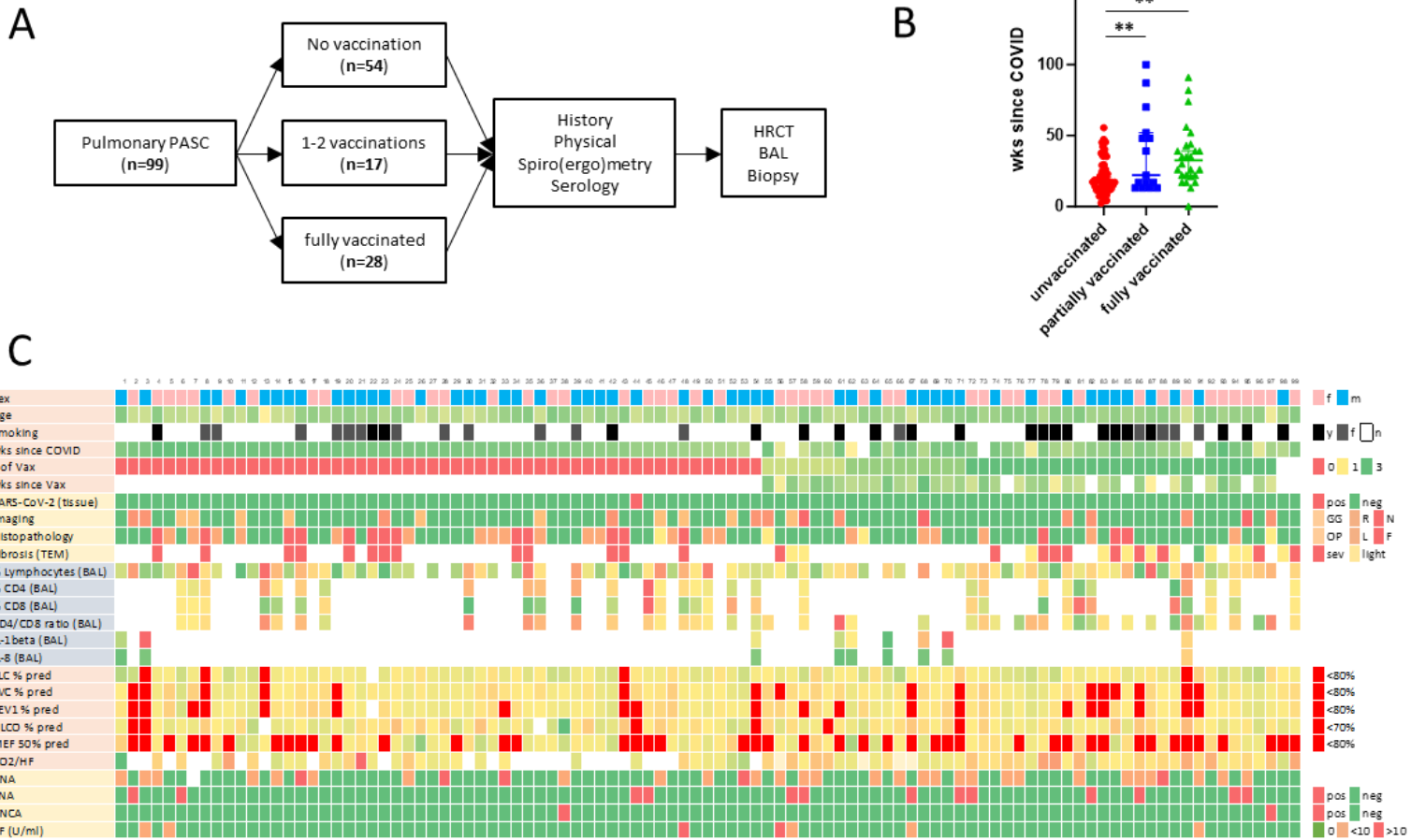
305

306

307

308

Figure 1



309

310 **Figure 1. Characterization and diagnostic work-up of PASC patients.** **A**, Flow diagram for diagnostic
 311 work-up of suspected PASC-ILD patients. Lung biopsies from 99 PASC patients were finally included in
 312 histopathological assessment. **B**, interval between infection and clinical presentation. ****** $p < 0.05$ **C**,
 313 heatmap stratified according vaccination status displaying clinical data and the results from tissue-
 314 based SARS-CoV-2 detection, imaging, histopathology, BAL analysis, lung function tests and
 315 autoantibody screening.

316

317

318

319

320

321

322

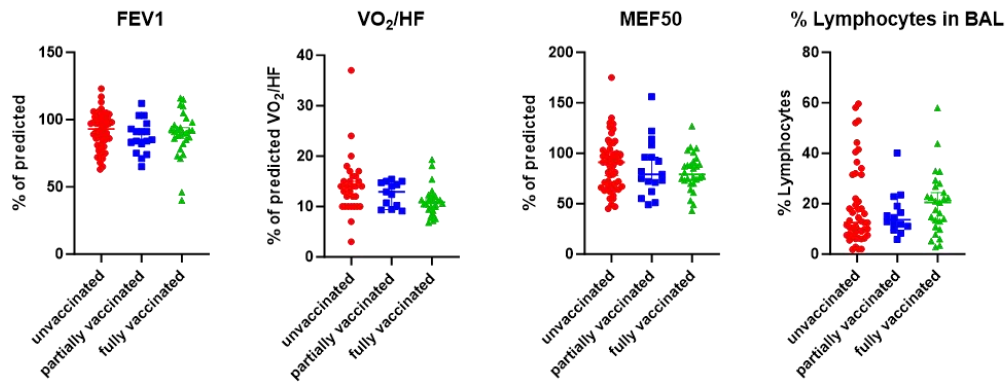
323

324

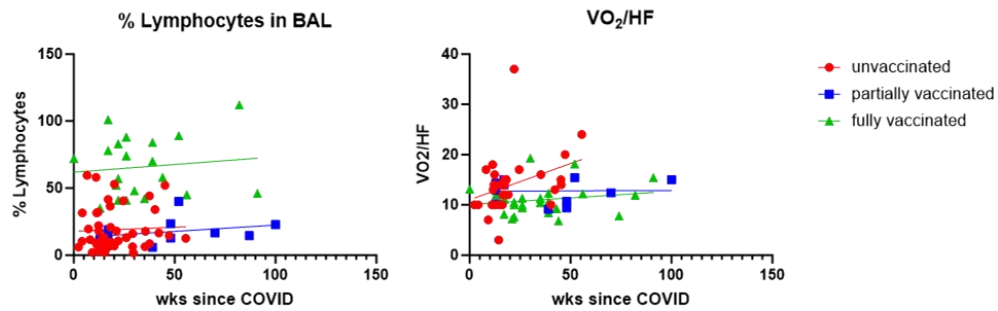
325
326
327
328
329
330
331
332
333
334
335
336
337
338
339
340
341
342
343
344
345
346
347
348
349
350
351
352
353
354
355
356
357
358
359

Figure 2

A



B



C

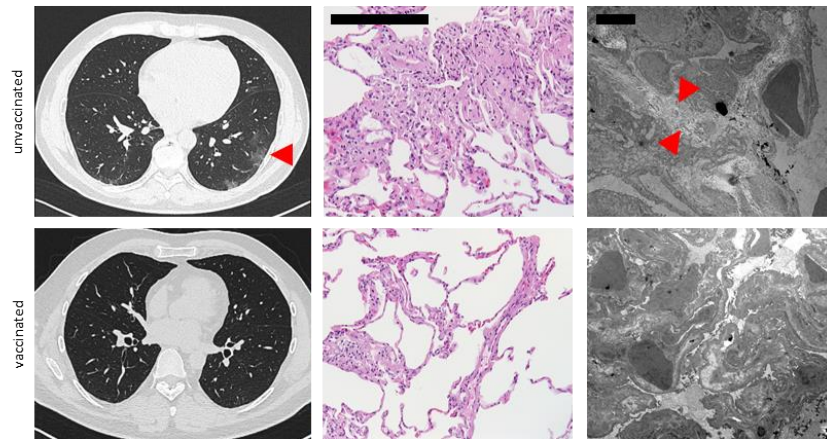


Figure 2. Lung function tests, BAL analyses and representative images from histopathology and HRCT. A, No significant difference between FEV1, oxygen pulse, MEF50 and BAL lymphocyte count according to vaccination status. **B,** No significant correlation between oxygen pulse or BAL lymphocyte count and time since infection, irrespective of vaccination status. **C,** Representative HRCT images showing ground glass opacities (arrowhead) in an unvaccinated compared to a vaccinated PASC patient vs. (left panel). Representative microphotographs of H.E.-stained lung tissue samples from an unvaccinated PASC patient showing interstitial lymphocytosis and discrete centrilobular fibrosis (center panel). *Scale bar, 200 μ m.* Ultrastructural analyses show interstitial collagen deposition (arrowhead) in an unvaccinated PASC patient.

360 **Table 1.** Clinical characteristics, lung function and imaging/histopathology results in PASC patients stratified
361 according to vaccination status.

362

Characteristics	Unvaccinated (n=54)	partially vaccinated (n=17)	fully vaccinated (n=28)	p-value
Age (years; median, range)	41 (18-81)	39 (24-61)	29 (19-73)	0.0056**
Gender, n (%)				
Female	19 (35)	8 (47)	17 (61)	0.0806
Male	35 (65)	9 (53)	11 (39)	
Smoking status, n (%)				
Current smoker	5 (9)	5 (29)	11 (39)	0.0135*
Former smoker	12 (22)	1 (6)	4 (14)	
Never smoker	37 (69)	11 (65)	13 (46)	
Weeks since SARS-CoV-2, median (range)	17 (2-56)	22 (13-100)	35 (13-91)	0.0002***
Presence of autoantibodies¹, n (%)	20 (37)	10 (59)	13 (46)	0.2579
FVC, % pred, median (IQR)	93 (56-120)	90 (68-110)	91 (34-116)	0.3549
TLC, % pred, median (IQR)	103 (63-148)	96 (81-149)	104 (57-142)	0.9556
FEV1, % pred, median (IQR)	93 (63-123)	85 (65-112)	91 (40-116)	0.4239
MEF50, % pred, median (IQR)	91 (45-175)	79 (49-156)	79 (43-127)	0.378
D_{LCO}, % pred, median (IQR)	94 (53-210)	89 (69-124)	96 (72-123)	0.564
VO2/HF, median (IQR)	14 (3-37)	12.9 (9.1-15.4)	10.9 (6.8-19.3)	0.034*
Low FVC <80% pred, n (%)	7 (13)	3 (18)	6 (21)	0.612
Low TLC <80% pred, n (%)	4 (7)	0	1 (4)	0.5753
Low FEV1 <80% pred, n (%)	10 (19)	4 (24)	6 (21)	0.3224
Low MEF50 <80% pred, n (%)	20 (37)	9 (53)	14 (50)	0.3612
Low D_{LCO} <70% pred, n (%)	4 (7)	2 (12)	0	0.1961
BAL				
Lymphocyte count, median (IQR)	12,5 (1,8-59,6)	13,65 (5,8-40,1)	20,5 (2,8-58)	0.6623
Imaging, n (%)				
Ground glass opacities	9 (17)	1 (6)	0	0.0394*
Reticulation	5 (9)	2 (12)	4 (14)	0.086
Noduli	0	2 (12)	1 (4)	0.0495*
Histopathology, n (%)				
Organizing pneumonia	1 (2)	2 (12)	1 (4)	0.2128
Lymphoid follicles	14 (26)	3 (18)	3 (11)	0.3029
Fibrosis	13 (24)	0	3 (11)	0.0353*
Interstitial Fibrosis (TEM), n (%)				
light	0	2 (12)	9 (32)	0.0021**
severe	13 (24)	1 (6)	9 (32)	

¹ANA titer ≥ 1:320 and/or positive IB (Scl-70, PCNA, PM-Scl, dsDNA, SS-B, Histone) or RF > 20 U/ml; FVC: forced vital capacity; IQR, interquartile range; TLC: total lung capacity; FEV1: forced expiratory volume in 1 s; MEF50: mean expiratory flow at 50% of FVC; D_{LCO}: diffusing capacity of the lung for carbon monoxide; VO2/HF: oxygen pulse; BAL: broncho-alveolar lavage; TEM, transmission electron microscopy; *p<0.05; **p<0.005; ***p<0.001

363

364

365

366

367

368

369

370

371

372

373

374

375

376