

36 **ABBREVIATIONS**

37	AET	Analytical Evaluation Threshold (ISO 10993-18 (2020))
38	BSA	Body Surface Area calculated according to DuBois
39	CE	Conformité Européenne
40	DGAV	Deutsche Gesellschaft für Allgemein- und Viszeralchirurgie
41	ECOG	Eastern Cooperative Oncology Group
42	FDA	U.S. Food and Drug Administration
43	GC-MS	Gas Chromatography coupled with Mass Spectrometry
44	HSGC-MS	Head-space Gas Chromatography coupled with Mass Spectrometry
45	IC	Ion Chromatography
46	ICP-OES	Inductively Coupled Plasma Atomic Emission Spectrometry
47	LC-MS	Liquid phase chromatography □ coupled to a Mass Spectrometer
48	MDN	Multi-Directional Nebulizer (QuattroJet™, REGER Medizintechnik
49		GmbH, Villingendorf, Germany)
50	PCI	Peritoneal Carcinomatosis Index according to Sugarbaker
51	PIPAC	Pressurized IntraPeritoneal Aerosol Chemotherapy
52	PSM	Peritoneal Surface Malignancies
53	RIPAC	Rotational intraperitoneal aerosol chemotherapy
54	SDN	Single-direction nebulizer

55

56

57

58

59

60

61

62

63

64

65 **AUTHOR CONTRIBUTIONS**

66 Fabian Kockelmann and Urs Giger-Pabst: study design, coordination of the study, data
67 acquisition, data interpretation, logistics, drafting of the manuscript, and critical revision of
68 the manuscript

69 Amayu Wakoya Gena, Hayder Alsaad and Conrad Voelker: schlieren experiments, drafting of
70 the manuscript, and critical revision of the manuscript

71 Daniel Göhler and Mehdi Ouaiissi: drafting of the manuscript and intellectual and scientific
72 contributions depending on their field of expertise

73 Sarah Barbey: study protocol, coordination of animal experiments, and perioperative
74 management of animals

75 Jürgen Zieren: study design, PIPAC procedures, data acquisition, data interpretation, logistics,
76 drafting of the manuscript, and critical revision of the manuscript

77

78 **DISCLOSURE**

79 All authors have no conflicts of interest or financial ties to disclose. The animal experiments
80 were funded by the Association Tourangelle de recherche en oncologie du val de Loire (AT-
81 ROVL). All data produced in the present study are available upon reasonable request to the
82 authors. The MDNs for the ex- and in-vivo animal experiments were provided from REGER
83 Medizintechnik GmbH, Villigendorf, Germany)

84

85 **ACKNOWLEDGEMENTS**

86 We are thankful to Aesculap Akademie GmbH, Bochum, Germany for providing the technical
87 equipment to simulate laparoscopic surgery. Especially to Mrs. Anna-Maria Krug, Training
88 Manager at Aesculap Akademie GmbH, Bochum, Germany for her important help. We also
89 thank Mr. Mohsen Faraji and Mr. Burak Kabakci, Technomedics GmbH Illertissen, Germany
90 for providing technical and logistical support for the schlieren experiments in Weimar,
91 Germany. The schlieren flow visualizations were supported by the German Research
92 Foundation (DFG), Grant No. 444059583.

93

94 **MINI ABSTRACT**

95 Toxicological analyses confirm that doxorubicin, cisplatin, and oxaliplatin nebulized with the
96 MDN do not release leachables that pose a toxicological risk to patients. Through technical
97 risk analysis and PIPAC simulations, a safety concept for the administration of MDN-PIPAC
98 was established. No technical/medical intraoperative adverse events were observed. The
99 perioperative course was comparable to that of the conventional axial single-direction
100 nebulizer (SDN) PIPAC.

101

102 **ABSTRACT**

103 **Background/Aim:** To test the chemoresistance of a multi-directional nebulizer (MDN) and to
104 establish and implement a perioperative clinical safety concept for its clinical use to deliver
105 pressurised intraperitoneal aerosol chemotherapy (MDN-PIPAC).

106 **Study design:** Ex-vivo nebulization of cytostatic drugs with the MDN device to assess
107 chemoresistance/toxicological risks. Establishment of a perioperative safety concept for the
108 clinical administration of MDN-PIPAC by ex- and in-vivo porcine simulation studies.
109 Unicentric case series of 30 MDN-PIPACs in 21 patients with peritoneal surface malignancies
110 (PSM). Endpoints were intraoperative adverse events and perioperative complications
111 (Clavien-Dindo).

112 **Results:** Toxicological studies/risk assessment confirm the safety of administering PIPAC
113 with the MDN. The horizontal nozzles must protrude at least 7 mm beyond the most distal
114 end of the trocar tip and lateral tilting should be prevented by fixation of the device in a
115 single-arm holder. A total of 21 patients (male/female ratio: 2:1) with a mean age of 62
116 (range: 38-86) years underwent 30 consecutive MDN-PIPACs for peritoneal surface
117 malignancies of different origin. ECOG 0 and 1 were seen in five and 16 patients,
118 respectively. Thirteen, seven, and one patient underwent one, two, and three MDN-PIPACs,
119 respectively. Two patients received only one cycle of MDN-PIPAC because they were
120 considered candidates for cytoreductive surgery and heated intraperitoneal chemotherapy.
121 There were no intraoperative technical/medical problems observed. Four patients suffered
122 from postoperative grade I complications.

123 **Conclusions:** Compounds leached during chemotherapy nebulization with the MDN are
124 toxicologically safe. MDN-PIPAC administrations are safe and the postoperative course is
125 comparable to that of the conventional PIPAC nebulizer.

126

127 **KEYWORDS**

128 PIPAC, multi-directional nebulizer (MDN), MDN-PIPAC, chemical compatibility,
129 toxicological risk analysis, CT-peritoneography, schlieren imaging, clinical safety, clinical
130 feasibility

131

132 **1.0 INTRODUCTION**

133 For more than a decade, pressurised intraperitoneal aerosol chemotherapy (PIPAC) has been
134 used for the treatment of peritoneal surface malignancies (PSM). Clinical results are
135 encouraging, but data from prospective, randomized trials clearly demonstrating the efficacy
136 of this treatment are still lacking [1, 2]. A common feature of all previously available
137 nebulizers for PIPAC therapy is that they all have only one nebulizer unit (axial single-
138 direction nebulizer (SDN)), which ejects the chemotherapeutic droplets in an axial direction.
139 The majority (97.5 % of the volume) of the nebulized chemotherapy impacts the peritoneum
140 directly, which is located below the nebulizer orifice [3]. It has also been suggested that the
141 locally high drug deposition that occurs when using a SDN results in potential local toxicity
142 that could lead to an increase in perioperative complications, particularly when additional
143 surgical procedures such as complex adhesiolysis or bowel resection are performed at the
144 same time as PIPAC [4 - 6]. However, more recent clinical data appear to relativise such
145 assumptions [7].

146 However, the PIPAC nebulizer technology has been further developed to optimize the spatial
147 distribution of the drug. A new and innovative concept is multi-directional drug
148 aerosolization. Recent data obtained with a multi-directional drug nebulizer prototype
149 reported an improved spatial drug distribution pattern in an ex-vivo PIPAC model compared
150 to standard SDN technology [8].

151 A first multi-directional nebulizer (MDN) for the clinical off-label application of PIPAC
152 (MDN-PIPAC) is now commercially available. In addition to the conventional axial nozzle,
153 three additional horizontal nozzles are integrated into the nebulizer head at 120° intervals.
154 This nozzle configuration enables nebulization of the chemotherapy over a spray angle of
155 almost 240° - compared to 77° with a SDN [9]. Since there are still no documented preclinical
156 or clinical applications with this device worldwide, we decided to conduct further extensive
157 preclinical studies before the first clinical MDN-PIPAC applications.

158 Therefore, the objectives of this study were (i) to investigate a potential toxicological risk
159 from substances leaking from the device when used in combination with cytotoxic drugs, and
160 (ii) to develop an intraoperative safety concept for the administration of MDN-PIPAC using
161 an ex-vivo PIPAC model, schlieren imaging, and in-vivo large animal CT peritoneography,
162 and iii) to analyse a consecutive case series of 30 MDN-PIPACs to evaluate perioperative
163 safety and feasibility in patients with peritoneal surface malignancies (PSM).

164

165 **2.0 MATERIAL & METHODS**

166 **2.1 Research sites and institutes:** Nebulization for cytostatic drug
167 compatibility/toxicology studies of the MDN and the in-vivo animal experiments were carried
168 out at the French National Research Institute for Agriculture, Food and Environment
169 (INRAE), Centre Val de Loire Nouzilly, France. Schlieren imaging was performed at the
170 Bauhaus-University Weimar, Weimar, Germany. Chemical characterisation and toxicological

171 evaluation were conducted by RESCOLL, Pessac, France, and TentaConsult Pharma & Med
172 GmbH, Münster, Germany, respectively.

173 **2.2 MDN chemotherapy compatibility study:** Doxorubicin, cisplatin, and oxaliplatin were
174 purchased from Hexal AG, Holzkirchen, Germany, Accord Healthcare B.V. Utrecht, the
175 Netherlands, and Medac GmbH, Wedel, Germany. Drug doses (doxorubicin 6 mg, cisplatin
176 30 mg, and oxaliplatin 120 mg per m² of body surface area (BSA)) were studied according to
177 data from phase I safety studies and clinical use [10 - 12]. A patient with a height of 1.90 m
178 and a weight of 100 kg was assumed. The BSA was calculated according to the DuBois
179 formula [13]. Glucose 5% and NaCl 0.9% were purchased from B. Braun, Melsungen,
180 Germany. Oxaliplatin was diluted with glucose 5% and doxorubicin and cisplatin with NaCl
181 0.9% to a total of 50 ml and 150 ml, respectively. The same solutions were used as blank
182 controls. Blank control solutions were immediately filled into sterile glass bottles (ref. #
183 FRAA-250-60, Labbox GmbH, Düsseldorf, Germany) and stored protected from light at 4°C.
184 The chemotherapy solutions for nebulization experiments were filled into syringes (ELS 200
185 ml (S), MEDTRON AG, Saarbrücken, Germany), the syringe instated into the high-pressure
186 injector head (Accutron[®] HP-D Vision, MEDTRON AG, Saarbrücken, Germany), vented,
187 and then connected to the high-pressure line of the MDN (QuattroJet[™], REGER
188 Medizintechnik GmbH, Villigendorf, Germany). The shaft of the MDN was wrapped with
189 sterile surgical compress proximal to the head of the nebulizer and then positioned vertically
190 in a tight and stable position in the neck of a sterile 250 ml glass bottle (ref. # FRAA-250-60,
191 Labbox GmbH, Düsseldorf, Germany). Nebulization could take place unhindered with the
192 nebulizer head in the body of the bottle at a flow rate of 1.5 ml/s with an upper pressure limit
193 of 300 psi. Nebulization was undertaken under a vertical laminar air flow bench. Doxorubicin
194 and Cisplatin were nebulized one after the other but into the sample bottle. All experiments
195 were performed in triplicates. The sample and blank control solution bottles were sealed
196 airtight immediately after the experiments and stored protected from light at 4°C. The samples
197 were transported to the laboratory for further processing by courier within 4 hours while
198 refrigeration was maintained.

199 **2.3 Chemical characterisation and toxicological risk assessment:** MDN device
200 (QuattroJet[™], REGER Medizintechnik GmbH, Villigendorf, Germany) and chemical
201 characterisation according to the ISO 10993-18:2020 [14]. Head-Space Gas Chromatography
202 coupled with Mass Spectrometry (HSGC-MS) was used for detecting volatile organic
203 compounds, Gas Chromatography coupled with Mass Spectrometry (GC-MS) for detecting
204 semi-volatile organic compounds, Liquid Phase Chromatography coupled to a Mass
205 Spectrometer (LC-MS) for detecting non-volatile organic compounds, Inductively Coupled
206 Plasma Atomic Emission Spectrometry (ICP-OES) for quantifying the inorganic elements,
207 and Ion Chromatography (IC) for quantifying the ions. The Analytical Evaluation Threshold
208 (AET) was applied. The AET defines the threshold below which leachable or extractable
209 substances cannot be identified or quantified and therefore it can be assumed without further
210 evaluation that such a substance does not pose a toxicological risk.

211 The parameters used for the toxicological risk assessment were set to consider the worst case.
212 Three consecutive MDN-PIPAC administrations were assumed with no time interval in

213 between (instead of a treatment interval of four to six weeks between each PIPAC cycle). In
214 addition, the exposure of children with a body weight of 10 kg was calculated with the
215 amount used for the treatment of an adult. The toxicological risk associated with leachables
216 was assessed by collecting data and identifying critical health endpoints through literature
217 searches and toxicological risk assessment from PubChem (HSDB), PubMed, ChemIDplus,
218 ECHA databases, and various other online sources and databases (e.g., FDA.gov) in
219 accordance with ISO 10993-17:2023 [15].

220 **2.4 Preclinical assessment of the MDN-PIPAC safety checklist and schlieren imaging:**

221 As a first step, a team of two surgeons and one PIPAC nurse analysed whether the use of the
222 MDN (QuattroJet™, REGER Medizintechnik GmbH, Villigendorf, Germany) could result in
223 additional intraoperative risks or hazards for healthcare personnel. Potential risks were
224 assessed for clinical relevance. Appropriate safety measures were then developed and
225 integrated into our existing intraoperative PIPAC safety checklist [16]. In a second step, using
226 this adapted intraoperative PIPAC safety checklist, the team repeatedly simulated MDN-
227 PIPAC applications in the operating room using NaCl 0.9% (B. Braun, Melsungen, Germany)
228 on an established ex-vivo PIPAC model [17] to test the coherence of the adapted
229 intraoperative PIPAC safety measures and the safety checklist.

230 In addition, the schlieren imaging system of the Bauhaus-University Weimar (Figure 1) was
231 used to investigate the potential for chemotherapy aerosol/CO₂ backflow through the trocar
232 valve system into the operating theatre environment during MDN-PIPAC. A worst-case
233 scenario was simulated in which the head of the MDN is misplaced in the trocar shaft,
234 resulting in nebulization in the trocar sleeve. Schlieren imaging is a flow visualization
235 technique that allows for visualizing density gradients in fluids by capitalizing on the
236 refraction of light when entering a medium of different density.

237 The utilized schlieren system uses a single concave spherical mirror, where the light beams
238 from the source and the returning light rays from the mirror align coincidentally, forming an on-
239 axis single-mirror coincident schlieren system [18 - 20]. The system consists of five optical
240 elements: concave spherical mirror (1 m in diameter), light source (light-emitting diode
241 (LED) including condenser lens and pinhole), beam splitter, schlieren cut-off, and digital
242 camera (Canon EOS 5DS R, with 50.6 megapixels image size and a 135 mm focal-length
243 lens). The schlieren mirror has a surface accuracy of $\lambda/9.5$, where λ represents the wavelength
244 of HeNe laser light. This high level of accuracy makes it highly sensitive, enabling the
245 visualization of very small density gradients in fluids. In this study, the density gradient
246 results from differences between the leaking CO₂ and the surrounding air. To enhance
247 visualization, the CO₂ was heated using an insufflator (Figure 2), creating a sufficiently large
248 density gradient for schlieren imaging. The system's ability to visualize this density gradient
249 was also tested prior to the investigation (Figure 5A). Throughout the investigations, the
250 camera's video imaging was set at 50 frames per second.

251 The schlieren flow visualizations investigated possible CO₂/aerosol backflow scenarios during
252 clinically relevant MDN-PIPAC scenarios in an ex-vivo PIPAC model with three litre
253 volume, MDN in central, vertical position, fixed on a stand in a 12 mm balloon trocar (Kii
254 Sleeve with advanced fixation, Applied Medical, California, USA) with lateral nebulizer

255 nozzles that protrude 7 mm beyond the distal end of the trocar shaft. Stable capnoperitoneum
256 of 12 or 20 mmHg was maintained throughout the whole experiments (Insufflator Flow 50, B.
257 Braun SE, Melsungen, Germany). Injection of 50- and 150-ml distilled water at 1.5 ml
258 flow/min (SinoPower-D, Sino Medical-Device Technology Co., Ltd, Shenzhen, China).
259 Worst-case scenario simulation at 20 mmHg capnoperitoneum, flow rate 1.5 ml/min with
260 incorrect positioning of the MDN head in the distal trocar shaft, so that nebulization occurred
261 in the trocar shaft. During the flow visualizations, the ex-vivo PIPAC model was placed in
262 front of the schlieren mirror (Figure 2).

263 **2.5 In-vivo animal MDN-PIPAC and CT-peritoneography:** Domestic pigs were handled
264 and cared for according to all relevant guidelines by authorised investigators. The study (file #
265 40583) was approved by the French Ministry of Higher Education and Research (Ministère de
266 l'enseignement supérieur et de la recherche). A total of three male animals weighing from 47
267 to 42 kg were used. Anaesthesia was induced by intramuscular injection of ketamine 20
268 mg/kg, xylazine 2 mg/kg, and a subcutaneous injection of atropine 0.02 mg/kg, and then
269 completed by endotracheal intubation. The animals were maintained under anaesthesia by
270 isoflurane 3%, intravenous sufentanil, and cisatracurium. The animals were fixed in a supine
271 position in the CT-scanner (SOMATOM Definition AS 128, Siemens, Germany) to deliver
272 HP/HD PIPAC described previously [12]. The MDN was placed at the centre of the abdomen
273 in a perpendicular position so that the horizontal nozzle openings protruded approx. 7 mm
274 beyond the end of the 12-mm trocar (Kii balloon blunt-tip access system, Applied Medical,
275 California, USA). The orientation of these horizontal nozzle openings was chosen so that one
276 nozzle was directed into the right and left upper abdomen and the third nozzle into the small
277 pelvis. Another 5-mm trocar was inserted into the abdominal cavity to monitor the position of
278 the nozzle head with a 5 mm camera and the nebulization process. CT-peritoneography was
279 performed using a modified technique previously described in [21]. For this purpose, 100 ml
280 Imeron[®] 300 (Bracco Imaging GmbH, Konstanz, Germany) was diluted in 900 ml NaCl 0.9%
281 (B Braun, Melsungen, Germany) in a ratio of 1:10. 150 ml of this solution was then
282 administered for HP/HP-PIPAC CT-peritoneography at a flow rate of 1.5 ml/s (Accutron CT-
283 D Vision, MEDTRON AG, Saarbrücken, Germany). CT-peritoneography was performed
284 immediately at the end of the HP/HD-PIPAC. After CT acquisition, the animals were
285 immediately euthanized by intravenous injection of phenobarbital.

286 **2.6 Patients' selection criteria for MDN-PIPAC:** The clinical study was performed in
287 line with the guidelines of the Declaration of Helsinki at the Department of Surgery, Klinikum
288 Dortmund, University Hospital of the University Witten/Herdecke, Germany. All patients
289 gave oral and written informed consent. The approval of the Ethics Committee of the Medical
290 Faculty of the University of Münster and the Medical Association Westphalia-Lippe in
291 Germany (file # 2021-360-f-s) was obtained. All patients had histologically confirmed
292 primary or metastatic peritoneal surface malignancies (PSM). Patients were selected by a
293 multidisciplinary tumor board accredited by the German Society for General and Visceral
294 Surgery (DGAV). All procedures were performed as previously described in detail in [10, 12]
295 and were performed by one of the authors (J. Z., senior surgeon). The time interval between
296 cycles was between four to six weeks. Systemic chemotherapy was discontinued one week
297 prior and after MDN-PIPAC. Patients were informed that PIPAC treatment was not provided

298 within the framework of evidence-based therapy guidelines. All patients gave their oral and
299 written consent. Oxaliplatin at a dose of 120.0 mg/m² body surface area (BSA) diluted in a
300 total of 150 ml glucose 5% was administered in case of PSM of colorectal and appendiceal
301 primary tumours. For all other tumour entities, doxorubicin 6.0 mg/m² BSA diluted in 50 ml
302 NaCl 0.9% followed by cisplatin 30.0 mg/m² BSA diluted in 150 ml NaCl 0.9% was
303 administered [10 - 12]. According to the manufacturer's instructions, the MDN was operated
304 at a liquid fluid volume flow of 1.5 ml/s with an upper pressure limit of 300 psi. Access to the
305 peritoneal cavity was always obtained via an infraumbilical open Hasson approach. Before
306 starting the drug nebulization, the capnoperitoneal pressure was increased from 12 to 20
307 mmHg and then kept constant for 30 minutes.

308 **2.7 Perioperative short-term outcome and data acquisition:** Retrospective data
309 acquisition of a consecutive case series of 30 delivered MDN-PIPACs. The entire staging
310 laparoscopy, including documentation of the Sugarbaker PCI score, the amount of ascites and
311 the quality of chemotherapy nebulization, is monitored by video according to our standards
312 for intraoperative documentation. All data are stored electronically in the patient's record.
313 Data acquisition and database management are carried out by the co-author J. Z. as part of the
314 required quality assurance as a certified centre of the DGAV. Perioperative adverse events are
315 graded according to the Clavien-Dindo Classification [22, 23]. Data are expressed as absolute
316 numbers whereas continuous data are expressed as are expressed as median values followed
317 by the range in parentheses, i.e. median (range).

318

319 **3.0 RESULTS**

320 **3.1 Chemical characterisation and toxicological risk assessment:** The results of the
321 chemical analyses of nebulized chemotherapy solutions are summarized in Table 1.

322 The independent systematic toxicological risk assessment based on the assumption of three
323 consecutive PIPAC sessions on the same day in a child with a body weight of 10 kg revealed
324 no toxicological risk for the few compounds detected after nebulization.

325 **3.2 Preclinical technical, safety checklist and surgical approach assessment for MDN-**
326 **PIPAC:** The following three relevant sub-areas were defined and perioperative measures were
327 implemented:

328 **3.2.1 Operational parameters:** According to previous research data and the manufacturer's
329 specifications, the MDN is operated best with a pressure of 150-250 psi with an upper
330 safety limit pressure of 300 psi. In practice, this pressure operating window
331 corresponds to the liquid volume flow rate of 1.2 ml/s-1.6 ml/s. [2]. Accordingly,
332 these operating parameters were stored in the high-pressure injector as a separate
333 MDN-PIPAC working programme. As there are no other differences in handling and
334 technical operation compared to the conventional nebulizer used, no additional
335 measures were necessary.

336 **3.2.2 Construction & Design:** Due to the three horizontal nozzles, there is a potential risk of
337 drug nebulization in the trocar if the horizontal nozzles are not placed sufficiently

338 beyond the distal end of the trocar into the abdominal cavity. In the worst case,
339 retrograde leakage of chemotherapy through the trocar valve into the operating theatre
340 could occur and harm healthcare workers. To avoid this, the correct positioning of the
341 nebulizer head in the trocar has been added to our standard safety checklist. The four-
342 eye principle is used to check that the horizontal nozzles extend beyond the most distal
343 point of the trocar. It should be noted that most trocars are bevelled at an angle of
344 approximately 15°. The most distal end of the trocar is therefore used as the reference
345 point (Figure 3A).

346 **3.2.3 Surgical approach:** To optimize spatial aerosol distribution during MDN-PIPAC, the
347 spraying distance between the nozzle orifice and the peritoneum should be as large as
348 possible [2, 7]. Periumbilical, perpendicular placement of the MDN is therefore ideal,
349 if surgically possible (Figure 4A). Additionally, we decided to orientate the MDN in a
350 way that one horizontal spray jet pointed to the right upper, a second to the left upper
351 abdominal quadrant, and the third towards the small pelvis (Figure 4B). In addition,
352 we decided to routinely fix the nebulizer intraoperatively in a single-arm holder (M-
353 TRAC, Braun, Melsungen, Germany) to further prevent tilting and axial sliding into
354 the trocar. The central periumbilical perpendicular MDN position as well as the
355 orientation of the horizontal nozzle orifices were integrated into our intraoperative
356 safety checklist.

357 **3.3 Ex-vivo MDN-PIPAC simulation and schlieren imaging:** As the distal end of the trocar
358 is angled, special care must be taken to ensure that the distal end of the trocar is visible
359 intraoperatively so as not to interfere with the nebulization of the horizontal nozzles. The
360 correct position of the MDN head has therefore been included as a separate item in our
361 extended safety checklist. The openings of the horizontal nozzles must extend at least 7
362 mm beyond the distal end of the trocar to avoid interference during nebulization (Figure
363 3A). In addition, the vertical position of the MDN in the 10/12-mm trocar was found to
364 cause the MDN to tend to slide inward in the trocar without additional fixation. To avoid
365 MDN slippage into the trocar, the device is placed on the trocar head with a rubber ring
366 (sterile, reusable trocar seal) previously pulled over the shaft of the nebulizer in such a
367 way that the rubber ring fits tightly on the trocar head and prevents the nebuliser from
368 slipping inside the trocar (Figure 3B). To further stabilize the position of the MDN, using
369 a single-arm holder turned out to be essential and was therefore also included in our
370 safety checklist. Mispositioning the MDN head with the horizontal nozzles nebulizing in
371 the trocar shaft could cause aerosol leakage into the environment. However, multiple
372 simulations of such a scenario showed no macroscopic detectable retrograde aerosol
373 leakage into the environment. The further schlieren visualisations also showed no
374 leakage of CO₂/aerosol into the environment in any of the scenarios investigated. Even
375 with unfavourable positioning of the MDN head with nebulization in the distal trocar
376 shaft, there was no evidence of even a slight retrograde flow through the trocar valve.
377 Figure 5B shows a representative schlieren image.

378 **3.4 In-vivo pig MDN-PIPAC CT-peritoneography:** The CT-peritoneographies of the
379 three pigs could be performed without perioperative complications. The animals showed no
380 cardiorespiratory problems due to the capnoperitoneal pressure of 20 mmHg. Our previously

381 prepared MDN-PIPAC safety checklist was implemented without any problems. The
382 subsequent CT-peritoneographies showed an excellent distribution pattern of the administered
383 contrast agent aerosol. However, no contrast agent was visible in the ventral portions of the
384 abdominal cavity. Figure 6 depicts representative images of pig N° 1.

385 **3.5 Clinical baseline characteristics:** A total of 21 patients (male/female ratio: 2:1) with a
386 mean age of 62 (range: 38-86) years underwent 30 consecutive MDN-PIPACs. ECOG 0 and 1
387 were seen in five and 16 patients, respectively. Patients had PSM of the upper gastrointestinal
388 tract (n=6), ovarian cancer (n=4), colorectal cancer (n=3), hepato-pancreatico-biliary tract
389 (n=3), malignant epithelioid peritoneal mesothelioma (n=2), and other (n=3). Eleven patients
390 had metachronous PSM. Prior to MDN-PIPAC, seventeen patients had undergone primary
391 tumor resection. The median number of patients had 2 (range: 1-5) lines of systemic
392 chemotherapy before undergoing MDN-PIPAC. Seven patients had previously undergone a
393 median of 2 (range: 1-4) PIPACs with the conventional PIPAC nebulizer in our institutions.
394 The patients' preoperative baseline data are listed in Table 2.

395 **3.6 MDN-PIPAC procedure details, morbidity, and mortality:** Abdominal access was
396 achieved in all patients. Thirteen, seven, and one patient underwent one, two, and three MDN-
397 PIPACs, respectively. Two patients received only one cycle of MDN-PIPAC because they
398 were considered candidates for cytoreductive surgery (CRS) and heated intraperitoneal
399 chemotherapy (HIPEC) at the time of staging laparoscopy for MDN-PIPAC.

400 The median Sugarbaker PCI score and ascites at the first MDN-PIPAC were 25 (1-35) and
401 200 ml (0-800 ml), respectively. The overall mean (range) operative time was 52.3 (48-78)
402 minutes. The gradual pressure build-up and the subsequent exposure phase of 30 minutes at a
403 capnoperitoneal pressure of 20 mmHg were well tolerated. No patient showed signs of cardio-
404 respiratory impairment from the procedure. No intraoperative surgical or technical problems
405 occurred.

406 In total, four patients suffered grade I (Dindo-Clavien) complications after a total of 30 MDN-
407 PIPACs (4/30). Three patients experienced persistent nausea and vomiting postoperatively,
408 requiring prolonged intravenous rehydration and antiemetic therapy (without gastric tube) for
409 48 hours postoperatively. Another patient complained of abdominal pain, which could also be
410 managed after extending intravenous analgesic therapy. No complications grade II-V were
411 observed. The German health system requires a minimum hospitalization of 3 days for PIPAC
412 application in order to be fully reimbursed by the health insurance companies. All patients
413 were discharged on the third postoperative day at home.

414

415 **4.0 DISCUSSION**

416 For more than a decade, a PIPAC nebulizer has been available for off-label clinical use. This
417 technology, with an axially mounted nebulizer unit, has become the standard PIPAC device.
418 Due to its design and performance characteristics, the distribution pattern of the atomized
419 chemotherapy is not homogeneous. Below the opening of the nebulizer unit, approximately

420 97% by volume is deposited directly onto the underlying peritoneum by inertial impaction [4,
421 24 - 27]. Recently, other PIPAC nebulizers have become available on the market. However,
422 all nebulizers are based on the same/similar design as the standard technology. Therefore, the
423 problem of local chemotherapy accumulation and inhomogeneous drug distribution pattern in
424 the peritoneal cavity remains unresolved [2], which may affect the oncological efficacy of
425 PIPAC [28]. Therefore, the optimal position of the standard PIPAC nozzle has been
426 investigated in recent years in order to optimize the spatial distribution of chemotherapy [16,
427 29, 30]. More recently, new experimental PIPAC nozzle technologies have been developed.
428 Rotational intraperitoneal pressure aerosol chemotherapy (RIPAC) uses a modified nebulizer
429 technology similar to the standard PIPAC nebulizer. However, to optimize drug distribution,
430 the nozzle rotates 30° around its vertical axis in the abdominal cavity. In-vivo large animal
431 data indicate that RIPAC leads to a significantly more homogeneous distribution pattern and
432 higher penetration depths of doxorubicin into the tissue compared to the standard PIPAC [31,
433 32]. Another experimental approach is the use of a preclinical multi-directional nebulizer
434 (MDN). Braet et al. [33] observed in an ex-vivo PIPAC model that the use of their
435 experimental MDN prototype improved the spatial drug distribution of nebulized
436 nanoparticles compared to an SDN. Based on these experimental data, it seems obvious that
437 PIPAC nozzles, which optimize drug distribution, could also be promising in clinical
438 application. For some time now, a CE Class IIa certified MDN has been available for off-label
439 clinical use for MDN-PIPAC [2]. We carried out extensive preclinical testing before
440 introducing this new device into our daily practice.

441 After the premature discontinuation of a French prospective, randomized phase II study
442 (PIPAC EstoK 01) (<https://clinicaltrials.gov/study/NCT04065139>) [35], it was vividly
443 discussed whether toxic substances could arise during the application of PIPAC due to the
444 interaction of the chemotherapy solution with the PIPAC nebulizer/syringe/tube system.
445 Therefore, independent toxicological investigations were performed as a first step. For the
446 worst-case scenario with the highest chemotherapy doses, the toxicological investigations
447 showed that no relevant toxicologically questionable substances were observed. The risk
448 assessment was further based on the assumption that three PIPACs are administered
449 consecutively on one day to a patient with a body weight of 10 kg. Even this extreme scenario
450 did not reveal any cumulative toxicological risk for patients. Furthermore, these data indicate
451 that the MDN device could also be used in children with a body weight > 10 kg. It is
452 important to emphasize that our toxicological data are only valid for this type of nozzle.
453 According to our current knowledge, there is no data available for other types of nebulizers.

454 Our previous and present technical analysis with PIPAC surgeons and scrub nurses in our
455 department showed that the handling of the MDN differs only slightly from that of the
456 standard nebulizer [2]. The MDN unit requires a higher flow rate which can be programmed
457 into the high-pressure injector. However, a major difference is the three additional nozzles
458 built horizontally into the MDN head. Repetitive ex-vivo simulations have shown that the
459 correct mounting of the nozzle head is crucial. The lateral openings of the nebulizers must
460 protrude at least 7 mm beyond the distal end of the trocar for correct atomization.

461 During the technical risk assessment, concerns were expressed within the PIPAC team that
462 incorrect positioning of the MDN head in the trocar shaft could result in a possible aerosol

463 backflow via the trocar valve into the operating theatre and thus pose a significant risk to
464 healthcare staff. As initial simulations with the ex-vivo PIPAC model did not confirm these
465 fears; we carried out additional schlieren imaging experiments. All of them confirm that even
466 when the MDN head is incorrectly positioned, no CO₂ is released retrogradely into the
467 environment. Therefore, no backflow of aerosol is assumed based on the CO₂ visualization.

468 However, we observed that the MDN can slip into the trocar due to the increased weight of
469 the device. Therefore, we have added a sterile rubber ring to the MDN that is pulled over the
470 nozzle and positioned so that it rests directly on the trocar head, while at the same time
471 achieving the ideal position for the MDN head. Finally, another important safety point is the
472 consistent use of a single-arm holder, which additionally fixes the MDN in a strictly vertical
473 position in the trocar. This measure also prevents the MDN from accidentally tilting sideways
474 during the spraying process, which could affect the spatial distribution pattern of the drug. In
475 order to better monitor this correct position intraoperatively, it would be desirable if the
476 manufacturer could provide a safety mark indicating the ideal position of the MDN head in
477 the trocar. The manufacturer was informed of these points to improve the administrability and
478 safety of MDN-PIPAC.

479 To further refine the intraoperative MDN-PIPAC safety checklist, based on our previous ex-
480 vivo simulations, we performed MDN-PIPAC in the large animal model immediately
481 followed by CT-peritoneography to visualize the quality of the spatial aerosol distribution.
482 The administration of all three MDN-PIPACs went without any technical or safety problems.
483 The CT-peritoneographies revealed wide aerosol deposition. In particular, areas such as the
484 omental bursa, hepatic interlobar, and deep entero-enteric regions were also affected. Only the
485 ventral parts of the abdominal cavity showed no contrast. However, large gravity-dependent
486 fluid collections, as previously observed with a SDN, did not occur [27].

487 The clinical application of the elaborated intraoperative MDR-PIPAC safety checklist enabled
488 us to deliver 30 consecutive MDN-PIPACs without intraoperative problems. The
489 postoperative course was characterized by four patients with minor complications (Dindo-
490 Clavien grade I). Based on this initial experience, no clinical difference from SDN-PIPAC
491 was observed at our institution [12].

492

493 **5.0 CONCLUSION**

494 Toxicological data show that the use of the MDN does not generate any leachable substances
495 that could pose a risk to patients. Ex-vivo simulations confirm the importance of correct
496 positioning of the MDN in the trocar and, if possible, in a periumbilical position. Schlieren
497 imaging during ex-vivo MDN-PIPAC simulations showed that even in a worst-case scenario,
498 where the MDN head is incorrectly positioned in the trocar shaft, there is no backflow of CO₂
499 via the trocar valve into the environment. Consequently, no backflow of chemotherapy
500 aerosol is assumed. Moreover, our first clinical data on the MDN-PIPAC shows that it is safe
501 to use and causes no problems when the safety checklist is properly adapted to this device.
502 Finally, the perioperative clinical outcome of MDN-PIPAC is comparable to that of our
503 patients previously treated with the SDN. Whether such new devices will have a positive

Kockelmann et al. – V4_AW_HA (1)

504 impact on clinical outcomes remains uncertain. Unfortunately, it is unlikely that there will be
505 prospective studies in the near future to clarify this issue. Therefore, we suggest that the type
506 of nebulizer used for PIPAC should also be documented in the ISSPP PIPAC database [35].
507 Such a large database could provide insight into the role of different nebulizers used in
508 oncological outcomes.

509 **REFERENCES**

- 510 1. Di Giorgio A, Macrì A, Ferracci F, Robella M, Visaloco M, De Manzoni G, Sammartino
511 P, Sommariva A, Biacchi D, Roviello F, Pastorino R, Pires Marafon D, Rotolo S, Casella
512 F, Vaira M. 10 Years of Pressurized Intraperitoneal Aerosol Chemotherapy (PIPAC): A
513 Systematic Review and Meta-Analysis. *Cancers*. 2023; 15(4):1125.
514 <https://doi.org/10.3390/cancers15041125>
- 515 2. Nadiradze G, Horvath P, Sautkin Y, Archid R, Weinreich F-J, Königsrainer A, Reymond
516 MA. Overcoming Drug Resistance by Taking Advantage of Physical Principles:
517 Pressurized Intraperitoneal Aerosol Chemotherapy (PIPAC). *Cancers*. 2020; 12(1):34.
518 <https://doi.org/10.3390/cancers12010034>
- 519 3. Göhler D, Khosrawipour V, Khosrawipour T, Diaz-Carballo D, Falkenstein TA, Zieren J,
520 Stintz M, Giger-Pabst U. Technical description of the microinjection pump (MIP[®]) and
521 granulometric characterization of the aerosol applied for pressurized intraperitoneal
522 aerosol chemotherapy (PIPAC). *Surg Endosc*. 2017 Apr;31(4):1778-1784. doi:
523 10.1007/s00464-016-5174-5. Epub 2016 Sep 8. PMID: 27631320.
- 524 4. Tempfer CB, Rezniczek GA, Ende P, Solass W, Reymond MA. Pressurized
525 Intraperitoneal Aerosol Chemotherapy with Cisplatin and Doxorubicin in Women with
526 Peritoneal Carcinomatosis: A Cohort Study. *Anticancer Res*. 2015 Dec;35(12):6723-9.
527 doi: 10.1055/s-0035-1560004. PMID: 26637888.
- 528 5. Tavernier C, Passot G, Vassal O, Allaouchiche B, Decullier E, Bakrin N, Alyami M,
529 Davigo A, Bonnet JM, Louzier V, Paquet C, Glehen O, Kepenekian V. Pressurized
530 intraperitoneal aerosol chemotherapy (PIPAC) might increase the risk of anastomotic
531 leakage compared to HIPEC: an experimental study. *Surg Endosc*. 2020 Jul;34(7):2939-
532 2946. doi: 10.1007/s00464-019-07076-3. Epub 2019 Aug 27. PMID: 31456025.
- 533 6. Davigo A, Passot G, Vassal O, Bost M, Tavernier C, Decullier E, Bakrin N, Alyami M,
534 Bonnet JM, Louzier V, Paquet C, Allaouchiche B, Glehen O, Kepenekian V. PIPAC
535 versus HIPEC: cisplatin spatial distribution and diffusion in a swine model. *Int J*
536 *Hyperthermia*. 2020;37(1):144-150. doi: 10.1080/02656736.2019.1704891. PMID:
537 32003300.
- 538 7. Graversen M, Rouvelas I, Ainsworth AP, Bjarnesen AP, Detlefsen S, Ellebaek SB,
539 Fristrup CW, Liljefors MG, Lundell L, Nilsson M, Pfeiffer P, Tarpgaard LS, Tsekrekos A,
540 Mortensen MB. Feasibility and Safety of Laparoscopic D2 Gastrectomy in Combination
541 with Pressurized Intraperitoneal Aerosol Chemotherapy (PIPAC) in Patients with Gastric
542 Cancer at High Risk of Recurrence-The PIPAC-OPC4 Study. *Ann Surg Oncol*. 2023 Mar
543 3. doi: 10.1245/s10434-023-13278-w. Epub ahead of print. PMID: 36867174.
- 544 8. Braet H, Andretto V, Mariën R, Yücesan B, van der Vegte S, Haegebaert R, Lollo G, De
545 Smedt SC, Remaut K. The effect of electrostatic high pressure nebulization on the
546 stability, activity and ex vivo distribution of ionic self-assembled nanomedicines. *Acta*
547 *Biomater*. 2023 Oct 15;170:318-329. doi: 10.1016/j.actbio.2023.08.027. Epub 2023 Aug
548 19. PMID: 37598790.
- 549 9. Göhler D, Oelschlägel K, Ouaiissi M, Giger-Pabst U. Performance of different nebulizers
550 in clinical use for Pressurized Intraperitoneal Aerosol Chemotherapy (PIPAC). *medRxiv*
551 2023.03.24.23287646; doi: <https://doi.org/10.1101/2023.03.24.23287646>
552

- 553 10. Kim G, Tan HL, Sundar R, Lieske B, Chee CE, Ho J, Shabbir A, Babak MV, Ang WH,
554 Goh BC, Yong WP, Wang L, So JBY. PIPAC-OX: A Phase I Study of Oxaliplatin-Based
555 Pressurized Intraperitoneal Aerosol Chemotherapy in Patients with Peritoneal Metastases.
556 Clin Cancer Res. 2021 Apr 1;27(7):1875-1881. doi: 10.1158/1078-0432.CCR-20-2152.
557 Epub 2020 Nov 4. PMID: 33148667.
- 558 11. Robella M, De Simone M, Berchiolla P, Argenziano M, Borsano A, Ansari S, Abollino O,
559 Ficiarà E, Cinquegrana A, Cavalli R, Vaira M. A Phase I Dose Escalation Study of
560 Oxaliplatin, Cisplatin and Doxorubicin Applied as PIPAC in Patients with Peritoneal
561 Carcinomatosis. Cancers (Basel). 2021 Mar 3;13(5):1060. doi: 10.3390/cancers13051060.
562 PMID: 33802269; PMCID: PMC7958944.
- 563 12. Ramos Arias G, Sindayigaya R, Ouaiissi M, Buggisch JR, Schmeding M, Giger-Pabst U,
564 Zieren J. Safety and Feasibility of High-Pressure/High-Dose Pressurized Intraperitoneal
565 Aerosol Chemotherapy (HP/HD-PIPAC) for Primary and Metastatic Peritoneal Surface
566 Malignancies. Ann Surg Oncol. 2022 Nov 18. doi: 10.1245/s10434-022-12698-4. Epub
567 ahead of print. PMID: 36400887.
- 568 13. Du Bois, D. and Du Bois, E.F. A Formula to Estimate the Approximate Surface Area if
569 Height and Weight Be Known. Archives of Internal Medicine. 1916;17, 863-871.
570 <http://dx.doi.org/10.1001/archinte.1916.00080130010002>
- 571 14. ISO (International Standardisation Organisation). 2020. ISO 10993-18:2020. Biological
572 evaluation of medical devices. Part 18: Chemical characterization of medical device
573 materials within a risk management process
- 574 15. ISO (International Standardisation Organisation).ISO 10993-17:2023. Biological
575 evaluation of medical devices. Part 17: Toxicological risk assessment of medical device
576 constituents
- 577 16. Giger-Pabst U, Tempfer CB. How to Perform Safe and Technically Optimized Pressurized
578 Intraperitoneal Aerosol Chemotherapy (PIPAC): Experience After a Consecutive Series of
579 1200 Procedures. Journal of Gastrointestinal Surgery: Official Journal of the Society for
580 Surgery of the Alimentary Tract. 2018 Dec;22(12):2187-2193.
- 581 17. Solass W, Giger-Pabst U, Zieren J, Reymond MA. Pressurized intraperitoneal aerosol
582 chemotherapy (PIPAC): occupational health and safety aspects. Ann Surg Oncol. 2013
583 Oct;20(11):3504-11. doi: 10.1245/s10434-013-3039-x. Epub 2013 Jun 14. PMID:
584 23765417; PMCID: PMC3764316.
- 585 18. Gena AW, Voelker C, Settles GS. Qualitative and quantitative schlieren optical
586 measurement of the human thermal plume. Indoor Air. 2020;30:757-766.
587 <https://doi.org/10.1111/ina.12674>
- 588 19. Alsaad H, Schälte G, Schneeweiß M, Becher L, Pollack M, Gena AW, Schweiker M,
589 Hartmann M, Voelker C, Rossaint R, et al. The Spread of Exhaled Air and Aerosols
590 during Physical Exercise. Journal of Clinical Medicine. 2023; 12(4):1300.
591 <https://doi.org/10.3390/jcm12041300>
- 592 20. Dellweg D, Kerl J, Gena AW, Alsaad H, Voelker C. Exhalation Spreading During Nasal
593 High-Flow Therapy at Different Flow Rates. Crit Care Med. 2021 Jul 1;49(7):e693-e700.
594 doi: 10.1097/CCM.0000000000005009. PMID: 34135285; PMCID: PMC8204857.
- 595 21. Meyers MA. Peritoneography: Normal and Pathologic Anatomy. In: Dynamic Radiology
596 of the Abdomen. Springer, New York, NY. 1976; ISBN: 978-1-4757-3957-2

- 597 22. Dindo D, Demartines N, Clavien PA. Classification of surgical complications: a new
598 proposal with evaluation in a cohort of 6336 patients and results of a survey. *Ann Surg.*
599 2004 Aug;240(2):205-13. doi: 10.1097/01.sla.0000133083.54934.ae. PMID: 15273542;
600 PMCID: PMC1360123.
- 601 23. Clavien PA, Barkun J, de Oliveira ML, Vauthey JN, Dindo D, Schulick RD, de
602 Santibañes E, Pekolj J, Slankamenac K, Bassi C, Graf R, Vonlanthen R, Padbury R,
603 Cameron JL, Makuuchi M. The Clavien-Dindo classification of surgical complications:
604 five-year experience. *Ann Surg.* 2009 Aug;250(2):187-96. doi:
605 10.1097/SLA.0b013e3181b13ca2. PMID: 19638912.
- 606 24. Khosrawipour V, Khosrawipour T, Diaz-Carballo D, Förster E, Zieren J, Giger-Pabst U.
607 Exploring the Spatial Drug Distribution Pattern of Pressurized Intraperitoneal Aerosol
608 Chemotherapy (PIPAC). *Ann Surg Oncol.* 2016 Apr;23(4):1220-4. doi: 10.1245/s10434-
609 015-4954-9. Epub 2015 Nov 9. PMID: 26553440.
- 610 25. Davigo A, Passot G, Vassal O, Bost M, Tavernier C, Decullier E, Bakrin N, Alyami M,
611 Bonnet JM, Louzier V, Paquet C, Allaouchiche B, Glehen O, Kepenekian V. PIPAC
612 versus HIPEC: cisplatin spatial distribution and diffusion in a swine model. *Int J*
613 *Hyperthermia.* 2020;37(1):144-150. doi: 10.1080/02656736.2019.1704891. PMID:
614 32003300.
- 615 26. Giger-Pabst U, Bucur P, Roger S, Falkenstein TA, Tabchouri N, Le Pape A, Lerondel S,
616 Demtröder C, Salamé E, Ouaisi M. Comparison of Tissue and Blood Concentrations of
617 Oxaliplatin Administered by Different Modalities of Intraperitoneal Chemotherapy. *Ann*
618 *Surg Oncol.* 2019 Dec;26(13):4445-4451. doi: 10.1245/s10434-019-07695-z. Epub 2019
619 Aug 9. PMID: 31399820.
- 620 27. Bellendorf A, Khosrawipour V, Khosrawipour T, Siebigtheroth S, Cohnen J, Diaz-Carballo
621 D, Bockisch A, Zieren J, Giger-Pabst U. Scintigraphic peritoneography reveals a non-
622 uniform 99mTc-Pertechnetat aerosol distribution pattern for Pressurized Intra-Peritoneal
623 Aerosol Chemotherapy (PIPAC) in a swine model. *Surg Endosc.* 2018 Jan;32(1):166-174.
624 doi: 10.1007/s00464-017-5652-4. Epub 2017 Jun 22. PMID: 28643076.
- 625 28. Dedrick RL, Flessner MF. Pharmacokinetic problems in peritoneal drug administration:
626 tissue penetration and surface exposure. *J Natl Cancer Inst.* 1997 Apr 2;89(7):480-7. doi:
627 10.1093/jnci/89.7.480. PMID: 9086004.
- 628 29. Khosrawipour V, Khosrawipour T, Falkenstein TA, Diaz-Carballo D, Förster E, Osma A,
629 Adamietz IA, Zieren J, Fakhrian K. Evaluating the Effect of Micropump[®] Position,
630 Internal Pressure and Doxorubicin Dosage on Efficacy of Pressurized Intra-peritoneal
631 Aerosol Chemotherapy (PIPAC) in an Ex Vivo Model. *Anticancer Res.* 2016
632 Sep;36(9):4595-600. doi: 10.21873/anticancer.11008. PMID: 27630300.
- 633 30. Piao J, Park SJ, Lee H, Kim J, Park S, Lee N, Kim SI, Lee M, Song G, Lee JC, Kim HS;
634 KORIA TRIAL GROUP. Ideal Nozzle Position During Pressurized Intraperitoneal
635 Aerosol Chemotherapy in an Ex Vivo Model. *Anticancer Res.* 2021 Nov;41(11):5489-
636 5498. doi: 10.21873/anticancer.15362. PMID: 34732419.
- 637 31. Mun J, Park SJ, Kim HS. Rotational intraperitoneal pressurized aerosol chemotherapy in a
638 porcine model. *Gland Surg.* 2021 Mar;10(3):1271-1275. doi: 10.21037/gs-2019-ursoc-11.
639 PMID: 33842275; PMCID: PMC8033043.

Kockelmann et al. – V4_AW_HA (1)

- 640 32. Park SJ, Lee EJ, Lee HS, Kim J, Park S, Ham J, Mun J, Paik H, Lim H, Seol A, Yim GW,
641 Shim SH, Kang BC, Chang SJ, Lim W, Song G, Kim JW, Lee N, Park JW, Lee JC, Kim
642 HS; KoRIA* trial group. Development of rotational intraperitoneal pressurized aerosol
643 chemotherapy to enhance drug delivery into the peritoneum. *Drug Deliv.* 2021
644 Dec;28(1):1179-1187. doi: 10.1080/10717544.2021.1937382. PMID: 34121568; PMCID:
645 PMC8204987.
- 646 33. Braet H, Andretto V, Mariën R, Yücesan B, van der Vegte S, Haegebaert R, Lollo G, De
647 Smedt SC, Remaut K. The effect of electrostatic high-pressure nebulization on the
648 stability, activity and ex vivo distribution of ionic self-assembled nanomedicines. *Acta*
649 *Biomater.* 2023 Aug 19:S1742-7061(23)00492-0. doi: 10.1016/j.actbio.2023.08.027. Epub
650 ahead of print. PMID: 37598790.
- 651 34. Eveno C, Jouvin I, Pocard M. PIPAC EstoK 01: Pressurized IntraPeritoneal Aerosol
652 Chemotherapy with cisplatin and doxorubicin (PIPAC C/D) in gastric peritoneal
653 metastasis: a randomized and multicenter phase II study. *Pleura Peritoneum.* 2018 Jun
654 21;3(2):20180116. doi: 10.1515/pp-2018-0116. PMID: 30911659; PMCID:
655 PMC6405009.
- 656 35. Mortensen MB, Glehen O, Horvath P, Hübner M, Hyung-Ho K, Königsrainer A, Pocard
657 M, Reymond MA, So J, Frstrup CW. The ISSPP PIPAC database: design, process,
658 access, and first interim analysis. *Pleura Peritoneum.* 2021 Apr 22;6(3):91-97. doi:
659 10.1515/pp-2021-0108. PMID: 34676282; PMCID: PMC8482445.

660 **Figures and Tables**

661 **Table 1:** Toxicological analyses after nebulization of chemotherapy with the MDN

Methods of Analysis	Doxorubicin + Cisplatin	Oxaliplatin
HSGC-MS analysis for Volatile Organic Compounds	Not detected	Not detected
GC-MS analysis for Semi-Volatile Organic Compounds		
- 1, 6, 11, 16-Tetraoxacycloeicosane	Not detected	0.03 µg/ml
- 1, 6, 11, 16, 21-Pentaoxacyclopentacosane	Not detected	0.04 µg/ml
LC-MS analysis for Non-Volatile Organic Compounds		
- Cyclic polybutylene glycol (C20)	0.144 µg/ml	0.131 µg/ml
- Cyclic polybutylene glycol (C24)	0.246 µg/ml	0.123 µg/ml
- Cyclic polybutylene glycol (C32)	0.083 µg/ml	0.045 µg/ml
ICP-MS analysis for inorganic elements		
- Copper	0.049 µg/ml	Not detected
- Ferrum	0.057 µg/ml	0.011 µg/ml
- Manganese	0.015 µg/ml	0.014 µg/ml
IC analysis for anions		
- Acetates	Not detected	Not detected
- Fluorides	Not detected	Not detected
- Chlorides	Not detected	Not detected
- Bromides	Not detected	Not detected
- Nitrites	Not detected	Not detected
- Nitrates	Not detected	Not detected
- Sulfates	Not detected	Not detected
- Phosphates	Not detected	Not detected

662

663 *Legend: HSGC-MS = Head-space Gas Chromatography coupled with Mass Spectrometry;*
 664 *GC-MS = Gas Chromatography coupled with Mass Spectrometry; LC-MS = Liquid phase*
 665 *chromatography coupled to a Mass Spectrometer; ICP-OES = Inductively Coupled Plasma*
 666 *Atomic Emission Spectrometry; IC = Ion Chromatography;*

667

668


Variables	Total population (n = 21)
Age at first MDN-PIPAC (mean (range) in years)	62 (38-86)
Primary origin (n)	
- Colo-Rectal	3
- UGI	6
- HPB	3
- MPM	2
- Ovarian	4
- Other	3
ECOG (n)	
- 0	5
- 1	16
Synchronous PSM (n)	10
Prior primary tumor resection (n)	17
Prior systemic chemotherapy lines (median (range))	2 (1-5)
Prior standard PIPAC applications before MDP-PIPAC (median (range))	1 (1-4)
Ongoing systemic chemotherapy between MDN-PIPAC procedures (n)	14
The time between primary and metachronous PSM diagnosis (mean (range) in months)	21 (2-56)

669 **Table 2:** Baseline clinical characteristics of the patients with MDN-PIPAC

670 *Legend: PIPAC = pressurized intraperitoneal aerosol chemotherapy; MDN = multi-*
 671 *directional nebulizer; UGI = upper gastrointestinal; HPB = hepato- biliary tract; ECOG =*
 672 *Eastern Cooperative Oncology Group performance status; PSM = peritoneal surface*
 673 *malignancy*

674


675 **Figure 1:** The schlieren imaging system at the Bauhaus-University Weimar



676

677

678 **Figure 2:** Test setup for schlieren imaging during ex-vivo MDN-PIPAC simulations




679

680

681

682 **Figure 3:** Ex-vivo evaluation of the optimal position of the MDN in the 12-mm trocar

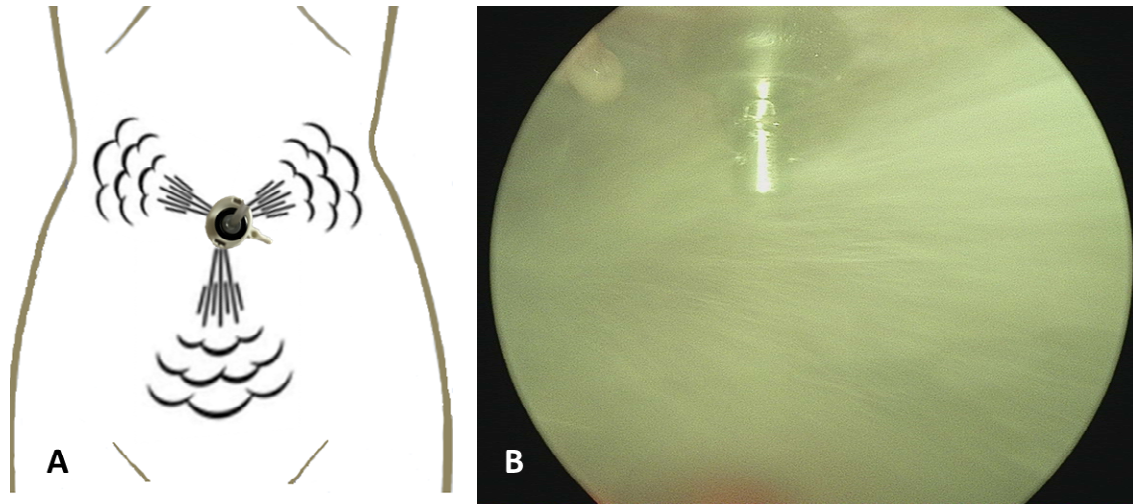


683

684 *Legend: A = MDN inserted into a 12 mm balloon trocar. The position of the MDN head must*
685 *be checked visually so that the lateral nozzles do not nebulize into the trocar. The white*
686 *triangles mark the distal end of the trocar. Note that the trocar is angled 15° at the distal end.*
687 *The black arrows point to the horizontal nozzle openings. These should protrude at least 7*
688 *mm beyond the most distal end of the trocar (left white arrow). B = MDN inserted into a 12*
689 *mm balloon trocar. The black arrow points to the sterile rubber ring pulled over the nebulizer*
690 *shaft which rests on the trocar head to prevent the nebulizer from gliding into the trocar.*


691

692 **Figure 4:** Periumbilical position of the MDN for optimized nebulization



694 *Legend: A = Sketch of infraumbilical position of the MDN for optimized nebulization of all*
695 *four nozzles (only horizontal nozzles shown); B = intraoperative view on the MDN head*

697 **Figure 5:** Schlieren imaging of different scenarios of MDN-PIPAC simulation

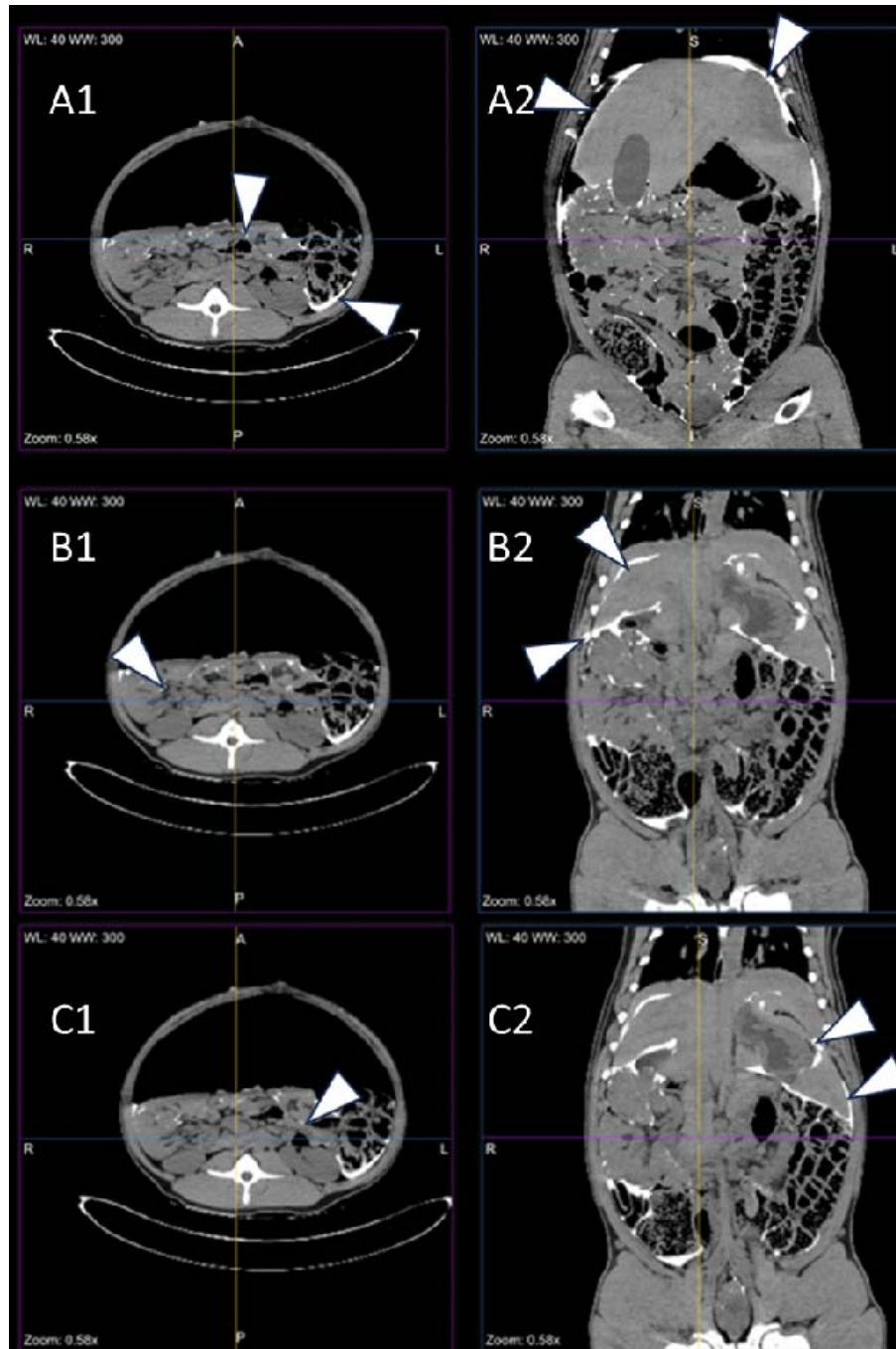


698

699 *Legend: A = a test schlieren image to demonstrate the visualization of CO₂ leakage; B =*
700 *schlieren visualization of 12 mmHg injection at 1.3 ml/s with a 50 ml of distilled water*

701

702 **Figure 6:** Representative MDN-PIPAC CT-peritoneography images of pig N° 1



703

704 *Legend: A1-C1 = horizontal section planes; A2-C2 = coronal section planes. The white*
705 *triangles point to the contrast agent accumulation: A1-C1 = enter-enteric and paracolic left;*
706 *A2 = subdiaphragmatic bilateral; B2 = homogeneous on the Glisson capsule, subhepatic and*
707 *interlobar; C2 = perigastric and perilienal*

708