

# **Intravascular Imaging-Guided Versus Angiography-Guided PCI:**

## **Systematic Review and Meta-analysis of 24 Randomized Controlled Trials**

David Hong, MD<sup>1\*</sup>, Woochan Kwon, MD<sup>1\*</sup>, Seung Hun Lee, MD, PhD<sup>2†</sup>, Doosup Shin, MD<sup>3</sup>,  
Hyun Kuk Kim, MD, PhD<sup>4</sup>, Kwan Yong Lee, MD, PhD<sup>5</sup>, Eun Ho Choo, MD, PhD<sup>5</sup>, Sung Eun  
Kim, MD<sup>6</sup>, Young Joon Hong, MD, PhD<sup>2</sup>, Young Keun Ahn, MD, PhD<sup>2</sup>, Myung Ho Jeong,  
MD, PhD<sup>2</sup>, Junho Ha, MD<sup>1</sup>, Minseok Hong, MD<sup>1</sup>, Ki Hong Choi, MD, PhD<sup>1</sup>, Taek Kyu Park,  
MD, PhD<sup>1</sup>, Jeong Hoon Yang, MD, PhD<sup>1</sup>, Young Bin Song, MD, PhD<sup>1</sup>, Joo-Yong Hahn, MD,  
PhD<sup>1</sup>, Seung-Hyuk Choi, MD, PhD<sup>1</sup>, Hyeon-Cheol Gwon, MD, PhD<sup>1</sup>, Joo Myung Lee, MD,  
MPH, PhD<sup>1†</sup>, The RENOVATE COMPLEX-PCI Investigators

\* DH and WK contributed equally as the first authors.

† SHL and JML contributed equally as the corresponding authors.

<sup>1</sup>Samsung Medical Center, Sungkyunkwan University School of Medicine, Seoul, Korea;

<sup>2</sup>Department of Internal Medicine and Cardiovascular Center, Chonnam National University

Hospital, Gwangju, Korea; <sup>3</sup>Division of Cardiology, Department of Internal Medicine, Duke

University Medical Center, Durham, NC, USA; <sup>4</sup>Department of Internal Medicine and

Cardiovascular Center, Chosun University Hospital, University of Chosun College of Medicine,

Gwangju, Korea; <sup>5</sup>Seoul St. Mary's Hospital, The Catholic University of Korea, Seoul, Korea;

<sup>6</sup>Department of Medicine, Inje University Ilsan Paik Hospital, Goyang, Korea.

**Running title:** A Meta-analysis of Intravascular Imaging-Guided PCI

**NOTE:** This preprint reports new research that has not been certified by peer review and should not be used to guide clinical practice.

1

2 **Word count:**

3 Manuscript – 3,584 (not including abstract, tables, figures, acknowledgments, references, and  
4 online-only material)

5 Number of Tables and Figures – 1/5

6

7 **Address for correspondence:**

8 Seung Hun Lee, MD, PhD

9 Division of Cardiology, Department of Internal Medicine, Chonnam National University

10 Hospital, Chonnam National University Medical School, 42, Jebong-ro, Dong-gu, Gwangju

11 61469, Republic of Korea

12 Tel; 82-10-6413-7449, Fax; 82-2-6455-1449

13 E-mail; lsh8602@naver.com, gfmaniac@gmail.com

14

15 Joo Myung Lee, MD, MPH, PhD

16 Department of Internal Medicine and Cardiovascular Center,

17 Heart Vascular Stroke Institute, Samsung Medical Center,

18 50, Irwon-dong, Gangnam-gu, Seoul 135–710, Republic of Korea

19 Telephone: 82-2-3410-3391; Fax: 82-2-3410-6278

20 E-mail: drone80@hanmail.net, joomyung.lee@samsung.com

1 **Abstract**

2 **Objective:** To evaluate comparative prognosis between intravascular imaging-guided PCI and  
3 angiography-guided PCI using a comprehensive meta-analysis including all previous  
4 randomized controlled trials.

5 **Design:** Systematic review and meta-analysis of randomized controlled trials.

6 **Data Sources:** Target trials were selected by a systematic electronic search strategy in the  
7 PubMed, EMBASE, and Cochrane databases from their inception to Sep, 2023.

8 **Study Selection:** Published randomized controlled trials which compared clinical outcomes  
9 between intravascular imaging-guided and angiography-guided PCI were included.

10 **Main Outcome and Measures:** Major adverse cardiac events (MACE), all-cause death,  
11 myocardial infarction (MI), target vessel revascularization (TVR), and stent thrombosis.

12 **Review Methods:** Random-effects model was used to calculate pooled relative risk (RR) and  
13 95% confidence interval (CI) between intravascular imaging-guided and angiography-guided  
14 PCI. Heterogeneity was assessed by  $I^2$  values.

15 **Results:** Among a total of 14,037 patients (7,383 in intravascular imaging-guided PCI and  
16 6,654 in angiography-guided PCI groups), intravascular imaging-guided PCI was associated  
17 with a lower risk of MACE than angiography-guided PCI (RR, 0.75; 95% CI, 0.67 to 0.84;  
18  $P<0.001$ ;  $I^2$ , 18.9%), driven by lower risk of MI (RR, 0.83; 95% CI, 0.70 to 0.97;  $P=0.019$ ;  $I^2$ ,  
19 0.0%), TVR (RR, 0.70; 95% CI, 0.61 to 0.79;  $P<0.001$ ;  $I^2$ , 0.0%), and stent thrombosis (RR,  
20 0.50; 95% CI, 0.32 to 0.78;  $P=0.002$ ;  $I^2$ , 0.0%). There was no difference in the risk of all-cause  
21 death (RR, 0.82; 95% CI, 0.67 to 1.01;  $P=0.068$ ;  $I^2$ , 0.0%), however, trials with 2<sup>nd</sup> generation  
22 drug-eluting stent (DES) showed significant reduction of all-cause death following  
23 intravascular imaging-guided PCI (RR, 0.77; 95% CI, 0.61 to 0.95;  $P=0.018$ ;  $I^2$ , 0.0%).

1 **Conclusions:** Compared to angiography-guided PCI, intravascular imaging-guided PCI was  
2 associated with a reduced the risk of MACE, by lowering the risks of MI, TVR, and stent  
3 thrombosis. Pooled analysis of trials with 2<sup>nd</sup> generation DES showed significantly lower risk  
4 of all-cause death following intravascular imaging-guided PCI than angiography-guided PCI.

5  
6 **Systematic Review Registration:** PROSPERO, CRD42023402677

7  
8 **Key Words:** Coronary artery disease; Percutaneous coronary intervention; Intravascular  
9 ultrasound; Optical coherence tomography; Meta-analysis.

## 1 **Summary Boxes**

### 2 **What is already known on this topic**

- 3 ● Due to limited sample size, previous randomized controlled trials (RCTs) were not  
4 able to show significant differences in the risks of hard clinical events such as death,  
5 myocardial infarction (MI), or stent thrombosis between intravascular imaging-  
6 guided percutaneous coronary intervention (PCI) and angiography-guided PCI.
- 7 ● Although previous meta-analyses showed that intravascular imaging-guided PCI  
8 resulted in a lower risk of death or MI than angiography-guided PCI, inclusion of both  
9 observational studies and RCTs caused heterogeneity and lowered the evidence level  
10 of the results.

### 11 **What this study adds**

- 12 ● The current meta-analysis exclusively included 24 RCTs and showed that  
13 intravascular imaging-guided PCI significantly reduced the risk of major adverse  
14 cardiac events (MACE), compared with angiography-guided PCI.
- 15 ● It should be noted that intravascular imaging-guided PCI reduced not only the risk of  
16 target-vessel revascularization but also the risks of hard clinical events such as MI  
17 and stent thrombosis.

1 **Abbreviations**

2 CI = confidence interval

3 DES = drug-eluting stent

4 IVUS = intravascular ultrasound

5 MACE = major adverse cardiac events

6 MI = myocardial infarction

7 OCT = optical coherence tomography

8 OR = odds ratio

9 PCI = percutaneous coronary intervention

10 RCT = randomized controlled trial

11 TVR = target vessel revascularization

12

## 1 **Introduction**

2 Percutaneous coronary intervention (PCI) is one of the important treatment options for  
3 patients with coronary artery stenosis. Despite improvement of drug-eluting stent (DES)  
4 platforms and PCI techniques, it is still unclear whether PCI can reduce death or myocardial  
5 infarction (MI) compared with guideline-directed medical treatment alone,<sup>1 2</sup> and PCI for  
6 complex coronary artery lesions is challenging in daily practice due to increased risk of stent  
7 failure.<sup>3-5</sup> Therefore, continuous efforts have been made to find how to guide and optimize PCI  
8 to improve clinical outcomes. In this regard, intravascular imaging using intravascular  
9 ultrasound (IVUS) and optical coherence tomography (OCT) would be useful by providing  
10 information on lesion characteristics, reference vessel size, stent expansion and apposition, and  
11 acute complications.<sup>6</sup>

12 Previous randomized controlled trials (RCTs) have shown lower rates of major adverse  
13 cardiac events (MACE) after intravascular imaging-guided PCI than after angiography-guided  
14 PCI,<sup>7-28</sup> although it mainly reduced the risk of repeat revascularization without significant  
15 difference in hard clinical events such as death, MI, or stent thrombosis. In contrast, the recently  
16 published RENOVATE-COMPLEX-PCI (Randomized Controlled Trial of Intravascular  
17 Imaging Guidance versus Angiography-Guidance on Clinical Outcomes After Complex  
18 Percutaneous Coronary Intervention) firstly demonstrated a superiority of intravascular  
19 imaging-guided PCI over angiography-guided PCI in patients with complex coronary artery  
20 lesions, mainly driven by reduced risk of cardiac death and MI with intravascular imaging  
21 guidance. The OCTOBER (European Trial on Optical Coherence Tomography Optimized  
22 Bifurcation Event Reduction) trial also showed the prognostic benefit of OCT-guided PCI over  
23 angiography-guided PCI in patients with complex bifurcation lesions.<sup>29</sup> Conversely, ILUMIEN  
24 IV (Optical Coherence Tomography [OCT] Guided Coronary Stent IMplantation Compared to

1 Angiography: a Multicenter Randomized Trial in PCI) failed to show significant difference in  
2 target vessel failure between the two strategies in patients with diabetes mellitus or complex  
3 coronary artery lesions.<sup>30</sup>

4 Therefore, we conducted an updated meta-analysis using all available RCTs to date to  
5 investigate whether intravascular imaging-guided PCI would improve clinical outcomes  
6 compared with angiography-guided PCI.

## 7 8 **Methods**

### 9 **Data Sources and Searches**

10 PubMed, EMBASE, Cochrane Central Register of Controlled Trials, the United States  
11 National Institutes of Health registry of clinical trials, and relevant websites were searched for  
12 pertinent published or unpublished studies from inception to September 2023. The electronic  
13 search strategy was complemented by manual examination of references cited by included  
14 articles, recent reviews, editorials, and meta-analyses. No restrictions were imposed on study  
15 period or sample size, but only articles in English were considered. Keywords included  
16 ‘intravascular ultrasound, ‘optical coherence tomography’, ‘PCI’, ‘percutaneous coronary  
17 intervention’, ‘coronary stenting’, ‘stenting’, ‘stent’, ‘stent implantation’, ‘angiography’, ‘impact’,  
18 ‘outcome’, ‘randomized’, and ‘randomized clinical trial’ (**Supplemental Table 1**). The present  
19 study complied with the Preferred Reporting Items for Systematic Reviews and Meta-Analyses  
20 (PRISMA) guidelines.<sup>31</sup> The study protocol was prespecified and registered with PROSPERO  
21 (CRD42023402677). Institutional Review Board (IRB) of Samsung Medical Center waived  
22 IRB approval process based on the study design, which is the study-level meta-analysis using  
23 published materials.

24



## 1 **Study Selection**

2           Studies were included if they met the following prespecified criteria: (1) RCTs  
3 comparing intravascular imaging-guided PCI versus angiography-guided PCI in patients with  
4 coronary artery disease; (2) clinical outcome assessment with follow-up duration of at least 1  
5 month; and (3) clinical outcomes including all-cause death, cardiac death, MI, target vessel  
6 revascularization (TVR), or stent thrombosis. Non-randomized studies, duplicated reports of  
7 previous RCTs, or post-hoc analysis including cost-effectiveness analysis of reported RCTs  
8 were not included (**Supplemental Table 2**). Two independent investigators (D.H. and W.K.)  
9 screened titles and abstracts, identified duplicates, performed full-article reviews, and  
10 determined inclusion. Two other investigators (S.H.L. and J.M.L.) supervised the search and  
11 adjudicated disagreements.

12

## 13 **Data Extraction and Quality Assessment**

14           Summary data as reported in the published manuscripts were analyzed. A standardized  
15 form was used to extract study characteristics; trial design; number of trial population; median  
16 follow-up duration; type of intravascular imaging devices; demographics; clinical and  
17 angiographic eligibility criteria, including clinical diagnosis and angiographic lesion  
18 characteristics; proportion of cardiovascular risk factors; and used stent types. The rates of all-  
19 cause mortality, MI, TVR, stent thrombosis, and MACE were collected, along with the  
20 definition of clinical events, as reported on an intention-to-treat basis. For trials which used  
21 both IVUS and OCT, group size and number of events were separately extracted, according to  
22 the type of intravascular imaging devices. In trials with available reports for both short- and  
23 long-term clinical outcomes, those with the longest follow-up duration were used in the current  
24 meta-analysis. In addition, unadjusted results of clinical events were used in the current meta-

1 analysis.

2           The quality of eligible trials was assessed using the Cochrane Collaborations tool  
3 Version 2 for assessing the risk of bias in RCTs regarding random sequence generation,  
4 allocation concealment, blinding of participants and outcome assessment, incomplete outcome  
5 assessment, or selective reporting. We did not exclude individual studies from the analysis  
6 based on the risk of bias in RCTs.

7

## 8 **Outcomes and Definitions**

9           The primary outcome was MACE at the longest available follow-up. Since the  
10 definition of MACE or composite outcomes varied across the trials, we used representative  
11 composite outcome reported under intention-to-treat principle in the included trials. The  
12 definition of MACE used in the included trials are presented in **Supplemental Table 3**. In most  
13 trials, MACE was a composite of all-cause death, MI, and TVR. Secondary outcomes included  
14 all-cause death, MI, TVR, and stent thrombosis.

15

## 16 **Data Synthesis and Analysis**

17           Primary and secondary outcomes were analyzed using random-effects models.  
18 Relative risks (RRs) with 95% confidence intervals (CIs) were presented as summary statistics.  
19 Because all included studies showed heterogeneity regarding study protocol and populations,  
20 fixed-effects models were only used for sensitivity analyses to check whether these models  
21 yielded similar results. The pooled RRs and 95% confidence intervals were calculated using  
22 the DerSimonian and Laird method for random effects, as well as the Mantel–Haenszel method  
23 for fixed effects. Because of progressive changes in primary study designs and clinical practice  
24 patterns, especially type of used stents (bare metal stent, 1<sup>st</sup> or 2<sup>nd</sup> generation DES), we

1 evaluated the impact of publication date on the overall effect of pooled RRs for the risk of  
2 MACE by a cumulative meta-analysis. Since all of the included trials in the cumulative meta-  
3 analysis had the same comparison groups, cumulative pooled effect estimates up to time point  
4 of last study inclusion could reflect temporal trends in effect size (RR). Statistical heterogeneity  
5 was quantified with the  $I^2$  statistics.  $I^2$  values <25%, 25% to 50%, and >50% indicate low,  
6 moderate, and high degrees of heterogeneity, respectively. Small study bias (publication bias)  
7 was assessed by funnel plot asymmetry and Egger's and Begg's tests; when visual asymmetry  
8 of funnel plot was suspected, the trim-and-fill method was used to estimate the number of  
9 missing studies and to calculate a corrected RR, as if these studies were present. The influence  
10 of an individual study was explored by estimating pooled RRs, with stepwise exclusion of one  
11 study.

12 Subgroup analyses were performed to determine whether effects differed across  
13 subgroups. These subgroups analyses were analyzed: (1) type of intravascular imaging devices  
14 (IVUS or OCT); (2) angiographic characteristics (all-comers population or patients with  
15 complex coronary artery disease); (3) type of complex coronary artery lesions (chronic total  
16 occlusion, left main disease, or diffuse long lesion); (4) type of used stents (bare metal stent,  
17 1<sup>st</sup> or 2<sup>nd</sup> generation DES); (5) clinical presentation (stable ischemic heart disease or acute  
18 coronary syndrome); and (6) presence of cardiovascular risk factors (diabetes mellitus or  
19 chronic kidney disease). Random-effects meta regression analysis was performed to evaluate  
20 differential effect size of intravascular imaging-guided PCI for MACE according to each  
21 subgroup. Two-sided P-values <0.05 were considered statistically significant. Statistical  
22 analysis was performed using STATA/SE 12.0 (Stata Corp LP, College Station, Texas, USA)  
23 and R programming language, version 4.2.2 (R Foundation for Statistical Computing, Vienna,  
24 Austria).

1  
2  
3  
4  
5  
6  
7  
8  
9  
10  
11  
12  
13  
14  
15  
16  
17  
18  
19  
20  
21  
22  
23  
24

## Results

### Included Trials and Patient Characteristics

Of a total of 809 searched articles, 38 were retrieved for full article review and 24 met prespecified inclusion criteria and were finally included (**Figure 1**). A total of 14,037 patients from 24 RCTs were included in the current meta-analysis. Among the total patients, 7,383 (52.6%) patients were treated with intravascular imaging-guided PCI and the remaining 6,654 (47.4%) patients were with angiography-guided PCI. The characteristics of the included trials are summarized in **Table 1**. The study population of 11 trials were all-comers without restriction by angiographic lesion characteristics and the remaining 13 trials exclusively enrolled patients with complex coronary artery lesions. Fifteen trials exclusively used IVUS, 6 trials exclusively used OCT, and the other 3 trials used both IVUS and OCT. 17 trials used 2<sup>nd</sup> generation DES and the other 7 trials used bare metal stent or 1<sup>st</sup> generation DES. The follow-up duration of each trial ranged from 6 months to 5 years and weighted median follow-up duration in the current meta-analysis was 2.0 years.

Regarding the quality of included trials, most trials were deemed to be at low risk of bias, although some criteria were unclearly described in few trials (**Supplemental Figure 1** and **Supplemental Table 4**). The characteristics of patients in the included trials are presented in **Supplemental Table 5**. Briefly, weighted mean age of the study population was 64.3 years and 75.6% were male. 64.8%, 30.5%, and 60.4% of the study population had hypertension, diabetes mellitus, and dyslipidemia, respectively. 55.7% of the study population presented with acute coronary syndrome. As only RCTs were included in the current study, baseline characteristics were balanced between intravascular imaging-guided PCI and angiography-guided PCI groups.

1

## 2 **Clinical Outcomes**

3           Among 14,037 patients from 24 RCTs, observed rates of MACE in pooled analysis  
4 were 9.1% and 12.4% at a weighted median follow-up of 2.0 years for intravascular imaging-  
5 guided PCI and angiography-guided PCI groups, respectively. In random-effects model,  
6 intravascular imaging-guided PCI was associated with a lower risk of MACE than  
7 angiography-guided PCI (RR, 0.75; 95% CI, 0.67 to 0.84;  $P<0.001$ ; heterogeneity  $I^2$ , 18.9%)  
8 (**Figure 2**). Number needed to treat to prevent one MACE was 33 (95% CI, 25 to 50). A fixed-  
9 effects model yielded similar results (RR, 0.75; 95% CI, 0.68 to 0.83;  $P<0.001$ ; heterogeneity  
10  $I^2$ , 18.9%). The lower risk of MACE in intravascular imaging-guided PCI was driven by  
11 significantly lower risks of MI (RR, 0.83; 95% CI, 0.70 to 0.97;  $P=0.019$ ; heterogeneity  $I^2$ ,  
12 0.0%) and TVR (RR, 0.70; 95% CI, 0.61 to 0.79;  $P<0.001$ ; heterogeneity  $I^2$ , 0.0%). Regarding  
13 stent thrombosis, observed rates were 0.5% and 1.2% at a weighted median follow-up of 2.0  
14 years for intravascular imaging-guided PCI and angiography-guided PCI groups, respectively  
15 (RR, 0.50; 95% CI, 0.32 to 0.78;  $P=0.002$ ; heterogeneity  $I^2$ , 0.0%). However, there was no  
16 difference in the risk of all-cause death between the 2 groups (RR, 0.82; 95% CI, 0.67 to 1.01;  
17  $P=0.068$ ; heterogeneity  $I^2$ , 0.0%) (**Figure 3**).

18           To assess the robustness and bias of the main results, additional analyses were  
19 performed. Fixed-effects models yielded consistent results with those from the random-effects  
20 models for MI, TVR, and stent thrombosis. In the cumulative meta-analysis to evaluate the  
21 temporal trend, intravascular imaging-guided PCI consistently showed a lower risk of MACE  
22 than angiography-guided PCI over time from 2000 to 2023 (**Supplemental Figure 2**). No  
23 individual study substantially influenced the pooled effect estimate for MACE (**Supplemental**  
24 **Figure 3**). Funnel plots, supported by Egger's and Begg's tests, indicated no small study bias

1 for MACE. The adjusted RRs for MACE by trim-and-fill method showed consistent results  
2 (RR, 0.75; 95% CI, 0.67 to 0.84; P<0.001) (**Supplemental Figure 4**).

3

#### 4 **Subgroup Analysis**

5 In subgroup analysis according to the all-comers population or patients with complex  
6 coronary artery lesions, intravascular imaging-guided PCI consistently showed a lower risk of  
7 MACE than angiography-guided PCI. However, the prognostic benefit of the intravascular  
8 imaging-guided PCI was relatively higher in patients treated by 2<sup>nd</sup> generation DES than  
9 previous types of stents (Interaction P value=0.014) (**Figure 4**). The prognostic benefit of  
10 intravascular imaging-guided PCI over angiography-guided PCI was consistently observed in  
11 both stable ischemic heart disease and acute coronary syndrome (**Supplemental Figure 5**).  
12 Other subgroup analyses also showed similar results (**Figure 4**). Although intravascular  
13 imaging-guided PCI marginally reduced the risk of all-cause death in overall meta-analysis,  
14 subgroup of the trials with 2<sup>nd</sup> generation DES showed significant reduction of all-cause death  
15 in intravascular imaging-guided PCI group than angiography-guided PCI group (RR, 0.77; 95%  
16 CI, 0.61 to 0.95; P=0.018; heterogeneity I<sup>2</sup>, 0.0%), which was not seen in the trials with bare  
17 metal stent or 1<sup>st</sup> generation DES (**Figure 5**).

18

#### 19 **Patient and Public Involvement**

20 No patient was involved in conceiving the research question, designing of the study,  
21 or interpreting the results.

22

#### 23 **Discussion**

24 The current updated meta-analysis compared clinical outcomes of intravascular

1 imaging-guided PCI versus angiography-guided PCI from 24 RCTs available to date. The  
2 major findings were as follows. (1) The intravascular imaging-guided PCI significantly  
3 reduced the risk of MACE, a composite of all-cause death, MI, or TVR, compared with  
4 angiography-guided PCI. (2) The intravascular imaging-guided PCI also significantly reduced  
5 MI, TVR, and stent thrombosis, compared with angiography-guided PCI. Although overall  
6 meta-analysis showed marginal effect of intravascular imaging-guided PCI regarding all-cause  
7 death, subgroup analysis of the trials with 2<sup>nd</sup> generation DES showed significantly reduced  
8 risk of all-cause death following intravascular imaging-guided PCI than angiography-guided  
9 PCI. (3) The prognostic benefit of intravascular imaging-guided PCI was consistently shown  
10 across various subgroups including complex coronary artery lesions and acute coronary  
11 syndrome.

12

### 13 **Current Status of Intravascular Imaging-Guided PCI**

14 Previous RCTs have reported that intravascular imaging-guided PCI reduced the risk  
15 of MACE compared with angiography-guided PCI, largely by lowering the risk of repeat  
16 revascularization.<sup>12-14 32</sup> However, those RCTs have not been considered to be definitive due to  
17 limited sample size or inclusion of highly selected coronary lesion subsets. In this regard,  
18 current practice guidelines recommend the use of intravascular imaging-guided PCI as Class  
19 IIa.<sup>1 2</sup> Furthermore, penetration rate of intravascular imaging in daily practice has been low,  
20 although it varies across different healthcare systems or clinical indications of PCI. For  
21 example, it was approximately 7.0-9.3% in the United States<sup>33 34</sup> and 27.5-28.6% in South  
22 Korea.<sup>35</sup>

23

### 24 **Prognostic Impact of Intravascular Imaging-Guided PCI**

1           Since most RCTs had only modest sample sizes to establish clinical benefit of  
2 intravascular imaging-guided PCI in terms of hard clinical events such as death, MI, or stent  
3 thrombosis, a few observational studies assessed a larger number of patients and showed that  
4 intravascular imaging-guided PCI resulted in a lower risk of death or MI than angiography-  
5 guided PCI.<sup>33-38</sup> Although previous meta-analyses presented similar results,<sup>39-40</sup> inclusion of  
6 both observational studies and RCTs would have caused heterogeneity and lowered the  
7 evidence level of the results. Recently, 3 large scaled RCTs have been published and showed  
8 conflicting results regarding the prognostic benefit of intravascular imaging-guided PCI.<sup>29-30-41</sup>  
9 The RENOVATE-COMPLEX-PCI trial evaluated 1,639 patients with complex coronary artery  
10 lesions and firstly showed a superiority of imaging-guided PCI using IVUS or OCT over  
11 angiography-guided PCI in reducing the hard clinical end point including cardiac death and MI  
12 at a median follow-up of 2.1 years (7.7% vs. 12.3%, respectively; HR, 0.64; 95% CI, 0.45-0.89;  
13 P=0.008).<sup>41</sup> Subsequent OCTOBER trial showed that OCT-guided PCI significantly reduced  
14 the risk of target vessel failure at 2 years than angiography-guided PCI in patients with complex  
15 bifurcation lesions (10.1% vs. 14.1%, respectively; HR, 0.70; 95% CI, 0.50-0.98; P=0.035).<sup>29</sup>  
16 Conversely, ILUMIEN IV trial failed to show significant prognostic benefit of OCT-guided  
17 PCI than angiography-guided PCI in patients with diabetes mellitus or complex coronary artery  
18 lesions at 2 years (7.4% vs. 8.2%, respectively; HR, 0.90; 95% CI, 0.67-1.19; P=0.45).<sup>30</sup>

19           The current meta-analysis was performed to clarify whether intravascular imaging-  
20 guided PCI would have prognostic benefit over angiography-guided PCI, especially for hard  
21 clinical events such as all-cause death, MI, or stent thrombosis. Compared with previous meta-  
22 analyses,<sup>39-40</sup> the current study included only RCTs and evaluated the largest number of  
23 randomized patients. Similar to the prior results, intravascular imaging-guided PCI was  
24 associated with a lower risk of MACE compared with angiography-guided PCI among all-



1 comers and patients with complex coronary artery lesions. The results suggested that  
2 intravascular imaging-guided PCI would prevent 1 MACE event in every 33 patients  
3 undergoing PCI. Importantly, it should be noted that intravascular imaging-guided PCI reduced  
4 not only the risk of TVR but also the risks of hard clinical events such as MI and stent  
5 thrombosis. The  $I^2$  values for all clinical outcomes evaluated in the current study were less than  
6 25%, indicating low heterogeneity among the included trials. Conversely, there was no  
7 significant difference in the risk of all-cause mortality between the 2 groups in meta-analysis  
8 of overall trials. However, it should be noted that pooled analysis of the trials with 2<sup>nd</sup>  
9 generation DES showed significantly reduced risk of all-cause death following intravascular  
10 imaging-guided PCI than angiography-guided PCI. Considering that bare metal stent or 1<sup>st</sup>  
11 generation DES are no longer used in contemporary PCI and that the risks of MI and stent  
12 thrombosis significantly reduced following intravascular imaging-guided PCI, it would be  
13 reasonable to accept survival benefit of intravascular imaging-guided PCI in contemporary  
14 practice. Currently ongoing trials will evaluate IVUS-guided PCI in all-comers with complex  
15 coronary artery lesions (IMPROVE [NCT04221815] and IVUS-CHIP [NCT04854070]) or  
16 unprotected left main disease (OPTIMAL [NCT04111770] and DKCRUSH-VIII  
17 [NCT03770650]), or OCT-guided PCI (OCCUPI [NCT03625908]), and these trials will  
18 provide additional information on the benefit of intravascular imaging-guided PCI, especially  
19 regarding the risk of death after PCI.

20

## 21 **Future Perspectives of Intravascular Imaging-Guided PCI**

22 In the current study, the treatment effect of intravascular imaging-guided PCI was  
23 consistent regardless of clinical presentation, cardiovascular comorbidities, type of used stents,  
24 and presence of complex coronary lesions. However, it should be noted that the effect size of

1 the intravascular imaging-guided PCI for the risk of MACE was relatively higher in patients  
2 with complex coronary artery lesions. These results were in line with the current guidelines  
3 which recommend the use of intravascular imaging-guided PCI mainly for complex coronary  
4 artery lesions.<sup>1 2</sup> With emerging evidences, further discussion is needed in interventional  
5 societies and guidelines committees as to whether intravascular imaging-guided PCI should be  
6 upgraded to Class I recommendation for complex coronary artery lesions. As shown in the  
7 subgroup analysis, among complex coronary artery lesions, more evidence from RCTs has been  
8 accumulated in chronic total occlusion, left main disease, and diffuse long lesion than other  
9 complex coronary artery lesions. Integration of ongoing trials and in-depth discussion are also  
10 needed to adequately define the complex coronary artery lesion that may benefit the most from  
11 intravascular imaging-guided PCI. In addition, it should not be underestimated that  
12 intravascular imaging-guided PCI also reduced the risk of MACE in all-comers. Concurrently,  
13 efforts should be made to standardize intravascular imaging optimization criteria that are  
14 practical, feasible, and prognostically well-validated. Considering low penetration rates of  
15 intravascular imaging in daily practice, more efforts need to be made to increase awareness and  
16 educate and support practicing interventional cardiologists.<sup>42</sup> Furthermore, cost-effectiveness  
17 of intravascular imaging-guided PCI should be clarified to help increase its penetration rate in  
18 daily practice.

19 In the current meta-analysis, intravascular imaging-guided PCI significantly reduced  
20 the risk of MACE in both stable ischemic heart disease and acute coronary syndrome patients.  
21 However, there has been limited evidence from RCT regarding the role of intravascular  
22 imaging-guided PCI in acute coronary syndrome. Similarly, there have only been a few RCTs  
23 comparing the clinical benefit of OCT-guided PCI over angiography-guided PCI and recent  
24 two large scaled trials (ILUMIEN IV and OCTOBER) showed conflicting results.<sup>29 30</sup> To date,

1 supporting evidence for OCT-guided PCI was mostly derived from RCTs which showed  
2 comparable clinical outcomes between IVUS- and OCT-guided PCI.<sup>20 21 43 44</sup> Similarly,  
3 subgroup analysis of the current study demonstrated no significant interaction according to the  
4 type of intravascular imaging devices, suggesting similar treatment effect between IVUS- and  
5 OCT-guided PCI. These results are in line with the recently published OCTIVUS trial which  
6 showed comparable clinical outcomes between IVUS-and OCT-guided PCI.<sup>44</sup> Currently  
7 ongoing OCCUPI (NCT03625908) trial will test the potential superiority of OCT-guided PCI  
8 over angiography-guided PCI. Furthermore, since those trials are enrolling both stable ischemic  
9 heart disease and acute coronary syndrome patients, their results will further enrich the  
10 evidence supporting the value of intravascular imaging-guided PCI.

11

## 12 **Limitations**

13 Some limitations should be acknowledged. First, this meta-analysis included clinically  
14 and methodologically diverse studies. Although we included only RCTs to the final analysis  
15 and got insignificant statistical inconsistency or heterogeneity, there were some differences in  
16 the study design including the enrollment criteria, type of stent used, type of intravascular  
17 imaging devices and procedural optimization criteria, follow-up protocols, and adjunctive  
18 pharmacotherapy after PCI. Second, the included trials were conducted from 2000 to 2023 and  
19 significant changes in practice patterns such as stent technology, PCI technique, and  
20 pharmacotherapy should be considered to interpret the results. However, the results from the  
21 cumulative meta-analysis imply that treatment effect of intravascular imaging-guided PCI was  
22 consistent over 20 years of period. Third, as this is a study-level meta-analysis, data of the  
23 individual patients were not included in the analysis, and therefore, we could not adjust for  
24 patient-level confounders especially the differences in target lesion complexity. Fourth, this

1 meta-analysis basically composed of 24 RCTs inherently shares the limitations of each trial.  
2 Fifth, we did not use Google Scholar or Web of Science in the initial search strategies, and  
3 some RCTs were added manually. However, same 24 RCTs were selected even after including  
4 these databases in search strategies and the current meta-analysis included the largest number  
5 of RCTs than previously conducted meta-analyses. Sixth, as current study included only a small  
6 number of patients with ST-segment elevation MI, caution is needed to extrapolate the results  
7 to patients with ST-segment elevation MI.

8

## 9 **Conclusion**

10 Compared to angiography-guided PCI, intravascular imaging-guided PCI was  
11 associated with a reduced the risk of MACE by lowering the risk of MI, TVR, and stent  
12 thrombosis. Pooled analysis of trials with 2<sup>nd</sup> generation DES showed significantly lower risk  
13 of all-cause death following intravascular imaging-guided PCI than angiography-guided PCI.

1 **Acknowledgment:** None.

2

3 **Contributors**

4 DH contributed to conception and design of the work, acquisition, analysis,  
5 interpretation of data for the work, drafting of the manuscript. WK contributed to acquisition,  
6 analysis, and interpretation of data for the work. SHL contributed to the conception of data for  
7 the work, interpretation of data for the work, and critical revision of the manuscript. JML  
8 contributed to the conception and design conception and design of the work, acquisition,  
9 analysis, interpretation of data for the work, and drafting of the manuscript. All other authors  
10 contributed to interpretation of data for the work, and critical revision of the manuscript. All  
11 authors approved the final version to be published. The guarantors (DH, WK, and JML) accept  
12 full responsibility for the work and/or the conduct of the study, had access to the data, and  
13 controlled the decision to publish. The corresponding authors (SHL and JML) attest that all  
14 listed authors meet authorship criteria and that no others meeting the criteria have been omitted.

15

16 **Funding:** None

17

18 **Competing interests**

19 Dr. Joo Myung Lee received an Institutional Research Grant from Abbott Vascular,  
20 Boston Scientific, Philips Volcano, Terumo Corporation, Zoll Medical, and Donga-ST. Prof.  
21 Joo-Yong Hahn received an Institutional Research Grant from National Evidence-based  
22 Healthcare Collaborating Agency, Ministry of Health & Welfare, Korea, Abbott Vascular,  
23 Biosensors, Boston Scientific, Daiichi Sankyo, Donga-ST, Hanmi Pharmaceutical, and  
24 Medtronic Inc. Prof. Hyeon-Cheol Gwon received an Institutional Research Grant from Boston

1 Scientific, Genoss, and Medtronic Inc. All other authors declare that there are no competing  
2 interests to declare.

3

4 **Ethical approval:** Not required.

5

#### 6 **Data Sharing**

7 Original data used in the current meta-analysis including the analytic codes will be  
8 shared upon reasonable request. Any relevant inquiry should be emailed to Dr. Joo Myung Lee  
9 (Email: [drone80@hanmail.net](mailto:drone80@hanmail.net)).

10 The lead author (JML) affirms that the manuscript is an honest, accurate, and  
11 transparent account of the study being reported; that no important aspects of the study have  
12 been omitted, and that any discrepancies from the study as planned have been explained.

13

#### 14 **Dissemination to participants and related patient and public communities**

15 There are no plans to disseminate the results to the individual study participants or the  
16 relevant patient community.

17

#### 18 **Copyright/License for Publication**

19 The Corresponding Author (JML) has the right to grant on behalf of all authors and  
20 does grant on behalf of all authors, a worldwide licence to the Publishers and its licensees in  
21 perpetuity, in all forms, formats and media (whether known now or created in the future), to i)  
22 publish, reproduce, distribute, display and store the Contribution, ii) translate the Contribution

- 1 into other languages, create adaptations, reprints, include within collections and create
- 2 summaries, extracts and/or, abstracts of the Contribution, iii) create any other derivative work(s)
- 3 based on the Contribution, iv) to exploit all subsidiary rights in the Contribution, v) the
- 4 inclusion of electronic links from the Contribution to third party material where-ever it may be
- 5 located; and, vi) licence any third party to do any or all of the above.

## 1   **References**

- 2   1    Neumann FJ, Sousa-Uva M, Ahlsson A, et al. 2018 ESC/EACTS Guidelines on  
3       myocardial revascularization. *Eur Heart J* 2019;40:87-165.  
4       doi:10.1093/eurheartj/ehy394
- 5   2    Lawton JS, Tamis-Holland JE, Bangalore S, et al. 2021 ACC/AHA/SCAI Guideline for  
6       Coronary Artery Revascularization: A Report of the American College of  
7       Cardiology/American Heart Association Joint Committee on Clinical Practice  
8       Guidelines. *Circulation* 2022;145:e18-e114. doi:10.1161/cir.0000000000001038
- 9   3    Iakovou I, Schmidt T, Bonizzoni E, et al. Incidence, predictors, and outcome of  
10      thrombosis after successful implantation of drug-eluting stents. *JAMA* 2005;293:2126-  
11      30. doi:10.1001/jama.293.17.2126
- 12  4    Magalhaes MA, Minha S, Chen F, et al. Clinical presentation and outcomes of coronary  
13      in-stent restenosis across 3-stent generations. *Circ Cardiovasc Interv* 2014;7:768-76.  
14      doi:10.1161/CIRCINTERVENTIONS.114.001341
- 15  5    Piccolo R, Giustino G, Mehran R, Windecker S. Stable coronary artery disease:  
16      revascularisation and invasive strategies. *Lancet* 2015;386:702-13. doi:10.1016/S0140-  
17      6736(15)61220-X
- 18  6    Raber L, Mintz GS, Koskinas KC, et al. Clinical use of intracoronary imaging. Part 1:  
19      guidance and optimization of coronary interventions. An expert consensus document of  
20      the European Association of Percutaneous Cardiovascular Interventions. *Eur Heart J*  
21      2018;39:3281-300. doi:10.1093/eurheartj/ehy285
- 22  7    Fitzgerald PJ, Oshima A, Hayase M, et al. Final results of the Can Routine Ultrasound  
23      Influence Stent Expansion (CRUISE) study. *Circulation* 2000;102:523-30.  
24      doi:10.1161/01.cir.102.5.523
- 25  8    Frey AW, Hodgson JM, Muller C, Bestehorn HP, Roskamm H. Ultrasound-guided  
26      strategy for provisional stenting with focal balloon combination catheter: results from  
27      the randomized Strategy for Intracoronary Ultrasound-guided PTCA and Stenting  
28      (SIPS) trial. *Circulation* 2000;102:2497-502. doi:10.1161/01.cir.102.20.2497
- 29  9    Mudra H, di Mario C, de Jaegere P, et al. Randomized comparison of coronary stent  
30      implantation under ultrasound or angiographic guidance to reduce stent restenosis  
31      (OPTICUS Study). *Circulation* 2001;104:1343-9. doi:10.1161/hc3701.096064
- 32  10   Oemrawsingh PV, Mintz GS, Schaliij MJ, et al. Intravascular ultrasound guidance  
33      improves angiographic and clinical outcome of stent implantation for long coronary  
34      artery stenoses: final results of a randomized comparison with angiographic guidance  
35      (TULIP Study). *Circulation* 2003;107:62-7. doi:10.1161/01.cir.0000043240.87526.3f
- 36  11   Russo RJ, Silva PD, Teirstein PS, et al. A randomized controlled trial of angiography  
37      versus intravascular ultrasound-directed bare-metal coronary stent placement (the  
38      AVID Trial). *Circ Cardiovasc Interv* 2009;2:113-23.  
39      doi:10.1161/CIRCINTERVENTIONS.108.778647
- 40  12   Jakabcin J, Spacek R, Bystron M, et al. Long-term health outcome and mortality  
41      evaluation after invasive coronary treatment using drug eluting stents with or without  
42      the IVUS guidance. Randomized control trial. HOME DES IVUS. *Catheter Cardiovasc*  
43      *Interv* 2010;75:578-83. doi:10.1002/ccd.22244
- 44  13   Chieffo A, Latib A, Caussin C, et al. A prospective, randomized trial of intravascular-  
45      ultrasound guided compared to angiography guided stent implantation in complex



- 1 coronary lesions: the AVIO trial. *Am Heart J* 2013;165:65-72.  
2 doi:10.1016/j.ahj.2012.09.017
- 3 14 Kim JS, Kang TS, Mintz GS, et al. Randomized comparison of clinical outcomes  
4 between intravascular ultrasound and angiography-guided drug-eluting stent  
5 implantation for long coronary artery stenoses. *JACC Cardiovasc Interv* 2013;6:369-  
6 76. doi:10.1016/j.jcin.2012.11.009
- 7 15 Kim BK, Shin DH, Hong MK, et al. Clinical Impact of Intravascular Ultrasound-  
8 Guided Chronic Total Occlusion Intervention With Zotarolimus-Eluting Versus  
9 Biolimus-Eluting Stent Implantation: Randomized Study. *Circ Cardiovasc Interv*  
10 2015;8:e002592. doi:10.1161/CIRCINTERVENTIONS.115.002592
- 11 16 Tan Q, Wang Q, Liu D, Zhang S, Zhang Y, Li Y. Intravascular ultrasound-guided  
12 unprotected left main coronary artery stenting in the elderly. *Saudi Med J* 2015;36:549-  
13 53. doi:10.15537/smj.2015.5.11251
- 14 17 Tian NL, Gami SK, Ye F, et al. Angiographic and clinical comparisons of intravascular  
15 ultrasound- versus angiography-guided drug-eluting stent implantation for patients with  
16 chronic total occlusion lesions: two-year results from a randomised AIR-CTO study.  
17 *EuroIntervention* 2015;10:1409-17. doi:10.4244/EIJV10I12A245
- 18 18 Kim JS, Shin DH, Kim BK, et al. Randomized comparison of stent strut coverage  
19 following angiography- or optical coherence tomography-guided percutaneous  
20 coronary intervention. *Rev Esp Cardiol (Engl Ed)* 2015;68:190-7.  
21 doi:10.1016/j.rec.2014.07.025
- 22 19 Antonsen L, Thayssen P, Maehara A, et al. Optical Coherence Tomography Guided  
23 Percutaneous Coronary Intervention With Nobori Stent Implantation in Patients With  
24 Non-ST-Segment-Elevation Myocardial Infarction (OCTACS) Trial: Difference in  
25 Strut Coverage and Dynamic Malapposition Patterns at 6 Months. *Circ Cardiovasc*  
26 *Interv* 2015;8:e002446. doi:10.1161/CIRCINTERVENTIONS.114.002446
- 27 20 Ali ZA, Maehara A, Genereux P, et al. Optical coherence tomography compared with  
28 intravascular ultrasound and with angiography to guide coronary stent implantation  
29 (ILUMIEN III: OPTIMIZE PCI): a randomised controlled trial. *Lancet* 2016;388:2618-  
30 28. doi:10.1016/S0140-6736(16)31922-5
- 31 21 Ali ZA, Karimi Galougahi K, Maehara A, et al. Outcomes of optical coherence  
32 tomography compared with intravascular ultrasound and with angiography to guide  
33 coronary stent implantation: one-year results from the ILUMIEN III: OPTIMIZE PCI  
34 trial. *EuroIntervention* 2021;16:1085-91. doi:10.4244/EIJ-D-20-00498
- 35 22 Meneveau N, Souteyrand G, Motreff P, et al. Optical Coherence Tomography to  
36 Optimize Results of Percutaneous Coronary Intervention in Patients with Non-ST-  
37 Elevation Acute Coronary Syndrome: Results of the Multicenter, Randomized  
38 DOCTORS Study (Does Optical Coherence Tomography Optimize Results of Stenting).  
39 *Circulation* 2016;134:906-17. doi:10.1161/CIRCULATIONAHA.116.024393
- 40 23 Kala P, Cervinka P, Jakl M, et al. OCT guidance during stent implantation in primary  
41 PCI: A randomized multicenter study with nine months of optical coherence  
42 tomography follow-up. *Int J Cardiol* 2018;250:98-103.  
43 doi:10.1016/j.ijcard.2017.10.059
- 44 24 Liu XM, Yang ZM, Liu XK, et al. Intravascular ultrasound-guided drug-eluting stent  
45 implantation for patients with unprotected left main coronary artery lesions: A single-  
46 center randomized trial. *Anatol J Cardiol* 2019;21:83-90.  
47 doi:10.14744/AnatolJCardiol.2018.21447

- 1 25 Hong SJ, Mintz GS, Ahn CM, et al. Effect of Intravascular Ultrasound-Guided Drug-  
2 Eluting Stent Implantation: 5-Year Follow-Up of the IVUS-XPL Randomized Trial.  
3 *JACC Cardiovasc Interv* 2020;13:62-71. doi:10.1016/j.jcin.2019.09.033
- 4 26 Chamie D, Costa JR, Jr., Damiani LP, et al. Optical Coherence Tomography Versus  
5 Intravascular Ultrasound and Angiography to Guide Percutaneous Coronary  
6 Interventions: The iSIGHT Randomized Trial. *Circ Cardiovasc Interv*  
7 2021;14:e009452. doi:10.1161/CIRCINTERVENTIONS.120.009452
- 8 27 Gao XF, Ge Z, Kong XQ, et al. 3-Year Outcomes of the ULTIMATE Trial Comparing  
9 Intravascular Ultrasound Versus Angiography-Guided Drug-Eluting Stent Implantation.  
10 *JACC Cardiovasc Interv* 2021;14:247-57. doi:10.1016/j.jcin.2020.10.001
- 11 28 Neleman T, van Zandvoort LJC, Tovar Forero MN, et al. FFR-Guided PCI Optimization  
12 Directed by High-Definition IVUS Versus Standard of Care: The FFR REACT Trial.  
13 *JACC Cardiovasc Interv* 2022;15:1595-607. doi:10.1016/j.jcin.2022.06.018
- 14 29 Holm NR, Andreassen LN, Neghabat O, et al. OCT or Angiography Guidance for PCI  
15 in Complex Bifurcation Lesions. *N Engl J Med* 2023 doi:10.1056/NEJMoa2307770
- 16 30 Ali ZA, Landmesser U, Maehara A, et al. Optical Coherence Tomography-Guided  
17 versus Angiography-Guided PCI. *N Engl J Med* 2023 doi:10.1056/NEJMoa2305861
- 18 31 Stewart LA, Clarke M, Rovers M, et al. Preferred Reporting Items for Systematic  
19 Review and Meta-Analyses of individual participant data: the PRISMA-IPD Statement.  
20 *Jama* 2015;313:1657-65. doi:10.1001/jama.2015.3656
- 21 32 Hong SJ, Kim BK, Shin DH, et al. Effect of Intravascular Ultrasound-Guided vs  
22 Angiography-Guided Everolimus-Eluting Stent Implantation: The IVUS-XPL  
23 Randomized Clinical Trial. *JAMA* 2015;314:2155-63. doi:10.1001/jama.2015.15454
- 24 33 Mentias A, Sarrazin MV, Saad M, et al. Long-Term Outcomes of Coronary Stenting  
25 With and Without Use of Intravascular Ultrasound. *JACC Cardiovasc Interv*  
26 2020;13:1880-90. doi:10.1016/j.jcin.2020.04.052
- 27 34 Park DY, Vemmou E, An S, et al. Trends and impact of intravascular ultrasound and  
28 optical coherence tomography on percutaneous coronary intervention for myocardial  
29 infarction. *Int J Cardiol Heart Vasc* 2023;45:101186. doi:10.1016/j.ijcha.2023.101186
- 30 35 Shin DH, Kang HJ, Jang JS, et al. The Current Status of Percutaneous Coronary  
31 Intervention in Korea: Based on Year 2014 & 2016 Cohort of Korean Percutaneous  
32 Coronary Intervention (K-PCI) Registry. *Korean Circ J* 2019;49:1136-51.  
33 doi:10.4070/kcj.2018.0413
- 34 36 Witzenbichler B, Maehara A, Weisz G, et al. Relationship between intravascular  
35 ultrasound guidance and clinical outcomes after drug-eluting stents: the assessment of  
36 dual antiplatelet therapy with drug-eluting stents (ADAPT-DES) study. *Circulation*  
37 2014;129:463-70. doi:10.1161/CIRCULATIONAHA.113.003942
- 38 37 Kinnaird T, Johnson T, Anderson R, et al. Intravascular Imaging and 12-Month  
39 Mortality After Unprotected Left Main Stem PCI: An Analysis From the British  
40 Cardiovascular Intervention Society Database. *JACC Cardiovasc Interv* 2020;13:346-  
41 57. doi:10.1016/j.jcin.2019.10.007
- 42 38 Choi KH, Song YB, Lee JM, et al. Impact of Intravascular Ultrasound-Guided  
43 Percutaneous Coronary Intervention on Long-Term Clinical Outcomes in Patients  
44 Undergoing Complex Procedures. *JACC Cardiovasc Interv* 2019;12:607-20.  
45 doi:10.1016/j.jcin.2019.01.227
- 46 39 Buccheri S, Franchina G, Romano S, et al. Clinical Outcomes Following Intravascular  
47 Imaging-Guided Versus Coronary Angiography-Guided Percutaneous Coronary

- 1 Intervention With Stent Implantation: A Systematic Review and Bayesian Network  
2 Meta-Analysis of 31 Studies and 17,882 Patients. *JACC Cardiovasc Interv*  
3 2017;10:2488-98. doi:10.1016/j.jcin.2017.08.051
- 4 40 Darmoch F, Alraies MC, Al-Khadra Y, Moussa Pacha H, Pinto DS, Osborn EA.  
5 Intravascular Ultrasound Imaging-Guided Versus Coronary Angiography-Guided  
6 Percutaneous Coronary Intervention: A Systematic Review and Meta-Analysis. *J Am*  
7 *Heart Assoc* 2020;9:e013678. doi:10.1161/JAHA.119.013678
- 8 41 Lee JM, Choi KH, Song YB, et al. Intravascular Imaging-Guided or Angiography-  
9 Guided Complex PCI. *N Engl J Med* 2023;388:1668-79. doi:10.1056/NEJMoa2216607
- 10 42 Choi KH, Lee SY, Song YB, et al. Prognostic Impact of Operator Experience and IVUS  
11 Guidance on Long-Term Clinical Outcomes After Complex PCI. *JACC Cardiovasc*  
12 *Interv* 2023;16:1746-58. doi:10.1016/j.jcin.2023.04.022
- 13 43 Kubo T, Shinke T, Okamura T, et al. Optical frequency domain imaging vs.  
14 intravascular ultrasound in percutaneous coronary intervention (OPINION trial): one-  
15 year angiographic and clinical results. *Eur Heart J* 2017;38:3139-47.  
16 doi:10.1093/eurheartj/ehx351
- 17 44 Kang DY, Ahn JM, Yun SC, et al. Optical Coherence Tomography-Guided or  
18 Intravascular Ultrasound Guided Percutaneous Coronary Intervention: The OCTIVUS  
19 Randomized Clinical Trial. *Circulation* 2023  
20 doi:10.1161/CIRCULATIONAHA.123.066429

21

## 1 **Figure Legends**

### 2 **Figure 1. Flow Diagram of Study Selection**

3 The study flow diagram was depicted following the guideline of Preferred Reporting Items for  
4 Systematic Reviews and Meta-Analyses (PRISMA).

### 6 **Figure 2. Meta-Analysis Comparing Major Adverse Cardiac Event Between 7 Intravascular Imaging vs. Angiography-Guided PCI**

8 Forest plots comparing major adverse cardiac event, a composite of all-cause death, myocardial  
9 infarction, and target vessel revascularization between intravascular imaging-guided and  
10 angiography-guided PCI. RRs with 95% CIs are displayed for individual studies and the pooled  
11 overall effect.

12 Abbreviations: **AIR-CTO**, Angiographic and clinical comparisons of intravascular ultrasound-  
13 versus angiography-guided drug-eluting stent implantation for patients with chronic total  
14 occlusion lesions; **AVID**, Angiography Versus Intravascular ultrasound-Directed stent  
15 placement; **AVIO**, Angiography Vs. IVUS Optimization; **CRUISE**, Can Routine Ultrasound  
16 Influence Stent Expansion; **CI**, indicates confidence interval; **CTO-IVUS**, Chronic Total  
17 Occlusion InterVention with drUg-eluting Stents guided by IVUS; **DOCTORS**, Does Optical  
18 Coherence Tomography Optimize Results of Stenting; **FFR-REACT**, Fractional flow reserve  
19 guided percutaneous coronary intervention optimization directed by high-definition  
20 intravascular ultrasound versus standard of care; **HOME DES IVUS**, Long-Term Health  
21 Outcome and Mortality Evaluation After Invasive Coronary Treatment Using Drug Eluting  
22 Stents with or without the IVUS Guidance; **iSIGHT**, Optical Coherence Tomography Versus  
23 Intravascular Ultrasound and Angiography to Guide Percutaneous Coronary Interventions;  
24 **IVUS-XPL**, Impact of Intravascular Ultrasound Guidance on Outcomes of Xience Prime

1 Stents in Long Lesions; **OCTACS**, Optical Coherence Tomography Guided Percutaneous  
2 Coronary Intervention With Nobori Stent Implantation in Patients With Non ST Segment  
3 Elevation Myocardial Infarction; **OCTOBER**, European Trial on Optical Coherence  
4 Tomography Optimized Bifurcation Event Reduction; **OPTICUS**, OPTimization with ICUS  
5 to reduce stent restenosis; **RENOVATE COMPLEX-PCI**, Randomized Controlled Trial of  
6 Intravascular Imaging Guidance versus Angiography-Guidance on Clinical Outcomes After  
7 Complex Percutaneous Coronary Intervention; **PCI**, percutaneous coronary intervention;  
8 **RESET**, Real Safety and Efficacy of a 3-Month Dual Antiplatelet Therapy Following  
9 Zotarolimus-Eluting Stents Implantation; **ROBUST**, Comparison of Biolimus A9 and  
10 Everolimus Drug-Eluting Stents in Patients With ST Segment Elevation Myocardial Infarction;  
11 **RR**, relative risk; **SIPS**, Strategy for Intracoronary Ultrasound-Guided PTCA and Stenting;  
12 **TULIP**, Thrombocyte activity evaluation and effects of Ultrasound guidance in Long  
13 Intracoronary stent Placement; and **ULTIMATE**, Intravascular Ultrasound Guided Drug  
14 Eluting Stents Implantation in “All-Comers” Coronary Lesions.

15

16 **Figure 3. Meta-Analysis Comparing Clinical Outcomes Between Intravascular Imaging**  
17 **vs. Angiography-Guided PCI**

18 Forest plots comparing individual clinical outcomes between intravascular imaging-guided and  
19 angiography-guided PCI. RRs with 95% CIs are displayed for individual studies and the pooled  
20 overall effect. (A) all-cause death, (B) myocardial infarction, (C) target vessel revascularization,  
21 and (D) stent thrombosis.

22 Abbreviations are as in Figure 2.

23

24 **Figure 4. Subgroup Analysis**

1 Forest plots of subgroup analysis comparing major adverse cardiac event, a composite of all-  
2 cause death, myocardial infarction, and target vessel revascularization between intravascular  
3 imaging-guided and angiography-guided PCI. RRs with 95% CIs are displayed for individual  
4 studies and the pooled overall effect.

5 Abbreviations are as in Figure 2.

6

7 **Figure 5. Meta-Analysis Comparing Death Between Intravascular Imaging vs. Angio-**  
8 **Guided Optimization Stratified by Stent Type**

9 Forest plots comparing all-cause death between intravascular imaging-guided and  
10 angiography-guided PCI according to type of used stents. RRs with 95% CIs are displayed for  
11 individual studies and the pooled overall effect.

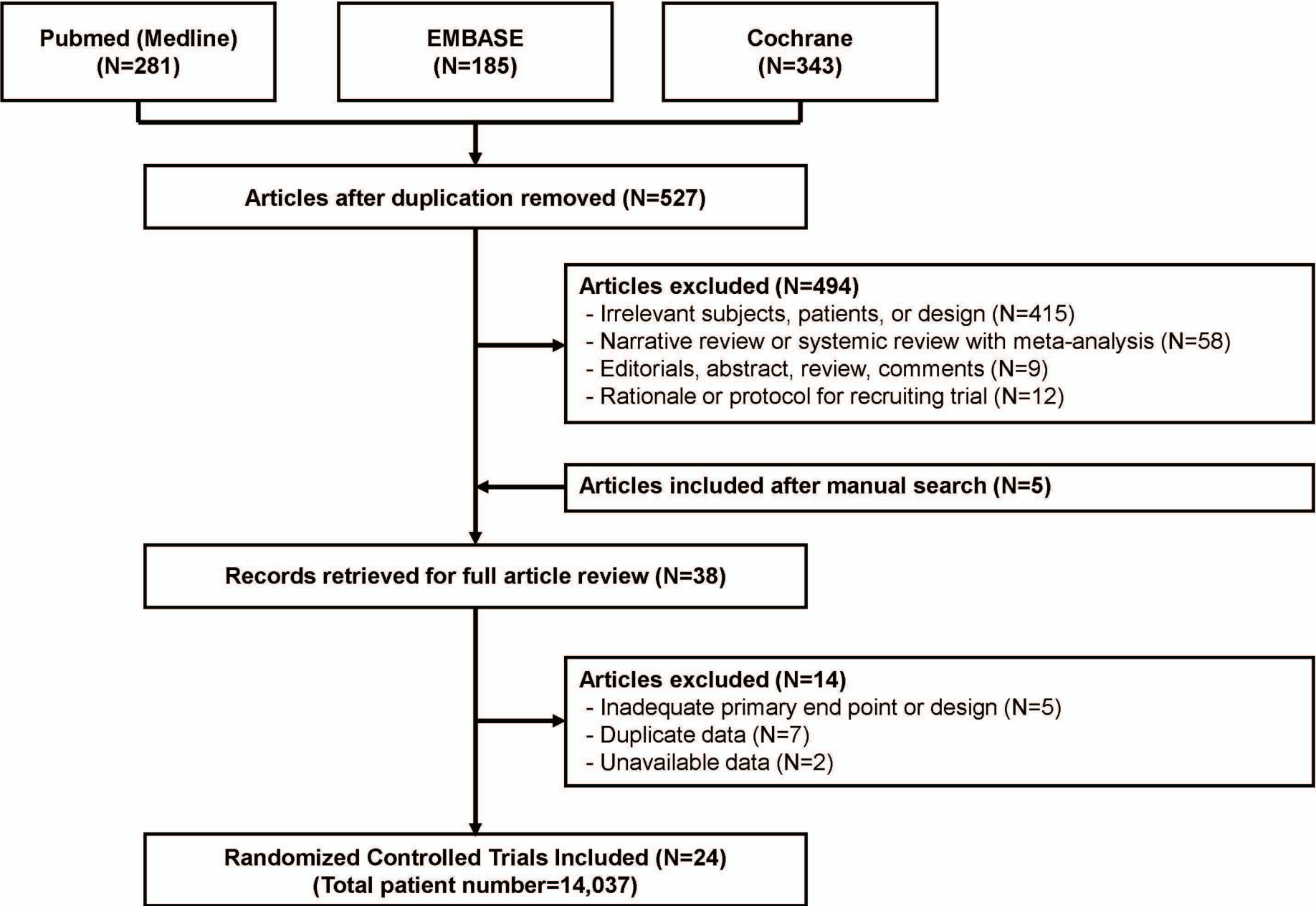
12 Abbreviations are as in Figure 2.

**Table 1. Baseline Characteristics of the Included Trials**

Trial	Enroll Period	Median Follow-up (year)	Study Population	Imaging-guided PCI (no)	Angiography-guided PCI (no)	Proportion of Imaging Devices (%)		Stent Type
						IVUS	OCT	
CRUISE	1996-1997	0.75	All patients undergoing PCI	270	229	100	0	BMS
SIPS	1996-1996	2	All patients undergoing PCI	121	148	100	0	BMS
OPTICUS	1996-1998	1	All patients undergoing PCI	273	275	100	0	BMS
TULIP	1998-2001	1	Long lesion	73	71	100	0	BMS
AVID	1995-1999	1	All patients undergoing PCI	369	375	100	0	BMS
HOME DES IVUS	2004-2005	1.5	Various complex lesions only	105	105	100	0	1 <sup>st</sup> Gen DES
AVIO	2008-2009	2	Various complex lesions only	142	142	100	0	1 <sup>st</sup> Gen DES
Kim et al. (RESET substudy)	2009-2012	1	Long lesion	269	274	100	0	2 <sup>nd</sup> Gen DES
CTO-IVUS	2012-2013	1	Chronic total occlusion	201	201	100	0	2 <sup>nd</sup> Gen DES
AIR-CTO	2010-2011	2	Chronic total occlusion	115	115	100	0	2 <sup>nd</sup> Gen DES
Tan et al.	2009-2012	2	Left main	61	62	100	0	2 <sup>nd</sup> Gen DES
Kim et al.	2011-2012	1	All patients undergoing PCI	58	59	0	100	2 <sup>nd</sup> Gen DES
OCTACS	2011-2013	0.5	Non ST-segment elevation MI	50	50	0	100	2 <sup>nd</sup> Gen DES
DOCTORS	2013-2015	0.5	All patients undergoing PCI	120	120	0	100	2 <sup>nd</sup> Gen DES
ROBUST	2011-2012	0.75	ST-segment elevation MI	105	96	0	100	2 <sup>nd</sup> Gen DES
Liu et al.	2010-2015	1	Left main	167	169	100	0	2 <sup>nd</sup> Gen DES
IVUS-XPL	2010-2014	5	Long lesion	700	700	100	0	2 <sup>nd</sup> Gen DES
ILUMIEN III	2015-2016	1	All patients undergoing PCI	289	142	47	53	2 <sup>nd</sup> Gen DES
ULTIMATE	2014-2017	3	All patients undergoing PCI	724	724	100	0	2 <sup>nd</sup> Gen DES
iSIGHT	2015-2016	1	All patients undergoing PCI	101	49	50	50	2 <sup>nd</sup> Gen DES
FFR-REACT	2017-2020	1	All patients undergoing PCI	145	146	100	0	2 <sup>nd</sup> Gen DES
RENOVATE COMPLEX-PCI	2018-2021	2.1	Various complex lesions only	1092	547	74	26	2 <sup>nd</sup> Gen DES
ILUMIEN IV	2018-2020	2	Various complex lesions only and diabetes mellitus	1233	1254	0	100	2 <sup>nd</sup> Gen DES
OCTOBER	2017-2022	2	True bifurcation	600	601	0	100	2 <sup>nd</sup> Gen DES

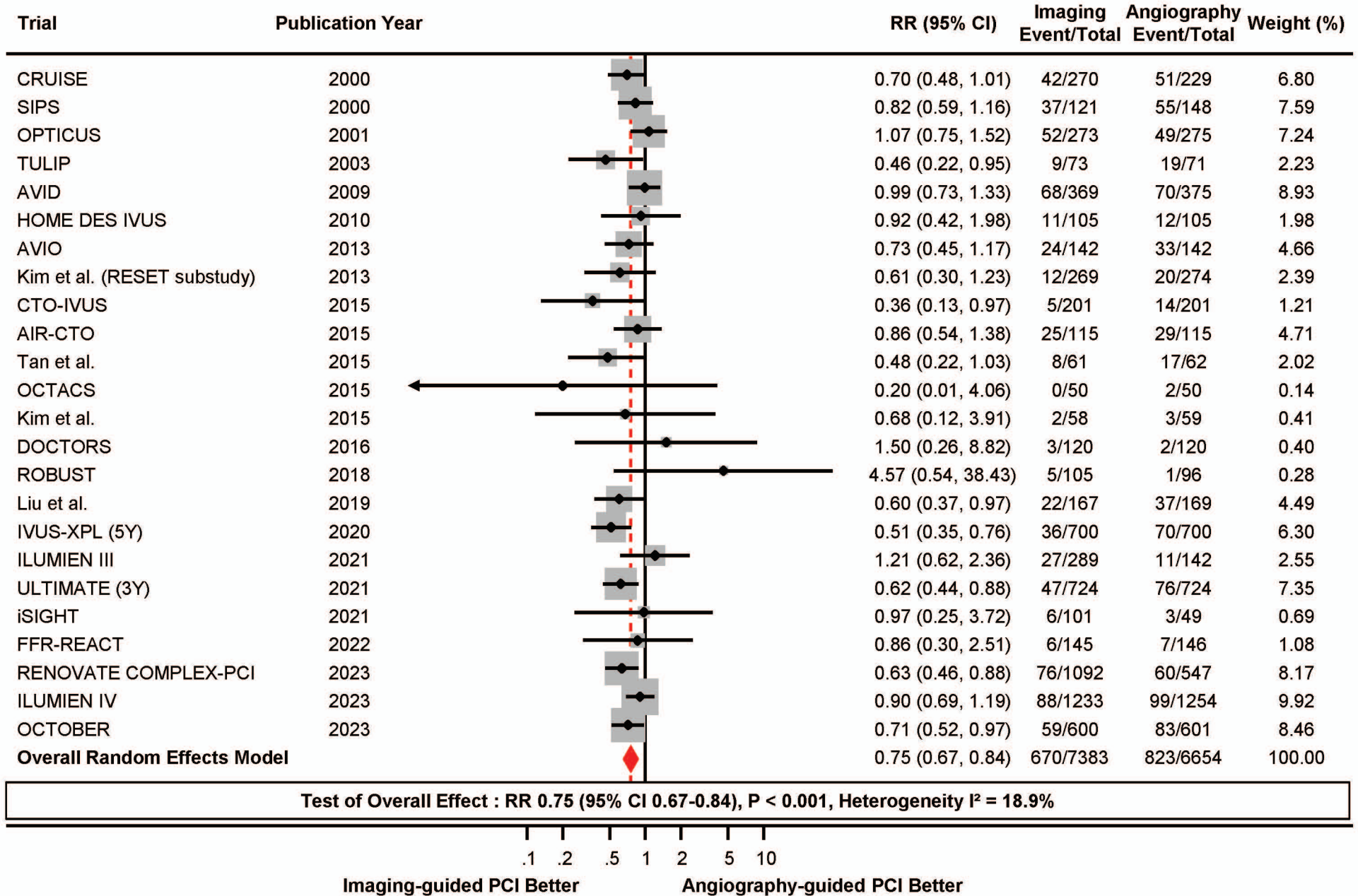
Abbreviations: BMS, bare metal stent; DES, drug-eluting stent; Gen, generation; IVUS, intravascular ultrasound; MI, myocardial infarction; OCT, optical coherence tomography; PCI, percutaneous coronary intervention.

Figure 1. Flow Diagram of Study Selection.



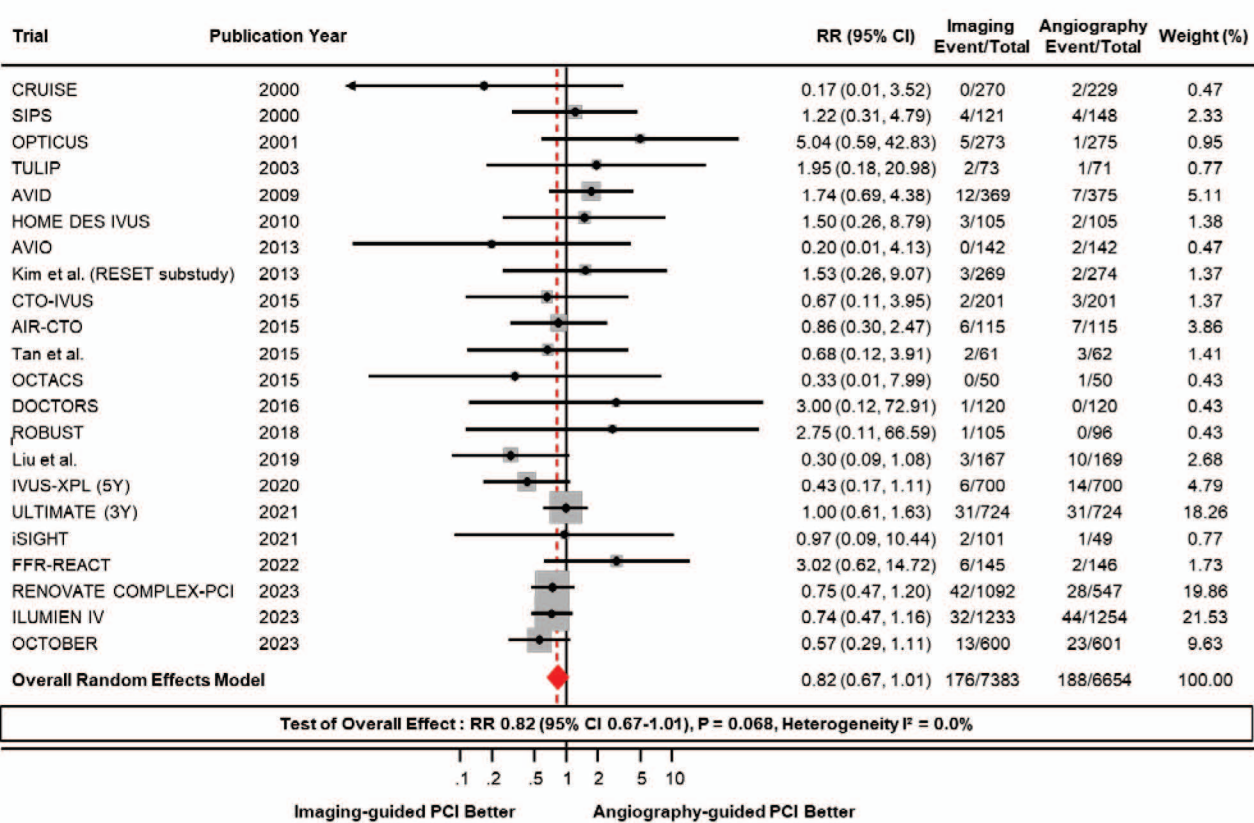


**Figure 2. Meta-Analysis Comparing Major Adverse Cardiac Event Between Intravascular Imaging vs. Angio-Guided Optimization**

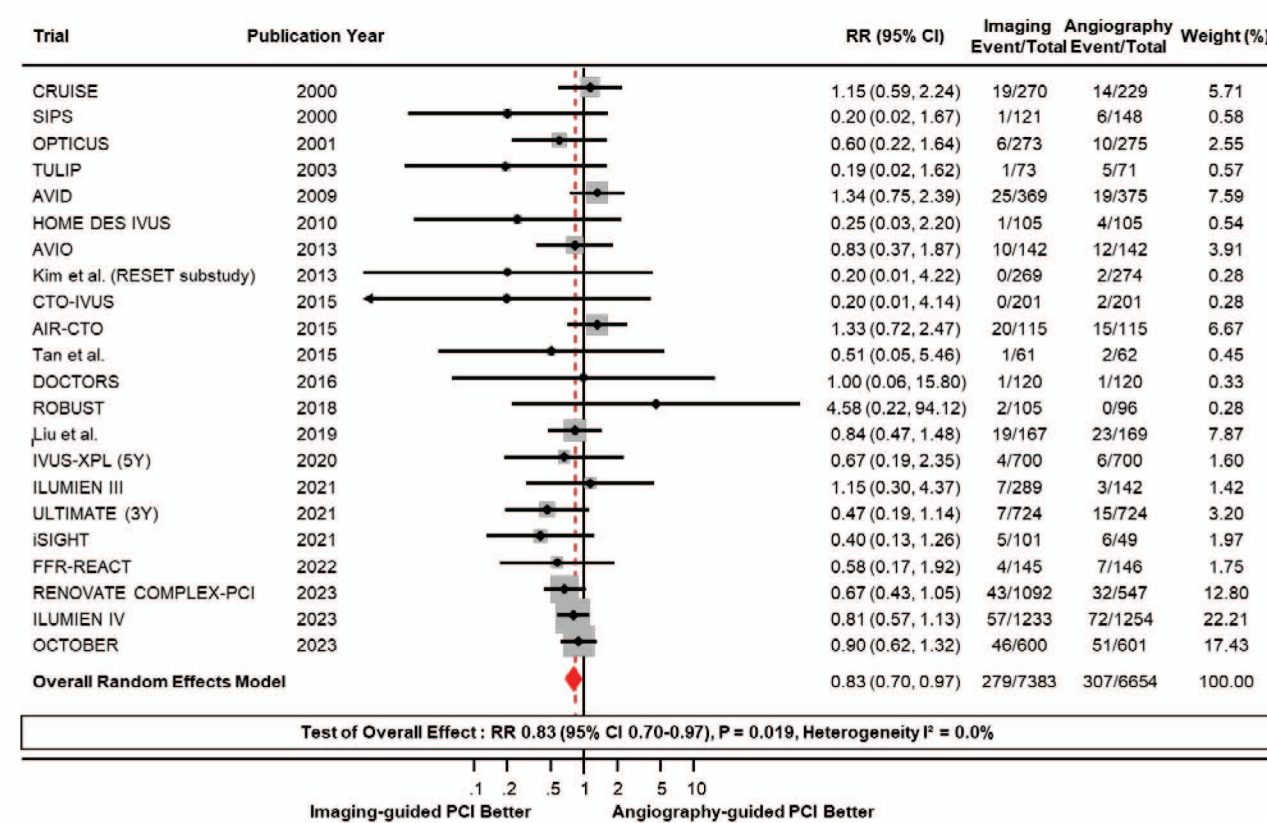


**Figure 3. Meta-Analysis Comparing Clinical Outcomes Between Intravascular Imaging vs. Angiography-Guided PCI**

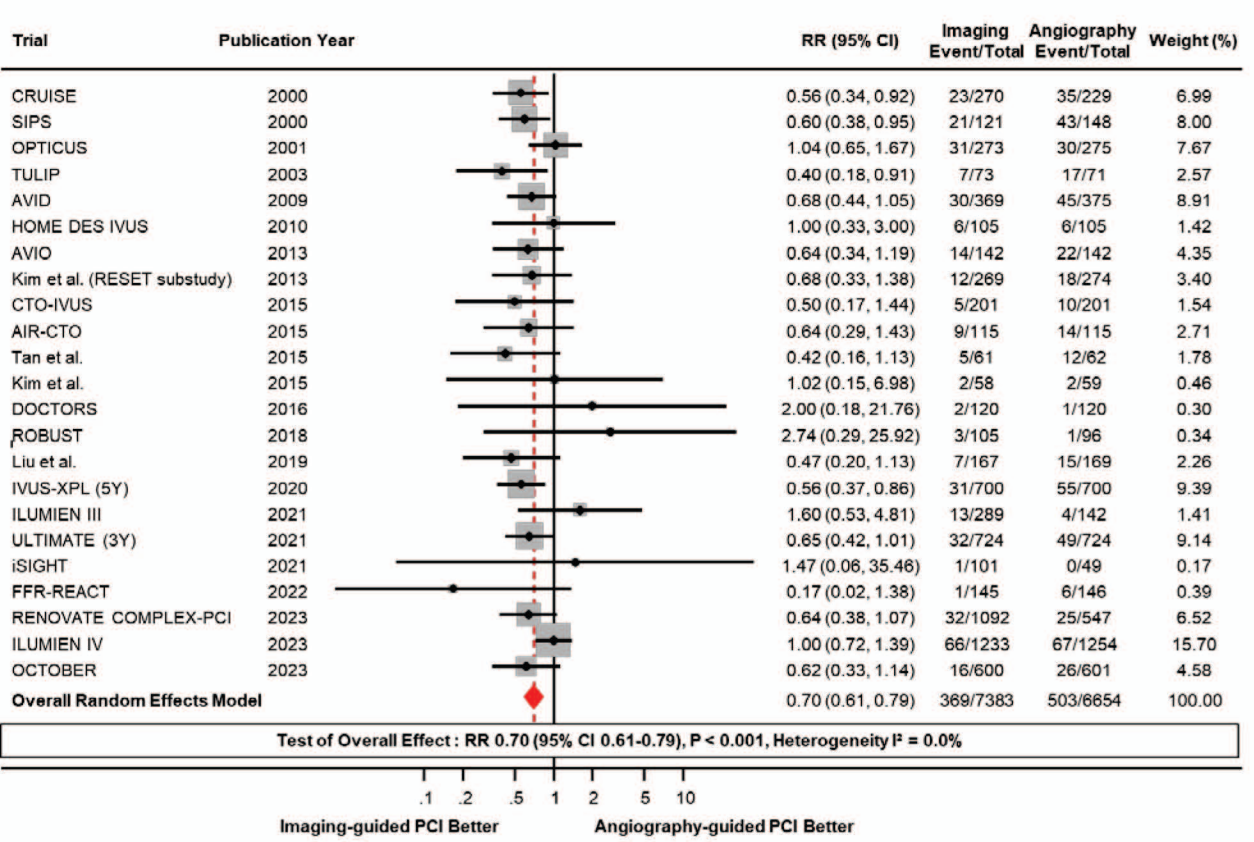
**A. Death**



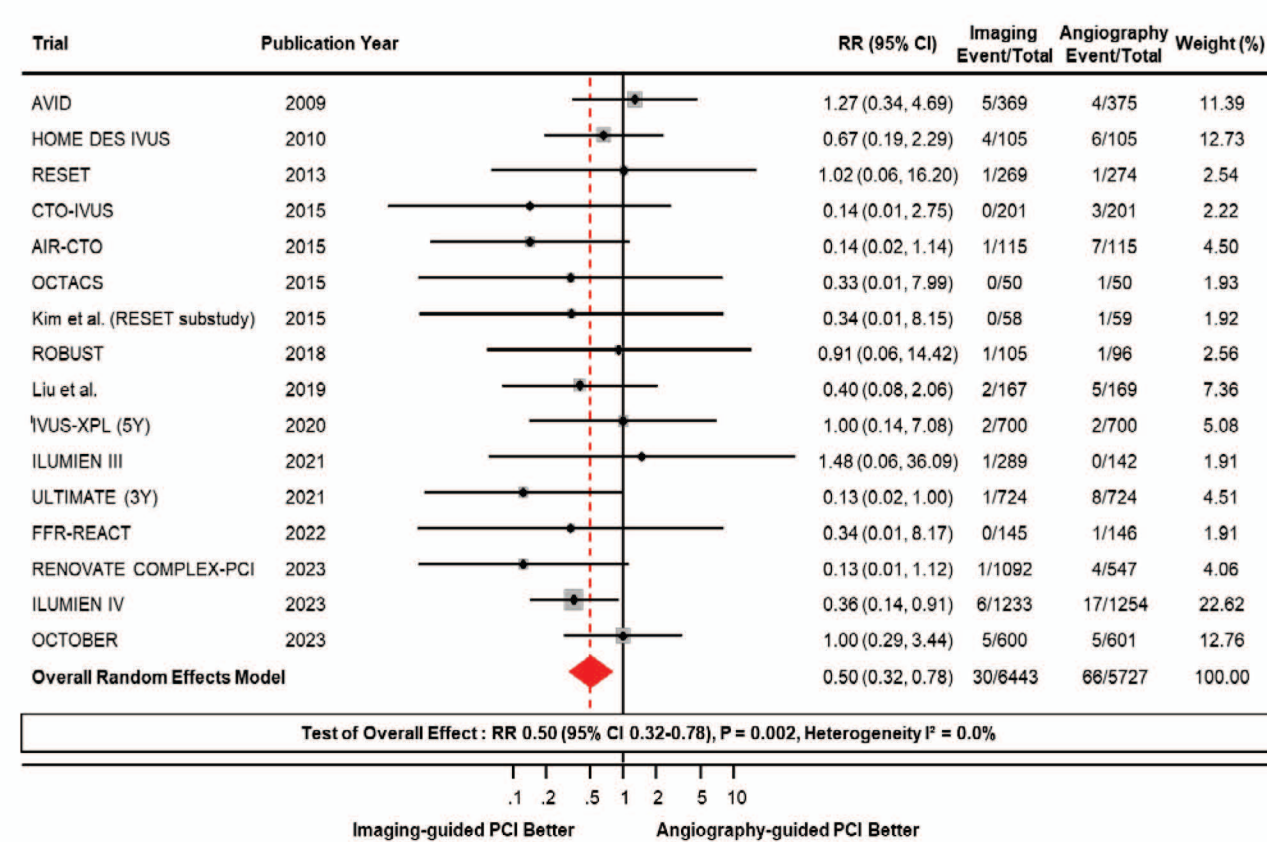
**B. Myocardial Infarction**



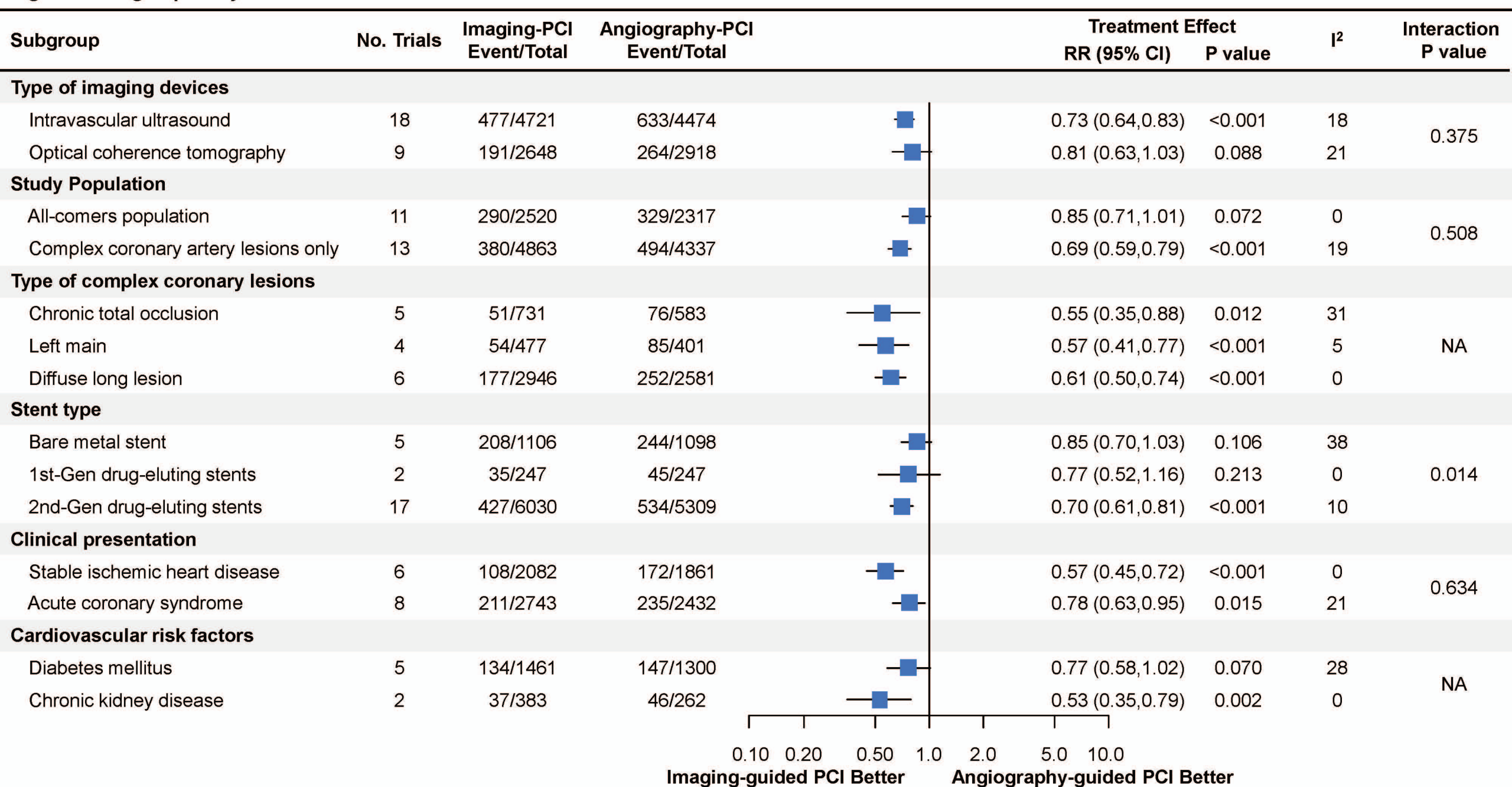
**C. Target Vessel Revascularization**



**D. Stent Thrombosis**



**Figure 4. Subgroup Analysis**



**Figure 5. Meta-Analysis Comparing Death Between Intravascular Imaging vs. Angio-Guided Optimization Stratified by Stent Type**

