

# Electroconvulsive therapy increases cortical thickness in depression: A systematic review

Toffanin Tommaso<sup>1\*</sup>, Cattarinussi Giulia<sup>2,3,4\*</sup>, Ghiotto Niccolò<sup>2</sup>, Lussignoli Marialaura<sup>2</sup>, Pavan Chiara<sup>2</sup>, Pieri Luca<sup>5</sup>, Schiff S.<sup>5</sup>, Finatti Francesco<sup>2</sup>, Romagnolo Francesca<sup>1</sup>, Folesani Federica<sup>1</sup>, Nanni Maria Giulia<sup>1</sup>, Caruso Rosangela<sup>1</sup>, Zerbinati Luigi<sup>1</sup>, Belvederi Murri Martino<sup>1</sup>, Ferrara Maria<sup>1</sup>, Pigato Giorgio<sup>6</sup>, Grassi Luigi<sup>1</sup>, Sambataro Fabio<sup>2,3\*\*</sup>

<sup>1</sup> Department of Neuroscience and Rehabilitation, Institute of Psychiatry, University of Ferrara, Ferrara, Italy

<sup>2</sup> Department of Neuroscience (DNS), University of Padova, Padua, Italy

<sup>3</sup> Padova Neuroscience Center, University of Padova, Padua, Italy

<sup>4</sup> Department of Psychological Medicine, Institute of Psychiatry, Psychology and Neuroscience, Kings College London, London, UK

<sup>5</sup> Department of Medicine, University of Padua, Padua, Italy

<sup>6</sup> Padua University Hospital, Padua, Padua, Italy

\* These authors contributed equally

\*\*Corresponding author:

Prof. Fabio Sambataro, M.D., Ph.D.

Padua University Hospital, Psychiatric Unit, Via Giustiniani, 2, 35128 Padova, Italy;

Tel. +39 0498212562; Email: [fabio.sambataro@unipd.it](mailto:fabio.sambataro@unipd.it)

Word count Abstract: 210/250

Word count Main Text: 5286/10000

N. of tables: 1

N. of figures: 3

## **Abstract**

**Objective:** Electroconvulsive therapy (ECT) is one of the most studied and validated available treatments for severe or treatment-resistant depression. However, little is known about the neural mechanisms underlying the ECT treatment. This systematic review aims to critically review all structural magnetic resonance imaging studies investigating longitudinal cortical thickness (CT) changes after ECT in patients with unipolar or bipolar depression.

**Methods:** We performed a search on PubMed, Medline, and Embase to identify all available studies published before April 20, 2023. A total of 10 studies were included.

**Results:** The investigations showed widespread increases in CT after ECT in depressed patients, involving mainly the temporal, insular, and frontal regions. In five studies, CT increases in a non-overlapping set of brain areas correlated with the clinical efficacy of ECT. The small sample size, heterogeneity in terms of populations, medications, comorbidities, and ECT protocols, and the lack of a control group in some investigations limit the generalizability of the results.

**Conclusions:** Our findings support the idea that ECT can increase CT in patients with unipolar and bipolar depression. It remains unclear whether these changes are related to the clinical response. Future larger studies with longer follow-up are warranted to thoroughly address the potential role of CT as a biomarker of clinical response after ECT.

**Keywords:** ECT, depression, treatment-resistant depression, cortical thickness, Hamilton rating scale for depression

## **Summations**

- This review summarizes how ECT affects CT in patients with unipolar or bipolar depression.
- The areas that were predominantly affected by ECT were temporo-insular and frontal regions. An association between the antidepressant effect of ECT and CT changes was reported by half of the included studies.
- Identifying the possible cortical changes associated with the clinical efficacy of ECT opens new targets to ameliorate ECT protocols.

## **Considerations**

The review is based on studies with small numbers of patients and considerable heterogeneity in terms of patients' characteristics and ECT protocols. Most studies cited did not have a randomized design, thus reducing the strength of evidence supporting a causal link between ECT and CT changes.

## Introduction

Electroconvulsive therapy (ECT) was first used in 1938 by Italian scientists Ugo Cerletti and Lucio Bini to induce an epileptic seizure to treat patients with schizophrenia (Gazdag and Ungvari, 2019). In the following decades, the introduction of general anesthesia and accurate operational protocols greatly improved ECT techniques (Kadiyala and Kadiyala, 2018; Kellner et al., 2020), allowing ECT to evolve to become a promising and well-tolerated treatment. Nowadays, it is considered the safest procedure performed under general anesthesia (Tørring et al., 2017). ECT is an important therapeutic strategy for affective disorders, including severe major depressive disorder (MDD), particularly with psychotic symptoms and a high risk of suicide, treatment-resistant depression (TRD), and depression in bipolar disorder (BD) (Fornaro et al., 2020; Kho et al., 2003). Despite the major advances in psychopharmacology and brain stimulation techniques, ECT remains one of the most effective treatments in psychiatry, with response rates in the treatment of unipolar and bipolar depression ranging from 74 to 77 % (Bahji et al., 2019).

The exact pathophysiological mechanisms underlying depression have not yet been clarified. Among the putative mechanisms, the “neurotrophin hypothesis of depression” suggests that a stress-induced decrease in the expression of brain-derived neurotrophic factor (BDNF) leads to atrophy of stress-vulnerable neurons in the hippocampus (Duman et al., 1997). Later studies expanded this theory, indicating that changes in BDNF expression and function result in structural brain alterations not only in the hippocampus but also in the prefrontal cortex (PFC) (Duman and Li, 2012). Crucially, magnetic resonance imaging (MRI) investigations have been supporting this theory, demonstrating reductions in gray matter volumes in MDD in the hippocampus and orbitofrontal cortex, as well as in the basal ganglia, thalamus, and anterior cingulate cortex (ACC) (Kempton et al., 2011; Koolschijn et al., 2009). In bipolar depression, similar volumetric alterations have been reported, particularly in the frontal and limbic areas. In addition to volumetric changes, alterations in surface measurements have also been reported in depression, such as cortical thickness (CT), which represents the depth of gray matter as the covering neural sheet of brain foldings and is correlated with the size of neurons, neuroglia, and nerve fibers (Narr et al., 2005). Importantly, a reduction in CT could indicate a reduction in dendritic arborization or changes in myelination at the gray/white matter interface (Sowell et al., 2004). The Enhancing Neuroimaging Genetics through Meta-Analysis (ENIGMA) Consortium demonstrated that lower CT in temporal regions is a common feature in various neuropsychiatric disorders (Boedhoe et al., 2018; Hoogman et al., 2019; Schmaal et al., 2017; Van Rooij et al., 2018). With regards to MDD, the ENIGMA Major Depressive Disorder Working Group reported thinner cortical gray matter in MDD compared to controls in the orbitofrontal cortex (OFC), ACC and posterior cingulate cortex (PCC), insula, and temporal lobes (Schmaal et al., 2017).

Furthermore, a decrease in CT was also found in elderly patients with MDD (Lim et al., 2012) and in those with a high risk for suicide (Wagner et al., 2012). Additionally, a thinner CT in the PCC could indicate a higher risk of nonremission in MDD patients (Järnum et al., 2011). In BD, a recent ENIGMA study highlighted that individuals with BD showed a widespread thinner cortex relative to HC, with the largest effect size in the left fusiform gyrus (Matsumoto et al., 2023).

Although the association between surface measures and the severity of depressive symptoms is unclear, changes in CT after response and remission have been reported after antidepressant treatment. In particular, in a 12-week trial using sertraline in patients with late-life depression, nonremitters presented thinner frontal poles at baseline compared to remitters (Sheline et al., 2012). Another trial showed that sertraline increased CT in the left medial PFC, right medial and lateral PFC, and within the right parietal-temporal lobes in patients with MDD compared to placebo (Nemati and Abdallah, 2020). In addition, CT also predicted the effectiveness of psychotherapy for late-life depression (Mackin et al., 2013). Therefore, reduced CT appears to be related to the reduced efficacy of pharmacological and pharmacotherapy interventions in MDD, and successful treatment appears to reverse atrophy in fronto-limbic areas (Motter et al., 2021). Crucially, reduced CT appears to be associated also with early-life traumas and with other affective disorders, including BD and anxiety (Yang et al., 2023; Zhu et al., 2022).

The neural mechanisms underlying the effects of ECT in the treatment of depression are still largely unknown, and this further contributes to the skepticism about its use (Bolwig, 2011). Importantly, recent meta-analytic evidence suggested that ECT is associated with volume increases in the hippocampus and increased integrity of white matter pathways in the frontal and temporal lobes (Gbyl and Videbeck, 2018). These findings have also been confirmed by a mega-analysis conducted by the Global ECT-MRI Research Collaboration (GEMRIC), which showed that ECT induced broadly distributed gray matter volumetric increases (Ousdal et al., 2020). Interestingly, CT may be more sensitive than volume to brain changes associated with ECT, including alterations in the glial and neuronal microstructure (Winkler et al., 2010).

Given these premises, we aimed to review the available evidence on CT alterations associated with ECT treatment in patients with depression to explore the association between changes in CT and the antidepressant effect of ECT.

## **Materials and methods**

### *Literature search and screening*

The study inclusion criteria were the following: a) include participants with a diagnosis of MDD or BD according to the Diagnostic and Statistical Manual of Mental Disorders (DSM) or International

Classification of Disease (ICD) criteria or TRD (any definition); b) participants underwent MRI pre- and post-ECT treatments; c) changes of CT were assessed longitudinally, i.e. before and after the ECT treatments; c) CT changes were longitudinally evaluated, i.e., before and after the ECT sessions (no restrictions in terms of the number of sessions or temporal distance between ECT and MRI).

A comprehensive search of the literature was performed on PubMed, Medline, and Embase using the following keywords: (ECT [Title/Abstract] OR Electroconvulsive Therapy [Title/Abstract] OR Electroconvulsive Treatment [Title/Abstract]) AND ((Major Depressive Disorder [Title/Abstract] OR Depression [Title/Abstract] OR Bipolar Disorder [Title/Abstract]) OR Bipolar Depression [Title/Abstract]) AND Cortical thickness [Title/Abstract]). No language restrictions were applied to identify peer-reviewed articles published up to April 2023.

We screened titles and abstracts of all potentially eligible studies, retrieving the full-text articles. References cited by each study were also manually screened to ensure that no relevant studies were left out. This procedure was carried out according to the Preferred Reporting Items for Systematic Reviews and Meta-Analysis (PRISMA) guidelines (Liberati et al., 2009). Of the 35 initial studies, 25 remained after removing duplicates, and 11 citations met the title/abstract screening eligibility criteria and were included. After full-text screening, 1 article was excluded because it did not report longitudinal changes after ECT (Wade et al., 2017), resulting in 10 eligible studies (Fig.1). Since only two studies reported quantitative measures of the effects of ECT on CT, we could not perform a meta-analysis.

### *Assessment of methodological quality*

The methodological quality of the included studies was assessed using a point system derived from Gbly and Videbech (Gbyl and Videbech, 2018). Briefly, the quality score consisted of the following items: a) number of subjects; b) presence of a control group; c) number of MRI scans the control group underwent; d) MRI scanner field strength; e) voxel size of the MRI scan; f) medication status; g) consecutively collected sample; h) duration of follow-up. A higher score indicated better methodological quality (see Supplementary Material).

## **Results**

### *Demographic, clinical, and ECT characteristics of included studies*

The characteristics of the included studies are described in Tab. 1. 253 patients (244 with MDD or TRD, 9 with bipolar depression, mean age  $46.3 \pm 10.6$  years; 67.9 % female; mean duration of the illness 17.7 years) and 143 healthy controls (mean age  $48.9 \pm 11.2$  years; 51.7 % female) were included. Seven studies reported that depressed participants received medications at the time of scan

(Bracht et al., 2023; Gbyl et al., 2019; Gryglewski et al., 2019; Sartorius et al., 2016; Schmitgen et al., 2020; Xu et al., 2019; Yroni et al., 2019). Seven studies repeated structural analysis twice (Bracht et al., 2023; Gryglewski et al., 2019; Ji et al., 2022; Sartorius et al., 2016; Schmitgen et al., 2020; van Eijndhoven et al., 2016; Xu et al., 2019) and three studies performed three MRI scans (Gbyl et al., 2019; Pirnia et al., 2016; Yroni et al., 2019). In all studies, the first scan was acquired within a week before the ECT session and the second within a week after treatment. Two studies acquired an intermediate scan between the first and last ECT sessions to explore acute changes in CT (Pirnia et al., 2016; Yroni et al., 2019), while one study acquired a scan before the first ECT session, a scan after the last ECT treatment, and a scan within six months after ECT treatment to examine the long-lasting effects of ECT on CT (Gbyl et al., 2019) (Fig. 2). The diagnosis of MDD was made according to DSM-IV, DSM-IV-TR, and DSM-5. Depressive symptoms were assessed with the Hamilton depression rating scales (HAM-D) (Hamilton, 1960) and in Pirnia et al. (2016) (Pirnia et al., 2016) also with the Montgomery-Åsberg depression rating scales (MADRS) (Montgomery and Åsberg, 1979). In most studies, the medications were kept unchanged before ECT (Bracht et al., 2023; Gbyl et al., 2019; Gryglewski et al., 2019; Schmitgen et al., 2020; Wade et al., 2017; Xu et al., 2019), while in two studies the medications were tapered (Sartorius et al., 2016; van Eijndhoven et al., 2016). Patients were excluded when they presented neurological disorders, addictive disorders, schizophrenia spectrum disorders and personality disorders, a history of head injury resulting in unconsciousness for more than 5 minutes, MRI contraindications, and previous ECT sessions received in the last six months/year.

Six studies included a comparison with a group of healthy participants who did not undergo ECT treatment, while Bracht et al. (2023) also included an MDD group who received Treatment As Usual (TAU) (Bracht et al., 2023). Regarding the ECT protocols, five studies used bilateral electrode placement (Gbyl et al., 2019; Ji et al., 2022; van Eijndhoven et al., 2016; Xu et al., 2019; Yroni et al., 2019), four studies used unilateral electrode placement (Gbyl et al., 2019; Gryglewski et al., 2019; Pirnia et al., 2016; Sartorius et al., 2016; Schmitgen et al., 2020; Wade et al., 2017). The study by Bracht et al. (2023) used mixed protocols: 17 patients started with right unilateral ECT, two patients with bitemporal ECT, and one patient with bifrontal stimulation (Bracht et al., 2023).

### *CT changes after ECT*

Most studies identified CT alterations in the temporal, insular and frontal areas, mainly proximally to the electrode (Fig. 3). Gryglewski et al. (2019) and Sartorius et al. (2016) combined voxel-based morphometry and CT analysis (Gryglewski et al., 2019; Sartorius et al., 2016). The first investigation reported a widespread increase in CT of the right hemisphere, including the insula,

supramarginal gyrus, inferior parietal gyrus, superior temporal gyrus, inferior temporal gyrus, superior temporal sulcus, temporal pole, postcentral gyrus and fusiform (Gryglewski et al., 2019). Similarly, Sartorius et al. (2016) found an increase in CT in the right temporal pole and the bilateral insula gyrus in MDD compared to HC (Sartorius et al., 2016). Van Eijndhoven et al. (2016) revealed large bilateral clusters of increased CT in TRD after ECT treatment extending from the temporal pole, middle and superior temporal gyrus to the insula, and inferior temporal gyrus in the left hemisphere. Post-hoc analyses demonstrated that the increase in CT of the insular cortex was greater in responders compared to non-responders to ECT. Notably, a higher number of ECT sessions was correlated with greater mean CT of the left temporal pole and the left middle and inferior temporal cortex (van Eijndhoven et al., 2016). Xu et al. (2019) calculated vertex-wise and regional CT within each of the 68 anatomically defined regions from the Desikan–Killiany Atlas in MDD (Xu et al., 2019). The authors reported a higher vertex-wise CT in the left temporal pole, left fusiform gyrus, left inferior parietal gyrus, left insula, as well as in the right lateral occipital gyrus, right supramarginal gyrus, right superior temporal gyrus, right insula and right precentral gyrus in patients with MDD after ECT. Furthermore, a greater regional CT was observed in the bilateral fusiform gyrus, bilateral parahippocampus, inferior temporal gyrus, left superior temporal gyrus, left inferior parietal gyrus, left insula, left superior temporal sulcus, right superior frontal gyrus and the right anterior rostral cingulate, as well as increased vertex-wise and regional CT in the left temporal pole, the fusiform gyrus and bilateral insula in MDD patients after ECT (Xu et al., 2019). Pirnia et al. (2016) and Yroni et al. (2019) to better delineate the course of CT changes during the entire ECT treatment, acquired an initial scan (T1), an intermediate scan between the first and the last ECT session (T2), and a scan within one week of the last ECT (T3) (Pirnia et al., 2016; Yroni et al., 2019). In the study of Yroni et al (2019), the second MRI was performed immediately after the first ECT was considered effective (Yroni et al., 2019). The researchers detected a significant increase in CT in the superior temporal gyrus in the patient group between baseline and time T3, between T2 and T3, but not between T1 and T2, suggesting that CT changes occur only after multiple ECT sessions. A post-hoc analysis revealed that, at baseline, MDD had thinner CT in the frontal lobe, in the fusiform gyrus, inferior, middle, and superior temporal gyri, parahippocampal gyrus, and the transverse temporal gyrus compared to HC. These differences were no longer significant after ECT (Yroni et al., 2019). In Pirnia et al. (2016), the second scan was performed within 48 hours after the second ECT treatment; CT became significantly thicker in the bilateral anterior cingulate cortex, the right parahippocampal gyrus, the superior temporal gyrus, and the temporal pole between T1 and T3 in patients with unipolar and bipolar depression. An additional ROI analysis showed significant effects of ECT in the anterior cingulate cortex, parahippocampal, entorhinal, superior temporal, inferior temporal, and fusiform cortex. To determine whether ECT

was associated with a normalization toward control values, differences in CT between patients and HC were examined at baseline across the whole cortex and in ROIs that showed significant effects of ECT. Within the cortical ROIs, at baseline, patients showed reduced CT in the fusiform and superior temporal cortex compared to HC, which was not present at the two subsequent time points (Pirnia et al., 2016). Gbyl et al. (2019) explored CT changes in MDD from baseline to six months after the last ECT, with an intermediate scan after the first ECT. They reported an increase in CT in 26 cortical regions, mainly within the frontal, temporal, and insular cortex immediately after the first series of ECT, which returned to baseline at six months of follow-up (Gbyl et al., 2019). A recent study by Bracht et al. (2023) compared longitudinal changes in CT between the ECT-treated group, treatment-as-usual (TAU) responders, and HC. Patients with unipolar and bipolar TRD were scanned twice, at the beginning and at the end of the ECT series, while patients with TAU were scanned at baseline and after achieving remission of depressive symptoms or within 12 weeks after the first MRI scan (Bracht et al., 2023). Global mean CT was increased in the right hemisphere in the ECT group and bilaterally in the TAU responders. Exploratory analyses revealed that CT changes common to the ECT group and TAU-responders included the right insula and the right lateral orbitofrontal cortex (Bracht et al., 2023). Another recent longitudinal study explored CT in 96 patients with MDD before and after ECT and reported CT increases in bilateral medial areas of the superior temporal gyrus and bilateral insula compared to baseline (Ji et al., 2022). Lastly, Schmitgen et al. (2020) investigated several surface-based measures in 12 patients with TRD and found no differences in CT relative to 12 HC and no longitudinal changes of this parameter in the group of patients before and after ECT (Schmitgen et al., 2020).

#### *Correlations between CT changes and clinical improvements*

Ten studies explored the correlations between CT changes and clinical improvements in depression measured with HAM-D between baseline and follow-up, and five reported a significant association. Gbyl et al. (2019) found a positive correlation between CT increases in the right lateral orbitofrontal gyrus and clinical improvement of depression (Gbyl et al., 2019). Similarly, positive correlations were observed between changes in CT in the fusiform, superior and inferior temporal gyrus and clinical improvement in depression (Pirnia et al., 2016); in particular, CT of the anterior cingulate cortex increased shortly (T1 and T2) after the initiation of ECT treatment and was predictive of the general clinical response (>50% improvement in HAM-D scores) to ECT. In van Eijndhoven et al. (2016), increased mean CT of the right insula was associated with clinical improvement in depressive symptoms (van Eijndhoven et al., 2016). Schmitgen et al. (2020) observed that pre- and post-ECT CT of the left rostral anterior cingulate gyrus predicted a greater improvement in depression. Furthermore, they also found a correlation between clinical improvement and increased



CT of the left medial orbitofrontal gyrus after but not before ECT treatment, suggesting a mediator role of cortical changes in this region (Schmitgen et al., 2020). Lastly, Xu et al. (2019) reported a correlation between vertex-wise CT increases in the left occipital gyrus and the improvement of depression. Furthermore, to test the brain mechanisms of tolerability of ECT, the authors explored the association between cognitive functions and CT changes. In particular, ECT-dependent memory impairments measured by Auditory Verbal Learning Test (ALVT) delayed recall scores were negatively correlated with CT increase in the left inferior parietal gyrus and marginally in the right precentral gyrus after ECT treatment (Xu et al., 2019).

## **Discussion**

This review summarized the evidence on CT changes associated with ECT among patients with depression. We found that ECT was associated with a widespread increase in CT in patients with depression, located primarily in the temporal lobe and insula cortex and, to a lesser extent, in the frontal areas. Some studies showed a correlation between increases in CT and clinical improvement.

### *Temporal lobe*

Most of the reviewed studies found that ECT was followed by increased CT in the temporal lobe, including the superior, middle, and inferior temporal gyri and temporal pole (Gbyl et al., 2019; Gryglewski et al., 2019; Ji et al., 2022; Pirnia et al., 2016; Sartorius et al., 2016; van Eijndhoven et al., 2016; Xu et al., 2019; Yroni et al., 2019). Although most increases were observed near the placement of the electrodes, temporal changes were also observed when the electrodes were located in the frontal lobe (Ji et al., 2022; Xu et al., 2019). Importantly, ECT has two main therapeutic components: seizure activity and electric perturbation due to an induced electric field (Fridgeirsson et al., 2021). The initial idea that the main benefits of ECT came from induced seizures has been disputed, given the evidence that increasing the strength of the electric field can affect the clinical effectiveness of ECT, without affecting the characteristics of the seizure (Argyelan et al., 2019). Notably, current literature suggests that greater intensity of the electric field may be associated with greater neuronal plasticity after treatment (Argyelan et al., 2019). In this regard, animal studies have shown that electroconvulsive seizures stimulate dendritic arborization, synaptic density, and glial proliferation (Maynard et al., 2018; Ongür et al., 2007). This may be a consequence of the increased expression and release of brain-derived neurotrophic factor induced by ECT (Polyakova et al., 2015), which could ultimately be the basis for the therapeutic efficacy of ECT. However, whether the efficacy of ECT is related to the electric field or the resulting seizure, or both, remains a debated matter (Deng et al., 2023). The temporal lobe plays a crucial role in the pathophysiology of

depression, as it is involved in the core neuropsychological features that are commonly disrupted in MDD and bipolar depression, including emotional processing and social cognition (Gillissie et al., 2022; Takahashi et al., 2010). Interestingly, cortical abnormalities in the temporal lobe have been commonly described in MDD and BD (Hibar et al., 2018; Schmaal et al., 2017). Furthermore, an accumulating body of evidence shows that the neurobiology of depression involves structural and functional dysfunctions in the corticolimbic network, particularly in the temporal lobe, hippocampus, and amygdala (Tassone et al., 2022; Zhong et al., 2016). Recently, Leaver et al. (2022) hypothesized a “network mechanism” of ECT, according to which seizures originating from the middle temporal lobe improve depressive symptoms by correcting or resetting corticolimbic alterations (Leaver et al., 2022). It has been suggested that the increase in temporal CT after ECT could be due to brain damage, including reactive inflammation or edema due to the electrical current near the site of electrode application (Coffey et al., 1991); thus, an increase in temporal CT after ECT could be considered a transient epiphenomenon of treatment, rather than a mechanism underlying its efficacy (Puri et al., 1998). However, although some accumulation of extracellular fluid has been observed using diffusion tensor imaging (Repple et al., 2020), most studies have not detected post-ECT gliosis or brain edema (Szabo et al., 2007), and specific studies, using T2-relaxometry to detect significant fluid shifts, did not support edema as a cause of structural changes detected after ECT (Girish et al., 2001; Kunigiri et al., 2007; Yrondi et al., 2018). Furthermore, a systematic review and meta-analysis of the effects of ECT on brain volumes (Gbyl and Videbech, 2018) did not support the theory of brain damage and did not find an increase in brain damage markers (Agelink et al., 2001; Kranaster et al., 2014; Zachrisson et al., 2000). These findings were confirmed by Gylb et al. (2022), who found no differences in serum S100B, a marker of brain injury, after an ECT series (Gbyl et al., 2022). Crucially, cortical thickening in the temporal lobe in MDD has been previously reported in association with antidepressant drug treatment (Nemati and Abdallah, 2020), suggesting that these effects could be a common mechanism underlying the effectiveness of antidepressant treatments. Consistent with the theories of neurotrophic and neuroplasticity of depression (Duman and Li, 2012), the observed changes in CT during ECT treatment may be the result of underlying increased neural growth, synaptogenesis, and synaptic rearrangement. This is consistent with an increase in neurotrophins after ECT [62]. Nonetheless, further confirmation is needed through randomized studies.

Increased CT in the superior and inferior temporal gyrus was associated with an improvement in depressive symptoms only in one study (Pirmia et al., 2016). Furthermore, Gbyl et al. (2019) observed that although CT in the temporal lobe increased after the first ECT, it returned to baseline after six months, even if the antidepressant effect persisted (Bolwig, 2011).

Taken together, this evidence suggests that temporal CT is primarily affected by ECT, regardless of electrode placement. Less clear is the role of temporal CT changes in clinical improvements. Although most investigations showed that changes in CT did not correlate with clinical symptoms, this was not replicated in all included studies. Therefore, more evidence is needed to clarify the role of temporal CT in changes in depressive symptoms.

### *Insula*

Seven investigations reported an increase in CT in the insula after ECT (Bracht et al., 2023; Gbyl et al., 2019; Gryglewski et al., 2019; Ji et al., 2022; Pirnia et al., 2016; Sartorius et al., 2016; van Eijndhoven et al., 2016; Xu et al., 2019). Previous literature has shown that the insula contributes to emotion regulation and pain perception and is also involved in the pathophysiology of MDD and bipolar depression (Nagai et al., 2007; Qiu et al., 2020; Schmaal et al., 2017; Sprengelmeyer et al., 2011). A study showed a correlation between cortical thickening in this region and reduced severity of depression (van Eijndhoven et al., 2016). In particular, Bracht et al. (2023) found an increase in CT in the right insula in both ECT and TAU responders, suggesting a potential role for CT as a marker of treatment response, which may not be specific for ECT (Bracht et al., 2023). In addition, recent evidence has shown that insular metabolic activity may represent a potential predictive biomarker of remission in MDD after treatment with antidepressants or psychotherapy (Kelley et al., 2021). Overall, this literature suggests that structural and functional insular neuroimaging abnormalities may play a role as biomarkers of antidepressant effects and predictive biomarkers of symptom remission, regardless of the type of treatment. In summary, the study results suggest that although ECT is associated with an increase in insular CT, the improvement in depression symptoms after ECT does not appear to be associated with CT changes in the insula.

### *Frontal lobe*

The frontal lobe, in particular the OFC, the superior, middle, and inferior frontal gyrus, have been consistently implicated in the pathophysiology of unipolar and bipolar depression (Altshuler et al., 2008; Drevets, 2007; Fitzgerald et al., 2008). Three of the ten studies included in the present review showed cortical thickening in these areas (Bracht et al., 2023; Gbyl et al., 2019; Xu et al., 2019) and, interestingly, only in the study by Xu et al. (2019) the electrodes were localized in the frontal lobe. Remarkably, Gbyl et al. (2019) reported a strong association between cortical thickening of the right lateral OFC and the antidepressant effect of ECT (Gbyl et al., 2019; Schmitgen et al., 2020). In depression, a reduced volume along with altered activity in OFC has previously been reported (Drevets, 2007). A recent study showed that direct stimulation of this region produced an acute

improvement in depressive symptoms in epileptic subjects with moderate to severe depression (Rao et al., 2018). Noticeably, OFC CT increased immediately after the ECT series but returned to baseline levels at six months of follow-up, despite the continued antidepressant effect, suggesting that the persistence of the clinical efficacy of ECT was not related to orbitofrontal CT. Interestingly, a recent GEMRIC consortium study identified a multivariate discriminative pattern of volume alterations in the cortical midline, striatal, and lateral prefrontal areas that differentiated responders from non-responders, suggesting that structural changes in prefrontal areas might play a role in the clinical response to ECT (Mulders et al., 2020).

#### *Other brain areas*

ECT was associated with cortical thickening in several other areas, including the ACC, the parahippocampal gyrus, the entorhinal cortex, the fusiform gyrus, the superior and inferior parietal gyrus, the pre- and postcentral gyrus, and the lateral occipital gyrus. Although all these areas have been consistently implicated in the pathogenesis of unipolar and bipolar depression and appear to be influenced by antidepressant treatments (Bartlett et al., 2018; Klimes-Dougan et al., 2018; Yi et al., 2022), only increased CT in the right lateral occipital gyrus, an area involved in the perception of the face and emotion (Nagy et al., 2012), was associated with clinical improvement (Xu et al., 2019).

#### *Biological significance of CT findings*

Cortical thickening has been previously reported in patients with depression after antidepressant medications (Bartlett et al., 2018; Koenig et al., 2018; Krause-Sorio et al., 2020) and neurostimulation treatments (Dalhuisen et al., 2021; Phillips et al., 2015; Wu et al., 2022), suggesting that cortical changes may not be specifically associated with ECT, but rather represent a generally shared mechanism of effectiveness of various antidepressant treatments. Surprisingly, however, both pretreatment CT and the early increase in CT seem to represent predictive biomarkers of the clinical response to antidepressants (Phillips et al., 2015) suggesting that various processes can underlie its clinical effectiveness. Neuroplasticity, including the processes of neurogenesis, synaptogenesis, dendrogenesis, gliogenesis, and angiogenesis, has been hypothesised to be the biological mechanism for the effects of ECT on CT (Hellsten et al., 2005; Jaggar et al., 2023; Wennström et al., 2004; Zhang et al., 2023). In particular, animal studies have reported that rats subjected to electroconvulsive stimulation show increased genesis of hippocampal neurons with the potential for long-term survival (Altar et al., 2003; Madsen et al., 2005; Olesen et al., 2017). In humans, ECT is associated with a rapid and widespread increase in gray matter volume in the post-

treatment phase (Ousdal et al., 2020), as well as an increased brain-derived neurotrophic factor (BDNF) and vascular endothelial growth factor (VEGF) (Sorri et al., 2021; Vanicek et al., 2019). However, the promptness of these volumetric changes suggests that neurogenesis is unlikely to be the only mediating factor for the volumetric effects of ECT (Ousdal et al., 2022). Taking into account this evidence, Ousdal et al. (2022) conceptualized a time-dependent model of the neural effects of ECT that includes three consecutive phases: disruption as the immediate effect, increased neuroplasticity as the short-term effect, and rewiring as the long-term effect (Ousdal et al., 2022). Most of the studies included in our review examined the short-term mechanisms of ECT. The only study that evaluated the long-term effects of ECT reported that CT returned to baseline levels after 6 months (Gbyl et al., 2019), suggesting that CT may not be suitable to detect potential “rewiring” effects. Importantly, the findings of broad cortical thickening after ECT are in line with volumetric studies (Ousdal et al., 2022). Interestingly, two of the included studies explored Gray Matter Volume (and CT (Gryglewski et al., 2019; Sartorius et al., 2016). Although regional structural changes following ECT were detected by both types of measures, they showed different patterns, suggesting that each measure could reflect specific histological changes. We hypothesize that CT can be more sensitive in detecting changes associated with brain atrophy (Lemaitre et al., 2012) compared to gray matter volume morphometry, that can better measure neuroplasticity and rewiring processes after electrical stimulation (Argyelan et al., 2019). Therefore, structural measures may provide complementary information that could help to understand the mechanisms underlying the differential changes in the brain across the cortical regions after ECT.

#### *Limitations and conclusions*

The findings of this review should be interpreted in light of the limitations of primary studies. First, only six studies had a control group, and not all studies reported baseline differences in CT between patients and HC. In addition, most studies did not have a randomized design, thus reducing the strength of evidence supporting a causal link between ECT and changes in CT. Furthermore, the sample sizes were relatively small. Second, concurrent medications (e.g., antidepressants) could also have contributed to CT changes, and this effect could only be estimated in the few controlled studies. Third, the different clinical phenotypes of the participants (e.g., comorbidities, illness phase, duration of the illness) may have contributed to the heterogeneity of the results. In addition, two studies also included individuals with bipolar depression, which may have affected the results. Fourth, in this literature, the sex-related difference in CT changes after ECT was not investigated, and this could be due to the lack of evidence of sex differences in CT in depression. Lastly, the

heterogeneity in the positioning of the electrodes during the administration of the ECT may have also influenced CT results.

In conclusion, available studies lend support to the hypothesis that ECT in depression is associated with cortical thickening of the temporal lobe, insula, and, to a lesser extent, frontal lobe, and several other areas of the brain involved in the pathophysiology of depression. These findings are consistent with evidence of increased CT after pharmacological and neuromodulation treatments, suggesting that cortical changes may not be specific to ECT, but rather reflect mechanisms of therapeutic response. Future studies with a randomized design, longer follow-up periods, and multiple methodologies of assessment of morphologic changes are warranted to increase knowledge of the effectiveness of ECT. Such studies may also clarify the potential role of CT and other cortical measures, including surface area, gyrification, and cortical complexity, as biomarkers of the clinical response in depression.

### **Conflict of Interest**

None.

### **Acknowledgments**

None.

### **Role of the Funding Source**

GC was supported by a grant from Cassa di Risparmio di Padova e Rovigo (CARIPARO).

## References

- Agelink, M.W., Andrich, J., Postert, T., Würzinger, U., Zeit, T., Klotz, P., Przuntek, H., 2001. Relation between electroconvulsive therapy, cognitive side effects, neuron specific enolase, and protein S-100. *J. Neurol. Neurosurg. Psychiatry* 71, 394–396. <https://doi.org/10.1136/jnnp.71.3.394>
- Altar, C.A., Whitehead, R.E., Chen, R., Wörtwein, G., Madsen, T.M., 2003. Effects of electroconvulsive seizures and antidepressant drugs on brain-derived neurotrophic factor protein in rat brain. *Biol. Psychiatry* 54, 703–709. [https://doi.org/10.1016/S0006-3223\(03\)00073-8](https://doi.org/10.1016/S0006-3223(03)00073-8)
- Altshuler, L., Bookheimer, S., Townsend, J., Proenza, M.A., Sabb, F., Mintz, J., Cohen, M.S., 2008. Regional brain changes in bipolar I depression: a functional magnetic resonance imaging study. *Bipolar Disord.* 10, 708–717. <https://doi.org/10.1111/j.1399-5618.2008.00617.x>
- Argyelan, M., Oltedal, L., Deng, Z.-D., Wade, B., Bikson, M., Joanlanne, A., Sanghani, S., Bartsch, H., Cano, M., Dale, A.M., Dannlowski, U., Dols, A., Enneking, V., Espinoza, R., Kessler, U., Narr, K.L., Oedegaard, K.J., Oudega, M.L., Redlich, R., Stek, M.L., Takamiya, A., Emsell, L., Bouckaert, F., Sienaert, P., Pujol, J., Tendolkar, I., van Eijndhoven, P., Petrides, G., Malhotra, A.K., Abbott, C., 2019. Electric field causes volumetric changes in the human brain. *eLife* 8, e49115. <https://doi.org/10.7554/eLife.49115>
- Bahji, A., Hawken, E.R., Sepehry, A.A., Cabrera, C.A., Vazquez, G., 2019. ECT beyond unipolar major depression: systematic review and meta-analysis of electroconvulsive therapy in bipolar depression. *Acta Psychiatr. Scand.* 139, 214–226. <https://doi.org/10.1111/acps.12994>
- Bartlett, E.A., DeLorenzo, C., Sharma, P., Yang, J., Zhang, M., Petkova, E., Weissman, M., McGrath, P.J., Fava, M., Ogden, R.T., Kurian, B.T., Malchow, A., Cooper, C.M., Trombello, J.M., McInnis, M., Adams, P., Oquendo, M.A., Pizzagalli, D.A., Trivedi, M., Parsey, R.V., 2018. Pretreatment and early-treatment cortical thickness is associated with SSRI treatment response in major depressive disorder. *Neuropsychopharmacol. Off. Publ. Am. Coll. Neuropsychopharmacol.* 43, 2221–2230. <https://doi.org/10.1038/s41386-018-0122-9>
- Boedhoe, P.S.W., Schmaal, L., Abe, Y., Alonso, P., Ameis, S.H., Anticevic, A., Arnold, P.D., Batistuzzo, M.C., Benedetti, F., Beucke, J.C., Bollettini, I., Bose, A., Brem, S., Calvo, A., Calvo, R., Cheng, Y., Cho, K.I.K., Ciullo, V., Dallaspezia, S., Denys, D., Feusner, J.D., Fitzgerald, K.D., Fouche, J.-P., Fridgeirsson, E.A., Gruner, P., Hanna, G.L., Hibar, D.P., Hoexter, M.Q., Hu, H., Huyser, C., Jahanshad, N., James, A., Kathmann, N., Kaufmann, C., Koch, K., Kwon, J.S., Lazaro, L., Lochner, C., Marsh, R., Martínez-Zalacáin, I., Mataix-Cols, D., Menchón, J.M., Minuzzi, L., Morer, A., Nakamae, T., Nakao, T., Narayanaswamy, J.C., Nishida, S., Nurmi, E., O'Neill, J., Piacentini, J., Piras, Fabrizio, Piras, Federica, Reddy, Y.C.J., Reess, T.J., Sakai, Y., Sato, J.R., Simpson, H.B., Soreni, N., Soriano-Mas, C., Spalletta, G., Stevens, M.C., Szeszko, P.R., Tolin, D.F., van Wingen, G.A., Venkatasubramanian, G., Walitza, S., Wang, Z., Yun, J.-Y., ENIGMA-OCD Working Group, Thompson, P.M., Stein, D.J., van den Heuvel, O.A., ENIGMA OCD Working Group, 2018. Cortical Abnormalities Associated With Pediatric and Adult Obsessive-Compulsive Disorder: Findings From the ENIGMA Obsessive-Compulsive Disorder Working Group. *Am. J. Psychiatry* 175, 453–462. <https://doi.org/10.1176/appi.ajp.2017.17050485>
- Bolwig, T.G., 2011. How does electroconvulsive therapy work? Theories on its mechanism. *Can. J. Psychiatry Rev. Can. Psychiatr.* 56, 13–18. <https://doi.org/10.1177/070674371105600104>
- Bracht, T., Walther, S., Breit, S., Mertse, N., Federspiel, A., Meyer, A., Soravia, L.M., Wiest, R., Denier, N., 2023. Distinct and shared patterns of brain plasticity during electroconvulsive therapy and treatment as usual in depression: an observational multimodal MRI-study. *Transl. Psychiatry* 13, 1–8. <https://doi.org/10.1038/s41398-022-02304-2>
- Coffey, C.E., Weiner, R.D., Djang, W.T., Figiel, G.S., Soady, S.A., Patterson, L.J., Holt, P.D., Spritzer, C.E., Wilkinson, W.E., 1991. Brain anatomic effects of electroconvulsive therapy. *A*

- prospective magnetic resonance imaging study. *Arch. Gen. Psychiatry* 48, 1013–1021. <https://doi.org/10.1001/archpsyc.1991.01810350053008>
- Dalhuisen, I., Ackermans, E., Martens, L., Mulders, P., Bartholomeus, J., de Bruijn, A., Spijker, J., van Eijndhoven, P., Tendolkar, I., 2021. Longitudinal effects of rTMS on neuroplasticity in chronic treatment-resistant depression. *Eur. Arch. Psychiatry Clin. Neurosci.* 271, 39–47. <https://doi.org/10.1007/s00406-020-01135-w>
- Deng, Z.-D., Robins, P.L., Regenold, W., Rohde, P., Dannhauer, M., Lisanby, S.H., 2023. How electroconvulsive therapy works in the treatment of depression: is it the seizure, the electricity, or both? *Neuropsychopharmacology* 1–13. <https://doi.org/10.1038/s41386-023-01677-2>
- Drevets, W.C., 2007. Orbitofrontal cortex function and structure in depression. *Ann. N. Y. Acad. Sci.* 1121, 499–527. <https://doi.org/10.1196/annals.1401.029>
- Duman, R.S., Heninger, G.R., Nestler, E.J., 1997. A molecular and cellular theory of depression. *Arch. Gen. Psychiatry* 54, 597–606. <https://doi.org/10.1001/archpsyc.1997.01830190015002>
- Duman, R.S., Li, N., 2012. A neurotrophic hypothesis of depression: role of synaptogenesis in the actions of NMDA receptor antagonists. *Philos. Trans. R. Soc. B Biol. Sci.* 367, 2475–2484. <https://doi.org/10.1098/rstb.2011.0357>
- Fitzgerald, P.B., Laird, A.R., Maller, J., Daskalakis, Z.J., 2008. A meta-analytic study of changes in brain activation in depression. *Hum. Brain Mapp.* 29, 683–695. <https://doi.org/10.1002/hbm.20426>
- Fornaro, M., Carvalho, A.F., Fusco, A., Anastasia, A., Solmi, M., Berk, M., Sim, K., Vieta, E., de Bartolomeis, A., 2020. The concept and management of acute episodes of treatment-resistant bipolar disorder: a systematic review and exploratory meta-analysis of randomized controlled trials. *J. Affect. Disord.* 276, 970–983. <https://doi.org/10.1016/j.jad.2020.07.109>
- Fridgeirsson, E.A., Deng, Z.-D., Denys, D., van Waarde, J.A., van Wingen, G.A., 2021. Electric field strength induced by electroconvulsive therapy is associated with clinical outcome. *NeuroImage Clin.* 30, 102581. <https://doi.org/10.1016/j.nicl.2021.102581>
- Gazdag, G., Ungvari, G.S., 2019. Electroconvulsive therapy: 80 years old and still going strong. *World J. Psychiatry* 9, 1–6. <https://doi.org/10.5498/wjp.v9.i1.1>
- Gbyl, K., Jørgensen, N.R., Videbech, P., 2022. Serum S100B protein after electroconvulsive therapy in patients with depression. *Acta Neuropsychiatr.* 34, 269–275. <https://doi.org/10.1017/neu.2022.8>
- Gbyl, K., Rostrup, E., Raghava, J.M., Carlsen, J.F., Schmidt, L.S., Lindberg, U., Ashraf, A., Jørgensen, M.B., Larsson, H.B.W., Rosenberg, R., Videbech, P., 2019. Cortical thickness following electroconvulsive therapy in patients with depression: a longitudinal MRI study. *Acta Psychiatr. Scand.* 140, 205–216. <https://doi.org/10.1111/acps.13068>
- Gbyl, K., Videbech, P., 2018. Electroconvulsive therapy increases brain volume in major depression: a systematic review and meta-analysis. *Acta Psychiatr. Scand.* 138, 180–195. <https://doi.org/10.1111/acps.12884>
- Gillissie, E.S., Lui, L.M.W., Ceban, F., Miskowiak, K., Gok, S., Cao, B., Teopiz, K.M., Ho, R., Lee, Y., Rosenblat, J.D., McIntyre, R.S., 2022. Deficits of social cognition in bipolar disorder: Systematic review and meta-analysis. *Bipolar Disord.* 24, 137–148. <https://doi.org/10.1111/bdi.13163>
- Girish, K., Jayakumar, P.N., Murali, N., Gangadhar, B.N., Janakiramaiah, N., Subbakrishna, D.K., 2001. ECT AND T2 RELAXOMETRY: A STATIC WALTER PROTON MAGNETIC RESONANCE IMAGING STUDY. *Indian J. Psychiatry* 43, 22–24.
- Gryglewski, G., Baldinger-Melich, P., Seiger, R., Godbersen, G.M., Michenthaler, P., Klöbl, M., Spurny, B., Kautzky, A., Vanicek, T., Kasper, S., Frey, R., Lanzenberger, R., 2019. Structural changes in amygdala nuclei, hippocampal subfields and cortical thickness following electroconvulsive therapy in treatment-resistant depression: longitudinal analysis. *Br. J. Psychiatry J. Ment. Sci.* 214, 159–167. <https://doi.org/10.1192/bjp.2018.224>
- Hamilton, M., 1960. A rating scale for depression. *J. Neurol. Neurosurg. Psychiatry* 23, 56–62. <https://doi.org/10.1136/jnnp.23.1.56>



- Hellsten, J., West, M.J., Arvidsson, A., Ekstrand, J., Jansson, L., Wennström, M., Tingström, A., 2005. Electroconvulsive seizures induce angiogenesis in adult rat hippocampus. *Biol. Psychiatry* 58, 871–878. <https://doi.org/10.1016/j.biopsych.2005.05.023>
- Hibar, D.P., Westlye, L.T., Doan, N.T., Jahanshad, N., Cheung, J.W., Ching, C.R.K., Versace, A., Bilderbeck, A.C., Uhlmann, A., Mwangi, B., Krämer, B., Overs, B., Hartberg, C.B., Abé, C., Dima, D., Grotegerd, D., Sprooten, E., Bøen, E., Jimenez, E., Howells, F.M., Delvecchio, G., Temmingh, H., Starke, J., Almeida, J.R.C., Goikolea, J.M., Houenou, J., Beard, L.M., Rauer, L., Abramovic, L., Bonnin, M., Ponteduro, M.F., Keil, M., Rive, M.M., Yao, N., Yalin, N., Najt, P., Rosa, P.G., Redlich, R., Trost, S., Hagenaars, S., Fears, S.C., Alonso-Lana, S., van Erp, T.G.M., Nickson, T., Chaim-Avancini, T.M., Meier, T.B., Elvsåshagen, T., Haukvik, U.K., Lee, W.H., Schene, A.H., Lloyd, A.J., Young, A.H., Nugent, A., Dale, A.M., Pfenning, A., McIntosh, A.M., Lafer, B., Baune, B.T., Ekman, C.J., Zarate, C.A., Bearden, C.E., Henry, C., Simhandl, C., McDonald, C., Bourne, C., Stein, D.J., Wolf, D.H., Cannon, D.M., Glahn, D.C., Veltman, D.J., Pomarol-Clotet, E., Vieta, E., Canales-Rodriguez, E.J., Nery, F.G., Duran, F.L.S., Busatto, G.F., Roberts, G., Pearlson, G.D., Goodwin, G.M., Kugel, H., Whalley, H.C., Ruhe, H.G., Soares, J.C., Fullerton, J.M., Rybakowski, J.K., Savitz, J., Chaim, K.T., Fatjó-Vilas, M., Soeiro-de-Souza, M.G., Boks, M.P., Zanetti, M.V., Otaduy, M.C.G., Schaufelberger, M.S., Alda, M., Ingvar, M., Phillips, M.L., Kempton, M.J., Bauer, M., Landén, M., Lawrence, N.S., van Haren, N.E.M., Horn, N.R., Freimer, N.B., Gruber, O., Schofield, P.R., Mitchell, P.B., Kahn, R.S., Lenroot, R., Machado-Vieira, R., Ophoff, R.A., Sarró, S., Frangou, S., Satterthwaite, T.D., Hajek, T., Dannlowski, U., Malt, U.F., Arolt, V., Gattaz, W.F., Drevets, W.C., Caseras, X., Agartz, I., Thompson, P.M., Andreassen, O.A., 2018. Cortical abnormalities in bipolar disorder: an MRI analysis of 6503 individuals from the ENIGMA Bipolar Disorder Working Group. *Mol. Psychiatry* 23, 932–942. <https://doi.org/10.1038/mp.2017.73>
- Hoogman, M., Muetzel, R., Guimaraes, J.P., Shumskaya, E., Mennes, M., Zwiers, M.P., Jahanshad, N., Sudre, G., Wolfers, T., Earl, E.A., Soliva Vila, J.C., Vives-Gilabert, Y., Khadka, S., Novotny, S.E., Hartman, C.A., Heslenfeld, D.J., Schweren, L.J.S., Ambrosino, S., Oranje, B., de Zeeu, P., Chaim-Avancini, T.M., Rosa, P.G.P., Zanetti, M.V., Malpas, C.B., Kohls, G., von Polier, G.G., Seitz, J., Biederman, J., Doyle, A.E., Dale, A.M., van Erp, T.G.M., Epstein, J.N., Jernigan, T.L., Baur-Streubel, R., Ziegler, G.C., Zierhut, K.C., Schranke, A., Høvik, M.F., Lundervold, A.J., Kelly, C., McCarthy, H., Skokauskas, N., O’Gorman Tuura, R.L., Calvo, A., Lera-Miguel, S., Nicolau, R., Chantiluke, K.C., Christakou, A., Vance, A., Cercignani, M., Gabel, M.C., Asherson, P., Baumeister, S., Brandeis, D., Hohmann, S., Bramati, I.E., Tovar-Moll, F., Fallgatter, A.J., Kardatzki, B., Schwarz, L., Anikin, A., Baranov, A., Gogberashvili, T., Kapilushniy, D., Solovieva, A., El Marroun, H., White, T., Karkashadze, G., Namazova-Baranova, L., Ethofer, T., Mattos, P., Banaschewski, T., Coghill, D., Plessen, K.J., Kuntsi, J., Mehta, M.A., Paloyelis, Y., Harrison, N.A., Bellgrove, M.A., Silk, T.J., Cubillo, A.I., Rubia, K., Lazaro, L., Brem, S., Walitza, S., Frodl, T., Zentis, M., Castellanos, F.X., Yoncheva, Y.N., Haavik, J., Reneman, L., Conzelmann, A., Lesch, K.-P., Pauli, P., Reif, A., Tamm, L., Konrad, K., Weiss, E.O., et al, 2019. Brain imaging of the cortex in ADHD: A coordinated analysis of large-scale clinical and population-based samples. *Am. J. Psychiatry* 176, 531–542. <https://doi.org/10.1176/appi.ajp.2019.18091033>
- Jaggar, M., Ghosh, S., Janakiraman, B., Chatterjee, A., Maheshwari, M., Dewan, V., Hare, B., Deb, S., Figueiredo, D., Duman, R.S., Vaidya, V.A., 2023. Influence of Chronic Electroconvulsive Seizures on Plasticity-Associated Gene Expression and Perineuronal Nets Within the Hippocampi of Young Adult and Middle-Aged Sprague-Dawley Rats. *Int. J. Neuropsychopharmacol.* 26, 294–306. <https://doi.org/10.1093/ijnp/pyad008>
- Järnum, H., Eskildsen, S.F., Steffensen, E.G., Lundbye-Christensen, S., Simonsen, C.W., Thomsen, I.S., Fründ, E.-T., Théberge, J., Larsson, E.-M., 2011. Longitudinal MRI study of cortical thickness, perfusion, and metabolite levels in major depressive disorder. *Acta Psychiatr. Scand.* 124, 435–446. <https://doi.org/10.1111/j.1600-0447.2011.01766.x>

- Ji, G.-J., Li, J., Liao, W., Wang, Y., Zhang, L., Bai, T., Zhang, T., Xie, W., He, K., Zhu, C., Dukart, J., Baeken, C., Tian, Y., Wang, K., 2022. Neuroplasticity-Related Genes and Dopamine Receptors Associated with Regional Cortical Thickness Increase Following Electroconvulsive Therapy for Major Depressive Disorder. *Mol. Neurobiol.* 60, 3. <https://doi.org/10.1007/s12035-022-03132-7>
- Kadiyala, P.K., Kadiyala, L.D., 2018. ECT: a new look at an old friend. *Curr. Opin. Anaesthesiol.* 31, 453–458. <https://doi.org/10.1097/ACO.0000000000000615>
- Kelley, M.E., Choi, K.S., Rajendra, J.K., Craighead, W.E., Rakofsky, J.J., Dunlop, B.W., Mayberg, H.S., 2021. Establishing Evidence for Clinical Utility of a Neuroimaging Biomarker in Major Depressive Disorder: Prospective Testing and Implementation Challenges. *Biol. Psychiatry* 90, 236–242. <https://doi.org/10.1016/j.biopsych.2021.02.966>
- Kellner, C.H., Obbels, J., Sienaert, P., 2020. When to consider electroconvulsive therapy (ECT). *Acta Psychiatr. Scand.* 141, 304–315. <https://doi.org/10.1111/acps.13134>
- Kempton, M.J., Salvador, Z., Munafò, M.R., Geddes, J.R., Simmons, A., Frangou, S., Williams, S.C.R., 2011. Structural Neuroimaging Studies in Major Depressive Disorder: Meta-analysis and Comparison With Bipolar Disorder. *Arch. Gen. Psychiatry* 68, 675–690. <https://doi.org/10.1001/archgenpsychiatry.2011.60>
- Kho, K.H., van Vreeswijk, M.F., Simpson, S., Zwinderman, A.H., 2003. A Meta-Analysis of Electroconvulsive Therapy Efficacy in Depression. *J. ECT* 19, 139.
- Klimes-Dougan, B., Westlund Schreiner, M., Thai, M., Gunlicks-Stoessel, M., Reigstad, K., Cullen, K.R., 2018. Neural and neuroendocrine predictors of pharmacological treatment response in adolescents with depression: A preliminary study. *Prog. Neuropsychopharmacol. Biol. Psychiatry* 81, 194–202. <https://doi.org/10.1016/j.pnpbp.2017.10.015>
- Koenig, J., Westlund Schreiner, M., Klimes-Dougan, B., Ubani, B., Mueller, B.A., Lim, K.O., Kaess, M., Cullen, K.R., 2018. Increases in orbitofrontal cortex thickness following antidepressant treatment are associated with changes in resting state autonomic function in adolescents with major depression – Preliminary findings from a pilot study. *Psychiatry Res. Neuroimaging* 281, 35–42. <https://doi.org/10.1016/j.psychres.2018.08.013>
- Koolschijn, P.C.M.P., van Haren, N.E.M., Lensvelt-Mulders, G.J.L.M., Hulshoff Pol, H.E., Kahn, R.S., 2009. Brain volume abnormalities in major depressive disorder: A meta-analysis of magnetic resonance imaging studies. *Hum. Brain Mapp.* 30, 3719–3735. <https://doi.org/10.1002/hbm.20801>
- Kranaster, L., Janke, C., Mindt, S., Neumaier, M., Sartorius, A., 2014. Protein S-100 and neuron-specific enolase serum levels remain unaffected by electroconvulsive therapy in patients with depression. *J. Neural Transm. Vienna Austria* 1996 121, 1411–1415. <https://doi.org/10.1007/s00702-014-1228-9>
- Krause-Sorio, B., Kilpatrick, L., Siddarth, P., Ercoli, L., Laird, K.T., Aguilar-Faustino, Y., Milillo, M.M., Narr, K.L., Lavretsky, H., 2020. Cortical thickness increases with levomilnacipran treatment in a pilot randomised double-blind placebo-controlled trial in late-life depression. *Psychogeriatrics* 20, 140–148. <https://doi.org/10.1111/psyg.12475>
- Kunigiri, G., Jayakumar, P.N., Janakiramaiah, N., Gangadhar, B.N., 2007. MRI T2 relaxometry of brain regions and cognitive dysfunction following electroconvulsive therapy. *Indian J. Psychiatry* 49, 195. <https://doi.org/10.4103/0019-5545.37321>
- Leaver, A.M., Espinoza, R., Wade, B., Narr, K.L., 2022. Parsing the Network Mechanisms of Electroconvulsive Therapy. *Biol. Psychiatry* 92, 193–203. <https://doi.org/10.1016/j.biopsych.2021.11.016>
- Lemaitre, H., Goldman, A., Sambataro, F., Verchinski, B., Meyer-Lindenberg, A., Weinberger, D., Mattay, V., 2012. Normal age-related brain morphometric changes: Nonuniformity across cortical thickness, surface area and grey matter volume? *Neurobiol. Aging* 33, 617.e1-617.e9. <https://doi.org/10.1016/j.neurobiolaging.2010.07.013>
- Liberati, A., Altman, D.G., Tetzlaff, J., Mulrow, C., Gøtzsche, P.C., Ioannidis, J.P.A., Clarke, M., Devereaux, P.J., Kleijnen, J., Moher, D., 2009. The PRISMA statement for reporting

- systematic reviews and meta-analyses of studies that evaluate healthcare interventions: explanation and elaboration. *BMJ* 339, b2700. <https://doi.org/10.1136/bmj.b2700>
- Lim, H.K., Jung, W.S., Ahn, K.J., Won, W.Y., Hahn, C., Lee, S.Y., Kim, I., Lee, C.U., 2012. Regional cortical thickness and subcortical volume changes are associated with cognitive impairments in the drug-naïve patients with late-onset depression. *Neuropsychopharmacol. Off. Publ. Am. Coll. Neuropsychopharmacol.* 37, 838–849. <https://doi.org/10.1038/npp.2011.264>
- Mackin, R.S., Tosun, D., Mueller, S.G., Lee, J.-Y., Insel, P., Schuff, N., Truran-Sacrey, D., Arean, P., Nelson, J.C., Weiner, M.W., 2013. Patterns of Reduced Cortical Thickness in Late-Life Depression and Relationship to Psychotherapeutic Response. *Am. J. Geriatr. Psychiatry* 21, 794–802. <https://doi.org/10.1016/j.jagp.2013.01.013>
- Madsen, T.M., Yeh, D.D., Valentine, G.W., Duman, R.S., 2005. Electroconvulsive seizure treatment increases cell proliferation in rat frontal cortex. *Neuropsychopharmacol. Off. Publ. Am. Coll. Neuropsychopharmacol.* 30, 27–34. <https://doi.org/10.1038/sj.npp.1300565>
- Matsumoto, J., Fukunaga, M., Miura, K., Nemoto, K., Okada, N., Hashimoto, N., Morita, K., Koshiyama, D., Ohi, K., Takahashi, T., Koeda, M., Yamamori, H., Fujimoto, M., Yasuda, Y., Ito, S., Yamazaki, R., Hasegawa, N., Narita, H., Yokoyama, S., Mishima, R., Miyata, J., Kobayashi, Y., Sasabayashi, D., Harada, K., Yamamoto, M., Hirano, Y., Itahashi, T., Nakataki, M., Hashimoto, Ryu-ichiro, Tha, K.K., Koike, S., Matsubara, T., Okada, G., Yoshimura, R., Abe, O., van Erp, T.G.M., Turner, J.A., Jahanshad, N., Thompson, P.M., Onitsuka, T., Watanabe, Y., Matsuo, K., Yamasue, H., Okamoto, Y., Suzuki, M., Ozaki, N., Kasai, K., Hashimoto, Ryota, 2023. Cerebral cortical structural alteration patterns across four major psychiatric disorders in 5549 individuals. *Mol. Psychiatry* 1–9. <https://doi.org/10.1038/s41380-023-02224-7>
- Maynard, K.R., Hobbs, J.W., Rajpurohit, S.K., Martinowich, K., 2018. Electroconvulsive seizures influence dendritic spine morphology and BDNF expression in a neuroendocrine model of depression. *Brain Stimulat.* 11, 856–859. <https://doi.org/10.1016/j.brs.2018.04.003>
- Montgomery, S.A., Asberg, M., 1979. A new depression scale designed to be sensitive to change. *Br. J. Psychiatry J. Ment. Sci.* 134, 382–389. <https://doi.org/10.1192/bjp.134.4.382>
- Motter, J.N., Lee, S., Sneed, J.R., Doraiswamy, P.M., Pelton, G.H., Petrella, J.R., Devanand, D.P., 2021. Cortical thickness predicts remission of depression with antidepressants in patients with late-life depression and cognitive impairment. *J. Affect. Disord.* 295, 438–445. <https://doi.org/10.1016/j.jad.2021.08.062>
- Mulders, P.C.R., Llera, A., Beckmann, C.F., Vandenbulcke, M., Stek, M., Sienaert, P., Redlich, R., Petrides, G., Oudega, M.L., Oltegal, L., Oedegaard, K.J., Narr, K.L., Magnusson, P.O., Kessler, U., Jorgensen, A., Espinoza, R., Enneking, V., Emsell, L., Dols, A., Dannlowski, U., Bolwig, T.G., Bartsch, H., Argyelan, M., Anand, A., Abbott, C.C., van Eijndhoven, P.F.P., Tendolkar, I., 2020. Structural changes induced by electroconvulsive therapy are associated with clinical outcome. *Brain Stimulat.* 13, 696–704. <https://doi.org/10.1016/j.brs.2020.02.020>
- Nagai, M., Kishi, K., Kato, S., 2007. Insular cortex and neuropsychiatric disorders: a review of recent literature. *Eur. Psychiatry J. Assoc. Eur. Psychiatr.* 22, 387–394. <https://doi.org/10.1016/j.eurpsy.2007.02.006>
- Nagy, K., Greenlee, M.W., Kovács, G., 2012. The lateral occipital cortex in the face perception network: an effective connectivity study. *Front. Psychol.* 3, 141. <https://doi.org/10.3389/fpsyg.2012.00141>
- Narr, K.L., Bilder, R.M., Toga, A.W., Woods, R.P., Rex, D.E., Szeszko, P.R., Robinson, D., Sevy, S., Gunduz-Bruce, H., Wang, Y.-P., DeLuca, H., Thompson, P.M., 2005. Mapping Cortical Thickness and Gray Matter Concentration in First Episode Schizophrenia. *Cereb. Cortex* 15, 708–719. <https://doi.org/10.1093/cercor/bhh172>
- Nemati, S., Abdallah, C.G., 2020. Increased Cortical Thickness in Patients With Major Depressive Disorder Following Antidepressant Treatment. *Chronic Stress* 4, 2470547019899962. <https://doi.org/10.1177/2470547019899962>

- Olesen, M.V., Wörtwein, G., Folke, J., Pakkenberg, B., 2017. Electroconvulsive stimulation results in long-term survival of newly generated hippocampal neurons in rats. *Hippocampus* 27, 52–60. <https://doi.org/10.1002/hipo.22670>
- Ongür, D., Pohlman, J., Dow, A.L., Eisch, A.J., Edwin, F., Heckers, S., Cohen, B.M., Patel, T.B., Carlezon, W.A., 2007. Electroconvulsive seizures stimulate glial proliferation and reduce expression of Sprouty2 within the prefrontal cortex of rats. *Biol. Psychiatry* 62, 505–512. <https://doi.org/10.1016/j.biopsych.2006.11.014>
- Ousdal, O.T., Argyelan, M., Narr, K.L., Abbott, C., Wade, B., Vandenbulcke, M., Urretavizcaya, M., Tendolkar, I., Takamiya, A., Stek, M.L., Soriano-Mas, C., Redlich, R., Paulson, O.B., Oudega, M.L., Opel, N., Nordanskog, P., Kishimoto, T., Kampe, R., Jorgensen, A., Hanson, L.G., Hamilton, J.P., Espinoza, R., Emsell, L., Eijndhoven, P. van, Dols, A., Dannlowski, U., Cardoner, N., Bouckaert, F., Anand, A., Bartsch, H., Kessler, U., Oedegaard, K.J., Dale, A.M., Oltedal, L., Erchinger, V.J., Haavik, J., Sørhaug, O.J.E., Jørgensen, M.B., Bolwig, T.G., Magnusson, P., Cano, M., Pujol, J., Menchón, J.M., Petrides, G., Sienaert, P., 2020. Brain Changes Induced by Electroconvulsive Therapy Are Broadly Distributed. *Biol. Psychiatry* 87, 451–461. <https://doi.org/10.1016/j.biopsych.2019.07.010>
- Ousdal, O.T., Brancati, G.E., Kessler, U., Erchinger, V., Dale, A.M., Abbott, C., Oltedal, L., 2022. The Neurobiological Effects of Electroconvulsive Therapy Studied Through Magnetic Resonance: What Have We Learned, and Where Do We Go? *Biol. Psychiatry* 91, 540–549. <https://doi.org/10.1016/j.biopsych.2021.05.023>
- Phillips, J.L., Batten, L.A., Tremblay, P., Aldosary, F., Blier, P., 2015. A Prospective, Longitudinal Study of the Effect of Remission on Cortical Thickness and Hippocampal Volume in Patients with Treatment-Resistant Depression. *Int. J. Neuropsychopharmacol.* 18, pyv037. <https://doi.org/10.1093/ijnp/pyv037>
- Pirnia, T., Joshi, S.H., Leaver, A.M., Vasavada, M., Njau, S., Woods, R.P., Espinoza, R., Narr, K.L., 2016. Electroconvulsive therapy and structural neuroplasticity in neocortical, limbic and paralimbic cortex. *Transl. Psychiatry* 6, e832. <https://doi.org/10.1038/tp.2016.102>
- Polyakova, M., Schroeter, M.L., Elzinga, B.M., Holiga, S., Schoenknecht, P., de Kloet, E.R., Molendijk, M.L., 2015. Brain-Derived Neurotrophic Factor and Antidepressive Effect of Electroconvulsive Therapy: Systematic Review and Meta-Analyses of the Preclinical and Clinical Literature. *PloS One* 10, e0141564. <https://doi.org/10.1371/journal.pone.0141564>
- Puri, B.K., Oatridge, A., Saeed, N., Ging, J.E., McKee, H.M., Lekh, S.K., Hajnal, J.V., 1998. Does electroconvulsive therapy lead to changes in cerebral structure. *Br. J. Psychiatry J. Ment. Sci.* 173, 267. <https://doi.org/10.1192/bjp.173.3.267a>
- Qiu, M., Liu, G., Zhang, H., Huang, Y., Ying, S., Wang, J., Shen, T., Peng, D., 2020. The Insular Subregions Topological Characteristics of Patients With Bipolar Depressive Disorder. *Front. Psychiatry* 11.
- Rao, V.R., Sellers, K.K., Wallace, D.L., Lee, M.B., Bijanzadeh, M., Sani, O.G., Yang, Y., Shanechi, M.M., Dawes, H.E., Chang, E.F., 2018. Direct Electrical Stimulation of Lateral Orbitofrontal Cortex Acutely Improves Mood in Individuals with Symptoms of Depression. *Curr. Biol.* 28, 3893–3902.e4. <https://doi.org/10.1016/j.cub.2018.10.026>
- Repple, J., Meinert, S., Bollettini, I., Grotegerd, D., Redlich, R., Zaremba, D., Bürger, C., Förster, K., Dohm, K., Stahl, F., Opel, N., Hahn, T., Enneking, V., Leehr, E.J., Böhnlein, J., Leenings, R., Kaehler, C., Emden, D., Winter, N.R., Heindel, W., Kugel, H., Bauer, J., Arolt, V., Benedetti, F., Dannlowski, U., 2020. Influence of electroconvulsive therapy on white matter structure in a diffusion tensor imaging study. *Psychol. Med.* 50, 849–856. <https://doi.org/10.1017/S0033291719000758>
- Sartorius, A., Demirakca, T., Böhringer, A., Clemm von Hohenberg, C., Aksay, S.S., Bumb, J.M., Kranaster, L., Ende, G., 2016. Electroconvulsive therapy increases temporal gray matter volume and cortical thickness. *Eur. Neuropsychopharmacol. J. Eur. Coll. Neuropsychopharmacol.* 26, 506–517. <https://doi.org/10.1016/j.euroneuro.2015.12.036>

- Schmaal, L., Hibar, D.P., Sämann, P.G., Hall, G.B., Baune, B.T., Jahanshad, N., Cheung, J.W., van Erp, T.G.M., Bos, D., Ikram, M.A., Vernooij, M.W., Niessen, W.J., Tiemeier, H., Hofman, A., Wittfeld, K., Grabe, H.J., Janowitz, D., Bülow, R., Selonke, M., Völzke, H., Grotegerd, D., Dannowski, U., Arolt, V., Opel, N., Heindel, W., Kugel, H., Hoehn, D., Czisch, M., Couvy-Duchesne, B., Rentería, M.E., Strike, L.T., Wright, M.J., Mills, N.T., de Zubicaray, G.I., McMahon, K.L., Medland, S.E., Martin, N.G., Gillespie, N.A., Goya-Maldonado, R., Gruber, O., Krämer, B., Hatton, S.N., Lagopoulos, J., Hickie, I.B., Frodl, T., Carballo, A., Frey, E.M., van Velzen, L.S., Penninx, B.W.J.H., van Tol, M.-J., van der Wee, N.J., Davey, C.G., Harrison, B.J., Mwangi, B., Cao, B., Soares, J.C., Veer, I.M., Walter, H., Schoepf, D., Zurowski, B., Konrad, C., Schramm, E., Normann, C., Schnell, K., Sacchet, M.D., Gotlib, I.H., MacQueen, G.M., Godlewska, B.R., Nickson, T., McIntosh, A.M., Pappmeyer, M., Whalley, H.C., Hall, J., Sussmann, J.E., Li, M., Walter, M., Aftanas, L., Brack, I., Bokhan, N.A., Thompson, P.M., Veltman, D.J., 2017. Cortical abnormalities in adults and adolescents with major depression based on brain scans from 20 cohorts worldwide in the ENIGMA Major Depressive Disorder Working Group. *Mol. Psychiatry* 22, 900–909. <https://doi.org/10.1038/mp.2016.60>
- Schmitgen, M.M., Kubera, K.M., Depping, M.S., Nolte, H.M., Hirjak, D., Hofer, S., Hasenkamp, J.H., Seidl, U., Stieltjes, B., Maier-Hein, K.H., Sambataro, F., Sartorius, A., Thomann, P.A., Wolf, R.C., 2020. Exploring cortical predictors of clinical response to electroconvulsive therapy in major depression. *Eur. Arch. Psychiatry Clin. Neurosci.* 270, 253–261. <https://doi.org/10.1007/s00406-019-01033-w>
- Sheline, Y.I., Disabato, B.M., Hranilovich, J., Morris, C., D'Angelo, G., Pieper, C., Toffanin, T., Taylor, W.D., MacFall, J.R., Wilkins, C., Barch, D.M., Welsh-Bohmer, K.A., Steffens, D.C., Krishnan, R.R., Doraiswamy, P.M., 2012. Treatment course with antidepressant therapy in late-life depression. *Am. J. Psychiatry* 169, 1185–1193. <https://doi.org/10.1176/appi.ajp.2012.12010122>
- Sorri, A., Järventausta, K., Kampman, O., Lehtimäki, K., Björkqvist, M., Tuohimaa, K., Hämäläinen, M., Moilanen, E., Leinonen, E., 2021. Electroconvulsive therapy increases temporarily plasma vascular endothelial growth factor in patients with major depressive disorder. *Brain Behav.* 11, e02001. <https://doi.org/10.1002/brb3.2001>
- Sowell, E.R., Thompson, P.M., Leonard, C.M., Welcome, S.E., Kan, E., Toga, A.W., 2004. Longitudinal Mapping of Cortical Thickness and Brain Growth in Normal Children. *J. Neurosci.* 24, 8223–8231. <https://doi.org/10.1523/JNEUROSCI.1798-04.2004>
- Sprengelmeyer, R., Steele, J.D., Mwangi, B., Kumar, P., Christmas, D., Milders, M., Matthews, K., 2011. The insular cortex and the neuroanatomy of major depression. *J. Affect. Disord.* 133, 120–127. <https://doi.org/10.1016/j.jad.2011.04.004>
- Szabo, K., Hirsch, J.G., Krause, M., Ende, G., Henn, F.A., Sartorius, A., Gass, A., 2007. Diffusion weighted MRI in the early phase after electroconvulsive therapy. *Neurol. Res.* 29, 256–259. <https://doi.org/10.1179/174313206X153842>
- Takahashi, T., Yücel, M., Lorenzetti, V., Walterfang, M., Kawasaki, Y., Whittle, S., Suzuki, M., Pantelis, C., Allen, N.B., 2010. An MRI study of the superior temporal subregions in patients with current and past major depression. *Prog. Neuropsychopharmacol. Biol. Psychiatry* 34, 98–103. <https://doi.org/10.1016/j.pnpbp.2009.10.005>
- Tassone, V.K., Demchenko, I., Salvo, J., Mahmood, R., Di Passa, A.-M., Kuburi, S., Rueda, A., Bhat, V., 2022. Contrasting the amygdala activity and functional connectivity profile between antidepressant-free participants with major depressive disorder and healthy controls: A systematic review of comparative fMRI studies. *Psychiatry Res. Neuroimaging* 325, 111517. <https://doi.org/10.1016/j.psychres.2022.111517>
- Tørring, N., Sanghani, S.N., Petrides, G., Kellner, C.H., Østergaard, S.D., 2017. The mortality rate of electroconvulsive therapy: a systematic review and pooled analysis. *Acta Psychiatr. Scand.* 135, 388–397. <https://doi.org/10.1111/acps.12721>

- van Eijndhoven, P., Mulders, P., Kwekkeboom, L., van Oostrom, I., van Beek, M., Janzing, J., Schene, A., Tendolkar, I., 2016. Bilateral ECT induces bilateral increases in regional cortical thickness. *Transl. Psychiatry* 6, e874. <https://doi.org/10.1038/tp.2016.139>
- Van Rooij, D., Anagnostou, E., Arango, C., Auzias, G., Behrmann, M., Busatto, G.F., Calderoni, S., Daly, E., Deruelle, C., Di Martino, A., Dinstein, I., Duran, F.L.S., Durston, S., Ecker, C., Fair, D., Fedor, J., Fitzgerald, J., Freitag, C.M., Gallagher, L., Gori, I., Haar, S., Hoekstra, L., Jahanshad, N., Jalbrzikowski, M., Janssen, J., Lerch, J., Luna, B., Martinho, M.M., McGrath, J., Muratori, F., Murphy, C.M., Murphy, D.G.M., O’Hearn, K., Oranje, B., Parellada, M., Retico, A., Rosa, P., Rubia, K., Shook, D., Taylor, M., Thompson, P.M., Tosetti, M., Wallace, G.L., Zhou, F., Buitelaar, J.K., 2018. Cortical and subcortical brain morphometry differences between patients with autism spectrum disorder and healthy individuals across the lifespan: Results from the ENIGMA ASD working group. *Am. J. Psychiatry* 175, 359–369. <https://doi.org/10.1176/appi.ajp.2017.17010100>
- Vanicek, T., Kranz, G.S., Vyssoki, B., Komorowski, A., Fugger, G., Höflich, A., Micskei, Z., Milovic, S., Lanzenberger, R., Eckert, A., Kasper, S., Frey, R., 2019. Repetitive enhancement of serum BDNF subsequent to continuation ECT. *Acta Psychiatr. Scand.* 140, 426–434. <https://doi.org/10.1111/acps.13080>
- Wade, B.S.C., Sui, J., Helleman, G., Leaver, A.M., Espinoza, R.T., Woods, R.P., Abbott, C.C., Joshi, S.H., Narr, K.L., 2017. Inter and intra-hemispheric structural imaging markers predict depression relapse after electroconvulsive therapy: a multisite study. *Transl. Psychiatry* 7, 1270. <https://doi.org/10.1038/s41398-017-0020-7>
- Wagner, G., Schultz, C.C., Koch, K., Schachtzabel, C., Sauer, H., Schlösser, R.G., 2012. Prefrontal cortical thickness in depressed patients with high-risk for suicidal behavior. *J. Psychiatr. Res.* 46, 1449–1455. <https://doi.org/10.1016/j.jpsychires.2012.07.013>
- Wennström, M., Hellsten, J., Tingström, A., 2004. Electroconvulsive seizures induce proliferation of NG2-expressing glial cells in adult rat amygdala. *Biol. Psychiatry* 55, 464–471. <https://doi.org/10.1016/j.biopsych.2003.11.011>
- Winkler, A.M., Kochunov, P., Blangero, J., Almasy, L., Zilles, K., Fox, P.T., Duggirala, R., Glahn, D.C., 2010. Cortical thickness or grey matter volume? The importance of selecting the phenotype for imaging genetics studies. *NeuroImage* 53, 1135–1146. <https://doi.org/10.1016/j.neuroimage.2009.12.028>
- Wu, P., Zhang, A., Sun, N., Lei, L., Liu, P., Wang, Y., Li, H., Yang, C., Zhang, K., 2022. Cortical Thickness Predicts Response Following 2 Weeks of SSRI Regimen in First-Episode, Drug-Naive Major Depressive Disorder: An MRI Study. *Front. Psychiatry* 12.
- Xu, J., Wang, J., Bai, T., Zhang, X., Li, T., Hu, Q., Li, H., Zhang, L., Wei, Q., Tian, Y., Wang, K., 2019. Electroconvulsive Therapy Induces Cortical Morphological Alterations in Major Depressive Disorder Revealed with Surface-Based Morphometry Analysis. *Int. J. Neural Syst.* 29, 1950005. <https://doi.org/10.1142/S0129065719500059>
- Yang, W., Jin, S., Duan, W., Yu, H., Ping, L., Shen, Z., Cheng, Y., Xu, X., Zhou, C., 2023. The effects of childhood maltreatment on cortical thickness and gray matter volume: a coordinate-based meta-analysis. *Psychol. Med.* 53, 1681–1699. <https://doi.org/10.1017/S0033291723000661>
- Yi, S., Wang, Z., Yang, W., Huang, C., Liu, P., Chen, Y., Zhang, H., Zhao, G., Li, W., Fang, J., Liu, J., 2022. Neural activity changes in first-episode, drug-naïve patients with major depressive disorder after transcutaneous auricular vagus nerve stimulation treatment: A resting-state fMRI study. *Front. Neurosci.* 16.
- Yroni, A., Nemmi, F., Billoux, S., Giron, A., Sporer, M., Taib, S., Salles, J., Pierre, D., Thalamos, C., Rigal, E., Danet, L., Pariente, J., Schmitt, L., Arbus, C., Péran, P., 2019. Grey Matter changes in treatment-resistant depression during electroconvulsive therapy. *J. Affect. Disord.* 258, 42–49. <https://doi.org/10.1016/j.jad.2019.07.075>

- Yrondi, A., Péran, P., Sauvaget, A., Schmitt, L., Arbus, C., 2018. Structural–functional brain changes in depressed patients during and after electroconvulsive therapy. *Acta Neuropsychiatr.* 30, 17–28. <https://doi.org/10.1017/neu.2016.62>
- Zachrisson, O.C., Balldin, J., Ekman, R., Naesh, O., Rosengren, L., Agren, H., Blennow, K., 2000. No evident neuronal damage after electroconvulsive therapy. *Psychiatry Res.* 96, 157–165. [https://doi.org/10.1016/s0165-1781\(00\)00202-x](https://doi.org/10.1016/s0165-1781(00)00202-x)
- Zhang, T., Tang, X., Wei, Y., Xu, L., Hu, Y., Cui, H., Zeng, J., Ye, J., Xie, Y., Tang, Y., Liu, H., Chen, T., Li, C., Liu, X., Wang, J., 2023. Serum angioneurin levels following electroconvulsive therapy for mood disorders. *Bipolar Disord.* <https://doi.org/10.1111/bdi.13317>
- Zhong, X., Pu, W., Yao, S., 2016. Functional alterations of fronto-limbic circuit and default mode network systems in first-episode, drug-naïve patients with major depressive disorder: A meta-analysis of resting-state fMRI data. *J. Affect. Disord.* 206, 280–286. <https://doi.org/10.1016/j.jad.2016.09.005>
- Zhu, Z., Zhao, Y., Wen, K., Li, Q., Pan, N., Fu, S., Li, F., Radua, J., Vieta, E., Kemp, G.J., Biswa, B.B., Gong, Q., 2022. Cortical thickness abnormalities in patients with bipolar disorder: A systematic review and meta-analysis. *J. Affect. Disord.* 300, 209–218. <https://doi.org/10.1016/j.jad.2021.12.080>

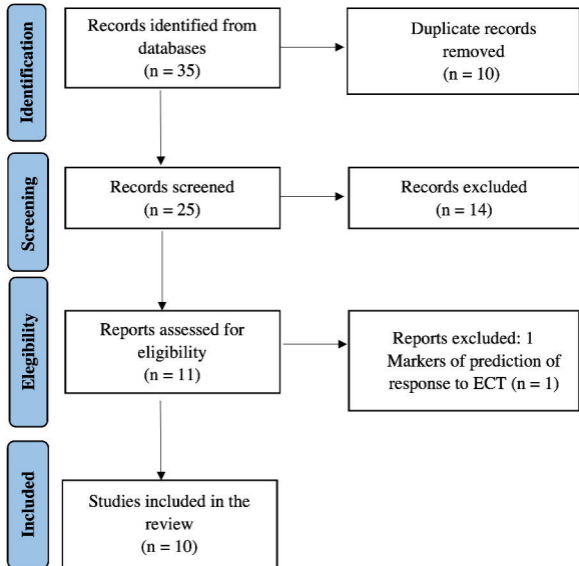
## Figure captions

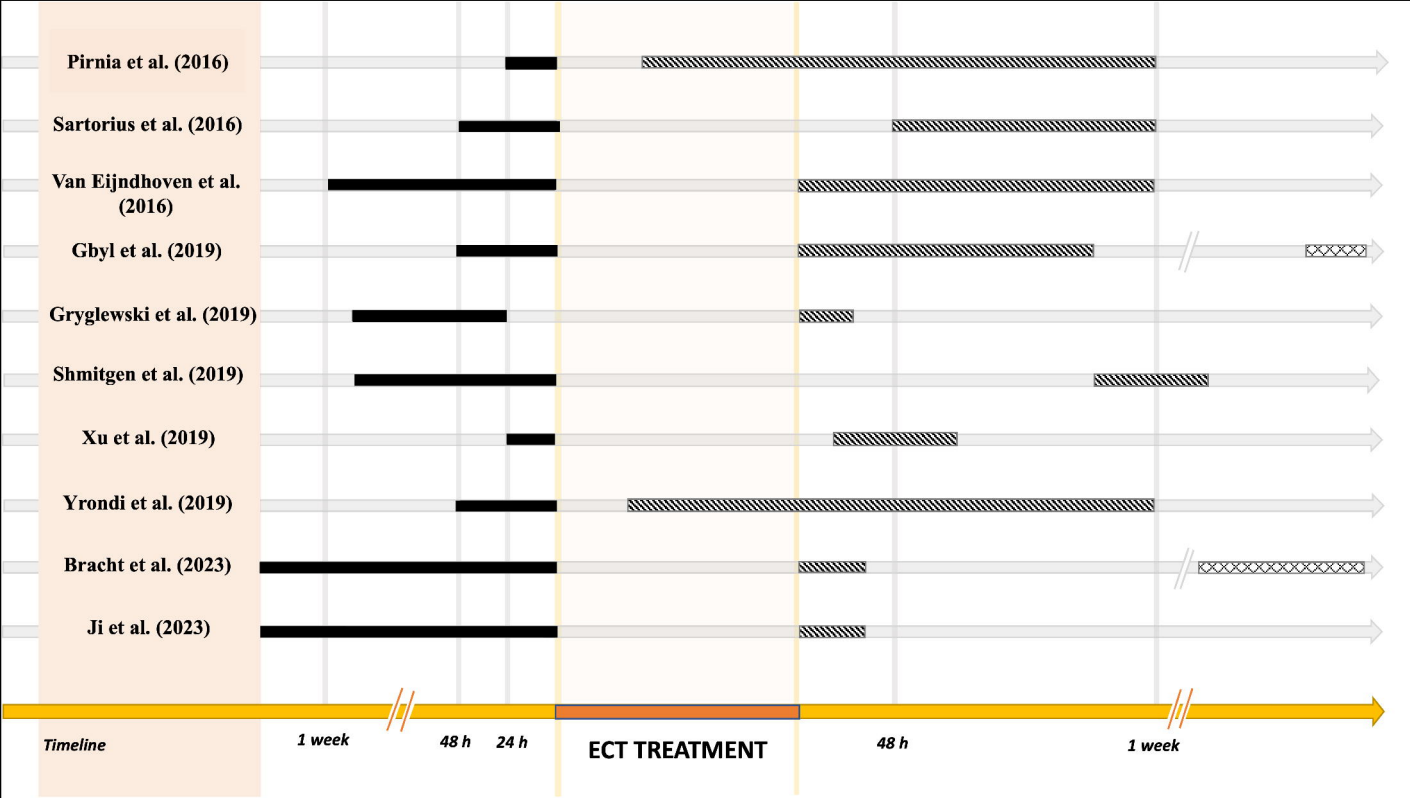
**Fig. 1. PRISMA flow chart of selection of publications for inclusion in the review.**

**Fig. 2. Magnetic resonance imaging (MRI) scan timeline of the studies of the effect of ECT on cortical thickness in patients with depression.** For each study, we have reported the timing of the structural magnetic resonance images relative to the entire ECT treatment (in orange), including the baseline scan (solid black line, T1), the second scan (hatched line, T2), and the third scan (cross-hatched line, T3). The time is measured relative to the beginning (T1) and end (T2, T3) of the ECT treatment.

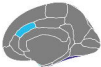
**Fig. 3. Changes in cortical thickness in patients with depression after ECT. Results from morphometric studies are displayed on the Desikan-Killiany atlas.** The medial and lateral cortical surfaces are displayed for each hemisphere on the leftmost part, the subcortical regions in the center, and the colorbar on the rightmost part of each panel, respectively. The color bar code indicates the total number of subjects who showed an increase in cortical thickness. L, left hemisphere; R, right hemisphere. The renderings were created using the R-package *ggseg*.



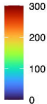
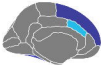




R



L



**Table 1: Studies investigating the effect of ECT on CT in depressed patients.**

Author, year	Subjects (M/F)	Diagnosis	Mean age (sd)	Study design	Electrode placement	N° of sessions	Field strength	Clinical scales	Timing of MRI scans	Timing of collection of clinical scales	ECT effect on CT	Correlations between CT changes and clinical variables
Pimia et al., 2016	Patients: 29 (11/18)	MDD-TRD (24), BD (5)	41.0 (13.0)	Longitudinal	Right unilateral	11.2	1.5 × ST	HAM-D, MADRS	- 24 hours before the first ECT - within 48 hours after the second ECT - within 1 week of the last ECT	- 24 hours before the first ECT - within 48 hours after the second ECT - within 1 week of the last ECT	Patients vs. HC (baseline): ↓ CT in the fusiform gyrus and superior temporal gyrus Patients: ↑ CT in bilateral anterior cingulate cortex, right parahippocampal gyrus, superior temporal gyrus and temporal pole between baseline and the last scan HC: no CT changes across time	Negative correlations between changes in CT in the fusiform, superior and inferior temporal gyrus and HAM-D scores. In the ACC, only responders showed a correlation between CT change and symptom improvement.
	HC: 29 (13/16)		40.1 (12.4)						- two time points with intervals equivalent to patients' first and third assessments	NA		
Sartorius et al., 2016	Patients: 18 (9/9)	MDD-TRD	51.7 (13.9)	Longitudinal	Right unilateral	11.3 ± 4.8	>2.5 ST	HAM-D	- 1 or 2 days before the first ECT - at least 2 days and within 2 weeks after the last ECT session	- 1-2 days before the first ECT - at least 2 days after ECT - within 2 weeks after the last ECT	Patients vs. HC: ↑ CT in right temporal pole and bilateral insula	NR
	HC: 36 (18/18)		51.6 (13.4)						NR	NA		
Van Eijndhoven et al., 2016	Patients: 23 (8/15)	MDD-TRD	50.7 (8.5)	Longitudinal	Bilateral at the temporal window	At least 10	1.5 × ST	HAM-D	- 1 week before the first ECT - within 1 week after the last ECT	- 1 week before the first ECT - within 1 week after the last ECT	Patients vs. HC (baseline): no differences in CT Patients: ↑ bilateral CT in temporal lobe, inferior and middle cortex and insula	Negative correlations between change in mean CT of the right insula and HAM-D scores. Positive correlation between change in mean CT of the left temporal pole, the left middle temporal cortex and the left inferior temporal cortex and the number of ECT sessions.
	HC: 22 (8/14)		50.8 (8.8)						- two time points with intervals equivalent to patients' first and third assessments	NA		

Gbyl et al., 2019	Patients: 18 (8/10)	MDD-TRD	46.8 (14.6)	Longitudinal	Bitemporal	Variable	>1 ST	HAM-D	- before the first ECT - right after the first ECT - 6 months after the last ECT	- before the first ECT - right after the first ECT - 6 months after the last ECT	↑ CT in frontal, temporal and insular cortex regions immediately after the first series of ECT, which returned to baseline 6 months after the last ECT	Negative correlation between increase in CT of the right lateral orbitofrontal cortex and HAM-D scores. No correlations between change in CT and cognitive functioning in any of the 26 tested regions.
Gryglewski et al., 2019	Patients: 14 (3/11)	MDD-TRD	46.9 (8.1)	Longitudinal	Right unilateral	A minimum of 8	3 ST	HAM-D	- twice before a series of ECT - once after a series of ECT	- twice before a series of ECT - once after a series of ECT	↑ CT after ECT in the right insula, supramarginal gyrus, inferior parietal cortex, superior temporal gyrus, inferior temporal gyrus, superior temporal sulcus, temporal pole, postcentral gyrus and fusiform gyrus	No correlations between CT and HAM-D score.
Schmitgen et al., 2019	Patients: 12 (4/8)	MDD-TRD	46.3 (11.3)	Longitudinal	Right unilateral	Variable	2.5 ST	HAM-D	- within 5 days before the first ECT - 6-8 days after the last ECT	- within 5 days before the first ECT - 6-8 days after the last ECT	Patients vs. HC: no significant differences in CT	Pre-ECT: correlation between changes in HAM-D scores and the CT of the left rostral anterior cingulate gyrus Post-ECT: correlation between changes in HAM-D scores and the CT of the left rostral anterior cingulate gyrus (strength pre- to post-ECT ↓), left medial orbitofrontal gyrus (strength pre- to post-ECT ↑).
	HC: 12 (4/8)		43.5 (11.5)						- one time point	NA		

Xu et al., 2019	Patients: 23 (11/12)	MDD-TRD	38.7 (11.0)	Longitudinal	Bifrontal	7.3 ± 2	NR	HAM-D	- 12/24 hours before the first ECT; - 24/72 hours after the last ECT	- 12-24 hours before the first ECT; - 24 -72 hours after the last ECT	↑ vertex-wise CT in left temporal pole, left fusiform gyrus, left inferior parietal gyrus, left insula, right lateral occipital gyrus, right supramarginal gyrus, right superior temporal gyrus, right insula and right precentral. ↑ regional CT in bilateral fusiform gyrus, bilateral parahippocampus and inferior temporal gyrus, left superior temporal gyrus, left inferior parietal gyrus, left insula, left superior temporal sulcus, right superior frontal gyrus and right rostral anterior cingulate. ↑ vertex-wise and regional CT in left temporal pole, fusiform gyrus and bilateral insula	Positive correlation between delayed recall of ALVT after ECT and changes in CT in the left inferior parietal gyrus. Positive correlation between the changes in vertex-wise CT in the right lateral occipital gyrus and the changes in the HAM-D scores. Negative correlation between the changes in vertex-wise CT in the right precentral gyrus and the changes in the ALVT delayed recall scores.
Yrondi et al., 2019	Patients: 17 (NR)	MDD-TRD	59.2 (7.1)	Longitudinal	Bilateral	12.1	1.5 to 2 × ST	HAM-D	- within 48h before the first ECT - after the first ECT considered effective - within 1 week of the last ECT	- within 48h before the first ECT - after the first ECT considered effective - within 1 week of the last ECT	Patients vs. HC (baseline): ↓ frontal CT, ↓ CT in fusiform gyrus, inferior, middle and superior temporal gyrus, parahippocampal gyrus and transverse temporal gyrus. Patients vs. HC (longitudinal): ↑ CT in superior temporal gyrus from the first and the second scan to the third scan	No correlations between structural changes and clinical variables.
	HC: 24 (NR)		61.9 (6.9)									
Bracht et al., 2023	Patients ECT: 20 (12/8)	MDD-TRD (16), BD (4)	44.9 (12.0)	Longitudinal	Right unilateral (n=17), bitemporal (n=2), bifrontal	12.7 ± 4	5 ST for RUL  2 ST for BT or BF	HAM-D, BDI-II	- before ECT-index series - after ECT-index series	- before ECT-index series  - after ECT-index series	Group x time interaction ECT vs. TAU vs. HC: ↑ global mean CT in the ECT-group and in TAU-responders but not in HC	No correlations between CT changes and clinical variables.

					(n=1)							
	Patients TAU: 20 (6/14)	MDD-TRD	44,2 (15)						-baseline - once remission was achieved or within 12 weeks after the first MRI in case of non-remission	- every 4 weeks		
	HC: 20 (12/8)	NA	43,6 (14)						-baseline - 61.2 ± 17 days after the first scan	NA		
Ji et al., 2023	Patients: 56 (12/44)	MDD-TRD	40,8 (12.1)	Longitudinal	Bifrontal	8.4 ± 1.4	>1 ST Costant current 0.9 A	HAM-D	- before ECT-index series - after ECT-index series	-baseline -after ECT	↑ CT in bilateral medial areas of the superior temporal gyrus and the bilateral insula	No correlations between CT changes and HAM-D scores.
	Patients: 40 (13/27)		39,3 (12.1)			7.8 ± 1.4						

AVLT: auditory verbal learning test; BD: bipolar disorder; BDI-II: Beck depression inventory-II; CT: cortical thickness; ECT: electroconvulsive therapy; HAM-D: Hamilton rating scale for depression; HC: healthy controls; MADRAS: Montgomery-Åsberg depression rating scales; MDD: major depressive disorder; NR: not reported; NA: not applicable; NR: not reported; ST: seizure threshold TAU: treatment as usual; TRD: treatment resistant depression.