

1  
2  
3  
4  
5  
6  
7  
8  
9  
10  
11  
12  
13  
14  
15  
16  
17  
18  
19  
20  
21  
22  
23  
24  
25  
26  
27  
28  
29  
30  
31  
32  
33  
34

**Artificial intelligence directed development of a digital twin to measure soft tissue shift during head and neck surgery**

David Männle<sup>1</sup>, Jan Pohlmann<sup>1</sup>, Sara Monji-Azad<sup>2</sup>, Jürgen Hesser<sup>2,3,4,5,6</sup>, Nicole Rotter<sup>1</sup>, Annette Affolter<sup>1</sup>, Anne Lammert<sup>1</sup>, Benedikt Kramer<sup>1</sup>, Sonja Ludwig<sup>1</sup>, Lena Huber<sup>1</sup>, Claudia Scherl<sup>1,6\*</sup>

<sup>1</sup> Department of Otorhinolaryngology, Head and Neck Surgery, University hospital Mannheim, Medical Faculty Mannheim, Heidelberg University, Mannheim, Germany

<sup>2</sup> Mannheim Institute for Intelligent Systems in Medicine (MIISM), Medical Faculty Mannheim, Heidelberg University, Mannheim, Germany

<sup>3</sup> Interdisciplinary Center for Scientific Computing (IWR), Heidelberg University, Heidelberg, Germany

<sup>4</sup> Central Institute for Computer Engineering (ZITI), Heidelberg University, Heidelberg, Germany

<sup>5</sup> CZS Heidelberg Center for Model-Based AI, Heidelberg University, Heidelberg, Germany

<sup>6</sup> AI Health Innovation Cluster, Heidelberg-Mannheim Health and Life Science Alliance, Heidelberg, Germany

\*corresponding author

Email: [claudia.scherl@umm.de](mailto:claudia.scherl@umm.de)

**Short title:**

Artificial intelligence for measuring soft tissue shift during head and neck surgery

**Associated Data**

Data Availability Statement

All relevant data are within the paper and its Supporting Information files.

**NOTE: This preprint reports new research that has not been certified by peer review and should not be used to guide clinical practice.**

35 **Abstract**

36 *Introduction:* Digital twins derived from 3D scanning data were developed to measure soft tissue  
37 deformation in head and neck surgery by an artificial intelligence approach. This framework was  
38 applied suggesting feasibility of soft tissue shift detection as a hitherto unsolved problem.

39 *Methods:* In a pig head cadaver model 104 soft tissue resection had been performed. The surface of  
40 the removed soft tissue (RTP) and the corresponding resection cavity (RC) was scanned (N=416) to  
41 train an artificial intelligence (AI) with two different 3D object detectors (HoloLens 2; ArtecEva). An  
42 artificial tissue shift (TS) was created by changing the tissue temperature from  $7,91\pm 4,1^{\circ}\text{C}$  to  
43  $36,37\pm 1,28^{\circ}\text{C}$ .

44 *Results:* Digital twins of RTP and RC in cold and warm conditions had been generated and volumes  
45 were calculated based on 3D surface meshes. Significant differences in number of vertices created by  
46 the different 3D scanners (HoloLens2 51313 vs. ArtecEva 21694,  $p<0.0001$ ) hence result in differences  
47 in volume measurement of the RTC ( $p=0.0015$ ). A significant TS could be induced by changing the  
48 temperature of the tissue of RC ( $p=0.0027$ ) and RTP ( $p<0.0001$ ). RC showed more correlation in TS by  
49 heating than RTP with a volume increase of  $3.1\ \mu\text{l}$  or  $9.09\%$  ( $p=0.449$ ).

50 *Conclusions:* Cadaver models are suitable for training a machine learning model for deformable  
51 registration through creation of a digital twin. Despite different point cloud densities, HoloLens and  
52 ArtecEva provide only slightly different estimates of volume. This means that both devices can be used  
53 for the task. TS can be simulated and measured by temperature change, in which RC and RTP react  
54 differently. This corresponds to the clinical behaviour of tumour and resection cavity during surgeries,  
55 which could be used for frozen section management and a range of other clinical applications.

56 **Keywords**

57 Digital twin, artificial intelligence, tissue shift, soft tissue, head and neck surgery, resection cavity,  
58 tumour

59

## 60 **Introduction**

61 Tissue shift (TS) is referred to as tissue displacements during soft tissue surgery. The tissue deforms  
62 after the wound opening due to its soft consistency and loss of tension. Consequently, anatomical  
63 landmarks can displace making orientation difficult. This effect has often been described in  
64 neurosurgery as brain shift and is considered a major source of error in neuro-navigation systems (1-  
65 3). Similar to neurosurgery, precise orientation is of immense importance in head and neck surgery,  
66 since many critical structures are located in very small space.

67 Therefore, navigation systems had been established. So far, these can only be used for the application  
68 of rigid bony structures, such as in sinus surgery (4). In visceral surgery marker-based tracking systems  
69 have been evaluated to aid in tumour resection and to compensate TS in soft tissue resections (5, 6).  
70 There are no marker-less navigation systems for head and neck surgery that compensate for soft tissue  
71 tracking. Resection of soft tissue tumours is a major field of head and neck surgery with tissue  
72 deformity causing difficulties. The study provides preliminary work for the development of a marker-  
73 free soft-tissue navigation system by determining TS using artificial intelligence (AI). Determining TS  
74 would have an enormous advantage for tumour resection itself and for handling frozen section  
75 procedure. Soft-tissue tumours could be resected better if orientation was improved by a navigation  
76 system. Furthermore, due to tissue deformation the exact spot for a re-resection after frozen section  
77 analysis is difficult to localize. Here, precise AI guided navigation can improve the safety, as areas to  
78 be re-resected can be detected in a better way.

79 Moreover, it is helpful to determine tissue deformation using AI in measuring and planning defect  
80 reconstruction with flaps. Due to TS, difficulties in fitting the flaps arise. The AI system developed in  
81 this study to determine TS could also help to gauge flap sizes more precisely in the future.

82 To the best authors' knowledge, there is no study on AI measuring TS on volume changes of tumours  
83 and corresponding resection cavity. In order to obtain large amounts of data for AI training and the  
84 limited number of surgeries, the current study simulates tumour resections on pig cadaver heads to

85 investigate a TS based on experimental volume changes. The study primarily intends to generate an AI  
86 system to register and measure TS. For that a simulation model for generating tissue shift was created.  
87

## 88 **Material and Methods**

89 Animal cadavers and 3D scans

90 To conduct this experimental study 52 pig head cadavers (Schradi Frischfleisch GmbH, Mannheim) had  
91 been dissected. The animal cadaver model was approved by the Mannheim Veterinary Office (DE 08  
92 222 1019 21). The pig heads were halved in the sagittal plane and stored at  $7,91 \pm 4,1^\circ\text{C}$  for immediate  
93 use or frozen at approximately  $-18^\circ\text{C}$  for later processing. The pig head cadavers (PHC) were covered  
94 with surgical drape and tissue blocks at the parotid region down to the masseter muscle had been  
95 removed as a simulated tumour resection. Surgical drapes were marked next to the resection cavities  
96 and to the removed piece of tissue to make this region recognizable to the 3D cameras as "region of  
97 interest" (ROI) (**Fig 1**).

98

### 99 **Fig 1: HMD images of pig head**

100 Arrows and lines point to "cranial" (1), "caudal"(2), "rostral"(3), and "occipital"(4) direction to indicate  
101 the region of interest to the 3D-cameras and photogrammetry. A1: cold resection cavity; A2: cold  
102 removed tissue with basal side upwards; B1: warm resection cavity; A2: warm removed tissue with  
103 basal side upwards.

104

105 After resection the cavity and the resected tissue piece (RTP) are scanned with the 3D cameras (cold  
106 scan). Furthermore, images for photogrammetry are taken with the Head Mounted Display (see  
107 below). Tissue shift is simulated by heating. The shape of the tissue changes as a result of the  
108 temperature alteration, leading to a soft tissue displacement. In order to provoke a controlled and  
109 measurable tissue shift the RTP is placed back into the cavity, the PHC is covered with plastic sheets to  
110 minimize dehydration and warmed up to  $36.37 \pm 1.28^\circ\text{C}$  in a heat chamber (*Binder GmbH, FD-53*) for

111 10 to 12 hours. The core temperature was measured continuously. Then immediately after warming  
112 the warm scans were performed.

113 To generate the raw data, scans were taken with a Head Mounted Display (HL2) (HoloLens 2©,  
114 Microsoft Corporation, Redmond, Washington, USA) and a 3D-object scanner ArtecEva (Artec3D,  
115 Luxembourg) (**Fig 2**). HoloLens and ArteEva have already been proven to be sufficient in the clinical-  
116 experimental use of head and neck surgery (7-9). Immediately before scanning core temperatures  
117 were measured using a piercing probe. With the HL2 approximately 15-20 images were taken from  
118 each angle in order to capture as much anatomical detail of the ROI as possible. To generate a detailed  
119 3D mesh with the ArtecEva the camera is moved around the objects at a distance of 40 to 100 cm for  
120 30-60 seconds.

121  
122 **Fig 2: 3D cameras.** (a) Microsoft HoloLens 2© (Microsoft Corporation, Redmond, Washington, USA),  
123 (b) Artec Eva 3D object scanner (Artec3D, Luxembourg). The *HoloLens 2* is a mixed-reality headset that  
124 augments the vision by superimposing the reality with movable 3D holograms. 3D figures can be  
125 viewed from any perspective and virtually positioned anywhere in the user's field of vision. Recordings  
126 are made with a camera integrated into the front part of the device in JPEG format (8 megapixels for  
127 still images and 1080 p30 pixels in video format). The 3D object scanner *ArtecEva* is hand-held 3D-  
128 camera being approved for medical use. It takes 16 pictures per second. The object to be scanned is  
129 illuminated alternately with a flashlight and a natural light. The 3D resolution is specified with an  
130 accuracy of 0.2mm.

131  
132 Data Generation

133 After the scans have been obtained, further processing takes place using photogrammetry. This  
134 process is done by using Meshroom software (Version 2021.1.0, Windows 10, Python 3.7.4) as a GUI  
135 for the Alice Vision Framework on a workstation with 16 Cores (AMD Ryzen 9 5950X) 64GB RAM and a  
136 single Nvidia 3080 Ti GPU. Mesh generation is done using Artec Studio 14 Professional, MeshLab 64bit,

137 v2021.07, and Blender 2.93.4. Individual 2D images, which are created from different angles and are  
138 taken into account to form a 3D mesh. Then, Meshroom examines and compares the available input  
139 images, recognizes them, and is thus able to determine the different camera positions. Therefore, the  
140 2D objects, depicted on the HL2 images in JPEG format, are converted into 3D figures.

141

142 Post-Processing

143 To improve the quality of the 3D objects, some post-processing steps are done using MeshLab  
144 software. For instance, some of the 3D figures contain holes in their surface structure. Then the "Close  
145 Holes" function is used. Furthermore, during the creation and editing of the meshes, a total number is  
146 set to 300,000 vertices for the entire mesh. Since uneven distribution of the vertices on the 3D figures  
147 arise because some surfaces of the object are captured better than others during scanning, a  
148 MeshResampling node is added to Meshroom's processing pipeline, and the "Simplification factor"  
149 setting is set to 1.0. It is worth mentioning that the development of the 3D meshes from the scans with  
150 the Artec Eva is carried out by the Artec Studio Professional 14 software, including the holes closing  
151 and ROI segmentation. During 3D mesh generation and post-processing steps, a 3D figure of each  
152 cavity and of the RTP is generated (**Fig 3**). The 3D figures created with Meshroom from the HL2 images  
153 are provided by the software in OBJ format. In contrast to the ArtecEva meshes, this format does not  
154 provide metric information such as the length and 3D object volume. However, for subsequent  
155 calculation of the volume of the resection cavity and the RTP the dimensionless sizes of the OBJ format  
156 have to be adapted to the real size. Additionally, an exact adjustment of the scales of the meshes from  
157 HL2 and Artec Eva images is necessary since the Meshroom software generates very small meshes  
158 compared to the real size of the objects. The metric information provided in the Artec meshes is  
159 considered the basis for calculating the scaling factor. Therefore, the length of the cranial line of the  
160 marks (**Fig 1**) is precisely measured three times in the MeshLab software and shown as " $l_{\text{target}}$ " in  
161 millimetres. Subsequently, the same measurement method is applied to the corresponding mesh from  
162 the HL2 recordings. The mean value is again calculated from the three measurements and shown as

163 " $l_{source}$ ", which is dimensionless. Consequently, the scaling factor  $f$  is calculated using the following  
164 equation:

$$165 \quad f = \frac{l_{target}}{l_{source}} \quad (1)$$

166  
167 With the calculated scaling factors, we are able to adjust the dimensionless sizes of the HL2 meshes to  
168 the real scales.

169  
170 Segmentation and Volume

171 Segmenting the resection cavity and the RTP meshes is done in MeshLab. The "Draw Polyline" tool is  
172 used to digitally cut out the ROI from the rest of the mesh. To this end, the edges of the resection  
173 cavity and the RTP piece are marked out with the polyline by repeated mouse clicks. This is followed  
174 by an inversion of this marking to the portions outside the ROI, which will be deleted at the end. In this  
175 way, the relevant measurement area is separated from its external environment leaving only the  
176 resected cavity and the RTP for subsequent evaluation. The process of cavity and tumour segmentation  
177 to create a digital twin is shown in **Fig 3**. The volumes of the resection cavity and the RTP is measured  
178 in  $\text{mm}^3$  and also calculated using the MeshLab software. The output is shown in **Fig 3D**.

179  
180 **Fig 3: Segmentation of meshes with MeshLab of the cold resection cavity**

181 A: Digital twin of HoloLens images; B: Digital twin of ArtecEva images; C: Completed segmentation of  
182 the ArtecEva mesh; D: View of the ArtecEva mesh after marking the volume of the ROI with the Convex  
183 Hull function and calculating it using Compute Geometric Measures

184  
185 Statistics

186 The Wilcoxon-signed-ranks test is used to compare the captured data using ArtecEva and HL2, with  
187 respect to the number of vertices in the ROI and the volume values of the cavity and of the RTP.  
188 Differences in volume as a function of temperature was also matched employing the Wilcoxon-signed-

189 ranks test. This examines whether the central tendencies of two dependent paired samples differ. All  
190 analyses are reported with p-value, median, standard deviation (SD), minimum, maximum, range  
191 (minimum-maximum), and 95% confidence interval (CI). A result with a p-value < 0.05 is considered  
192 statistically significant. GraphPad PRISM, Version 9, 2020 was used for statistical analysis. Data were  
193 included in the final data aggregation (S1 appendix).

194

## 195 Results

196 The collected data consist of temperature (°C), vertices, and volume amount (µl) which are provided  
197 both for cavity and RTP in cold and warm conditions. A total of 416 data sets from 104 halved pigs  
198 were evaluated. Due to insufficient quality problems of some meshes and some 3D objects 31 data  
199 sets were excluded from the present study as the ascertainment of vertices for determination the  
200 volumes were impossible, leaving 385 eligible cases for analysis. In this regard, 208 scans of cold tissue  
201 and 208 scans of warm tissue were unattainable.

202

### 203 Vertices and volume depending on the capture device

204 To analyse the number of vertices in the ROI, 193 pairs of values of the meshes from HL2 and ArtecEva  
205 are used. The data which is examined include the segmented resection cavity and RTP of both, cold  
206 and warm, captures. As shown in **Fig 4A**, the HL2 generates a significantly higher number of vertices  
207 after processing the meshes compared to the ArtecEva camera. With a value of 51313 vertices, the  
208 HL2 meshes have more than twice the span in comparison to the 21694 vertices of the Artec 3D  
209 objects. The median and standard deviation of the vertices of the HL2 and the Artec Eva meshes are  
210  $12928 \pm 6504$  (range: 1145 to 52458, 95%-CI: 12344-14005) and  $10158 \pm 3079$  (range: 1486 to 23180,  
211 95%-CI: 9424-10632), respectively ( $p < 0.0001$ ).

212 Details of the different cameras regarding the volume (µl) of resection cavity and RTP are depicted in  
213 **Fig 4B**. Deeming the resection cavity, there was no significant difference between the HL2 (median ±  
214 SD:  $35849 \mu\text{l} \pm 17482 \mu\text{l}$ , range:  $15814 \mu\text{l}$  to  $119618 \mu\text{l}$ , 95%-CI: 30648-40188) and the ArtecEva (median



215  $\pm$  SD: 36104  $\mu$ l  $\pm$  17656  $\mu$ l, range: 1253  $\mu$ l - 118037  $\mu$ l, 95%-CI: 31370-38815)  $p=0.9116$ . Analysing the  
216 RTP volume the following significant differences are found: HL2 (median  $\pm$  SD: 29425  $\mu$ l  $\pm$  13636  $\mu$ l,  
217 range: 13226  $\mu$ l to 86991  $\mu$ l, 95%-CI: 26217-33887) and ArtecEva (median  $\pm$  SD: 31723  $\mu$ l  $\pm$  14114  $\mu$ l,  
218 range: 13696  $\mu$ l to 92449  $\mu$ l, 95%-CI: 26504-35296), ( $p=0.0015$ ).

219

#### 220 **Fig 4: Vertices and volumes depending on the recording device**

221 A: *Vertices* of resection cavity and RTP recorded either with HL2 or ArtecEva; B: Comparison of *volumes*  
222 ( $\mu$ l) depending on recording device for either cavity or RTP.

223 HL2 = HoloLens, Artec = ArtecEva 3D object camera, RTP = resected tissue piece. Significance  
224 determined with Wilcoxon-signed-ranks test,  $p<0.0001$  = highly significant\*\*\*,  $p<0.01$  very  
225 significant\*\*,  $p<0.05$  significant, ns = not significant.

226

227 Volume as a function of tissue and temperature

228 The following volume determinations refer to the data collected with the ArtecEva, as this device is  
229 already approved for medical applications. Significant differences in volume can be seen in **Fig 5A**  
230 comparing the cavity and the RTP for warm and cold temperatures. In the cold state (7-8°C) volume of  
231 the resection cavity and the RTP reveal significant differences ( $p=0.0449$ ). The volume of the cavity  
232 revealed a median volume of 34074  $\mu$ l  $\pm$  16970  $\mu$ l (range 15373  $\mu$ l to 118037  $\mu$ l, 95%-CI: 28913-37990)  
233 and the RTP of 33318  $\mu$ l  $\pm$  14524  $\mu$ l (range 16485  $\mu$ l to 92449  $\mu$ l, 95% CI: 27105-37548). Comparing  
234 cavity and RTP in the warm state (36.37  $\pm$  1.28°C), median volume of the cavity is 37173  $\mu$ l  $\pm$  18496  $\mu$ l,  
235 (range: 12531  $\mu$ l to 117872  $\mu$ l, 95%-CI: 29906-45620). In contrast, the warm RTP exhibited a median  
236 volume of 31199  $\mu$ l  $\pm$  13501  $\mu$ l (range 13696  $\mu$ l to 85907  $\mu$ l, 95%-CI: 23943-35576),  $p \leq 0.0001$ .

237 The boxplots of the volume of the resection cavity and RTP before and after heating of the tissue are  
238 shown in **Fig 5B**. The resection cavities increase the volume significantly by a median of 3.1  $\mu$ l from  
239 34.1  $\mu$ l in the cold state to 37.2  $\mu$ l after heating ( $p=0.0027$ ). A highly significant decrease in RTP volume  
240 by median of 2.1  $\mu$ l from 33.3  $\mu$ l in the cold state to 31.2  $\mu$ l after heating was measured ( $p<0.0001$ ).

241

242 **Fig 5: Volume as a function of tissue type and temperature**

243 A: Volume as a function of tissue type: resection cavity (RC) and resected tissue piece (RTP) for cold  
244 and warm scans; B: Volume comparing cold (7-8°C) and warm ( $36.37 \pm 1.28$  °C) temperature of RC and  
245 RTP.

246 RC = resection cavity, RTP = resected tissue piece. Significance determined with Wilcoxon-signed-ranks  
247 test,  $p < 0.0001$  = highly significant\*\*\*,  $p < 0.01$  very significant\*\*,  $p < 0.05$  significant, ns = not significant.

248

249 **Discussion**

250 So far, no satisfactory method for measuring TS has been found. Numerous authors, mostly  
251 neurosurgeons, report on intraoperative imaging to determine TS during surgery (10-12). All methods  
252 are very time-consuming, costly and error-prone. With our AI based pilot investigation we describe a  
253 completely new approach. We were able to develop a pig carcass model on which soft tissue resections  
254 were performed. Tissue deformations were induced by controlled temperature changes. Hundreds of  
255 tissue scans trained an AI, which then registered and measured tissue deformation.

256 Two modern scanning devices were used and compared, Microsoft HoloLens 2 and Artec Eva 3D object  
257 scanner. Although the ArtecEva generates fewer vertices, the volume of the resection cavity is  
258 captured equally by both devices ( $p = 0.9116$ ). A higher number of vertices is not equivalent to an  
259 increase in accuracy. Many vertices of the HL2 overlapped. While requiring computing power the  
260 superimposed vertices did not contribute to volume calculation.

261 A TS can be simulated by changing the temperature of the tissue. This is caused by gaping of the  
262 borders of the resection cavity, loss of tissue tension and partial by dehydration. There is a change in  
263 Volume after heating. Cold tissue is rigid, thus preventing tissue to deform. The RTP and the defect  
264 remain precisely fitting when cold. The gaping of the borders of the cavity simulates the intraoperative  
265 behaviour of resection cavities quite well. During surgery the tension of the surrounding tissue leads  
266 to an enlargement of the defect. Our investigations show that temperature changes are suitable to

267 simulate this intraoperative tissue shift of the resection cavity. The RTP volume decreases after  
268 heating. This is due to changes in the elastic properties of the tissue, dehydration, and leakage of fat.  
269 Here, too, the clinically known phenomenon of tumour shrinkage after resection can be simulated  
270 well.

271 The simulation model presented here could be used for the following clinical problems: (1) *Frozen*  
272 *section management*: This is where the largest and most important application potential can be seen.

273 When assigning intraoperative frozen section findings, shifts in landmarks can occur due to TS in the  
274 resection cavity. That's why target deviation for subsequent re-resection could be up to 1 cm (13). As

275 a result, in 78% of all re-resection samples there is no residual tumour found. This could mean that the  
276 corresponding site in the tumour bed for the positive or close margins was incorrectly localized and

277 tumour cells might remain in the patient (14). Our method can help to measure the TS in order to  
278 better determine areas for subsequent re-resection to remove the tumour completely. This increases

279 the oncological safety of frozen section-controlled tumour resections. (2) *Flap planning*: In head and  
280 neck surgery large defects have to be closed by tissue transfer (flaps). During surgery it is common to

281 estimate the size of a flap before tumour removal by the size of the tumour. When planning to close  
282 the defect with a flap in that way, fitting difficulties of the flap are possible later on due to a TS on the

283 resection cavity. The method shown in this report can be used to determine the size and volume of  
284 the defect intraoperatively in order to better determine the dimensions and volume of the flap. In

285 addition, a subsequent flap shrinkage must be taken into account. It is recommended to include this  
286 shrinkage in the flap size planning beforehand (15, 16). Due to the possibility of precisely determining

287 the volume of the resection cavity with the presented method, it could also help to calculate the  
288 amount of overcorrection. (3) *Soft tissue navigation*: In soft tissue navigation inaccuracies occur due

289 to TS. Marker-based tracking systems should help to compensate TS, which is also not error-free (5).  
290 As a basis for the development of soft tissue navigation without markers, we present a completely new

291 AI-based approach. Similar to the method by Pfeiffer M et al for liver surgery (17) we developed a  
292 system to record tissue deformation in real-time, which could be an enormous orientation aid,

293 especially in head and neck surgery. Because, due to the anatomically very narrow conditions with  
294 many structures in a small space, it is difficult to find tumours and remove them in such a way that  
295 important structures are spared.

296  
297 Based on the investigations, it shows that generating controlled TS is possible in an animal cadaver  
298 model and to measure it by volume differences. In future works, this methodology can be applied to  
299 real tumour resection during soft tissue surgery. For this, additional work is needed in training AI to  
300 augment model prediction and accuracy, which than will also recognize different tumour formations.

301

## 302 **Conclusions**

303 In this study, we verified that cadaver models are suitable for training an AI through creation of big  
304 data. In the scanning process, the number of vertices depends on the recording device. The more  
305 vertices were generated, the more superimpositions of these occurred, which are not included in the  
306 volume calculation. TS can be simulated by temperature change mirroring a number of clinical  
307 phenomena, for which the presented method can be helpful in the future.

308

## 309 **Acknowledgements**

310 We would like to thank Johann Kern and Petra Prohaska for the provision of animal laboratory space  
311 including all necessary equipment and their assistance during resection and scanning process.  
312 Furthermore, we thank Dennis Feiler and Holger Ladewig (DFC SYSTEMS, Munich) for excellent  
313 technical support. The study was funded by the German Federal Ministry of Economic Affairs and  
314 Climate Action, Central Innovation Programme for small and medium-sized enterprises (SMEs);  
315 funding number: KK5044704CS0.

316

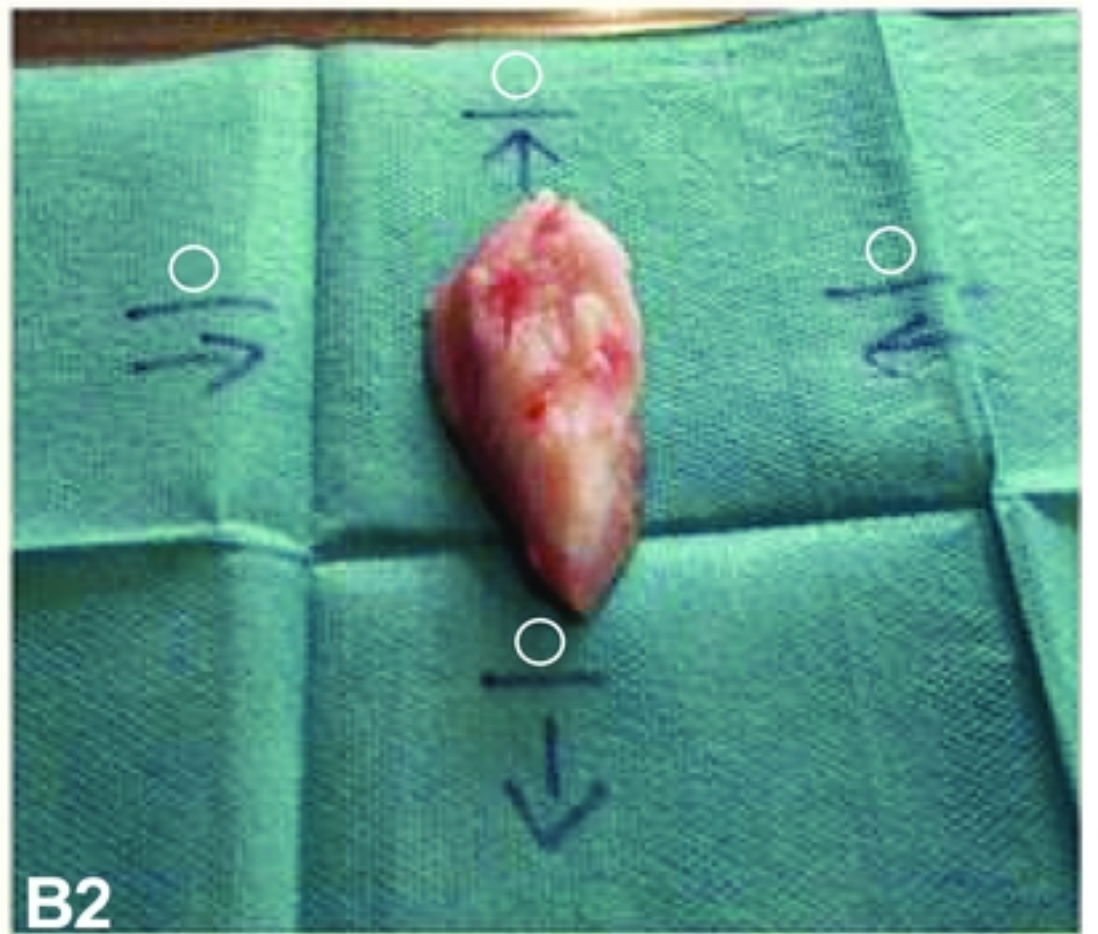
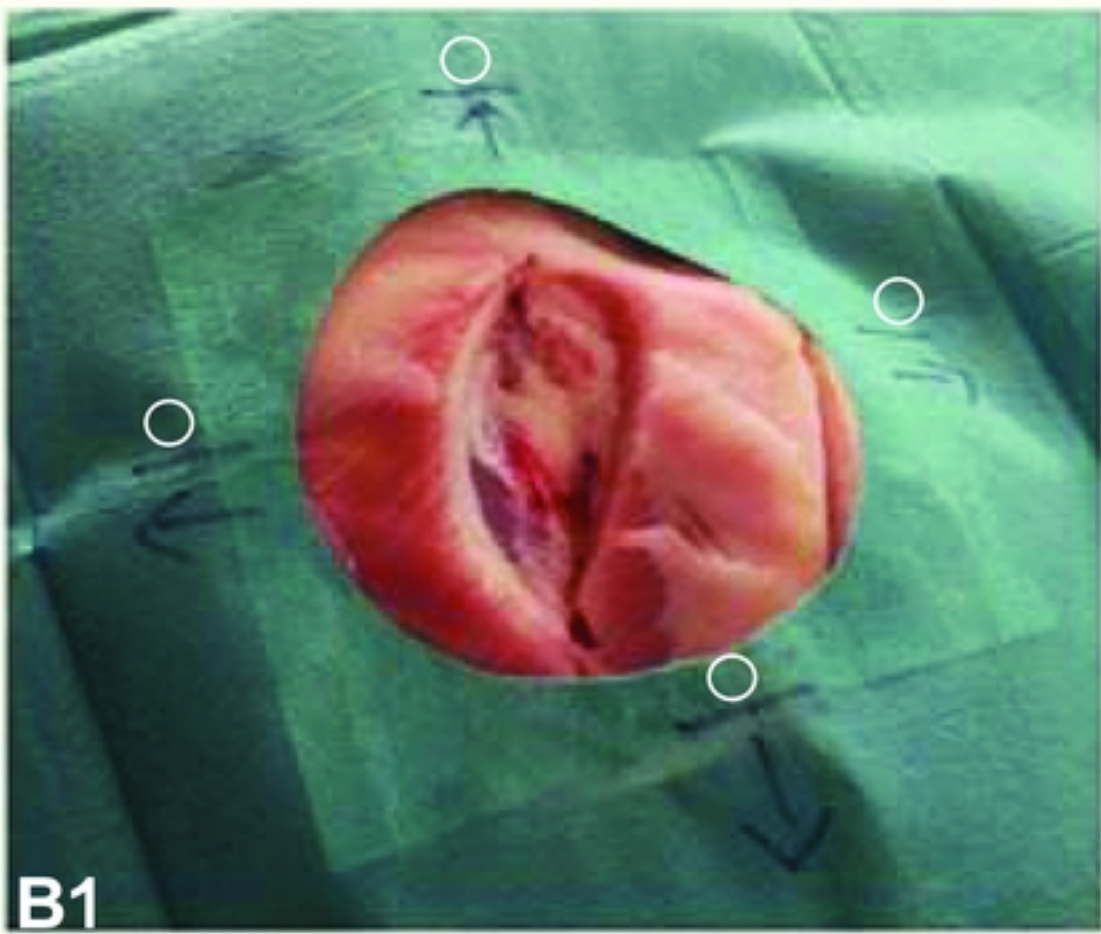
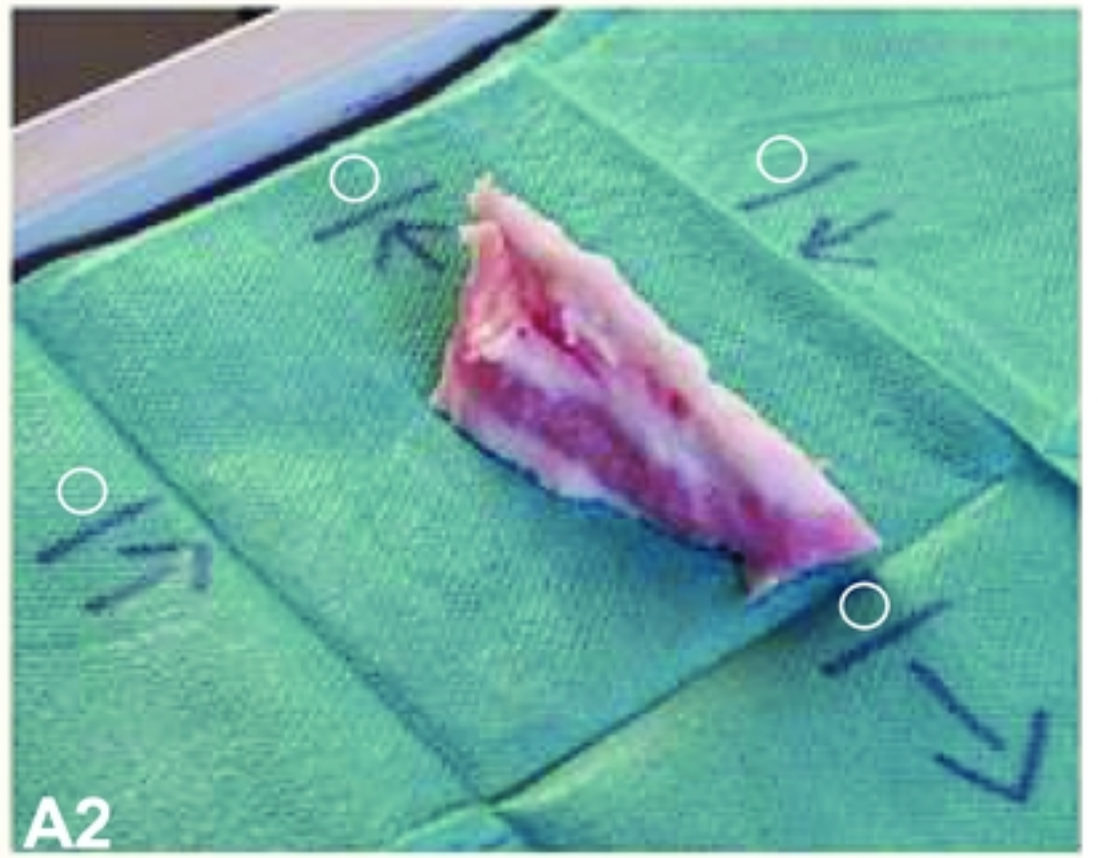
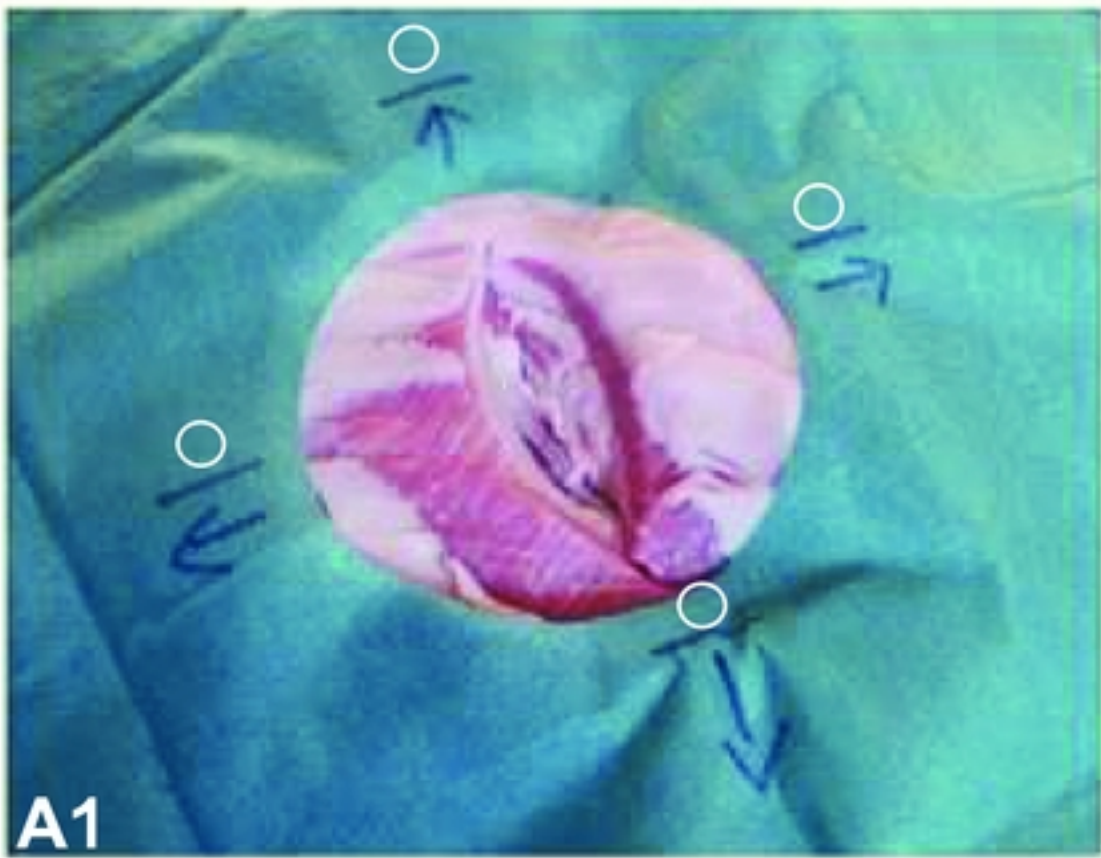
## 317 **References**

318 1. Khan MF, Mewes K, Gross RE, Skrinjar O. Assessment of brain shift related to deep brain  
319 stimulation surgery. *Stereotact Funct Neurosurg.* 2008;86(1):44-53.

- 320 2. Miyagi Y, Shima F, Sasaki T. Brain shift: an error factor during implantation of deep brain  
321 stimulation electrodes. *J Neurosurg*. 2007;107(5):989-97.
- 322 3. Reinertsen I, Lindseth F, Askeland C, Iversen DH, Unsgård G. Intra-operative correction of brain-  
323 shift. *Acta Neurochir (Wien)*. 2014;156(7):1301-10.
- 324 4. Citardi MJ, Batra PS. Intraoperative surgical navigation for endoscopic sinus surgery: rationale  
325 and indications. *Curr Opin Otolaryngol Head Neck Surg*. 2007;15(1):23-7.
- 326 5. Eppenga R, Kuhlmann K, Ruers T, Nijkamp J. Accuracy assessment of target tracking using two  
327 5-degrees-of-freedom wireless transponders. *Int J Comput Assist Radiol Surg*. 2020;15(2):369-  
328 77.
- 329 6. Kok END, Eppenga R, Kuhlmann KFD, Groen HC, van Veen R, van Dieren JM, et al. Accurate  
330 surgical navigation with real-time tumor tracking in cancer surgery. *NPJ Precis Oncol*. 2020;4:8.
- 331 7. Scherl C, Männle D, Rotter N, Hesser J, Stallkamp J, Balkenhol T, et al. Augmented reality during  
332 parotid surgery: real-life evaluation of voice control of a head mounted display. *Eur Arch*  
333 *Otorhinolaryngol*. 2023;280(4):2043-9.
- 334 8. Scherl C, Stratemeier J, Karle C, Rotter N, Hesser J, Huber L, et al. Augmented reality with  
335 HoloLens in parotid surgery: how to assess and to improve accuracy. *Eur Arch*  
336 *Otorhinolaryngol*. 2021;278(7):2473-83.
- 337 9. Scherl C, Stratemeier J, Rotter N, Hesser J, Schönberg SO, Servais JJ, et al. Augmented Reality  
338 with HoloLens® in Parotid Tumor Surgery: A Prospective Feasibility Study. *ORL J*  
339 *Otorhinolaryngol Relat Spec*. 2021;83(6):439-48.
- 340 10. Ivan ME, Yarlagadda J, Saxena AP, Martin AJ, Starr PA, Sootsman WK, et al. Brain shift during  
341 bur hole-based procedures using interventional MRI. *J Neurosurg*. 2014;121(1):149-60.
- 342 11. Mohammadi A, Ahmadian A, Azar AD, Sheykh AD, Amiri F, Alirezaie J. Estimation of  
343 intraoperative brain shift by combination of stereovision and doppler ultrasound: phantom  
344 and animal model study. *Int J Comput Assist Radiol Surg*. 2015;10(11):1753-64.
- 345 12. Miga MI, Sun K, Chen I, Clements LW, Pheiffer TS, Simpson AL, et al. Clinical evaluation of a  
346 model-updated image-guidance approach to brain shift compensation: experience in 16 cases.  
347 *Int J Comput Assist Radiol Surg*. 2016;11(8):1467-74.
- 348 13. Kerawala CJ, Ong TK. Relocating the site of frozen sections--is there room for improvement?  
349 *Head Neck*. 2001;23(3):230-2.
- 350 14. Chang AM, Kim SW, Duvvuri U, Johnson JT, Myers EN, Ferris RL, et al. Early squamous cell  
351 carcinoma of the oral tongue: comparing margins obtained from the glossectomy specimen to  
352 margins from the tumor bed. *Oral Oncol*. 2013;49(11):1077-82.
- 353 15. Yokoi S, Nishio N, Fujimoto Y, Fujii M, Iwami K, Hayashi Y, et al. Feasibility of virtual surgical  
354 simulation in the head and neck region for soft tissue reconstruction using free flap: a  
355 comparison of preoperative and postoperative volume measurement. *Int J Oral Maxillofac*  
356 *Surg*. 2021;50(3):316-22.
- 357 16. Kamizono KI, Yoshida S, Yasumatsu R, Kadota H. Volumetric changes of transferred free  
358 anterolateral thigh flaps in head and neck lesions. *Auris Nasus Larynx*. 2021;48(4):751-7.
- 359 17. Pfeiffer M, Riediger C, Weitz J, Speidel S. Learning soft tissue behavior of organs for surgical  
360 navigation with convolutional neural networks. *Int J Comput Assist Radiol Surg*.  
361 2019;14(7):1147-55.

362





Figure



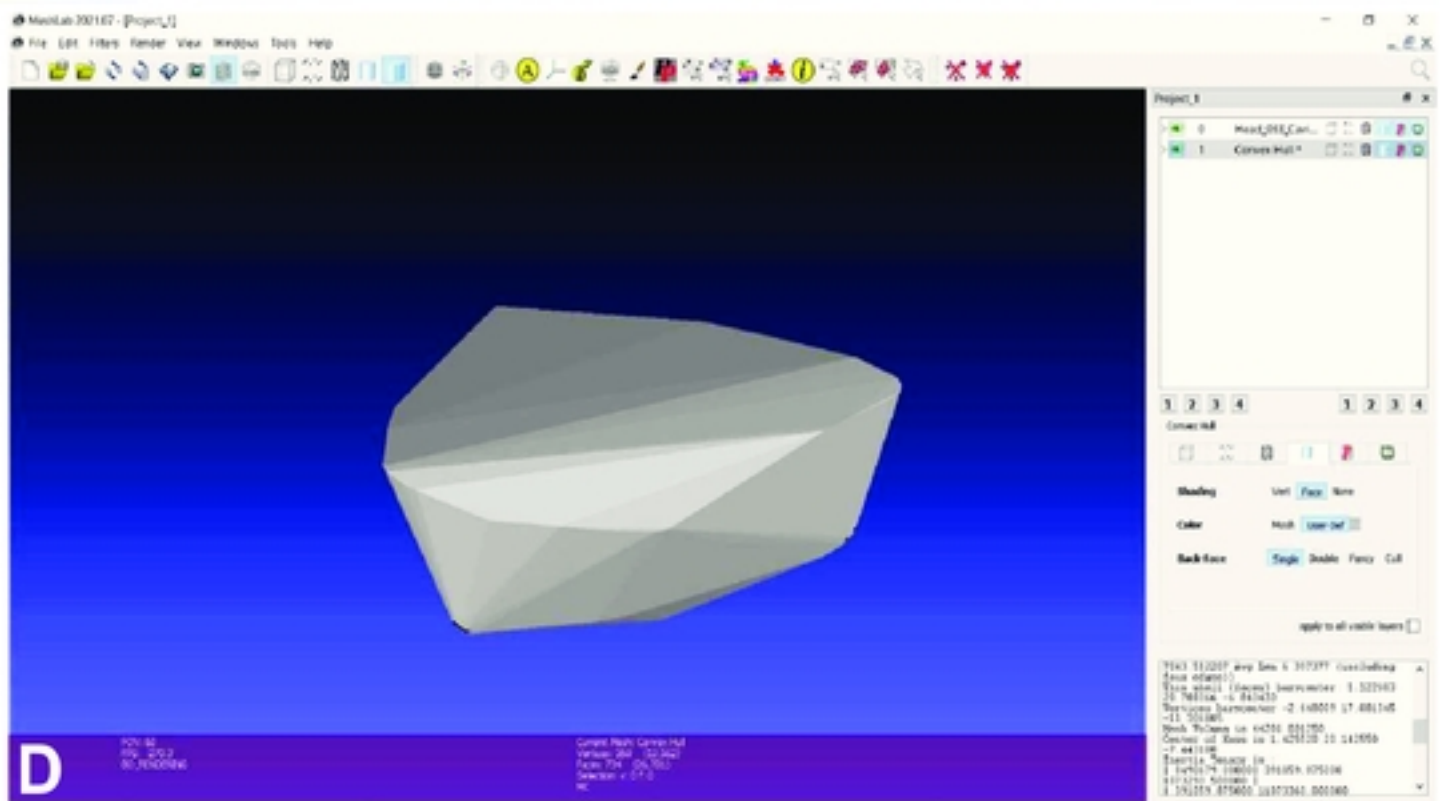
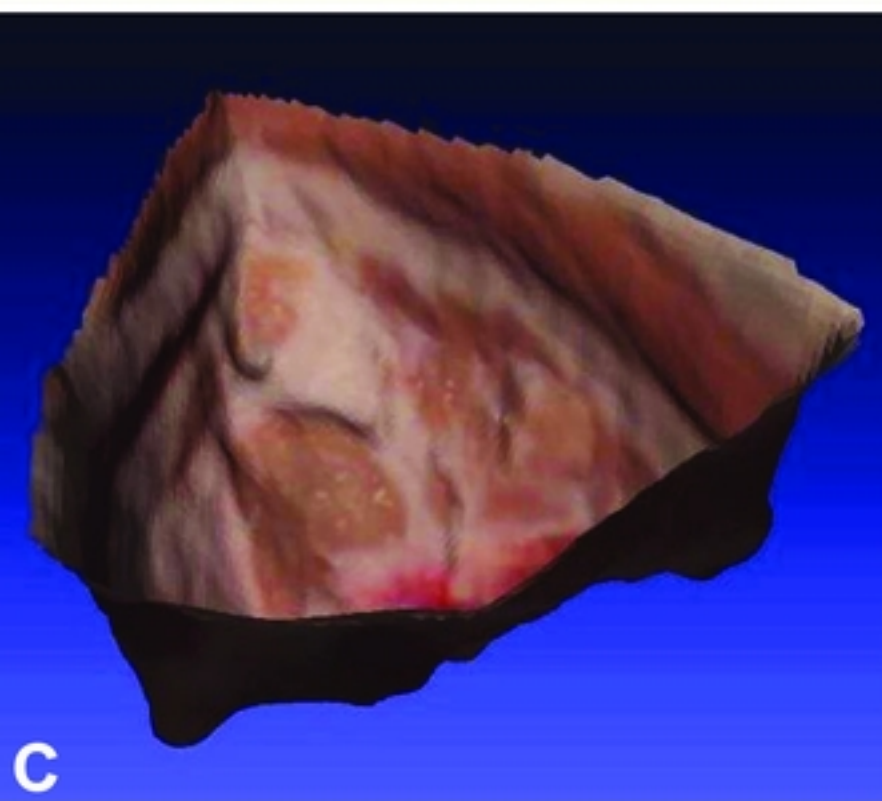
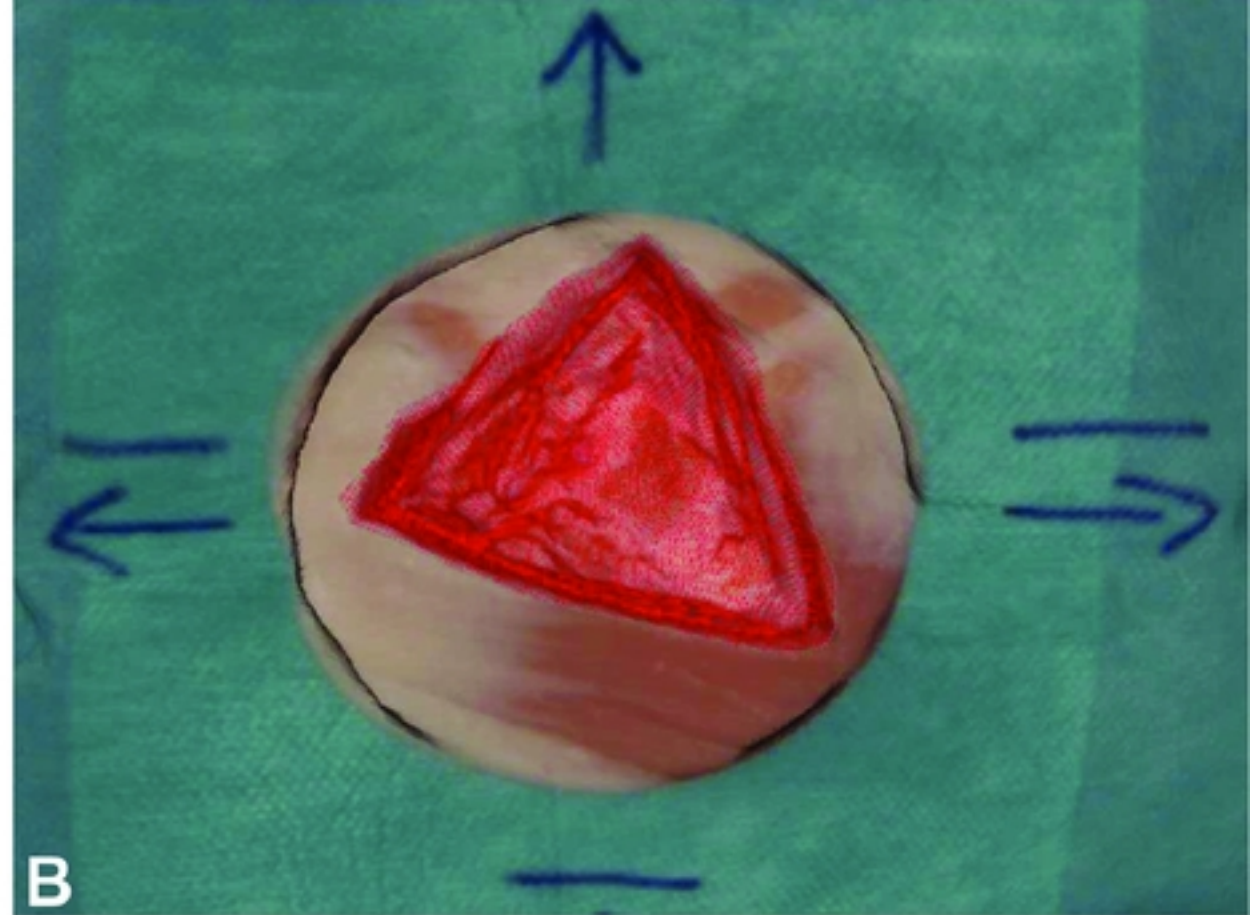
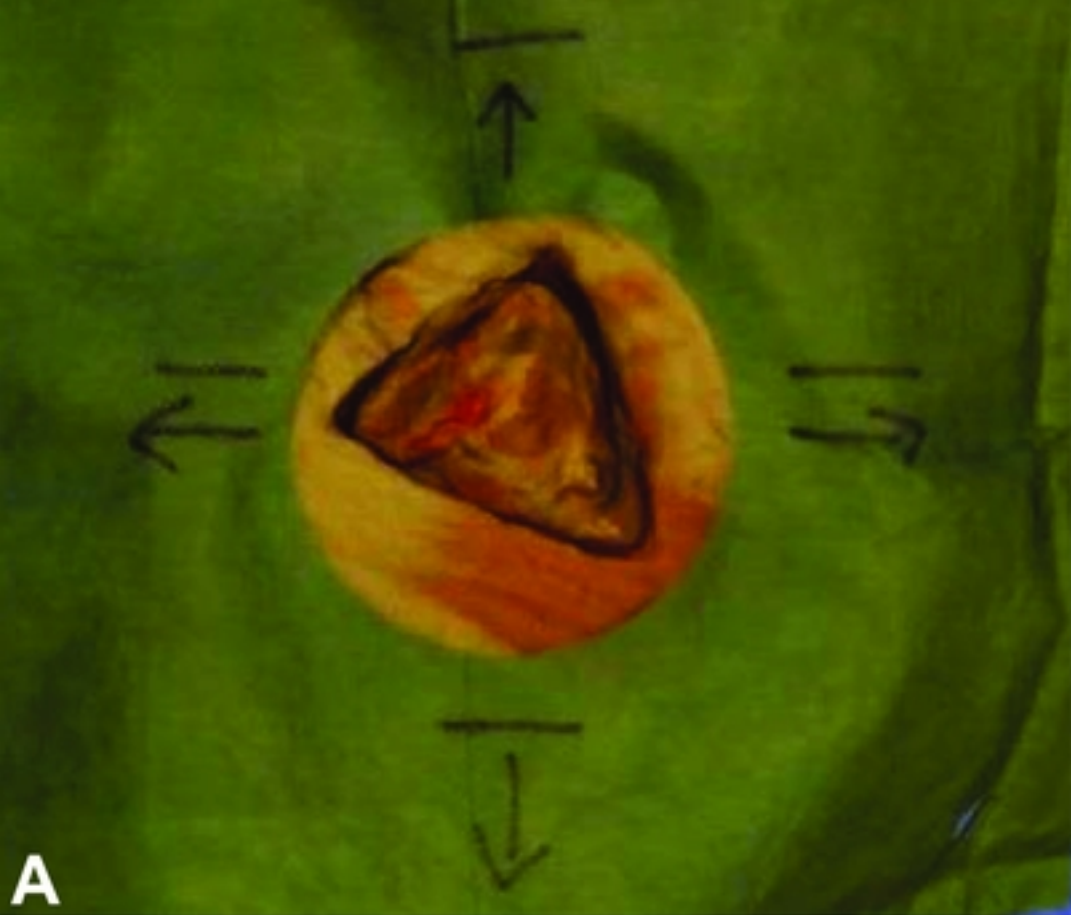
**A**



**B**

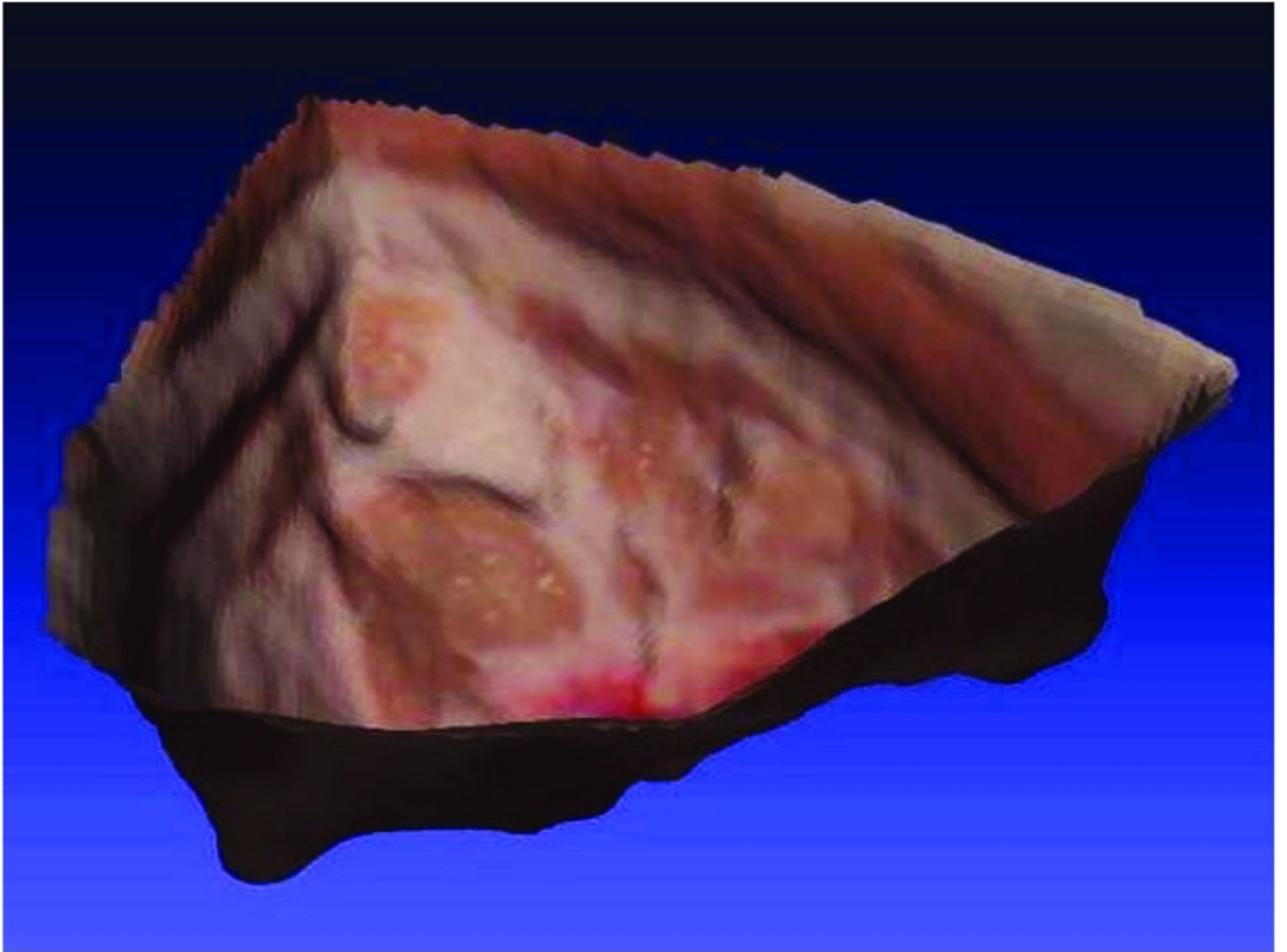
Figure



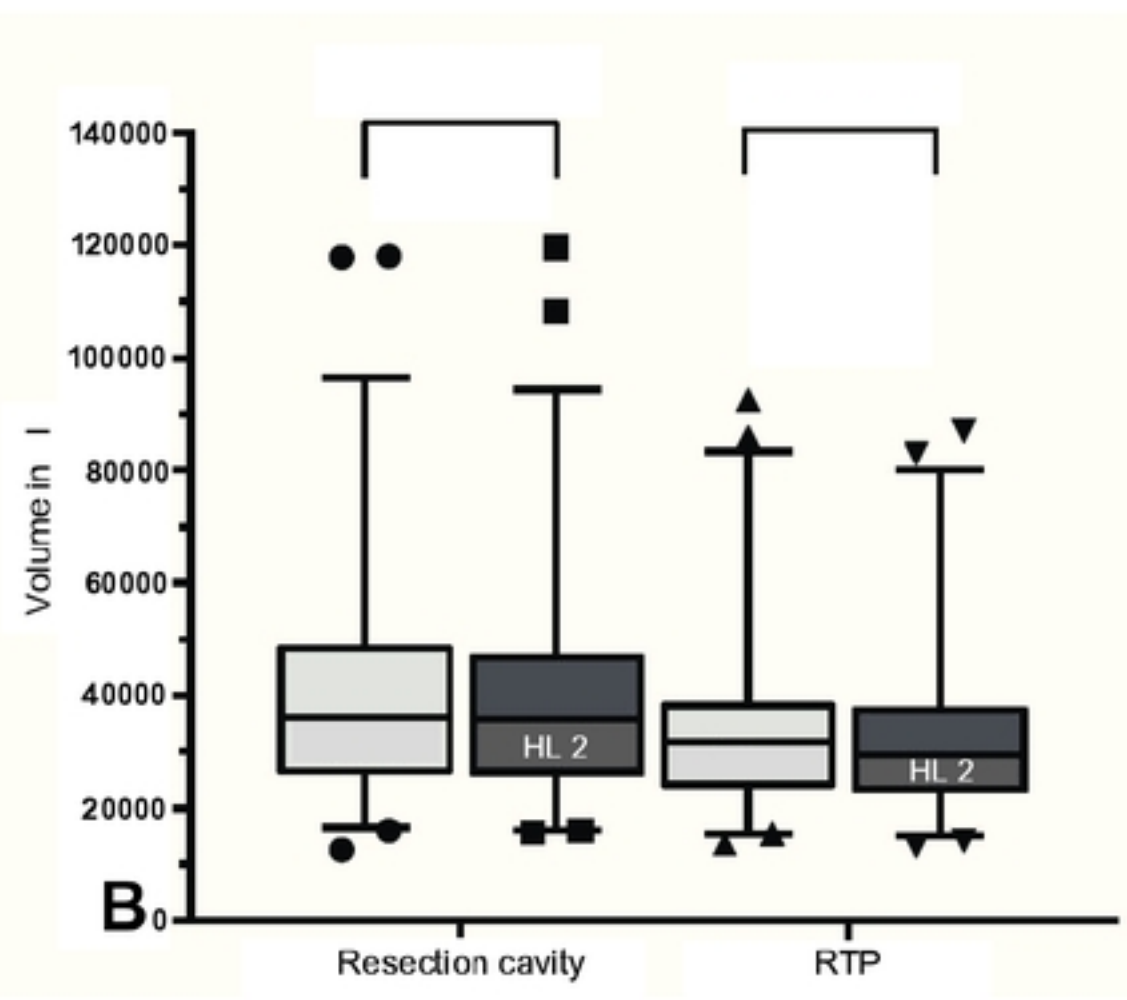
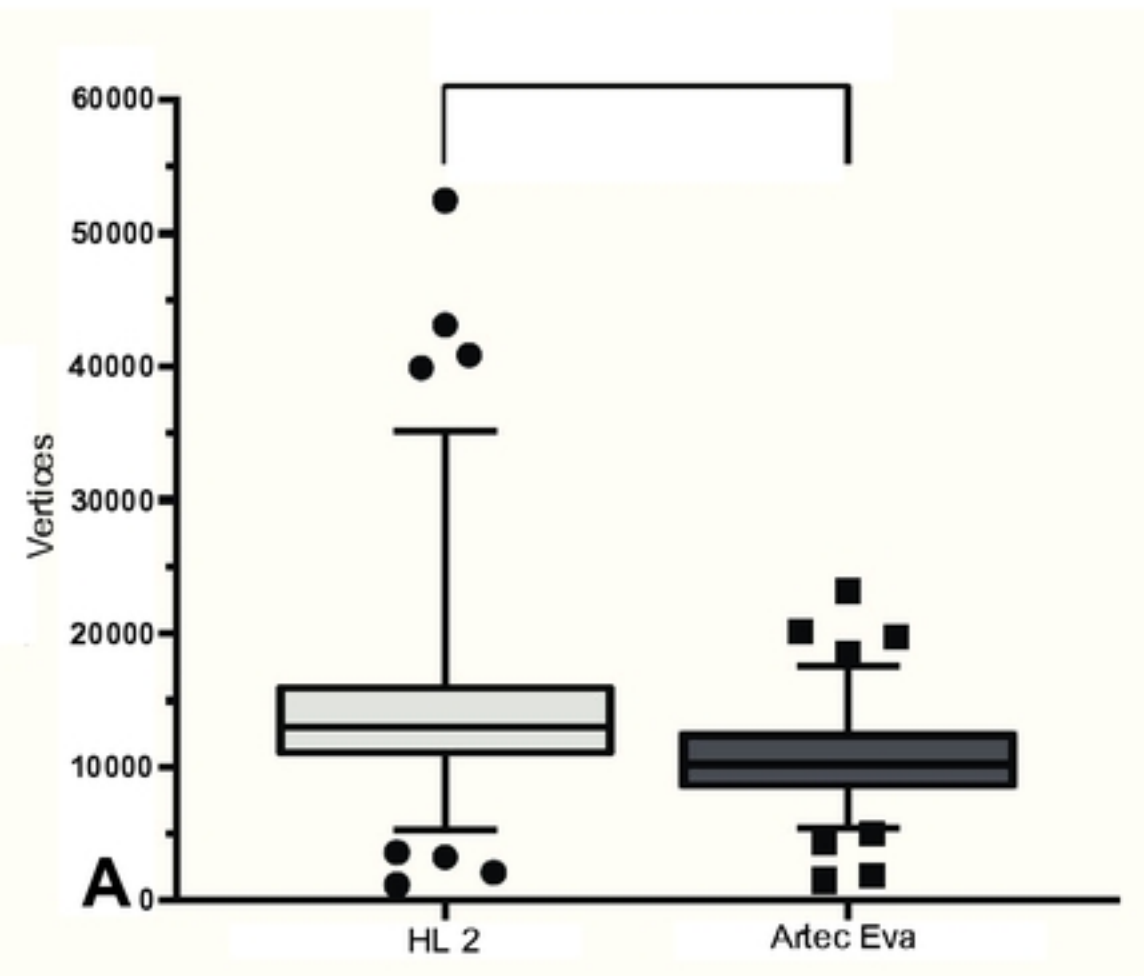


Figure

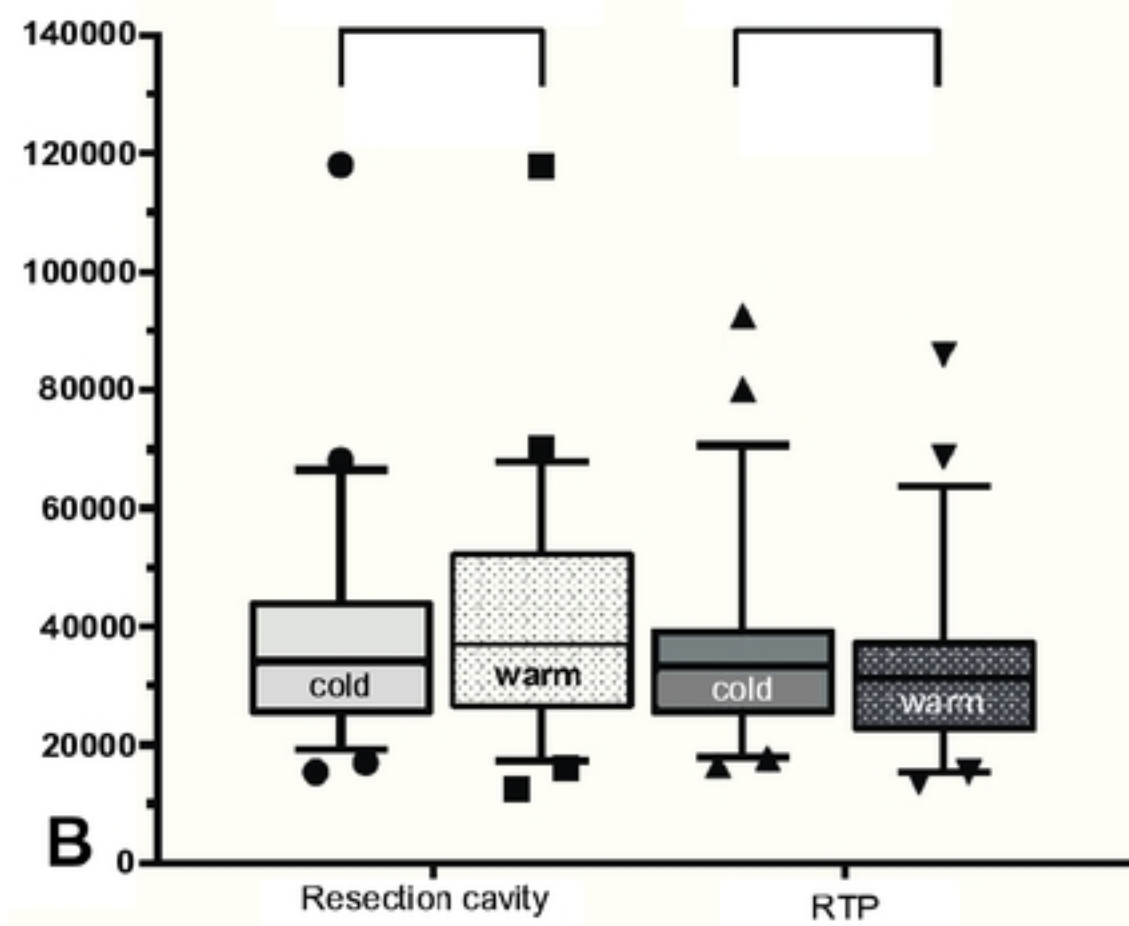
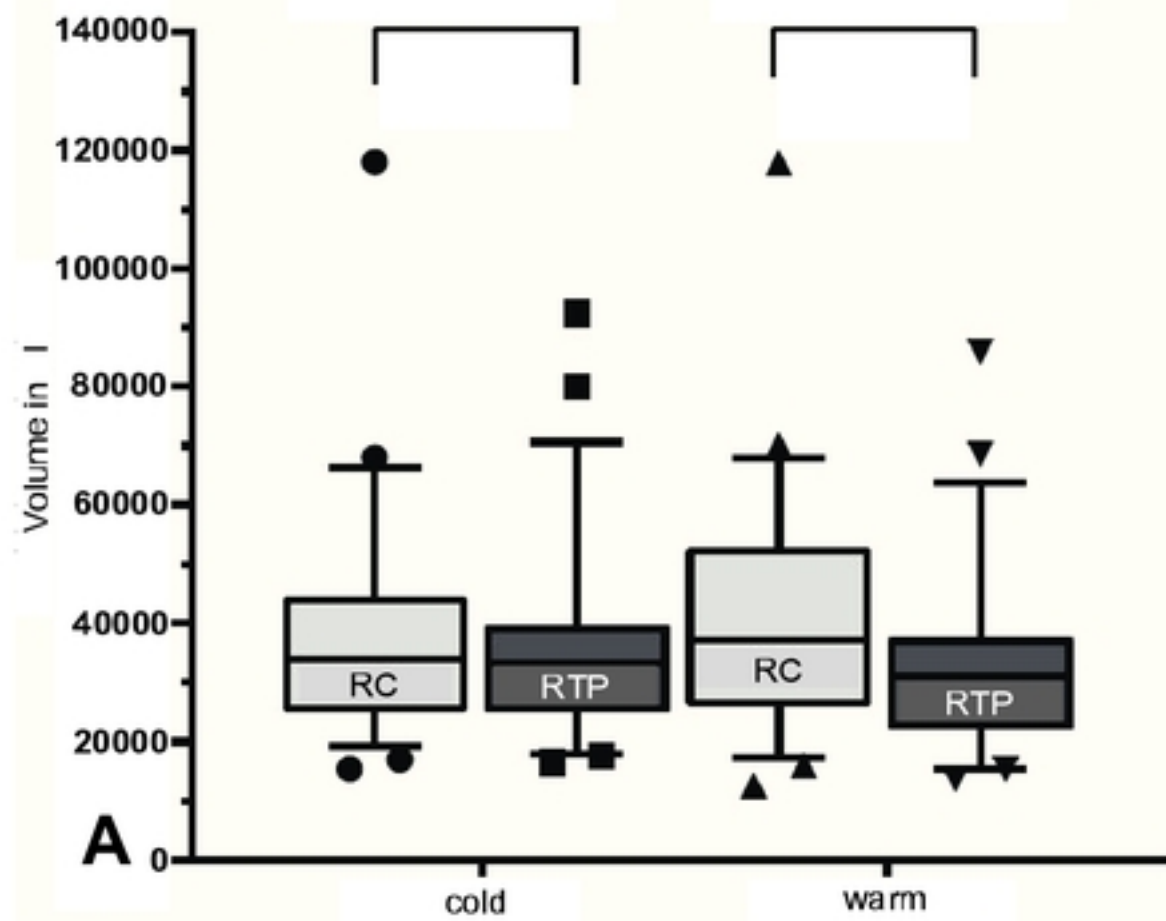




Figure



Figure



Figure