medRxiv preprint doi: https://doi.org/10.1101/2022.09.19.22280133; this version posted September 20, 2022. The copyright holder for this preprint (which was not certified by peer review) is the author/funder, who has granted medRxiv a license to display the preprint in perpetuity.

It is made available under a CC-BY-ND 4.0 International license .

Therapeutic and Interventional Bronchoscopy Performed in Critically ill COVID-19 patients: A Systematic Review

Saikat Samadder*

Saikat Samadder, The Oxford college of Science, HSR Layout, Bangalore-560102, Karnataka, India.

Corresponding Author: Saikat Samadder, The Oxford college of Science, HSR Layout, Bangalore-560102, Karnataka, India.

Email: saikat.samadder46@gmail.com

Phone: +91 9674-515-980

ORCID number: Saikat Samadder (0000-0001-8693-0863)

Author Contribution: Saikat Samadder solely contributed all the works related to research and manuscript preparation.

Supported by: No grants were obtained for this research work.

NOTE: This preprint reports new research that has not been certified by peer review and should not be used to guide clinical practice.

medRxiv preprint doi: https://doi.org/10.1101/2022.09.19.22280133; this version posted September 20, 2022. The copyright holder for this preprint (which was not certified by peer review) is the author/funder, who has granted medRxiv a license to display the preprint in perpetuity.

It is made available under a CC-BY-ND 4.0 International license .

Abstract:

Background: Coronavirus disease 2019 (COVID-19) is a highly infectious disease responsible for huge number of deaths in global population. Bronchoscopy was contraindicated for acute respiratory failure in critical patients due to possible transmission of virus to healthcare provider due to aerosol generating procedure (AGP). The safety, efficacy, complication rate, deaths, and transmission rate of virus to healthcare workers due to therapeutic and interventional bronchoscopy performed on COVID-19 patients are accessed.

Methods: A systematic review of literature was performed as per PRISMA 2020 guidelines. To obtain literatures available in PubMed, MEDLINE, and Google Scholars with timeline from 1st Jan 2020 – 10th Dec 2021. Databases were searched with MeSH terms bronchoscopy and COVID-19 it fetched 7350 articles. Applying primary inclusion criteria of bronchoscopy in COVID-19 patients. Secondary inclusion criteria therapeutic and interventional bronchoscopy excluding the articles on diagnostic bronchoscopy.

Result: Total 72 clinically relevant literatures were identified and included for further review. 1887/2558 patients underwent bronchoscopy for treatment of severe or critical COVID-19 pneumonia. therapeutic bronchoscopy was performed in 1241/1887 (65.8%) patients and interventional bronchoscopy was performed in 831/1887 (44.03%) patients. Overall, complications observed in 200/1887 (10.5%) patients. Total, 579/1887 (30%) patients died as per the literatures. Total 15 HCW (8%) were found infected during the studies. It led to successful completion of procedures in 924/940 (98.3%) patients. All three types of bronchoscopes were found to be safe for the patients. The safety, efficacy, complication rate to be 97.5%, and

medRxiv preprint doi: https://doi.org/10.1101/2022.09.19.22280133; this version posted September 20, 2022. The copyright holder for this preprint (which was not certified by peer review) is the author/funder, who has granted medRxiv a license to display the preprint in perpetuity.

It is made available under a CC-BY-ND 4.0 International license .

98.3%, and 2.5% respectively in severely SARS-CoV-2 infected patients undergoing bronchoscopy.

Conclusion: This study suggests that bronchoscopy is a safe and effective procedure to be performed in patients suffering from COVID-19 pneumonia. Proper use of personal protective equipments (PPE) during bronchoscopic procedure reduced the risk of transmission of the virus from the patients to the healthcare provider.

Key Words: SARS-CoV-2; COVID-19; Therapeutic Bronchoscopy; Flexible bronchoscope; Disposable bronchoscope; Pneumonia; Mucus plug; Aerosol generating procedure.

Introduction: In the past two years COVID-19 disease has imposed a major threat to the global population. As per WHO till 21st December 2021 there was more than 274 million infected cases and 5.3 million deaths globally. More than 8 billion doses of vaccines against SARS-CoV-2 were administered throughout the world [1]. Patients with comorbidities like diabetes, cardiovascular disease, cancer, pre-existing lung disease, liver and kidney diseases are at high risk of getting admitted to Intensive Care Unit (ICU) post acquiring severe pneumonia infection [2]. Several studies observed that aged male patients infected by SARS-CoV-2 are more likely to die and requires prolonged ICU stay regardless of treatment provided for saving these patients [3]. This virus successfully mutated as new variants known as alpha, beta, gamma, delta, epsilon, eta, theta, iota, kappa, lambda, and mu [4]. Delta variant and Omicron were reported to be more infectious than its predecessor evolving from Wuhan, China [4, 5].

Bronchoscopy is a widely used technique to diagnose different types of diseases associated with respiratory system. Bronchoscopy is one of the oldest medical device used by the surgeons since 1897 [5]. It is being successfully used to

medRxiv preprint doi: https://doi.org/10.1101/2022.09.19.22280133; this version posted September 20, 2022. The copyright holder for this preprint (which was not certified by peer review) is the author/funder, who has granted medRxiv a license to display the preprint in perpetuity.

It is made available under a CC-BY-ND 4.0 International license .

treat and diagnose various types of viral pneumonia caused by *cytomegalovirus*, *rhinovirus*, *Influenza* virus [7]. Bronchoscopes are used to diagnose tuberculosis, different types of suspected pulmonary carcinoma by bronchial wash, endobronchial ultrasound (EBUS), radial probe (RP-EBUS), transbronchial biopsy, bronchial brushing, needle aspiration, and forceps grasping of tissue for acquiring samples [8]. It is already in use for identifying the underlying diseased state of immunocompromised patients [9]. Bronchoscopy is considered AGP along with it various other procedures that are considered AGP are as follows; endotracheal intubation, open suctioning, administration of nebulized treatment, manual ventilation before intubation, turning the patient to the prone position, disconnecting the patient from the ventilator, non-invasive positive-pressure ventilation, tracheostomy, cardiopulmonary resuscitation, endo-tracheal aspiration (ETA), bronchoalveolar lavage (BAL), and bronchial aspiration (BA) [10]. Additionally, inadequate sedation, coughing during laryngoscopy, direct laryngoscopy, manual ventilation is associated risk of transmission of virus due to AGP (11). Fever and cough are the initial symptoms of this disease, presence of thick copious secretions is a major complication observed in critically-ill COVID-19 patients resulting in atelectasis.

Therapeutic and interventional bronchoscopy is an effective procedure utilized in severe or critically ill ICU admitted patients [12-15]. The use of therapeutic bronchoscopy was mainly used for the indications like acute lung failure, atelectasis, hyperaemia, routine clearance of obstructive airway in patient with lung transplantation due to COVID-19 pneumonia [16-21]. Studies suggested that the use of fibreoptic bronchoscopy helped to reduce tracheal intubation induced coughing and subsequent spread of virus [16]. In COVID-19 pneumonia patients therapeutic usage of bronchoscopy included, mucus plug and hematic secretion aspiration provided

medRxiv preprint doi: https://doi.org/10.1101/2022.09.19.22280133; this version posted September 20, 2022. The copyright holder for this preprint (which was not certified by peer review) is the author/funder, who has granted medRxiv a license to display the preprint in perpetuity.

It is made available under a CC-BY-ND 4.0 International license .

therapeutic benefit for the patients [17, 22, 23-24]. In COVID-19 patients the ETT jammed because of excessive secretions more frequently found in patients compared to pre-COVID respiratory illness [25]. While interventional procedures like reduction in lung volume, hemostasis of active bleeding, intubation, extubation, tracheostomy, FBA, surfactant delivery, and decannulation provided positive outcome for the ICU patients under prolonged mechanical ventilation [13, 26]. Percutaneous tracheostomy (PT) in the ICU patients is widely used to facilitate weaning from mechanical ventilation, to anticipate prolonged mechanical ventilation, to aid in the management of respiratory secretions and protect the airway in patients at risk of aspiration, to prevent laryngeal injury, and to minimize sedatives [27]. The therapeutic bronchoscopic procedure lasted for maximum 10 minutes, while guided PDT lasted for around 25-30 minutes for most of the COVID-19 patients [28-30].

A survey on response of physicians for use of bronchoscopy on intubated patients supported the use, found no associated risk on healthcare workers [31]. In COVID-19 pneumonia patient bronchoscopy is used for diagnosis of secondary bacterial or fungal infection, the use of diagnostic bronchoscopy was under-utilized, due to busy hospital environment and risk of AGP during the COVID-19 pandemic [32]. There are sufficient data pertaining to bronchoscopic diagnosis of secondary infections in COVID-19 patients and its efficiency to diagnose co-infection [33-34]. At present there is no review article available to determine the safety, efficacy, complications, deaths associated with the use of therapeutic and interventional bronchoscopy in COVID-19 patients. Among COVID-19 patients, gender, pregnancy, and age specific trends of death or complication post bronchoscopy is unknown. Various bronchoscopes disposable, rigid or standard

medRxiv preprint doi: https://doi.org/10.1101/2022.09.19.22280133; this version posted September 20, 2022. The copyright holder for this preprint (which was not certified by peer review) is the author/funder, who has granted medRxiv a license to display the preprint in perpetuity.

It is made available under a CC-BY-ND 4.0 International license .

utilized more frequently in COVID-19 patients was not evaluated and associated complications and risk of transmission to HCW are not assessed yet.

Methods: Systematic review of literature was done in PubMed, MEDLINE, and Google Scholars database further in INSPERO register from 1st Jan 2020 till 10th Dec 2021 as per PRISMA 2020 guidelines [35]. In Google Scholars database searches were performed with each terms "Bronchoscopic washings", "Bronchial aspirations", "Therapeutic bronchoscopy", "Toilet bronchoscopy", "Interventional bronchoscopy", "Foreign Body Aspiration" and "COVID-19". In PubMed and PMC databases advanced search was performed to retrieve articles specific to bronchoscopy in COVID-19 patients with MEDLINE and time as filter (1st Jan 2020- 10th Dec 2021). The specific search strings with MeSH terms (((Bronchial aspirations) OR (Pregnancy) OR (Airway management) OR (Suction) OR (Tracheostomy) OR (Trach) OR (Endotracheal tube) OR (Toilet Bronchoscopy) OR (Foreign Body) OR (Intubation) OR (Interventi*) OR (Therapeutic) AND (Bronchoscop*) AND (COVID-19) was used. During the initial screening articles in foreign language, duplicates and, in-vivo studies excluded. Under primary inclusion criteria clinical study reports presenting bronchoscopy in COVID-19 patients without any bar on age and gender included, non-bronchoscopy reports excluded. Articles suggesting practice, current understanding, guidelines, recommendations, considerations, review articles, ethical and consensus statements excluded. Secondary inclusion criteria included studies confirming COVID-19 by RT-PCR are included, studies with main focus on therapeutic and interventional bronchoscopy, excluding the articles on bronchoscopy in COVID-19 patients with diagnostic and evaluation purposes along with studies on tracheostomy. Bronchoscopy performed in patients to confirm certain suspected condition like mucosal ulceration, tracheomalacia, bronchiectasis, tracheal stenosis,

medRxiv preprint doi: https://doi.org/10.1101/2022.09.19.22280133; this version posted September 20, 2022. The copyright holder for this preprint **(which was not certified by peer review)** is the author/funder, who has granted medRxiv a license to display the preprint in perpetuity.

It is made available under a CC-BY-ND 4.0 International license .

pneumomediastinum etc. are excluded. Several studies isolated BAL using bronchoscope to identify microbes and modify the anti-microbial therapy for patients, such studies considered diagnostic rather than therapeutic usage. However, studies with information on both diagnostic and therapeutic/interventional bronchoscopy are included without any assumption on numbers. Articles with information on safety and efficacy were segregated and cumulative analysis of number with COVID-19 patients undergoing bronchoscopy is analyzed. Limited complications in patients and transmission of virus to healthcare professionals considered as safety information, the success rate in patients contributed to efficacy assessment cumulatively calculation shown (**Refer Supplementary Table 1-3**). The overall subjects in each studies are tabulated assessed and presented with percentage as outcome of study (**Refer figure 1**). No automation tool was used to search the literatures. Due to study type no ethical committee approval was acquired for this review. The author solely contributed all the works related to research.

Search Results: Upon performing searches in Google Scholars, PubMed and MEDLINE found 5196, 181, and 1973 articles respectively. No systematic review found in PROSPERO register searched with terms bronchoscopy and COVID-19. 2296 articles excluded duplicates, non-English articles, and in-vivo studies. 5054 articles screened for the clinical information of bronchoscopy in COVID-19 patients. Remaining 4189 articles excluded among those review articles. Among those 865 articles sorted for retrieval of non-clinical, and other clinical studies non-specific to bronchoscopy excluded (n=446). Potentially eligible 419 articles included for detailed screening therefore downloaded for further review, under secondary exclusion criteria 336 articles excluded for not confirming COVID-19 by RT-PCR, studies on laryngoscopy, tracheostomy, diagnostics and exploratory bronchoscopy. Lastly, 80

medRxiv preprint doi: https://doi.org/10.1101/2022.09.19.22280133; this version posted September 20, 2022. The copyright holder for this preprint **(which was not certified by peer review)** is the author/funder, who has granted medRxiv a license to display the preprint in perpetuity.

It is made available under a CC-BY-ND 4.0 International license .

articles included in study from search among those 72 clinical reports met all the criteria, 42 observational, prospective, retrospective, interventional, and cohort studies, 1 study was proof of concept, 8 case reports, and 21 case series found to have met the inclusion criteria are shown in **supplementary tables 4**. The data on diagnostic outcomes met rejection, only clinical information on therapeutic and interventional roles from those studies considered. The case series and case reports containing critical complications important for this study included. The flow-chart for systematic review of literature as per PRISMA 2020 guideline is presented in **Figure 1**.

Results: 72 clinical studies comprised of 2558 patients among them 1887 critically ill COVID-19 patients (74%) received various pulmonary treatment using bronchoscope. Bronchoscopy was performed in all age groups including infants, adolescents, adults, elderly male and female patients. Therapeutic bronchoscopy was performed in 1241/1887 (65.8%) patients, bronchoscopic removal of various forms of thick secretions, mucus plug, and aspiration of hematic clots performed in 1230/1241 (99.11%) patients, surfactant therapy was delivered to 7/1221 (0.56%) patients and FBA in 4 patients (0.32%) **refer Supplementary table 1 and 3**. Interventional bronchoscopy was performed in 831/1887 (44.03%) patients. Various procedures PDT 563/831 (67.7%) patients, other therapeutic interventions included ETT placement, lung volume reduction, air leakage verification, decannulation, extubation, intubation, stent/valves placement and for treatment of bleeding and airway injury in COVID-19 (28.5%) patients treated using bronchoscopy **refer Supplementary table 2 and 3.** There were 14 studies reported the use of both therapeutic and interventional bronchoscopy delivered in 871 patients, one study did not differentiate IB and TB with 31 patients **refer Supplementary table 3**.

medRxiv preprint doi: https://doi.org/10.1101/2022.09.19.22280133; this version posted September 20, 2022. The copyright holder for this preprint **(which was not certified by peer review)** is the author/funder, who has granted medRxiv a license to display the preprint in perpetuity.

It is made available under a CC-BY-ND 4.0 International license .

Overall, complications found to be 200/1887 (10.5%) patients. Whereas, bronchoscopy related complications noted in 47/1837 (2.49%) patients for mild desaturation 22 patients, mild hemoptysis in 6, ETT displaced in 3, fever in 2, required intubation for 2 patient, no improvement in 4 patients, 1 bronchoscope technical problem and 7 others events related. Major bleeding, infection, and pneumothorax not observed in patients with SARS-CoV-2 infection undergoing bronchoscopy. In 11 studies involving 396 patients not reported about deaths, 32 authors reported that no deaths observed among 227 patients. Total, 579/2558 (20%) patients died as per the literatures, bronchoscopy related deaths not found. The procedure was well tolerated in most of the patients there was no death directly caused by its use of bronchoscopy. In 11 studies, 70 COVID-19 patients underwent bronchoscopy and no complications or deaths were noted (**Refer Supplementary table 1, 2 & 3**).

In 12 articles the bronchoscope was found to be both safe and effective in patients. In 26 studies the use of bronchoscope was found to be safe for 1151 patients with severe COVID-19 among them 20 authors reported in their study bronchoscopes are safe for HCWs. In 58 studies the use of bronchoscopy was successful, led to effective completion of attempted procedures in 924/940 (98.2%) patients. In 7 studies bronchoscopy showed lack of efficacy on 13 patients and 1 bronchoscopy technical problem during ongoing procedure resulted in 14/940 (1.7%) inefficacy in infected patients.

Male to female ratio was high in majority of studies, 8 studies with 397/2558 patients did not report gender of patients. In 64 studies total male 1563/2161 (72.3%) patients required more ICU admission than females therefore it is eminent that number of bronchoscopies performed more compared to female 598/2161 (27.6%)

medRxiv preprint doi: https://doi.org/10.1101/2022.09.19.22280133; this version posted September 20, 2022. The copyright holder for this preprint (which was not certified by peer review) is the author/funder, who has granted medRxiv a license to display the preprint in perpetuity.

It is made available under a CC-BY-ND 4.0 International license .

patients (**Refer Supplementary table 4**). In 33 studies 15/423 (3.5%) HCW infected with SARS-CoV-2 during their study period. Various studies referred either of the terms fibreoptic, bedside, flexible or portable bronchoscopes to designate the use of standard bronchoscopy. There is no major difference in complication rate caused by disposable bronchoscope in 4/38 (10.5%) patients reported in 17 studies, compared to standard bronchoscopes in 32/128 (19.7%) patients reported in 21 studies. Disposable bronchoscopes more frequently used in high income countries than in low or middle income nations. Majority of the studies conducted in countries like USA, Italy, and China (**refer Supplementary figure 4)**. The overall results including success rate, mortality, efficacy, complications, rate of transmission to HCWs, type of bronchoscopes used, and number of studies per country are shown in **table 1**.

Discussion:

Therapeutic Bronchoscopy in Critical patients: Therapeutic bronchoscopy is a potential procedure used to clear the airway obstruction caused by thick mucus secretions. It is useful for patients with severe or critical condition, deposition of excessive mucus or secretions are commonly seen in these COVID-19 patients (25, 18, 20-21, 36-37). Bronchoscopy should not be performed in COVID-19 patients with severe respiratory insufficiency managed under non-invasive mechanical ventilation (12). Removal of mucus plug, gelatinous mucus, thick hematic secretions caused due to hyperaemia, bronchoscopy was a lifesaving procedure for these patients [38, 39, 40, 41, 42]. Thick mucus plug resulted in airway obstruction and difficulty in ventilation (43-44). Atelectasis in patients require immediate medical attention for clearance of debris and it substantially increased oxygenation (45-47 & 17). Due to prolonged ventilation, veno venous extracorporeal mechanical oxygenation (VV-ECMO), and tracheostomy patients requires flushing out of pneumothorax (48-50). Several studies

medRxiv preprint doi: https://doi.org/10.1101/2022.09.19.22280133; this version posted September 20, 2022. The copyright holder for this preprint (which was not certified by peer review) is the author/funder, who has granted medRxiv a license to display the preprint in perpetuity.

It is made available under a CC-BY-ND 4.0 International license .

reported usefulness of therapeutic bronchoscopy among those very few found bronchoscopy ineffective and technical problem in patients [51, 11, 21, 25]. Bhatraju et al. reported in their study 17 patients required bronchoscopy without any secondary infection, however patients required vasopressors. Active use of heated humidification or moist heated humidifiers was used in several studies that reduced bronchoscopy time (23, 25). Bronchoscopy was successfully performed in 2 positive patients for mucus secretions aspiration and FBA removal (52). Foreign body aspiration was done only in few patients with COVID-19, mostly FBA was done once the RT-PCR test turned negative [53]. The presence of haematic secretions in the distal bronchial tract was found to the reason of high mortality in patients (50). In one COVID-19 patient chest drain was performed due to pneumothorax but oxygenation status did not change post bronchoscopic suction of mucus plug (54). Pulmonary toilet was done by the use of bronchoscopes to remove mucus and secretions in COVID-19 patients [55, 29-30].

In a study laryngoscopy and tracheostomy resulted in tissue laceration resulting in death of 4 patients, the patients who died are older than patients who survived (56). There was no significant difference in-hospital mortality or ICU admission of COVID-19 positive patients compared to negative patients respectively [50]. The COVID-19 disease trends to affect less and has mild clinical course in pregnant women compared to influenza [57]. Post-partum COVID-19 related complications exacerbates, severity in these women are rare during pregnancy and therapeutic bronchoscopy could be performed successfully post-delivery [45-46, 58-59]. In infants or pediatric patients bronchoscopy proved to be a safe therapeutic device used for mucus plug removal [40, 52-53, 60]. In elderly patients with COVID-

medRxiv preprint doi: https://doi.org/10.1101/2022.09.19.22280133; this version posted September 20, 2022. The copyright holder for this preprint (which was not certified by peer review) is the author/funder, who has granted medRxiv a license to display the preprint in perpetuity.

It is made available under a CC-BY-ND 4.0 International license .

19 requiring lung transplant underwent routine therapeutic bronchoscopy no complications seen in patients caused by its regular usage (19-20).

Interventional Bronchoscopy in Critical Patients: Interventional bronchoscopy is a useful technique to reduce the disease burden of severe or critical SARS-CoV-2 pneumonia [61, 13]. Bronchoscopy guided tracheostomy is a very useful technique for reducing mortality in ICU [62-63, 64, 11]. Various types of interventional bronchoscopy performed in critical COVID-19 patients to complement endotracheal intubation (ETT), orotracheal intubation, (OTT) repositioning, bronchoscopic percutaneous dilational tracheostomy, stent and valve placement, embolization of airway bleeding, air leakage detection, lung volume reduction, bronchoscopic assessment pre-decannulation and decannulation were performed [25, 12, 50, 65-66, 56, 22]. Meyer et al. reported bronchoscope guided PDT decreased the risk of bleeding in comparison to open tracheostomies, considering the high rate of anti-coagulation therapy required for these patients. Guided PDT reduced transmission of virus to HCWs from critically ill COVID-19 patients [15, 68-69], although there was no major difference in complication rate in PDT compared to open tracheostomy [64, 61]. However, in a pre-COVID study demonstrated that use of bronchoscopes did not affect the overall outcome in patients with open or percutaneous tracheostomy [70]. Early PDT for COVID-19 patients was found related to reduced stay in ICU than those underwent delayed PDT [71]. The use of bronchoscopes for ETT placement reduced aerosolization process (69, 68). Therefore, possibly no transmission to bronchoscopists could be identified in studies related to bronchoscopy guided PDT in infected patients (**Refer Supplementary table 2-3**). The survival rate post-tracheobronchial stents placement found to be only 3-4 months in patients with malignant airway disease; the one-year survival rate was reported to be 15% (65). In

medRxiv preprint doi: https://doi.org/10.1101/2022.09.19.22280133; this version posted September 20, 2022. The copyright holder for this preprint (which was not certified by peer review) is the author/funder, who has granted medRxiv a license to display the preprint in perpetuity.

It is made available under a CC-BY-ND 4.0 International license .

few studies mortality rate post-tracheostomy was reported to be below 8% in COVID-19 patients (72).

Complications Observed in Patients: In a randomized controlled study with COVID-19 and non-COVID-19 patients found tracheal and thoracic complications only in COVID-19 patients (73). Tracheal complications included lesions and tracheoesophageal fistulas, the thoracic complications included pneumothorax, pneumomediastinum, and subcutaneous emphysema are commonly observed in COVID-19 patients during bronchoscopy (73, 56). The COVID-19 patients supine or prone positioned during bronchoscopy did not change the course of patient's hospital stay and no complications observed (74, 28). Bronchoscopy was not performed in pregnant women with severe COVID-19, bronchoscopy was considered safe post-partum. Therefore, no complications related to bronchoscopy could be observed during gestational period (45-46, 59). Bronchoscopy guided intubation in COVID-19 patients could be considered safe strategy, as mild desaturation could be observed [11, 75]. Therapeutic bronchoscopy delivered to pediatric or young patients was safe for severe COVID-19 pneumonia (60, 40).

The main complications observed in patients related to bronchoscopy in COVID-19 patients were no improvement in very few patients, minor bleeding, cellulitis, drop in oxygen saturation (SpO2) <90%, or desaturation, pneumothorax, site irritation, mild respiratory failure, and difficult to swallow were common during pre-COVID-19 era [71, 76, 35, 77, 21]. Several studies reported patient underwent bronchoscopic aspiration of secretions but died due to disease progression without mentioning any complication related to bronchoscope [78, 79, 26]. Technical problem and difficulty in swallowing two complications of bronchoscope observed in two studies, both used disposable bronchoscopes [25]. Complications were more often due

medRxiv preprint doi: https://doi.org/10.1101/2022.09.19.22280133; this version posted September 20, 2022. The copyright holder for this preprint (which was not certified by peer review) is the author/funder, who has granted medRxiv a license to display the preprint in perpetuity.

It is made available under a CC-BY-ND 4.0 International license .

to PDT and tracheostomy leading to major or minor bleeding, delayed complications, cellulitis, infection and pneumothorax [71, 27, 80, 69, 81-84, 73]. Events valve migration, ETT dislodgement in patients was not associated to bronchoscopy [85, 49]. Major bleeding, hemoptysis, and delayed bleeding was rare after therapeutic bronchoscopy and was found in patients undergoing bronchoscopy guided PDT (49, 77). Bronchoscopy guided tracheostomy caused majority of adverse events in COVID-19 patients compared to other interventional bronchoscopy or therapeutic bronchoscopic procedures (61, 86, 3, 82, 81, 56, 87). Bronchoscopes were not responsible for occurrence of any major events in severely ill patients undergone PDT (**Refer Supplementary figure 2-3**). Numerous articles could be found related to open and guided tracheostomy a separate meta-analysis should be conducted in COVID patients to understand the safety and efficacy of both procedures. The major complications found are not associated to its usage.

Mortality Rate: None of the articles reported the death of the patients due to the use of bronchoscopes. Death of the patients were mainly related to disease progression in patents and due to prolonged stay in ICU [17, 45, 59, 50]. There was no mortality reported in bronchoscopists performing the maneuvers. Age, mucus plugs, hematic secretions and mucosal hyperaemia was found to be major contributor for in-hospital mortality of COVID-19 pneumonia patients (50). Bronchoscopy was not considered as a worse prognostic factor for predicting mortality in COVID-19 patients (25). Bahatraju et al. reported in their multi-center case series deaths occurred in 12 out of 24 patients with do not resuscitate orders, two of their patients received TB it is unknown if patients died, as the clinical course did not change for these patients. Botti et al. reported patients did not die due to bronchoscopy or open/closed tracheostomy and possible cause of death was severe ARDS. Deaths were reported to be caused by

medRxiv preprint doi: https://doi.org/10.1101/2022.09.19.22280133; this version posted September 20, 2022. The copyright holder for this preprint (which was not certified by peer review) is the author/funder, who has granted medRxiv a license to display the preprint in perpetuity.

It is made available under a CC-BY-ND 4.0 International license .

ARDS, increase in viral replication, multi-organ failure, mechanical ventilation, open tracheostomy and PDT (45, 88, 71, 72, 3, 83, 81). Lacerations caused deaths of patients, could be due to the infection or post tracheostomy event not relevant to therapeutic usage of bronchoscopes [56, 73].

Infection in Healthcare Providers: Overall, 15 HCW reportedly infected with SARS-CoV-2 virus during the course of their routine participation in study. However, none of the studies reported that any of these transmission could be due to the bronchoscopic procedure [16, 24, 76, 28]. These infections were not transmitted from patients in ICU wards as there was no outbreak of viral infections observed among other HCW present associated with the same bronchoscopic procedures [52]. Thereby, suggesting that the procedure is safe for the bronchoscopists, as maximum precautionary measures were adapted to reduce the aerosolization process [26, 52-53, 55, 59, 89].

Additionally, it was well documented in each of the studies that proper use of personnel protection equipment (PPE), googles, double gloves, cap, shoe cover, visor, gown, and filtering face piece level 3 (FFP3) mask [54, 56]. Use of positive pressure hood, bronchoscopy under negative pressure ventilation, regular body temperature checks for HCWs, and weekly RT-PCR. Compliance with reprocessing of bronchoscopes reduced the rate of transmission and co-infection in patients (3, 68, 86, 75, 29). The HCWs performing high risk maneuvers during 2020-2021 pandemic were comparatively safer than those performed tracheal intubations in SARS-CoV-1 epidemic (90). During SARS-CoV-1 epidemic 53 HCWs infected from the high risk procedure such as intubation (91).

medRxiv preprint doi: https://doi.org/10.1101/2022.09.19.22280133; this version posted September 20, 2022. The copyright holder for this preprint (which was not certified by peer review) is the author/funder, who has granted medRxiv a license to display the preprint in perpetuity.

It is made available under a CC-BY-ND 4.0 International license .

Types of Bronchoscopes Used for Therapeutic Benefits: Disposable bronchoscopy was used in 14 studies mainly high income countries, utilized single use bronchoscopes, while middle income countries used traditional standard bronchoscopes. Rigid bronchoscopy used in small number of patients in 6 studies all patients survived without any major complication **refer supplementary table 1**. Disposable bronchoscopes were found to have least number of complications caused by it (86, 25), compared to standard bronchoscopes which were responsible for few mild-moderate events (14, 74, 21, 11, 51, 45, 76, 56). Cheap and affordable re-useable bronchoscopes would be beneficial for reducing infections lower or middle income countries, presently are less utilized. Disposable or standard fibreoptic bronchoscopes usage did show any major difference in transmission rate to HCWs.

Limitations: Long-term follow-up data on patient's death was not available in many articles, due to their study design therefore the mortality rate is calculated based on data available. In few studies gender of subjects was not available so it was difficult to identify exact number of males and females included in the studies. In majority of the studies number of bronchoscopists participating in the studies not reported. There could be an overall risk of bias due to low number of randomized controlled trial included in this review, inconsistency, indirectness, and imprecision not assessed for each studies included.

Conclusion: Bronchoscopy is a very potential tool available for diagnosis and treatment of various respiratory diseases [22, 79]. It was widely used during the pandemic to diagnose co-infection in patients, to overrule false RT-PCR results from the nasopharyngeal samples and to change antibiotics to mitigate life threatening situations caused by co-infection [38]. This study is important because until December 2021 there were no anti-viral drug available in market globally to treat the

medRxiv preprint doi: https://doi.org/10.1101/2022.09.19.22280133; this version posted September 20, 2022. The copyright holder for this preprint (which was not certified by peer review) is the author/funder, who has granted medRxiv a license to display the preprint in perpetuity.

It is made available under a CC-BY-ND 4.0 International license .

critically ill COVID-19 pneumonia patients, and bronchoscopy demonstrated a reliable tool for treatment of various critical conditions. The procedure was well tolerated in most of the patients there was no major complications or death directly caused by its usage. There were no severe irreversible or new adverse event found related to bronchoscopy treatment in patients with critical COVID-19. This study favors the use of bronchoscope for the clearance of lung blockage and for rescuing oxygenation status in patients, and helped to overcome other detrimental situations resulted by interventional procedures or prolonged ICU stay and progression of viral pneumonia [12]. The use of bronchoscope reduced the lung blockage caused by various forms of increased mucus secretions these are more commonly seen only in COVID-19 pneumonia patients, unlike patients with other respiratory diseases [74, 92, 25, 17]. Therefore, treatment using heat moist exchanger or humidifiers, surfactant, expectorant, and nebulization therapy could be useful for aspiration of thick mucus reducing the time of bronchoscopic procedure and increasing overall efficacy [26, 36, 23, 25]. During the early phase of COVID-19 pandemic bronchoscopy and laryngoscopy use was reduced (32, 91). In future epidemic and pandemic situations, bronchoscope could be effectively used without delay as per the need in ICU under appropriate precautionary measures.

Conflicts of Interest: The author was involved in clinical evaluation reports writing in HCL technologies India for Olympus bronchoscopes from Mar 2021 - May 2021. However, author neither received any funding directly from Olympus during this tenure nor authored any reports and there is no influence of any bronchoscope manufacturer in preparation of this manuscript.

Funding Sources: This research did not receive any kind of specific grant from funding agencies of public, commercial, or non-profit domain.

medRxiv preprint doi: https://doi.org/10.1101/2022.09.19.22280133; this version posted September 20, 2022. The copyright holder for this preprint **(which was not certified by peer review)** is the author/funder, who has granted medRxiv a license to display the preprint in perpetuity.

It is made available under a CC-BY-ND 4.0 International license .

Acknowledgement: The author would like to thank Dr. Levra (University of Torino, Italy) for clarification of doubts. I extend my gratitude and appreciation to all health-care workers who provided and cared for the study subjects during the COVID-19 pandemic despite of transmission risk.

Reference:

1. WHO | WHO Coronavirus (COVID-19) Dashboard. Accessed on 12 Dec 2021. Website: https://covid19.who.int/

2. Sanyaolu A, Okorie C, Marinkovic A, Patidar R, Younis K, Desai P, et al. Comorbidity and its Impact on Patients with COVID-19. SN Compr Clin Med. 2020 Jun 25:1-8. doi: 10.1007/s42399-020-00363-4. PMID: 32838147.

3. Chao TN, Harbison SP, Braslow BM, Hutchinson CT, Rajasekaran K, Go BC, et al. Outcomes After Tracheostomy in COVID-19 Patients. Ann Surg. 2020 Sep 1;272(3):e181-e186. doi: 10.1097/SLA.0000000000004166.

4. WHO | Tracking SARS-CoV-2 variants | Accessed on 5 May 2022. https://www.who.int/activities/tracking-SARS-CoV-2-variants.

5. Torjesen I, Covid-19: Omicron may be more transmissible than other variants and partly resistant to existing vaccines, scientists fear. BMJ 2021;375:n2943 http://dx.doi.org/10.1136/bmj.n2943

6. Panchabhai TS and Mehta AC, Historical Perspectives of Bronchoscopy Connecting the Dots. Ann Am Thorac Soc. May 2015;12,5:631–641 DOI: 10.1513/AnnalsATS.201502-089PS.

7. Baron A, Hachem M, Tran Van Nhieu J, Botterel F, Fourati S, Carteaux G et al. Bronchoalveolar Lavage in Patients with COVID-19 with Invasive Mechanical Ventilation for Acute Respiratory Distress Syndrome. Ann Am Thorac Soc. 2021;18(4):723-726. doi:10.1513/AnnalsATS.202007-868RL.

8. Andolfi M, Potenza R, Capozzi R, Liparulo V, Puma F, Yasufuku K et al. The role of bronchoscopy in the diagnosis of early lung cancer: a review. J Thorac Dis 2016;8(11):3329- 3337 doi: 10.21037/jtd.2016.11.81

9. Jain P, Sandur S, Meli Y, Arroliga AC, Stoller JK, and Mehta AC et al. Role of Flexible Bronchoscopy in Immunocompromised Patients with Lung Infiltrates. CHEST 2004; 125:712–722. doi: 10.1378/chest.125.2.712.

10. Klompas M, Baker M, Rhee C. et al. What Is an Aerosol-Generating Procedure? JAMA Surg. 2021;156(2):113-114. doi:10.1001/jamasurg.2020.6643

11. Wu CN, Xia LZ, Li KH, Ma WH, Yu DN, Qu B,et al. High-flow nasal-oxygenation-assisted fibreoptic tracheal intubation in critically ill patients with COVID-19 pneumonia: a prospective randomised controlled trial. Br J Anaesth. 2020 Jul;125(1):e166-e168. doi: 10.1016/j.bja.2020.02.020.

medRxiv preprint doi: https://doi.org/10.1101/2022.09.19.22280133; this version posted September 20, 2022. The copyright holder for this preprint **(which was not certified by peer review)** is the author/funder, who has granted medRxiv a license to display the preprint in perpetuity.

It is made available under a CC-BY-ND 4.0 International license .

12. Guarino C, Cesaro C, Fiorentino G, Rossi F, Polverino BM, Fragranza F, et al. Bronchoscopy in COVID-19 patients: When, how and why. Experience in clinical practice. Monaldi Arch Chest Dis. 2021 Mar 2;91(2). doi:10.4081/monaldi.2021.1744.

13. Cumbo-Nacheli Gustavo, Colt Henri, Agrawal A, Cicenia J, Corbetta L, Goel, AD. et al. Bronchoscopy in Patients with Known or Suspected COVID-19, Journal of Bronchology & Interventional Pulmonology: April 2022 - Volume 29 - Issue 2 - p 146-154 doi: 10.1097/LBR.0000000000000805

14. Mondoni M, Sferrazza Papa GF, Rinaldo R, Faverio P, Marruchella A, D'Arcangelo F, et al. Utility and safety of bronchoscopy during the SARS-CoV-2 outbreak in Italy: a retrospective, multicentre study. Eur Respir J. 2020 Oct 15;56(4):2002767. doi: 10.1183/13993003.02767- 2020.

15. Sood RN, Palleiko BA, Alape-Moya D, Maxfield MW, Holdorf J, Uy KF et al. COVID-19 Tracheostomy: Experience in a University Hospital with Intermediate Follow-up. J Intensive Care Med. 2021 Dec;36(12):1507-1512. doi: 10.1177/08850666211043436.

16. Levra S, Veljkovic A, Comune M, Bernardi V, Sandri A, Indellicati D et al. Bronchoscopy in times of COVID-19 pandemic: An interventional pulmonology unit experience. Respir Med Res. 2021 Nov;80:100830. doi:10.1016/j.resmer.2021.100830.

17. Chang SH, Jiang J, Kon ZN, Williams DM, Geraci TC, Smith DE, et al. Safety and Efficacy of Bronchoscopy in Critically Ill Patients With Coronavirus Disease 2019. Chest. 2021 Feb;159(2):870-872. doi: 10.1016/j.chest.2020.09.263.

18. Guo WG, Fang B, Xian YS, Yu ZH, Zhou LX, et al. Successful treatment of a critically ill patient with acute respiratory distress syndrome from COVID-19 using mechanical ventilation strategy with low levels of positive end-expiratory pressure: A CARE-compliant case report. Medicine (Baltimore). 2020 Dec 4;99(49):e23160. doi: 10.1097/MD.0000000000023160.

19. Mao L, Luo L, Wang D, Yu Y, Dong S, Zhang P, et al. Early rehabilitation after lung transplantation with extracorporeal membrane oxygenation (ECMO) of COVID-19 patient: a case report. Ann Transl Med. 2021 Mar;9(6):512. doi: 10.21037/atm-21-456.

20. Chen JY, Qiao K, Liu F, Wu B, Xu X, Jiao GQ, et al. Lung transplantation as therapeutic option in acute respiratory distress syndrome for coronavirus disease 2019-related pulmonary fibrosis. Chin Med J (Engl). 2020 Jun 20;133(12):1390-1396. doi: 10.1097/CM9.0000000000000839.

21. Chen QY, He YS, Liu K, Cao J, Chen YX et al. Bronchoscopy for diagnosis of COVID-19 with respiratory failure: A case report. World J Clin Cases. 2021 Feb 16;9(5):1132-1138. doi: 10.12998/wjcc.v9.i5.1132.

22. Mehta R, Bansal S, Kumar A, Thorbole A, Chakravarthi L, Kalpakam H, et al. Bronchoscopy in COVID19 ARDS patients on mechanical ventilation – a prospective study. medRxiv [Preprint] 2021.02.02.21250362; doi: https://doi.org/10.1101/2021.02.02.21250362

23. Díez-Ferrer M, Martin-Cabeza C, Cubero N, Sabater-Riera J, Santos S, López-Lisbona RM et al. Role of bronchoscopy in critically ill patients with COVID-19

medRxiv preprint doi: https://doi.org/10.1101/2022.09.19.22280133; this version posted September 20, 2022. The copyright holder for this preprint (which was not certified by peer review) is the author/funder, who has granted medRxiv a license to display the preprint in perpetuity.

It is made available under a CC-BY-ND 4.0 International license .

pneumonia. Rev Clin Esp (Barc). 2021 Aug-Sep;221(7):430-431. doi: 10.1016/j.rceng.2020.12.006.

24. Lormans P, Blot S, Amerlinck S, Devriendt Y, Dumoulin A, et al. COVID-19 acquisition risk among ICU nursing staff with patient-driven use of aerosol-generating respiratory procedures and optimal use of personal protective equipment. Intensive Crit Care Nurs. 2021 Apr;63:102993. doi: 10.1016/j.iccn.2020.102993.

25. Bruyneel M, Gabrovska M, Rummens P, Roman A, Claus M, Stevens E, et al. Bronchoscopy in COVID-19 intensive care unit patients. Respirology. 2020 Dec;25(12):1313-1315. doi: 10.1111/resp.13932.

26. Piva S, DiBlasi RM, Slee AE, Jobe AH, Roccaro AM, Filippini M, et al. Surfactant therapy for COVID-19 related ARDS: a retrospective case-control pilot study. Respir Res. 2021 Jan 18;22(1):20. doi: 10.1186/s12931-020-01603-w.

27. Jonckheere W, Mekeirele M, Hendrickx S, Jonckheer J, Diltoer M, Ghijselings I, et al. Percutaneous tracheostomy for long-term ventilated COVID-19-patients: rationale and first clinical-safe for all-experience. Anaesthesiol Intensive Ther. 2020;52(5):366-372. doi: 10.5114/ait.2020.101216.

28. Torrego A, Pajares V, Fernández-Arias C, Vera P, Mancebo J, et al. Bronchoscopy in Patients with COVID-19 with Invasive Mechanical Ventilation: A Single-Center Experience. Am J Respir Crit Care Med. 2020 Jul 15;202(2):284-287. doi: 10.1164/rccm.202004-0945LE.

29. Rajajee V, Williamson CA, et al. Use of a Novel Negative-Pressure Tent During Bedside Tracheostomy in COVID-19 Patients. Neurocrit Care. 2020 Oct;33(2):597-603. doi: 10.1007/s12028-020-01068-1.

30. Mallick T, Barakat M, Baptiste TR, Hasan M, Engdahl R, et al. Successful Use of Veno-Venous Extracorporeal Membrane Oxygenation in a Patient with Severe COVID-19 Pneumonia. Cureus. 2020 Dec 6;12(12):e11938. doi: 10.7759/cureus.11938.

31. Gao CA, Bailey JI, Walter JM, Coleman JM, Malsin ES, Argento AC, et al. Bronchoscopy on Intubated Patients with COVID-19 Is Associated with Low Infectious Risk to Operators. Ann Am Thorac Soc. 2021 Jul;18(7):1243-1246. doi: 10.1513/AnnalsATS.202009-1225RL.

32. Mahmood K, Abbott M, Van Nostrand K, Bechara R, Gonzalez AV, Brucker A, et al. Low utilisation of bronchoscopy to assess COVID-19 respiratory infection: a multicenter experience. BMJ Open Resp Res 2021;8:e000962. doi:10.1136/bmjresp-2021-000962

33. Ippolito M, Misseri G, Catalisano G, Marino C, Ingoglia G, Alessi M, et al. Ventilator-Associated Pneumonia in Patients with COVID-19: A Systematic Review and Meta-Analysis. Antibiotics (Basel). 2021 May 7;10(5):545. doi: 10.3390/antibiotics10050545.

34. Chong WH, Neu KP, et al. Incidence, diagnosis and outcomes of COVID-19-associated pulmonary aspergillosis (CAPA): a systematic review. J Hosp Infect. 2021 Jul; 113:115-129. doi: 10.1016/j.jhin.2021.04.012.

35. Page MJ, McKenzie JE, Bossuyt PM, Boutron I, Hoffmann TC, Mulrow CD, et

medRxiv preprint doi: https://doi.org/10.1101/2022.09.19.22280133; this version posted September 20, 2022. The copyright holder for this preprint (which was not certified by peer review) is the author/funder, who has granted medRxiv a license to display the preprint in perpetuity.

It is made available under a CC-BY-ND 4.0 International license .

al. The PRISMA 2020 statement: an updated guideline for reporting systematic reviews. BMJ 2021;372:n71. doi: 10.1136/bmj.n71

36. Liu Y, Wang M, Luo G, Qian X, Wu C, Zhang Y, et al. Experience of N-acetylcysteine airway management in the successful treatment of one case of critical condition with COVID-19: A case report. Medicine (Baltimore). 2020 Oct 16;99(42):e22577. doi: 10.1097/MD.0000000000022577.

37. Liu M, Chen Z, Dai MY, Yang JH, Chen XB, Chen D, et al. Lessons learned from early compassionate use of convalescent plasma on critically ill patients with Covid-19. Transfusion. 2020 Oct;60(10):2210-2216. doi: 10.1111/trf.15975.

38. Patrucco F, Albera C, Bellocchia M, Foci V, Gavelli F, Castello LM, et al. SARS-CoV-2 Detection on Bronchoalveolar Lavage: An Italian Multicenter experience. Respiration. 2020;99(11):970-978. doi: 10.1159/000511964.

39. Paramythiotou E, Dimopoulos G, Koliakos N, Siopi M, Vourli S, Pournaras S, Meletiadis J, et al. Epidemiology and Incidence of COVID-19-Associated Pulmonary Aspergillosis (CAPA) in a Greek Tertiary Care Academic Reference Hospital. Infect Dis Ther. 2021 Sep;10(3):1779-1792. doi: 10.1007/s40121-021-00486-8.

40. Lima G, Cardoso E, Paredes MC, et al. Extracorporeal Membrane Oxygenation Support in a Young Patient with COVID-19 Infection. Cureus. 2020 Jun 19;12(6):e8694. doi: 10.7759/cureus.8694.

41. Wiles S, Mireles-Cabodevila E, Neuhofs S, Mukhopadhyay S, Reynolds JP, Hatipoğlu U, et al. Endotracheal Tube Obstruction Among Patients Mechanically Ventilated for ARDS Due to COVID-19: A Case Series. J Intensive Care Med. 2021 May;36(5):604-611. doi: 10.1177/0885066620981891.

42. Senyei G, Nettlow D, Nobari MM, Miller RJ, Cheng GZ, et al. A Multi-Modal Approach to Life-Threatening Hemoptysis in a Patient with COVID-19 ARDS. Am Res Crit Care Med 2021; 203:A1995 https://doi.org/10.1164/ajrccmconference.2021.203.1_MeetingAbstracts.A1995

43. Widysanto A, Sutanto YS, Soetjipto AS, Lugito NP, Siahaan SS, et al. Bronchoscopy Manifestation In Severe COVID-19 Patient: Case Series. [Preprint] Research Square; 2020. DOI: 10.21203/rs.3.rs-103263/v1.

44. Widysanto A, Wahyuni TD, Simanjuntak LH, Sunarso S, Siahaan SS, Haryanto H, et al. Happy hypoxia in critical COVID-19 patient: A case report in Tangerang, Indonesia. Physiol Rep. 2020 Oct;8(20):e14619. doi: 10.14814/phy2.14619.

45. Taban EM, Richards GA, et al. Observational study of therapeutic bronchoscopy in critical hypoxaemic ventilated patients with COVID-19 at Mediclinic Midstream Private Hospital in Pretoria, South Africa. Afr J Thorac Crit Care Med. 2020 Dec 1;26(4):10.7196/AJTCCM.2020.v26i4.119. doi: 10.7196/AJTCCM.2020.v26i4.119.

46. Aviles T, Rodriguez S, Pylypiv O, et al. CoVid-19, Mucus plug, and immediate postpartum: A Concerning triad. Journal of Scientific Innovation in Medicine. 2021; 4(2): 41, pp. 1–3. doi: https://doi.org/10.29024/jsim.139.

47. Behera D, Behera RR, Jagaty RR, Das R, Venkataram R, Subhankar S, Samal V, et al. An Atypical Case of Mild COVID-19 Infection with Severe Guillain-Barré

medRxiv preprint doi: https://doi.org/10.1101/2022.09.19.22280133; this version posted September 20, 2022. The copyright holder for this preprint (which was not certified by peer review) is the author/funder, who has granted medRxiv a license to display the preprint in perpetuity.

It is made available under a CC-BY-ND 4.0 International license .

Syndrome as Neurological Manifestation. J Health Allied Sci. 2021;03:113-211 Doi: 10.1055/s-0041-1731142

48. Fitzgerald AL, Vachharajani HH, Davidson BP, Kruit NJ, Eslick AT, et al. The Prolonged Use of VV ECMO Support in COVID-19: A Case Report. J Crit Care Med (Targu Mures). 2020 Nov 7;6(4):224-230. doi: 10.2478/jccm-2020-0034.

49. Donatelli P, Trenatacosti F, Pellegrino MR, Tonelli R, Bruzzi G, Andreani A, et al. Endobronchial valve positioning for alveolar-pleural fistula following ICU management complicating COVID-19 pneumonia. BMC Pulm Med. 2021 Sep 27;21(1):307. doi: 10.1186/s12890-021-01653-w.

50. Arenas-De Larriva M, Martín-DeLeon R, Urrutia Royo B, Fernández-Navamuel I, Gimenez Velando A, Nuñez García L, et al. The role of bronchoscopy in patients with SARS-CoV-2 pneumonia. ERJ Open Res. 2021 Jul 12;7(3):00165-2021. doi: 10.1183/23120541.00165-2021.

51. Bhatraju PK, Ghassemieh BJ, Nichols M, Kim R, Jerome KR, Nalla AK, et al. Covid-19 in Critically Ill Patients in the Seattle Region - Case Series. N Engl J Med. 2020 May 21;382(21):2012-2022. doi: 10.1056/NEJMoa2004500.

52. Goussard P, Van Wyk L, Burke J, Malherbe A, Retief F, Andronikou S, et al. Bronchoscopy in children with COVID-19: A case series. Pediatr Pulmonol. 2020 Oct;55(10):2816-2822. doi: 10.1002/ppul.25015.

53. Patigaroo SA, Qazi SM, Ahmad R, Latoo MA, Dar NH, Showkat SA, Ali A, et al. Pediatric Rigid Bronchoscopy for Tracheobronchial Foreign Bodies in Covid Times: Short Personal Experience. Indian J Otolaryngol Head Neck Surg. 2020 Sep 16:1-9. doi: 10.1007/s12070-020-02143-x.

54. Lock C, Nix CM, et al. Use of point-of-care lung ultrasonography in the critical care setting as an aid to identifying the correct diagnosis in an acutely desaturating patient with COVID-19- related acute respiratory distress syndrome. BMJ Case Rep. 2021 Mar 16;14(3):e240891. doi: 10.1136/bcr-2020-240891.

55. Kon ZN, Smith DE, Chang SH, Goldenberg RM, Angel LF, Carillo JA, et al. Extracorporeal Membrane Oxygenation Support in Severe COVID-19. Ann Thorac Surg. 2021 Feb;111(2):537-543. doi: 10.1016/j.athoracsur.2020.07.002.

56. Loor K, Alvarez A, Felipe Montiel A, Ferrer R, Roca O, García-de-Acilu M, et al. Safety, diagnostic, and therapeutic value of flexible bronchoscopy in critically ill COVID-19 patients. Can J Anaesth. 2021 Mar;68(3):434-435. doi: 10.1007/s12630-020-01887-y.

57. Murthy S, Gomersall CD, Fowler RA, et al. Care for Critically Ill Patients With COVID-19. JAMA. 2020;323(15):1499–1500. doi:10.1001/jama.2020.3633

58. An P, Wood BJ, Li W, Zhang M, Ye Y, et al. Postpartum exacerbation of antenatal COVID-19 pneumonia in 3 women. CMAJ. 2020;192(22): E603-E606. doi:10.1503/cmaj.200553

59. Gomez GPR, Venkatram S, Fuentes GD, et al. Utility and Safety of Fiberoptic Bronchoscopy in Patients Infected with COVID-19. A Case Series. J Pulm Med Respir Res. 2021 7: 055. DOI:10.24966/PMRR-0177/100055

medRxiv preprint doi: https://doi.org/10.1101/2022.09.19.22280133; this version posted September 20, 2022. The copyright holder for this preprint **(which was not certified by peer review)** is the author/funder, who has granted medRxiv a license to display the preprint in perpetuity.

It is made available under a CC-BY-ND 4.0 International license .

60. Minen F, Freire Gomez X, Procopiuc L, Nyman A, James P, Griffiths B, Lillie J, et al. A pediatric case series evaluating the benefits of combined bronchoscopy and CT in ECMO Perfusion ; 2021, 36(1 SUPPL):79-80, doi: 10.1177/02676591211007763.

61. Botti C, Lusetti F, Neri T, Peroni S, Castellucci A, Salsi P, Ghidini A, et al. Comparison of percutaneous dilatational tracheotomy versus open surgical technique in severe COVID-19: Complication rates, relative risks and benefits. Auris Nasus. Larynx. 2021 Jun;48(3):511-517. doi: 10.1016/j.anl.2020.10.014.

62. Khan E, Lal S, Hashmi J, Thomas J, Malik MA, et al. Per-cutaneous dilatation tracheostomy (PCTD) in COVID-19 patients and peri-tracheostomy care: A case series and guidelines. Pak J Med Sci. 2020 Nov-Dec;36(7):1714-1718. doi: 10.12669/pjms.36.7.3518.

63. Vargas M, Russo G, Iacovazzo C, Servillo G, et al. Modified percutaneous tracheostomy in COVID-19 critically ill patients. Head & Neck. 2020;42:1363–1366. https://doi.org/10.1002/hed.26276

64. Yeung E, Hopkins P, Auzinger G, Fan K, et al. Challenges of tracheostomy in COVID-19 patients in a tertiary centre in inner city London. Int J Oral Maxillofac Surg. 2020 Nov;49(11):1385-1391. doi: 10.1016/j.ijom.2020.08.007.

65. Ichinomiya T, Murata H, Sekino M, Yokoyama H, Ogami-Takamura K, Higashijima U, et al. Tracheobronchial Stent Insertion Under Venovenous Extracorporeal Membrane Oxygenation in a Patient with Coronavirus Disease 2019. J Cardiothorac Vasc Anesth. 2021 Sep 10:S1053-0770(21)00822-3. doi: 10.1053/j.jvca.2021.09.009.

66. May J, Ramos-Bascon N, Barnes N, Madden B, et al. Large airway complications in COVID-19 pneumonia. Monaldi Arch Chest Dis. 2021 Jul 22. doi: 10.4081/monaldi.2021.1894.

67. Meyer CD, Capra GG, Strange RG, Weimerskirch BP, Santiago GF, et al. Airway Management of COVID-19 Positive Patients Aboard USNS COMFORT Mission to New York City. J Craniofac Surg. 2020 Sep;31(6):e660-e661. doi: 10.1097/SCS.0000000000006891.

68. Sood RN, Dudiki N, Alape D, Maxfiel MW, et al. Healthcare Personnel Safety During Percutaneous Tracheostomy in Patients with COVID-19: Proof-of-Concept Study. J Intensive Care Med. 2021 May;36(5):612-616. doi: 10.1177/0885066620980384.

69. Angel L, Kon ZN, Chang SH, Rafeq S, Palasamudram Shekar S, Mitzman B, et al. Novel Percutaneous Tracheostomy for Critically Ill Patients with COVID-19. Ann Thorac Surg. 2020 Sep;110(3):1006-1011. doi: 10.1016/j.athoracsur.2020.04.010

70. Gadkaree SK, Schwartz D, Gerold K, Kim Y, et al. Use of Bronchoscopy in Percutaneous Dilational Tracheostomy. JAMA Otolaryngol Head Neck Surg. 2016;142(2):143–149. doi:10.1001/jamaoto.2015.3123.

71. Tetaj N, Maritti M, Stazi G, Marini MC, Centanni D, Garotto G, et al. Icu Covid-Study Group. Outcomes and Timing of Bedside Percutaneous Tracheostomy of COVID-19 Patients over a Year in the Intensive Care Unit. J Clin Med. 2021 Jul 28;10(15):3335. doi: 10.3390/jcm10153335.

medRxiv preprint doi: https://doi.org/10.1101/2022.09.19.22280133; this version posted September 20, 2022. The copyright holder for this preprint **(which was not certified by peer review)** is the author/funder, who has granted medRxiv a license to display the preprint in perpetuity.

It is made available under a CC-BY-ND 4.0 International license .

72. Long SM, Chern A, Feit NZ, Chung S, Ramaswamy AT, Li C, et al. Percutaneous and Open Tracheostomy in Patients with COVID-19: Comparison and Outcomes of an Institutional Series in New York City. Ann Surg. 2021 Mar 1;273(3):403-409. doi: 10.1097/SLA.0000000000004428.

73. Giacomo Fiacchini, Domenico Trico, Alessandro Ribechini, Francesco Forfori, Etrusca Brogi, Marco Lucchi, et al. Evaluation of the Incidence and Potential Mechanisms of Tracheal Complications in Patients With COVID-19. JAMA Otolaryngol Head Neck Surg. 2021;147(1):70-76. doi:10.1001/jamaoto.2020.4148

74. Sugimoto R, Kenzaka T, Fujikawa M, Kawasaki S, Nishisaki H, et al. Humidifier Use and Prone Positioning in a Patient with Severe COVID-19 Pneumonia and Endotracheal Tube Impaction Due to Highly Viscous Sputum. Cureus. 2020 Jun 15;12(6):e8626. doi: 10.7759/cureus.8626.

75. Cai SJ, Wu LL, Chen DF, Li YX, Liu YJ, Fan YQ, et al. Analysis of bronchoscope-guided tracheal intubation in 12 cases with coronavirus disease 2019 under the personal protective equipment with positive pressure protective hood. Zhonghua Jie He He Hu Xi Za Zhi. 2020 Apr 12;43(4):332-334. doi: 10.3760/cma.j.cn112147-20200222-00153.

76. Pb S, Madan K, Mohan A, Hadda V, Tiwari P, Guleria R, Mittal S, et al. Acute hypoxemia due to lung collapse in COVID-19: the role of therapeutic bronchoscopy. Adv Respir Med. 2021;89(4):448-450. Doi: 10.5603/ARM.a2021.0009

77. Leiten EO, Martinsen EM, Bakke PS, Eagan TM, Grønseth R, et al. Complications and discomfort of bronchoscopy: a systematic review. Eur Clin Respir J. 2016;3:33324. 2016. doi:10.3402/ecrj.v3.33324

78. Paderno A, Fior M, Berretti G, Del Bon F, Schreiber A, Grammatica A, et al. COVID-19 and Total Laryngectomy-A Report of Two Cases. Ann Otol Rhinol Laryngol. 2021 Jan;130(1):104-107. doi: 10.1177/0003489420935500.

79. Dewiyana A. Kusmana, Edwin Adhi Darmawan Batubara, Raka Aldy Nugraha, Theresia Rasta Karina Natasha Setyasty Primaditta, et al. Bronchoscopic Intervention May be Associated with Better Outcomes in Mechanically Ventilated Coronavirus Disease-19 Patients: A Case Series. Open Access Macedonian Journal of Medical Sciences. 2020 Oct 14; 8(T1):276-281. Doi: org/10.3889/oamjms.2020.5390

80. Morvan JB, Rivière D, Danguy des Déserts M, Bonfort G, Mathais Q, Pasquier P, et al. Percutaneous dilatational tracheostomy for saturating influx of COVID-19 patients: Experience of military ENT physicians deployed in Mulhouse, France. Eur Ann Otorhinolaryngol Head Neck Dis. 2020 Sep;137(4):263-268. doi:

10.1016/j.anorl.2020.06.016.

81. Daniel I. Loube, Kashif Z. Hassan, Sang H. Lee, Bruce L. Davidson. Bedside tracheostomy for a COVID-19 cohort. Respiratory Medicine Case Reports 32 (2021) 101346 doi:10.1016/j.rmcr.2021.101346

82. Kim EJ, Yoo EH, Jung CY, Kim KC, et al. Experience of percutaneous tracheostomy in critically ill COVID-19 patients. Acute Crit Care. 2020 Nov;35(4):263-270. doi: 10.4266/acc.2020.00444.

medRxiv preprint doi: https://doi.org/10.1101/2022.09.19.22280133; this version posted September 20, 2022. The copyright holder for this preprint **(which was not certified by peer review)** is the author/funder, who has granted medRxiv a license to display the preprint in perpetuity.

It is made available under a CC-BY-ND 4.0 International license .

83. Murphy P, Holler E, Lindroth H, Laughlin M, Simons CJ, Streib EW, et al. Short-term Outcomes for Patients and Providers After Elective Tracheostomy in COVID-19-Positive Patients. J Surg Res. 2021 Apr;260:38-45. doi: 10.1016/j.jss.2020.10.013.

84. Oberg CL, Keyes C, Panchabhai TS, Sajawal Ali M, Oh SS, Grogan TR, et al. Combined Percutaneous Tracheostomy and Endoscopic Gastrostomy Tubes in COVID-19: A Prospective Series of Patient Outcomes. J Intensive Care Med. 2021 Nov;36(11):1340-1346. doi: 10.1177/08850666211038875.

85. Szewczyk J, Adkinson BC, Akkineni S, Nguyen DM, Arias SA, Villamizar NR, et al. Endobronchial valves: a bridge to definitive surgical management in COVID-19 recurrent pneumothorax. J Thorac Dis. 2021 Jan;13(1):411-413. doi: 10.21037/jtd-20-3248.

86. Boujaoude Z, Madisi N, Patel B, Rachoin JS, Dellinger RP, Abouzgheib W, et al. Safety and Feasibility of a Novel Protocol for Percutaneous Dilatational Tracheostomy in Patients with Respiratory Failure due to COVID-19 Infection: A Single Center Experience. Pulm Med. 2021 Jan 13;2021:8815925. doi: 10.1155/2021/8815925.

87. Sun BJ, Wolff CJ, Bechtold HM, Free D, Lorenzo J, Minot PR, et al. Modified percutaneous tracheostomy in patients with COVID-19. Trauma Surg Acute Care Open. 2020 Dec 14;5(1):e000625. doi: 10.1136/tsaco-2020-000625.

88. Valchanov K, Salaunkey K, Parmar J, et al. Percutaneous Dilatational Tracheostomy in Coronavirus Disease 2019 Extracorporeal Membrane Oxygenation Patients: A Case Series. J Cardiothorac Vasc Anesth. 2021;35(1):348-350. doi:10.1053/j.jvca.2020.06.024

89. Muljono CG, Marhana IA, Syafaah I, Setiawan HW, Semedi BP, Abbas KA, et al. Increase of lung function usage bronchoscopy in COVID-19 patients: Three case series in Indonesian adult. Int J Surg Case Rep. 2021 Nov 23;89:106623. doi: 10.1016/j.ijscr.2021.106623.

90. Chen, WQ, Ling, WH, Lu CY. et al. Which preventive measures might protect health care workers from SARS?. BMC Public Health **9,** 81 (2009). https://doi.org/10.1186/1471-2458-9-81

91. Kay JK, Parsel SM, Marsh JJ, McWhorter AJ, Friedlander PL. Risk of SARS-CoV-2 Transmission During Flexible Laryngoscopy: A Systematic Review. *JAMA Otolaryngol Head Neck Surg*. 2020;146(9):851-856. doi:10.1001/jamaoto.2020.1973

92. Lu W, Liu X, Wang T, Liu F, Zhu A, Lin Y, et al. Elevated MUC1 and MUC5AC mucin protein levels in airway mucus of critical ill COVID-19 patients. J Med Virol. 2021 Feb;93(2):582-584. doi: 10.1002/jmv.26406.

medRxiv preprint doi: https://doi.org/10.1101/2022.09.19.22280133; this version posted September 20, 2022. The copyright holder for this preprint **(which was not certified by peer review)** is the author/funder, who has granted medRxiv a license to display the preprint in perpetuity.

It is made available under a CC-BY-ND 4.0 International license .

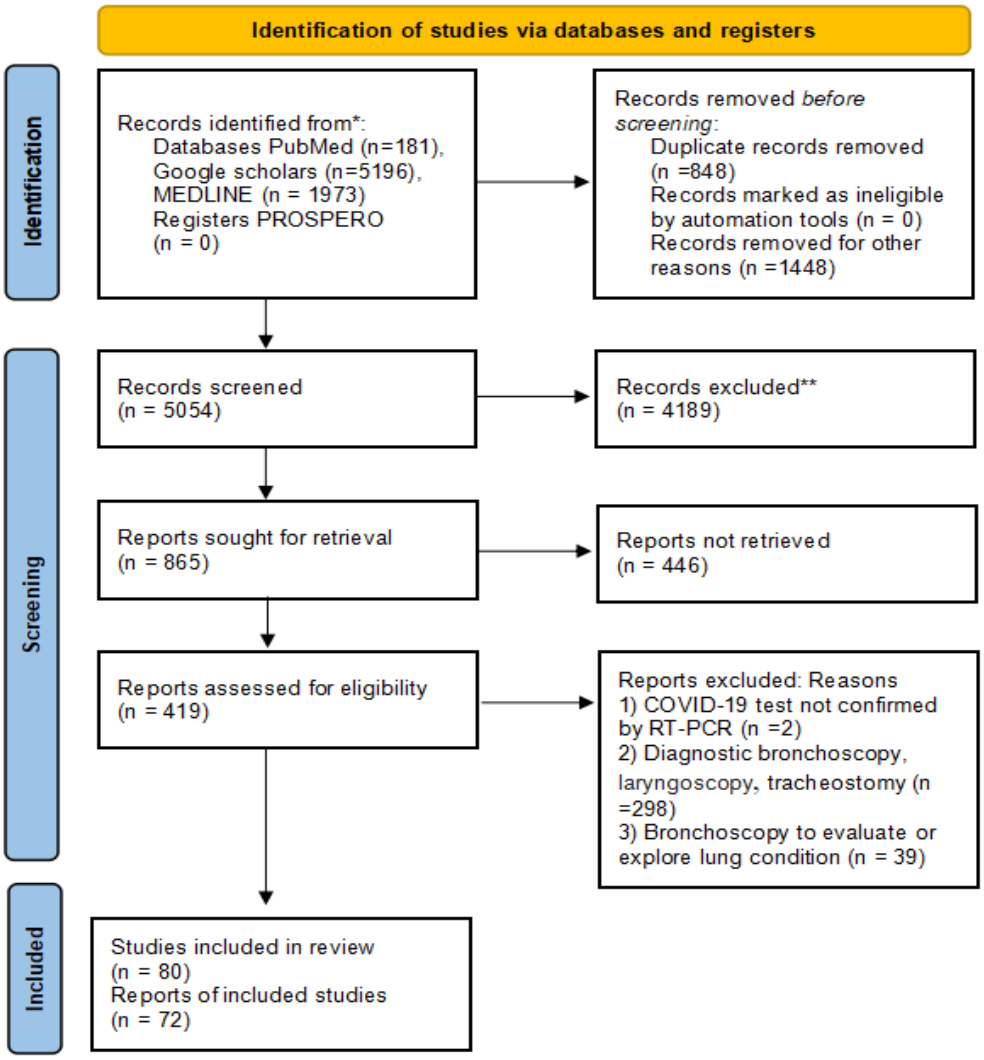

Figure 1: flow-chart for systematic review of literature.

medRxiv preprint doi: https://doi.org/10.1101/2022.09.19.22280133; this version posted September 20, 2022. The copyright holder for this preprint (which was not certified by peer review) is the author/funder, who has granted medRxiv a license to display the preprint in perpetuity.

It is made available under a CC-BY-ND 4.0 International license .

Overall Study findings	Number of studies	Rate (%) or overall trend
Total number of COVID-19 patients Total number of patients undergoing bronchoscopy	72	2558 1887
Total number of male Female	64/72	72 (1563 Males) 28 (598 Females)
Efficacy Failure in Successful procedure	58/72	98.3 1.7
Safety	26/72	97.5
Total Mortality in COVID-19 patients Mortality caused by bronchoscope	72 29/72	22 0
Total complications in COVID-19 patients Complications caused by bronchoscope	33/72 35/72	10.5 2.5
Rate of transmission to HCWs performed bronchoscopy Transmission caused by bronchoscopy	33/72 33/72	3.5 0
Number of studies/country	72/72	USA 24, Italy 10, China 9, Spain 4, France 1, UK 3, Ireland 1, Greece 1, Portugal 1, Belgium 3, Japan 2, South Korea 1, India 4, Indonesia 4, Pakistan 2, South Africa 1, Australia 1.
Types of bronchoscopes Standard/flexible/fibreoptic/bedside/video-bronchoscope/portable bronchoscope Disposable bronchoscope Rigid bronchoscope	 52/72 18/72 4/72	 Middle and High income nations Upper middle and high income countries Low and High income nations.

Table 1: Overall major findings of this review are shown in above table with various study parameters such as number of patients gender, success rate, safety, mortality, complications, transmission rate, studies per country, and types of bronchoscopes as per number of studies and rate or trend.

medRxiv preprint doi: https://doi.org/10.1101/2022.09.19.22280133; this version posted September 20, 2022. The copyright holder for this preprint (which was not certified by peer review) is the author/funder, who has granted medRxiv a license to display the preprint in perpetuity.

It is made available under a CC-BY-ND 4.0 International license .

Ref	No. of patients	Therapeutic Bronchoscopy (TB)	Overall Complications and relation to bronchoscopy	Death	Success Rate	Safe	HCW infected
46	1	Mucus plug removed	-	0	1/1		-
47	1	Mucous plug removed	-	0	1/1		-
51	2	Mucous plug removed	No improvement in 2 patients	-	0/2		-
17	107	Secretions, clots, or mucus plugs removed	3 patients ETT dislodgement during the procedure	29	-	Yes	NI 9 HCW
21	1	Sputum aspiration	No improvement in 1 patients	0	0/1		-
20	2	Bronchoscopic clearance of airway	-	0	-	Yes	-
23	51	Thick mucus plugs removal	-	-	-	Yes	-
48	1	Removal of thrombus, fibrous tissue strands	-	0	1/1		-
18	1	White mucoid sputum bolts suctioned	-	0	1/1		-
52	2	Thick pus removal and FBA	-	0	2/2	Yes	4 HCW NI
59	8	Therapeutic bronchoscopy	-	3	-	Yes	9 HCW NI
79	3	Bronchoscopic controlled suctioning	-	1	3/3		-
16	51	Bronchial sputum and hemoptysis clearance	-	-	-	Yes	2 out of 11 infected
40	1	Secretions removal	-	0	-	Yes	-
36	1	Airway secretion was cleared	-	0	1/1		-
37	3	Bronchoscopic sputum suctioned	MOF in 3 NR to bronchoscope	0	3/3		-
54	1	Mucus plug was suctioned	-	-	1/1		-
24	59	Therapeutic bronchoscopy provided	-	-	-	Yes	11 out of 115 infected
92	16	Respiratory tract mucus aspiration	-	0	16/16		-
19	1	Daily TB for airway clearance in LT	0	0	1/1		-
60	1	Mucus plug removal	0	-	-	Yes	-
89	3	Removal of thick mucus	0	0	3/3		NI
78	1	Bronchoscopic aspiration of secretions	TB not beneficial in 1 patient	1	0/1		-
53	1	FBA	0	0	1/1		4 HCW NI
38	2	Mucus plug-related atelectasis	-	-	2/2		-
39	1	Therapeutic bronchoscopy for atelectasis	0	0	1/1		-
26	7	Surfactant delivered via bronchoscope	-	1	7/7		NI
42	1	Occlusive gelatinous Clot removal	0	0	1/1		-
76	1	Mucus Plug removal	Intubation due to hypoxia	0	1/1		1 out of 3 infected
74	1	Bronchoscopic suction or drainage	Decreased the patient's SpO2	0	1/1		-
45	7	Gelatinous mucus and plugs	Desaturation in 3 patients	2 on MV	7/7		-
28	88	White and gelatinous secretions and mucohematic plugs removed	Minor transient drop of SpO2 <90% (unknown number)*	-	88/88		1 out of 3 infected
43	3	Thick and copious mucus plug removed	0	0	3/3		-
44	1	Thick mucus plug removed	0	0	1/1		-
41	11	Limestone-like secretions cleared	-	4	11/11		-
55	27	Toilet bronchoscopy	13 had complications NR to TB	1	27/27		20 HCW NI
36 articl es	469		Total 28, 12 relevant events,	42/171 deaths in 8 studies	In 186/ 189 patients 28 study	282	15 infected in 177 HCW

Supplementary table 1: Clinical Studies with Therapeutic Bronchoscopy: Total number of patients undergoing bronchoscopy. In mortality column 0 represents no deaths observed, NI: Not Infected, HCW: Healthcare worker, NR: Not related, (-) Not reported, ETT: Endotracheal tube, SpO2: Oxygen saturation, MOF: Multi-organ failure, MV: Mechanical ventilation, FBA: Foreign body aspiration, ICU: Intensive care unit, LT: Lung transplant.

medRxiv preprint doi: https://doi.org/10.1101/2022.09.19.22280133; this version posted September 20, 2022. The copyright holder for this preprint (which was not certified by peer review) is the author/funder, who has granted medRxiv a license to display the preprint in perpetuity.

It is made available under a CC-BY-ND 4.0 International license .

Ref	No. of patients	Interventional Bronchoscopy use	Overall Complication and relation to bronchoscopy	Death	Success rate	IB Safe	HCW infected
61	17	Bronchoscopy guided PDT	9 complications due to PDT	3	17/17	-	3 HCW NI
86	25	Bronchoscopy guided PDT	PDT related minor bleeding in 1 patient, desaturation in 2 patients related to IB	9	25/25	Yes	4 HCW NI
75	12	Bronchoscopy guided tracheal intubation	-	-	12/12	Yes	9 HCW NI
3	29	Bronchoscopy guided PDT	1 bleeding 1 cellulitis NR to IB	6 due to PDT	29/29	Yes	4 HCW NI
49	2	Bronchoscopy guided air leak using a balloon occlusion test and valve placement	Valves migrated in 1 patient NR to IB	0	2/2	Yes	-
73	30	Bronchoscopy guided PDT	Late tracheal complication in 28 due to COVID-19 NR to PDT or IB	8	30/30	-	-
27	16	Bronchoscopic assistance in PDT	1 patients had infection, and 2 bleeding due to PDT	4	16/16	Yes	All 4 HCW NI
62	3	Bronchoscopic assistance in PDT	0	0	3/3	Yes	All 4 HCW NI
82	7	Bronchoscopic assistance in PDT	Bleeding in 2 NR to bronchoscope	5	-	Yes	All 5 NI
72	2	Bronchoscopic treatment for bleeding	-	0	2/2	-	2 HCW NI
81	12	Bronchoscopy guided PDT	Brief bleeding due to PDT in 1 patient	2 due to ARDS	-	Yes	24 HCW NI
67	5	PDT under bronchoscopic assistance in 1 and 4 other additional IB	-	0	5/5	-	6 HCW NI
83	11	Bronchoscopy guided PDT	2 bleeding and 1 pneumothorax NR	3	11/11	Yes	All 4 NI
84	58	Bronchoscopy guided PDT	Minor bleeding 12, Site irritation in 6 patients, repeat procedure in 5 NR	0	58/58	-	All 3 NI
68	11	Bronchoscopy guided PDT	Delayed bleeding in 1 patient NR	0	11/11	Yes	All 4 NI
87	9	Confirm ETT placement for tracheostomy with bronchoscope	2 late bleeding NR to IB	4	9/9	-	All 3 NI
85	1	Air leakage detection and lung volume reduction with EBV	Valves migrated NR to IB	0	1/1	-	-
71	120	Fibro-bronchoscopy guided PDT	Minor bleeding 23 patients, subcutaneous emphysema in 3, dysphagia in 11 patients. All were PDT related.	42 deaths COVID-19 related	-	Yes	NI 24 HCW
88	38	Bronchoscopic assistance in PDT	Skin bleeding in 2 NR to bronchoscopy	Intracranial hemorrhage 2, MOF 4	38/38	-	2 HCW NI
63	3	Bronchoscopy guided PT	-	0	3/3	-	All 3 HCW NI
11	58	Bronchoscopy guided intubation	SpO2 <90% in 9 patients related to IB	-	49/58	-	NI 6 HCW
64	28	Bronchoscopy guided tracheostomy	2 patients bleeding NR to IB	2	28/28	-	NI
22 articles	497	PDT in 409 patients + Other IBs 88 patients	129 patients in 17 studies, 11 events from IB observed	94/427 in 13 studies	349/358 in 19 studies	248	0/111 infected

Supplementary Table 2: Clinical Studies with Interventional Bronchoscopy: Total number of patients undergoing bronchoscopy. In mortality column 0 represents no deaths observed, PT: Percutaneous tracheostomy, EBV: Endobronchial valves, (-) Not reported, NI: Not infected, Acute respiratory distress syndrome, ARDS; MOF: Multi-organ failure. (*) complications in unknown number of patients [28].

medRxiv preprint doi: https://doi.org/10.1101/2022.09.19.22280133; this version posted September 20, 2022. The copyright holder for this preprint (which was not certified by peer review) is the author/funder, who has granted medRxiv a license to display the preprint in perpetuity.

It is made available under a CC-BY-ND 4.0 International license .

Ref	No. of Patients	Therapeutic Bronchoscopy (TB)	Interventional Bronchoscopy (IB)	Overall Complication and relation to bronchoscopy	Deaths of Patients	Success Rate	Safe	HCW infected
69	96	Secretions were suctioned using bronchoscope (#)	Bronchoscopy guided PDT (#)	PDT related bleeding in 5	7 died of respiratory and MOF	96/98	-	3 HCW NI
25	26	Removed bronchial plugs in 21 (67%) patients	ETT repositioning 4, extubation in 1	1 required intubation and 1 bronchoscope technical problem	9	25/26	-	4 HCW NI
12	69	Obstruction by secretions or blood clots and lung resistance in 30 patients	OTT repositioning, tracheostomy, and assistance in intubation for 39 patients	-	-	69/69	Yes	115 HCW NI
65	1	Bronchial obstruction removed (#)	Y-stent placement (#)	0	0	1/1	Yes	NI
50	399	Aspiration of secretions 378 patients (95.2%), and intrabronchial drug delivery	Cannula placement, occlusion, cryotherapy, and intubation in total 21 patients	-	399	-	Yes	-
56	69	Extraction of secretions in 50, atelectasis in 2 and respiratory distress in 4 patients.	Hemoptysis treatment in 10, stent placement in 3 patients.	7 Drop in Spo2, and 5 Mild hemoptysis related to bronchoscopy	23	-	Yes	NI
30	1	Bronchoscopic pulmonary toilet (#)	Bronchoscopy guided PDT (#)	-	0	1/1	-	-
66	4	Mucus plug suctioned in 1 patient	Decannulation in 1 patient ETT in 1 and PDT in 1 patient	-	1	3/4	-	-
22	52	Mucus Plug removal in 30 patients	ETT repositioning 15, and 7 patients for PDT	0	0	-	Yes	NI
14*	31	Management of obstructive atelectasis	Hemoptysis control, intubation, and tracheostomy related complications treated	Fever in 2 related to IB or TB	0	31/31	Yes	2 HCW NI
80	16	Aspiration of blood and tracheobronchial secretions (#)	Bronchoscopy guided PDT (#)	2 minor, 1 major hemoptysis and 1 minor infection (total 4 related to PDT)	0	16/16	-	All 4 NI
13	117	62 airway clearance, 1 foreign body aspiration, large airway stenosis in 8	35 ETT placement, 7 tracheostomy placement and 4 pre-decannulation	6 patients with TB, 1 patient with IB	1 IB patient died	101/107$	-	-
29	3	Toilet bronchoscopy (#)	To confirm PDT tracheal tube position (#)	0	1	3/3	-	All 3 HCW NI
15	37	Pre PDT suctioning of mucous plugs (#)	Bronchoscopic assisted PDT (#)	Bleeding 4, Cellulitis 3, Dislodgement of ETT in 2 patients related to PDT	2	37/37	-	All 4 NI
Total 14 studies	Total 921	Total = 772 patients, 587 only TB, TB+IB in all 154 patients (#), (*) 31 patients	Total 334 = 149 only IB, TB+IB in all 154 patients (#) (*) 31 patients	Total 43 patients, 23 events relevant to IB	443/720 in 8 studies	389/393	621	0/135

Table 3: Clinical Studies with both Therapeutic and Interventional use of Bronchoscopy, Total number of patients undergoing bronchoscopy. In mortality column 0 represents no deaths observed, PDT: Percutaneous dilational tracheostomy, (-) Not reported, NI; represents Not Infected, (*) represents the number of patients receiving IB is unknown [14]. Post bronchoscopy clinical decline within 12 hrs ($). The studies in which both the procedures performed in patients are mentioned as (#) represents number of patients undergoing both TB and IB.

medRxiv preprint doi: https://doi.org/10.1101/2022.09.19.22280133; this version posted September 20, 2022. The copyright holder for this preprint **(which was not certified by peer review)** is the author/funder, who has granted medRxiv a license to display the preprint in perpetuity.

It is made available under a CC-BY-ND 4.0 International license .

Ref	Study type	Country of Origin	Total no. of patients in each studies	Male	Female	TB	IB	Bronchoscope type used in the study	Author's comment on Clinical Impact
69	Single-center cohort study	USA	98	80	18	Yes	Yes	Flexible bronchoscope	Therapy effective Deaths due to respiratory and MOF
46	Case report	USA	1	0	1	Yes	-	Standard bronchoscope	Post-bronchoscopy re-expansion of lung
47	Case report	India	1	0	1	Yes	-	Standard bronchoscope	Lung expansion
51	Multi-center case series	USA	24	15	9	Yes	-	Standard bronchoscope	Did not change clinical course
61	Retrospective Study	Italy	47	34	13	-	Yes	Standard bronchoscope	No difference in PDT and OT
86	Retrospective study	USA	32	16	16	-	Yes	Disposable bronchoscope	Safe and effective
25	Retrospective study	Belgium	32	-	-	Yes	Yes	Disposable bronchoscope	Useful in severe patients
75	Retrospective study	China	12	9	3	-	Yes	Portable bronchoscope	Successful intubation
17	Retrospective study	USA	107	87	20	Yes		Disposable bronchoscope	Safe for use
3	Prospective study	USA	53	33	20	-	Yes	Standard bronchoscope	Safe for patients and HCW
21	Case report	China	1	1	0	Yes	-	Standard bronchoscope	Did not improve
20	Case series	China	3	3	0	Yes	-	Standard bronchoscope	Patient survived
49	Case series	Italy	2	2	0	-	Yes	Standard bronchoscope	Patient survived
23	Retrospective study	Spain	51	-	-	Yes	-	Disposable bronchoscope	Effective airway management
48	Case Report	Australia	1	0	1	Yes	-	Standard bronchoscope	Airway bleeding managed
73	Retrospective cohort study	Italy	30	22	8	-	Yes	Standard bronchoscope	All patients recovered
12	Prospective study	Italy	87	-	-	Yes	Yes	Disposable bronchoscope	Useful and effective tool
18	Case report	China	1	1	0	Yes	-	Standard bronchoscope	Optimal PEEP improved bronchoscopy
52	Case series	South Africa	4	3	1	Yes	-	Standard bronchoscope	Emergency bronchoscopy was safe
65	Case Report	Japan	1	1	0	Yes	Yes	Fiberoptic and rigid bronchoscope	Safe for patients and HCW
27	Retrospective study	Belgium	16	11	5	-	Yes	Disposable bronchoscope	Bronchoscopy can be performed safely
62	Case series	Pakistan	3	2	1	-	Yes	Standard bronchoscope	PDT safe under bronchoscopy
82	Retrospective study	South Korea	7	6	1	-	Yes	Disposable bronchoscope	Bronchoscopic PDT is safe
79	Case series	Indonesia	3	2	1	Yes	-	Standard bronchoscope	Helpful in weaning
50	Multicentre cohort study	Spain	485	357	128	Yes	Yes	60% Disposable and 40% standard bronchoscopes	Bloody secretions led to death of 496 patients
16	Interventional study	Italy	57	-	-	Yes	-	Flexible bronchoscope	Safe to use bronchoscopy
40	Case Report	USA	1	0	1	Yes	-	Standard bronchoscope	Patient discharged
36	Case Report	China	1	1	0	Yes	-	Standard bronchoscope	Patient cured
37	Case Report	China	3	3	0	Yes	-	Standard bronchoscope	Therapy useful
54	Case Study	Ireland	1	1	0	Yes	-	Standard bronchoscope	Improved oxygen saturation
72	Prospective study	USA	67	48	19	-	Yes	Standard bronchoscope	Bronchoscope used to treat complications
56	Single center retrospective study	Spain	75	54	21	Yes	Yes	Disposable bronchoscope	Bronchoscope is safe invasive technique
24	Prospective study	Belgium	59	-	-	Yes	-	Standard bronchoscope	High-risk bronchoscopic maneuvers are safe
81	case-series	USA	12	7	5	-	Yes	Disposable bronchoscope	Promoted weaning and safe for HCW
92	Observational Study	China	16	12	4	Yes	-	Bedside bronchoscopy	Increased in lung O2 and Co2 exchange
30	Case study	Pakistan	1	1	0	Yes	Yes	Standard bronchoscope	Complete recovery

medRxiv preprint doi: https://doi.org/10.1101/2022.09.19.22280133; this version posted September 20, 2022. The copyright holder for this preprint **(which was not certified by peer review)** is the author/funder, who has granted medRxiv a license to display the preprint in perpetuity.

It is made available under a CC-BY-ND 4.0 International license .

19	Case study	China	1	0	1	Yes	-	Standard bronchoscope	Therapeutic bronchoscopy is needed post-LT
66	Case series	UK	5	5	0	Yes	Yes	Fibreoptic and Rigid bronchoscope	large airway intervention beneficial
22	Prospective study	India	61	51	10	Yes	Yes	Bedside bronchoscopy	Improved lungs condition after therapeutic suctioning
67	Retrospective study	USA	7	-	-	-	Yes	Standard bronchoscope	Decreased peri & postoperative bleeding
60	Case series	Portugal	11	-	-	Yes	-	Standard bronchoscope	FBB gave a clear therapeutic benefit post CT scan
14	Retrospective multi-center study	Italy	109	77	32	Yes	Yes	Rigid and flexible Bronchoscopes	Bronchoscopy is a useful technique
80	Retrospective study	France	18	14	4	Yes	Yes	Disposable bronchoscope	Percutaneous tracheostomy is feasible for physicians
89	Prospective case series	Indonesia	3	1	2	Yes	-	Disposable bronchoscope	The procedure improved the lung function
83	Observational study	USA	18	13	5	-	Yes	Disposable bronchoscope	Bronchoscopic PDT safe
13	Online survey of Global pandemic SARS-CoV-2 bronchoscopy database (GPS-BD)	USA	289	207	82	Yes	Yes	-	Bronchoscopy has reasonable clinical benefit
84	Prospective single-arm cohort study	USA	58	39	19	-	Yes	Standard bronchoscope	Critically ill patients survived after PDT
78	Case series	Italy	2	2	0	Yes	-	Standard bronchoscope	Laryngectomies with COVID-19 are complex
53	Case series	India	1	1	0	Yes	-	Rigid bronchoscopy	Patient discharged
38	Multicenter retrospective study	Italy	43	31	12	Yes	-	Standard bronchoscope	Bronchoscopic BAL isolation effective method
39	Case Series	Greece	1	1	0	Yes	-	Standard bronchoscope	Transferred from ICU
26	Retrospective study	Italy	21	17	4	Yes	-	Standard bronchoscope	Surfactant delivery through bronchoscopy is effective therapy
29	Retrospective case series	USA	3	2	1	Yes	Yes	Standard bronchoscope	Feasible to perform PDT on intubated patient with optimal PEEP and FiO2
42	Case report	USA	1	1	0	Yes	-	Standard bronchoscope	Successfully managed using serial therapeutic bronchoscopy
15	Retrospective cohort study	USA	37	22	15	Yes	Yes	Disposable bronchoscope	Benefit to patients with PDT placement
68	Proof of concept study	USA	11	7	4	-	Yes	Disposable bronchoscope	Efficacious and adaptable protocol for bronchoscopy guided PDT
76	Case report	India	1	1	0	Yes	-	Standard bronchoscope	Complete resolution of lung failure
87	Retrospective study	USA	12	9	3	-	Yes	Fibreoptic bronchoscope	Modified PDT are safe in patients
74	Case report	Japan	1	1	0	Yes	-	Standard bronchoscope	Successful treatment patient discharged
85	Case study	USA	1	1	0	-	Yes	Flexible bronchoscope	Patient has sufficiently recovered
45	Observational study	South Africa	14	9	5	Yes	-	Flexible fibreoptic bronchoscopy	Oxygenation improved
71	Retrospective observational study	Italy	120	80	40	-	Yes	Video-assisted fibro-bronchoscopy	Procedure was safe for all HCW
28	Observational study	Spain	93	-	-	Yes	-	Disposable bronchoscopy	Patients can be benefit from bronchoscopy
59	Case series	USA	8	6	2	Yes	-	Disposable bronchoscope	Potentially safe for patient care
88	Prospective study	UK	38	31	7	-	Yes	Disposable bronchoscope	All procedures were successful
63	Retrospective study	USA	3	2	1	-	Yes	Standard bronchoscope	Modified percutaneous tracheostomy is feasible
43	Case series	Indonesia	3	3	0	Yes	-	Standard bronchoscope	Significant clinical improvement seen
44	Case report	Indonesia	1	1	0	Yes	-	Standard bronchoscope	The patient survived

medRxiv preprint doi: https://doi.org/10.1101/2022.09.19.22280133; this version posted September 20, 2022. The copyright holder for this preprint **(which was not certified by peer review)** is the author/funder, who has granted medRxiv a license to display the preprint in perpetuity.

It is made available under a CC-BY-ND 4.0 International license .

41	Case series	USA	11	9	2	Yes	-	Standard bronchoscope	Patient rescued from ETT block
11	A prospective randomized controlled trial	China	58	33	25	-	Yes	Portable bronchoscope	HFNO provided a shorter intubation for critically ill.
64	Single center prospective study	UK	72	51	21	-	Yes	Standard bronchoscope	OT and PDT both are equally favorable.
69	Retrospective study	USA	27	23	4	Yes	-	Standard bronchoscope	Judge well before using ECMO.
		Majority of studies from USA 23, Italy 10, China 9.	2558	1563 male	598 female			DB 17 studies, RB 1 studies, SB 49 studies, 1 not reported, 3 studies RB+SB, and 1 study used SB+DB	Safety 17 studies, 5 studies no comments on bronchoscopy, 50 studies on efficacy

Supplementary Table 4: Clinical Studies with both Therapeutic and Interventional use of Bronchoscopy mentioned as "Yes". "F" represents female and "M" represents male. (-) Not reported, In 7 articles gender not mentioned. DB: Disposable bronchoscope, SB: Standard bronchoscope, RB: Rigid bronchoscope. The