

1 **Beneficial influence of single-stage posterior surgery for the treatment of lumbar brucella**
2 **spondylitis combined with spondylolisthesis**

3 **Authors and affiliations**

4 Yao Zhang, Chang-song Zhao, Jia-min Chen, Qiang Zhang*

5 Yao Zhang: Department of Orthopedics, Beijing Ditan Hospital, Capital Medical University,
6 Beijing 100015, China

7 Chang-song Zhao: Department of Orthopedics, Beijing Ditan Hospital, Capital Medical University,
8 Beijing 100015, China

9 Jia-min Chen: Department of Pathology, Beijing Ditan Hospital, Capital Medical University,
10 Beijing 100015, China

11 Zhang Qiang: Department of Orthopedics, Beijing Ditan Hospital, Capital Medical University,
12 Beijing 100015, China

13 *Corresponding author

14 Prof. Qiang Zhang, M.D, Ph.D, the guarantor of the paper

15 Tel.: +86-10-13718271838

16 Fax: +86-10-84322588

17 E-mail: 765926411@qq.com

18 Department of Orthopedics

19 Beijing Ditan Hospital, Capital Medical University

20 No.8, Jingshun East Street, Chaoyang District

21 Beijing 100015, China

22 **Abstract**

NOTE: This preprint reports new research that has not been certified by peer review and should not be used to guide clinical practice.

23 We aimed to evaluate the clinical efficacy of the single-stage posterior surgical treatment for
24 patients of lumbar brucella spondylitis combined with spondylolisthesis. In this study, we
25 performed a retrospective analysis of 16 patients with lumbar brucellosis spondylitis combined
26 with spondylolisthesis from January 2015 to January 2019. All patients underwent single-stage
27 posterior lumbar debridement, reduction, interbody fusion, and instrumentation. Preoperative and
28 postoperative of the visual analog scale (VAS), the Japanese orthopedic association scores (JOA),
29 the Oswestry disability index (ODI), erythrocyte sedimentation rate (ESR), and C-reactive protein
30 (CRP) were compared. In addition, the spondylolisthesis reduction rate, reduction loss rate,
31 interbody fusion rate, and complication rate were recorded. VAS, JOA, ODI, ESR, and CRP were
32 conducted with repeated analysis of variance data at different follow-ups. The postoperative
33 follow-up was 12 to 36 months, with an average of (25.0±8.1) months. VAS, JOA, ODI, ESR, and
34 CRP were significantly better at two-week and one-year follow-up than preoperative results
35 ($P=0.000$, respectively). In addition, one year after the operation, VAS, JOA, ODI, ESR, and CRP
36 showed a significant improvement ($P=0.000$, respectively). The average spondylolisthesis
37 reduction in two weeks after operation was (91.2±6.7) %, and the median reduction loss rate in
38 one year after operation was 8.0 (5.0,9.8) %. At the last follow-up, all patients achieved interbody
39 fusion, no loosening and fracture of instrumentation were found, and no recurrence happened.

40 Single-stage posterior operation for lumbar debridement, reduction, interbody fusion, and
41 instrumentation is beneficial for treating lumbar brucellosis spondylitis combined with
42 spondylolisthesis. Furthermore, the reconstruction of spinal stability may relieve pain, heal lesions,
43 and improve patients' living.

44 **Key words** lumbar spine; Brucellosis spondylitis; spondylolisthesis; surgical treatment

45 **Introduction**

46 Brucellosis is a common zoonosis affecting half a million people annually. The disease is
47 transmitted to humans through direct/indirect contact with infected animals or raw meat and dairy
48 product consumption. In China, the brucellosis epidemic mainly exists in Inner Mongolia
49 Autonomous Region and Hebei Province. Brucellosis could enter the human body through the
50 respiratory tract, skin, and digestive tract, resulting in human fever and multiple organ damage
51 [1,2]. Brucella mainly invades large joints, and the most frequently affected part is the spine [3].
52 The incidence of brucella spondylitis is 2% ~ 60% [4,5], which is prone to the lumbar spine. Due
53 to the apparent destruction of the upper and lower edges of the vertebral body, it is easy to cause
54 spinal instability [6].

55 At present, antibiotic treatment combined with surgical treatment is still the primary method
56 for treating Brucella spondylitis, and the clinical efficacy is not satisfactory for patients with
57 antibiotic treatment only. The patients with brucella spondylitis require surgical treatment,
58 accounting for 3% ~ 29% [4]. After spinal infection with Brucella, necrotic tissue or intervertebral
59 disc destruction occurs in the spinal canal. These lesions will cause indirect or direct compression
60 of the nerve and neurological symptoms. In addition, antibiotic treatment can not relieve the
61 symptoms caused by the compression of the spinal cord, cauda equina nerve, and nerve root, so
62 surgical treatment is required [7].

63 Lumbar spondylolisthesis is one of the common causes of low back and leg pain, and the
64 specific pathogenesis is unclear. Its classification and treatment methods are diverse. The
65 treatment principle is to restore the spinal sequence as much as possible and eliminate the causes
66 of pain [8]. At present, there is no unified theory about the choice of conservative and surgical

67 treatment, the choice of surgical approach, the choice of minimally invasive and open, and the
68 choice of fusion and decompression [9].

69 So far, there are few reports on surgical treatment of lumbar brucella spondylitis combined
70 with spondylolisthesis. This study evaluated the clinical efficacy of the single-stage posterior
71 surgical treatment for lumbar brucella spondylitis combined with spondylolisthesis.

72 **Materials and methods**

73 **Patient population**

74 From January 2015 to January 2019, we included 212 patients with lumbar brucella
75 spondylitis in our department. 142 patients were under antibiotic treatment, and 70 were treated
76 with surgery. Patients met the following indications for surgery: 1. Persisting low back pain; 2.
77 Progressive neurological deficit; 3. Spinal instability; 4. Paravertebral abscesses not easily
78 absorbed; 5. Poor outcomes following antibiotic treatment (ESR and CRP not significantly
79 decreased). 16 cases of lumbar brucella spondylitis combined with spondylolisthesis underwent
80 single-stage posterior debridement, reduction, interbody fusion, and instrumentation. (**Fig 1**)

81 The inclusion criteria were as follows: 1. Epidemic history: living in or having been to
82 pastoral areas, having exposure to cattle and sheep, or eating non sterilized cattle, mutton, or dairy
83 products; 2. Symptoms and signs: fever, sweats, fatigue, weight loss, low back pain, and lower
84 limb nerve symptoms; 3. Imaging findings: preoperative X-ray, CT, and MRI findings were
85 consistent with the signs of brucella spondylitis and combined with spondylolisthesis; 4.
86 Serological and microbiological evidence: Rose Bengal plate agglutination test (RBP) was
87 positive or histopathological examination was positive; 5. No other etiological findings (such as
88 *Mycobacterium tuberculosis*, *Staphylococcus aureus*, fungi, et al.). (**Table 1**)

89 All patients in this study voluntarily signed a written informed consent form to join the
90 scientific research and signed a written informed consent form for surgical treatment.

91 **Data collection**

92 The operation time, intraoperative bleeding, and complications were recorded. The patients
93 were followed up regularly at 2 weeks, 1 month, 2 months, 3 months, 6 months, and 1 year after
94 the operation. During the follow-up, X-rays of the lumbar spine were performed in the frontal,
95 lateral and dynamic positions, and a CT scan of the lumbar spine would be performed if necessary.
96 We calculated the spondylolisthesis reduction rate 2 weeks after operation by measuring the
97 vertebral body slippage, i.e. $(\text{preoperative slippage} - \text{postoperative slippage}) / \text{preoperative}$
98 $\text{slippage} \times 100\%$ [10]. The spondylolisthesis rate at 2 weeks and 1 year after operation was
99 measured by Taillard's measurement [11], and the reduction loss rate was also calculated. In
100 addition, we observed the condition of the fusion of bone graft and checked the instrumentation 2
101 weeks and 1 year after the operation [12,13]. The visual analysis scale (VAS), the Japanese
102 Orthopaedic Association scores (JOA), the Oswestry disability index (ODI), and laboratory tests
103 included preoperative and postoperative erythrocyte sedimentation rate (ESR), and C-reactive
104 protein (CRP) were recorded.

105 **Preoperative preparation**

106 Patients were treated with combinations of antibiotics. The regimens included oral
107 doxycycline 200 mg/day, oral rifampicin 600mg/day, and intravenous levofloxacin 500mg/day, or
108 plus intravenous ceftriaxone sodium 2g/day for at least 6 weeks. In addition, nutrition
109 enhancement and correction of anemia and hypoproteinemia in needed patients were also carried
110 out.

111 **Surgical techniques**

112 Under general anesthesia, the patients were placed in the prone position. The pedicle of the
113 spondylolisthesis vertebral body was determined and marked fluoroscopically. First, the posterior
114 median incision was made. Then, the skin, subcutaneous, and fascia layers were incised
115 successively and separated to both sides along the spinous process until the lamina and facet joints.
116 Then reduction screws were placed on both sides of the spondylolisthesis vertebral body, and
117 ordinary pedicle screws were placed in the adjacent vertebral body. Subsequently, unilateral or
118 bilateral fenestration decompression was performed. Then, the inflammatory tissues in the spinal
119 canal, intervertebral space, paravertebral and damaged bone were removed entirely, and the
120 intervertebral space was removed until there was blood exudation. Then, we repeatedly washed it
121 with a flushing gun, dried it, installed the longitudinal connecting rod, and lifted and restored the
122 spondylolisthesis vertebral body while opening the intervertebral space properly. Finally, the
123 bitten autologous bone was implanted into the bone defect between vertebrae, and then the
124 polyetheretherketone (PEEK) cage was obliquely inserted. After moderate compression, it was
125 tightened and fixed. Then, we rewashed the gun. After checking that there was no active bleeding,
126 we placed a drainage tube routinely and sutured the incision layer by layer. In the end, the tissues
127 taken during the operation were sent for pathological examination. (**Fig.2**)

128 **Statistical analysis**

129 All statistical analyses were performed using the SPSS software (version 25.0; IBM SPSS,
130 New York). Continuous variables were presented as mean \pm standard deviation or medians with
131 interquartile ranges, while categorical variables as the frequencies or percentages of events.
132 Mann-Whitney U test was used for nonnormally distributed continuous variables and a t-test for

133 normally distributed variables. VAS, JOA, ODI, ESR, and CRP were conducted with repeated
134 measures analysis of variance data. The P value ≤ 0.05 was considered to indicate statistical
135 significance.

136 **Results**

137 **Basic information**

138 Among the 16 patients, there were 14 males and 2 females. The age ranged from 46 to 68
139 years, with an average of (59.2 ± 6.5) years. The follow-up time of 16 patients ranged from 12 to
140 36 months, with an average of (25.0 ± 8.1) months. In addition, 12 patients had a history of living
141 in or having been to pastoral areas, and 14 patients had a history of having exposure to cattle and
142 sheep or eating non sterilized cattle, mutton, or dairy products.

143 All patients had back pain (100%), followed by weakness or fatigue (87.5%), fever (75%),
144 sweats (75%), then weight loss and neurological symptoms of lower limbs (62.5%, respectively).

145 There were 3 cases of L1 / 2 slippage, 2 cases of L2 / 3 slippage, 1 case of L3 / 4 slippage, 4
146 cases of L4 / 5 slippage, and 6 cases of L5 / S1 slippage. There were 9 cases of anterior slippage
147 and 7 cases of posterior slippage, including 10 cases with the isthmus. In addition, there were 11
148 cases with grade I, 5 with grade II, and no grade III, according to Meyerding grade [14]. (**Table 1**)

149 **Surgical data and findings**

150 The operation time of 16 patients ranged from 1.5 h to 3.0 h, the median was 2.0 (1.5,2.0) h,
151 the amount of bleeding was 300 ml ~ 550 ml, and the average was (403.1 ± 64.2) ml. The
152 incisions of 14 patients healed in the first stage, and 2 patients healed delayed due to local scabs.
153 There were no related complications, and no spinal cord, cauda equina, nerve root, and vascular
154 injury were found early after the operation.

155 The pathological HE staining of 16 patients showed many inflammatory cells such as
156 monocytes, lymphocytes, and neutrophils in the lesion area, which was consistent with the
157 changes in brucellosis. Brucella could be seen by Giemsa staining. (Fig.3)

158 **Comparison of preoperative and postoperative lumbar function index**

159 The VAS score decreased from 8.0 (8.0,8.8) preoperatively to 2.0 (1.3,2.0) and 0.0 (0.0,1.0)
160 at 2 weeks and 1 year after the operation, respectively. The JOA score increased from the average
161 (11.8 ± 3.6) preoperatively to (18.6 ± 2.3) and (23.6 ± 2.7) at 2 weeks and 1 year after the
162 operation, respectively. ODI index decreased from (88.5 ± 5.6) % preoperatively to (35.7 ± 3.1) %
163 and (9.3 ± 5.7) % at 2 weeks and 1 year after the operation, respectively. VAS score, JOA score,
164 and ODI index at 2 weeks and 1 year after the operation were significantly different from those
165 before the operation ($P = 0.000$) (Table 2). Moreover, 1 year after the operation, the VAS score,
166 JOA score, and ODI index were significantly different from those 2 weeks after the operation ($P =$
167 0.000) (Table 2).

168 **Comparison of preoperative and postoperative ESR and CRP**

169 ESR and CRP gradually decreased to normal in 16 patients. ESR decreased from 35.5
170 (14.5,43.0) mm/h preoperatively to (12.9 ± 5.3) mm/h and (9.2 ± 3.6) mm/h at 2 weeks and 1 year
171 after the operation, respectively. CRP decreased from (20.3 ± 10.2) mg/l preoperatively to (7.6 ±
172 3.1) and (3.5 ± 1.7) mg/l at 2 weeks and 1 year after the operation, respectively. ESR and CRP at 2
173 weeks and 1 year after the operation were significantly different from those before the operation
174 ($P = 0.000$) (Table 2). Moreover, 1 year after the operation, ESR and CRP were significantly
175 different from those 2 weeks ($P = 0.000$). (Table 2)

176 **Radiological evaluation**

177 The average spondylolisthesis reduction rate 2 weeks after operation was (91.2 ± 6.7) %, and
178 the median reduction loss rate 1 year after operation was 8.0 (5.0,9.8) %. At the last follow-up, all
179 patients achieved interbody fusion without loosening or fracture of instrumentation, and no patient
180 had recurrence (**Fig. 2**).

181 **Discussion**

182 The pathological changes of brucella spondylitis are mainly infectious vertebrates and discitis,
183 with vertebral destruction, spinal instability, and spinal cord or nerve compression [3-5,15]. In
184 recent years, with further research on spinal biomechanics, researchers believed that surgery
185 should be carried out to remove the lesions and reconstruct spinal stability to relieve pain and
186 promote the recovery of nerve function when antibiotic treatment is not enough for curing
187 [7,16,17]. Tebet [18] classified the causes of spondylolisthesis as isthmic, degenerative, and
188 traumatic, especially isthmus and degeneration. The incidence of lumbar spondylolisthesis in the
189 general population is about 2% ~ 6%. However, few studies on the correlation between brucella
190 spondylitis and lumbar spondylolisthesis have been done. There is also a lack of statistical data on
191 the incidence of lumbar spondylolisthesis in patients with brucella spondylitis. As we all know,
192 the spine's stability depends on the joint maintenance of the complete vertebral body,
193 intervertebral disc, pedicle, ligament, and surrounding tissue. We believe that brucella spondylitis
194 mainly invades the adjacent vertebral upper and lower endplates and intervertebral discs, which
195 easily destroy the spine's stability, aggravate the degeneration, and then cause spondylolisthesis. In
196 this study, 10 of the 16 patients (62.6%) were combined with isthmus, with a high proportion,
197 which is one of the main factors of lumbar spondylolisthesis.

198 Clinically, various surgical methods for brucella spondylitis include anterior, posterior, or

199 anterior and posterior debridement for bone graft fusion, and minimally invasive surgical methods,
200 which emerged in recent years [7,16,17,19,20]. The traditional surgical methods of brucella
201 spondylitis are anterior and posterior combined debridement, bone graft fusion, and
202 instrumentation. This method has obvious disadvantages, including long operation time, changing
203 body position during operation, and too complex operation [21,22]. Therefore, more surgeons
204 have chosen posterior debridement, bone graft fusion, and instrumentation in recent years. This
205 operation avoids the shortcomings of traditional operations and can significantly reduce the
206 probability of recurrence [16,17,19]. The surgical methods of lumbar spondylolisthesis are also
207 diverse. The most classic surgical methods are posterior interbody fusion. Transforaminal and
208 extreme lateral approaches gradually developed, including the oblique lateral approach, which has
209 sprung up in recent years, are posterior. The surgical core is reduction, decompression, fixation,
210 and fusion [23,24]. So, we adopted a posterior approach in this study.

211 The spine's stability needs a typical spinal sequence to maintain, but there are still disputes
212 about whether the spondylolisthesis needs reduction and the degree of reduction. Poussa et al. [25]
213 showed that in situ fusion of spondylolisthesis vertebral body could also achieve satisfactory
214 clinical results, while spondylolisthesis reduction might bring discomfort for patients. On the other
215 hand, Dewald et al. [26] reported that complete reduction would lead to excessive nerve root
216 traction. Therefore, a partial reduction of the spondylolisthesis vertebral body should be
217 recommended. More researchers [27,28] suggested reducing the spondylolisthesis vertebral body
218 to the greatest extent, which will help restore the typical spinal sequence and promote bone graft
219 fusion. As the postoperative recovery of brucella spondylitis needs stability, we reduced the
220 spondylolisthesis vertebral body during the operation as much as possible in this study.

221 However, the reduction is temporary, and bone graft fusion is the ultimate goal. The use of
222 internal fixation instruments could maintain the reduction of the spondylolisthesis vertebral body,
223 and bone graft fusion would help the stability of the spine [29]. Dantas et al. [30] found that
224 posterolateral bone graft was not on the load-bearing axis, which was prone to the non-fusion of
225 bone graft or formation of the pseudo joint. Through a follow-up study, Miyashita et al. [31] found
226 that pedicle screws and interbody fusion cage could rebuild spinal stability, effectively maintain
227 the height of intervertebral space, reduce screw pressure, and reduce the incidence of fracture and
228 loosening of pedicle screws. Compared with simple debridement and bone graft fusion,
229 instrumentation could make the local stability conducive to bone graft fusion and promote lesions
230 cure, with fewer postoperative complications and a low recurrence rate [7,17,32]. Bone graft
231 fusion is the basis of spinal stability. Therefore, internal fixation instruments are conducive to
232 bone graft fusion. Said et al. [33] researched that the patients with lumbar spondylolisthesis
233 combined with an isthmus, posterior interbody fusion might restore spinal stability, improve bone
234 graft fusion, and have an excellent long-term clinical effect. In this study, 62.6% of patients were
235 complicated with an isthmus. Therefore, we adopted polyetheretherketone (PEEK) cages,
236 interbody fusion, and pedicle screw fixation.

237 The postoperative follow-up showed that the average spondylolisthesis reduction rate in 16
238 patients was (91.2 ± 6.7) % two weeks after the operation. The median reduction loss rate was 8.0
239 $(5.0,9.8)$ % one year after the operation, indicating the beneficial influence of the surgery. At the
240 last follow-up, all patients had an interbody fusion, no loosening, fractures of instrumentation
241 were found, and no patient had a recurrence, which means satisfactory clinical outcomes. During
242 the follow-up, the clinical symptoms of 16 patients gradually improved, and the inflammatory

243 indexes were back to normal. In addition, we found that the VAS score, JOA score, ODI index,
244 ESR, and CRP at two-week and one-year follow-up were significantly different from those before
245 the operation, which showed a marked improvement in the patient's condition. Moreover, VAS
246 score, JOA score, ODI index, ESR, and CRP at one-year follow-up were significantly better than
247 those at two-week follow.

248 Our study had limitations: the number of patients was small, the evaluation indicators were
249 insufficient, and the possibility of bias hampered the retrospective studies. Therefore, further
250 observation, research, and clinical evaluation of cohort studies are needed.

251 In conclusion, a single-stage posterior approach could achieve a beneficial outcome for
252 patients with lumbar brucella spondylitis combined with spondylolisthesis. Posterior lumbar
253 debridement, reduction, interbody fusion, and instrumentation could reconstruct the spine's
254 stability, relieve pain and promote the recovery of nerve function.

255 **Acknowledgements**

256 The authors thank the participants for making this study possible and the Department of Pathology
257 for technical support. This research was funded by the science foundation of Beijing Ditan
258 Hospital Capital Medical University (No.DTQL201803).

259 **Conflict of interests**

260 The authors declare that they have no conflict of interest.

261 **Funding**

262 This research was funded by the science foundation of Beijing Ditan Hospital Capital Medical
263 University (No.DTQL201803).

264 **Ethics approval and consent to participate**

265 Ethical approval from the Ethics Committee of Beijing Ditan Hospital, Capital Medical University
266 was obtained for this study. Each author certifies that all investigations were conducted in
267 conformity with ethical principles.

268 **Author contributions**

269 YZ and CSZ conceived the manuscript, participated in the collection of clinical data and
270 manuscript writing; YZ and JMC participated in the pathological examination, YZ and QZ
271 participated in the manuscript revision. All authors read and approved the final manuscript.

272 **References**

- 273 1. Tao Z, Chen Q, Chen Y, Li Y, Mu D, Yang H, Yin W.(2021) Epidemiological Characteristics
274 of Human Brucellosis - China, 2016-2019.China CDC Wkly. 3(6):114-119. [http://doi:
275 10.46234/ccdcw2021.030](http://doi:10.46234/ccdcw2021.030).
- 276 2. Liang C, Wei W, Liang X, De E, Zheng B. (2019) Spinal brucellosis in Hulunbuir, China,
277 2011-2016.Infect Drug Resist.12:1565-1571. [http://doi: 10.2147/IDR.S202440](http://doi:10.2147/IDR.S202440).
- 278 3. Sade R, Polat G, Ogul H, Kantarci M. (2017) Brucella spondylodiscitis.Med Clin
279 (Barc).149(5):234. [http://doi: 10.1016/j.medcli.2016.10.043](http://doi:10.1016/j.medcli.2016.10.043).
- 280 4. Deng Y, Liu X, Duan K, Peng Q. (2019) Research Progress on Brucellosis.Curr Med
281 Chem.26(30):5598-5608. [http://doi: 10.2174/0929867325666180510125009](http://doi:10.2174/0929867325666180510125009).
- 282 5. Kil-Byung Lim, Yee-Gyung Kwak, Dug-Young Kim, Young-Sup Kim, Jeong-A Kim. (2012)
283 Back pain secondary to Brucella spondylitis in the lumbar region.Ann Rehabil Med.36(2):282-286.
284 [http://doi: 10.5535/arm.2012.36.2.282](http://doi:10.5535/arm.2012.36.2.282).
- 285 6. Seyed Mokhtar Esmailnejad-Ganji, Seyed Mohammad Reza Esmailnejad-Ganji. (2019)
286 Osteoarticular manifestations of human brucellosis: A review. World J Orthop.10(2):54-62.

287 [http://doi: 10.5312/wjo.v10.i2.54](http://doi:10.5312/wjo.v10.i2.54).

288 7. Unuvar GK, Kilic AU, Doganay M. (2019) Current therapeutic strategy in osteoarticular
289 brucellosis. *North Clin Istanbul*.6(4):415-420. [http://doi: 10.14744/nci.2019.05658](http://doi:10.14744/nci.2019.05658).

290 8. Chan AK, Sharma V, Robinson LC, Mummaneni PV. (2019) Summary of Guidelines for the
291 Treatment of Lumbar Spondylolisthesis. *Neurosurg Clin N Am*.30(3):353-364. [http://doi:](http://doi:10.1016/j.nec.2019.02.009)
292 [10.1016/j.nec.2019.02.009](http://doi:10.1016/j.nec.2019.02.009).

293 9. Mohamad Bydon, Mohammed Ali Alvi, Anshit Goyal. (2019) Degenerative Lumbar
294 Spondylolisthesis: Definition, Natural History, Conservative Management, and Surgical Treatment.
295 *Neurosurg Clin N Am*. 30(3):299-304. [http://doi: 10.1016/j.nec.2019.02.003](http://doi:10.1016/j.nec.2019.02.003).

296 10. Steinhaus ME, Vaishnav AS, Shah SP, Clark NJ, Chaudhary CB, Othman YA, Urakawa H,
297 Samuel AM, Lovecchio FC, Sheha ED, McAnany SJ, Qureshi SA. (2022) Does loss of
298 spondylolisthesis reduction impact clinical and radiographic outcomes after minimally invasive
299 transforaminal lumbar interbody fusion? *Spine* J.22(1):95-103. [http://doi:](http://doi:10.1016/j.spinee.2021.06.009)
300 [10.1016/j.spinee.2021.06.009](http://doi:10.1016/j.spinee.2021.06.009). Epub 2021 Jun 10.

301 11. Yao-Yao Liu, Jun Xiao, Huai-Jian Jin, Zhong Wang, Xiang Yin, Ming-Yong Liu, Jian-Hua
302 Zhao, Peng Liu, Fei Dai. (2020) Comparison of unilateral and bilateral
303 polymethylmethacrylate-augmented cannulated pedicle screw fixation for the management of
304 lumbar spondylolisthesis with osteoporosis. *J Orthop Surg Res*.15(1):446. [http://doi:](http://doi:10.1186/s13018-020-01975-1)
305 [10.1186/s13018-020-01975-1](http://doi:10.1186/s13018-020-01975-1).

306 12. S I Suk, C K Lee, W J Kim, J H Lee, K J Cho, H G Kim. (1997) Adding posterior lumbar
307 interbody fusion to pedicle screw fixation and posterolateral fusion after decompression in
308 spondylolysis spondylolisthesis. *Spine (Phila Pa 1976)*.22(2):210-219; discussion 219-220.

- 309 [http://doi: 10.1097/00007632-199701150-00016](http://doi:10.1097/00007632-199701150-00016).
- 310 13. Hiroaki Nakashima, Yasutsugu Yukawa, Keigo Ito, Yumiko Horie, Masaaki Machino,
311 Shunsuke Kanbara, Daigo Morita, Shiro Imagama, Naoki Ishiguro, Fumihiko Kato. (2011)
312 Extension CT scan: its suitability for assessing fusion after posterior lumbar interbody fusion. *Eur*
313 *Spine J.* 20(9):1496-1502. [http://doi: 10.1007/s00586-011-1739-0](http://doi:10.1007/s00586-011-1739-0).
- 314 14. Ezekial Koslosky, David Gendelberg. (2020) Classification in Brief: The Meyerding
315 Classification System of Spondylolisthesis. *Clin Orthop Relat Res.* 478(5):1125-1130. [http://doi:](http://doi:10.1097/CORR.0000000000001153)
316 [10.1097/CORR.0000000000001153](http://doi:10.1097/CORR.0000000000001153).
- 317 15. Jiao H, Zhou Z, Li B, Xiao Y, Li M, Zeng H, Guo X, Gu G. (2021) The Mechanism of
318 Facultative Intracellular Parasitism of *Brucella*. *Int J Mol Sci.* 22(7):3673. [http://doi:](http://doi:10.3390/ijms22073673)
319 [10.3390/ijms22073673](http://doi:10.3390/ijms22073673).
- 320 16. Peng Na, Yang Mingzhi, Xinhua Yin, Yong Chen. (2021) Surgical management for lumbar
321 brucella spondylitis: Posterior versus anterior approaches. *Medicine (Baltimore).* 100(21):e26076.
322 [http://doi: 10.1097/MD.00000000000026076](http://doi:10.1097/MD.00000000000026076).
- 323 17. Rugang Zhao, Rui Ding, Qiang Zhang. (2020) Safety and efficacy of polyetheretherketone
324 (PEEK) cages in combination with one-stage posterior debridement and instrumentation in
325 Lumbar *Brucella* Spondylitis. *Clin Neurol Neurosurg.* 199:106259. [http://doi:](http://doi:10.1016/j.clineuro.2020.106259)
326 [10.1016/j.clineuro.2020.106259](http://doi:10.1016/j.clineuro.2020.106259).
- 327 18. Marcos Antonio Tebet. (2014) Current concepts on the sagittal balance and classification of
328 spondylolysis and spondylolisthesis. *Rev Bras Ortop.* 49(1):3-12. [http://doi:](http://doi:10.1016/j.rboe.2014.02.003)
329 [10.1016/j.rboe.2014.02.003](http://doi:10.1016/j.rboe.2014.02.003).
- 330 19. Chen Y, Yang JS, Li T, Liu P, Liu TJ, He LM, Qian LX, Hao DJ. (2017) One-stage Surgical

- 331 Management for Lumbar Brucella Spondylitis by Posterior Debridement, Autogenous Bone Graft
332 and Instrumentation: A Case Series of 24 Patients. *Spine (Phila Pa 1976)*. 42(19):E1112-E1118.
333 [http://doi: 10.1097/BRS.0000000000002093](http://doi:10.1097/BRS.0000000000002093).
- 334 20. Yin XH, Liu ZK, He BR, Hao DJ. (2018) One-stage surgical management for lumbar brucella
335 spondylitis with anterior debridement, autogenous graft, and instrumentation. *Medicine*
336 (Baltimore). 97(30):e11704. [http://doi: 10.1097/MD.00000000000011704](http://doi:10.1097/MD.00000000000011704).
- 337 21. Hangli Wu, Yaqing Cui, Liqun Gong, Jun Liu, Yayi Fan, Yongchun Zhou, Weiwei Li. (2021)
338 Comparison between single anterior and single posterior approaches of debridement interbody
339 fusion and fixation for the treatment of mono-segment lumbar spine tuberculosis. *Arch Orthop*
340 *Trauma Surg.* [http://doi: 10.1007/s00402-021-03955-4](http://doi:10.1007/s00402-021-03955-4). Online ahead of print.
- 341 22. Ufuk Talu, Abdullah Gogus, Cagatay Ozturk, Azmi Hamzaoglu, Unsal Domanic. (2006) The
342 role of posterior instrumentation and fusion after anterior radical debridement and fusion in the
343 surgical treatment of spinal tuberculosis: experience of 127 cases. *J Spinal Disord Tech*.
344 19(8):554-559. [http://doi: 10.1097/01.bsd.0000211202.93125.c7](http://doi:10.1097/01.bsd.0000211202.93125.c7).
- 345 23. Liu AF, Guo TC, Chen JX, Yu WJ, Feng HC, Niu PY, Zhai JB. (2021) Efficacy and Safety of
346 Oblique Lumbar Interbody Fusion Versus Transforaminal Lumbar Interbody Fusion for
347 Degenerative Lumbar Spondylolisthesis: A Systematic Review and Meta-Analysis. *World*
348 *Neurosurg.* 2021:S1878-8750(21)01838-6. [http://doi: 10.1016/j.wneu.2021.11.127](http://doi:10.1016/j.wneu.2021.11.127).
- 349 24. Chang MC, Kim GU, Choo YJ, Lee GW. (2021) Transforaminal Lumbar Interbody Fusion
350 (TLIF) versus Oblique Lumbar Interbody Fusion (OLIF) in Interbody Fusion Technique for
351 Degenerative Spondylolisthesis: A Systematic Review and Meta-Analysis. *Life (Basel)*. 11(7):696.
352 [http://doi: 10.3390/life11070696](http://doi:10.3390/life11070696).

- 353 25. Mikko Poussa, Ville Remes, Tommi Lamberg, Pekka Tervahartiala, Dietrich Schlenzka, Timo
354 Yrjönen, Kalevi Osterman, Seppo Seitsalo, Ilkka Helenius. (2006) Treatment of severe
355 spondylolisthesis in adolescence with reduction or fusion in situ: long-term clinical, radiologic,
356 and functional outcome. *Spine (Phila Pa 1976)*.31(5):583-590; discussion 591-592. [http://doi:
357 10.1097/01.brs.0000201401.17944.f7](http://doi:10.1097/01.brs.0000201401.17944.f7).
- 358 26. Christopher J DeWald, Jennifer E Vartabedian, Mary F Rodts, Kim W Hammerberg. (2005)
359 Evaluation and management of high-grade spondylolisthesis in adults. *Spine (Phila Pa 1976)*. 30(6
360 Suppl):S49-59. [http://doi: 10.1097/01.brs.0000155573.34179.7e](http://doi:10.1097/01.brs.0000155573.34179.7e).
- 361 27. Kyle N Kunze, Daniel T Lilly, Jannat M Khan, Philip K Louie, Joseph Ferguson, Bryce A
362 Basques, Michael T Nolte, Christopher J Dewald. (2020) High-Grade Spondylolisthesis in Adults:
363 Current Concepts in Evaluation and Management. *Int J Spine Surg*. 14(3):327-340. [http://doi:
364 10.14444/7044](http://doi:10.14444/7044). eCollection 2020 Jun.
- 365 28. Rui He, Guo-Lin Tang, Kun Chen, Zheng-Liang Luo, Xifu Shang. (2020) Fusion in situ versus
366 reduction for spondylolisthesis treatment: grading the evidence through a meta-analysis. *Biosci
367 Rep*. 40(6):BSR20192888. [http://doi: 10.1042/BSR20192888](http://doi:10.1042/BSR20192888).
- 368 29. Austevoll IM, Hermansen E, Fagerland MW, Storheim K, Brox JI, Solberg T, Rekeland F,
369 Franssen E, Weber C, Brisby H, Grundnes O, Algaard KRH, Böker T, Banitalebi H, Indrekvam K,
370 Hellum C; NORDSTEN-DS Investigators. (2021) Decompression with or without Fusion in
371 Degenerative Lumbar Spondylolisthesis. *N Engl J Med*. 385(6):526-538. [http://doi:
372 10.1056/NEJMoa2100990](http://doi:10.1056/NEJMoa2100990).
- 373 30. Dantas F, Dantas FLR, Botelho RV. (2021) Effect of interbody fusion compared with
374 posterolateral fusion on lumbar degenerative spondylolisthesis: a systematic review and

375 meta-analysis. Spine J. 2021:S1529-9430(21)01051-2. [http://doi: 10.1016/j.spinee.2021.12.001](http://doi:10.1016/j.spinee.2021.12.001).

376 Online ahead of print.

377 31. Miyashita T, Ataka H, Kato K, Tanno T. (2022) Good 5-year postoperative outcomes after

378 facet fusion using a percutaneous pedicle screw system for degenerative lumbar spondylolisthesis.

379 Neurosurg Rev. 2022. [http://doi: 10.1007/s10143-022-01747-x](http://doi:10.1007/s10143-022-01747-x). Online ahead of print.

380 32. Abulizi Y, Cai X, Xu T, Xun C, Sheng W, Gao L, Maimaiti M. (2021) Diagnosis and Surgical

381 Treatment of Human Brucella Spondylodiscitis. J Vis Exp. (171). [http://doi: 10.3791/61840](http://doi:10.3791/61840).

382 33. Said E, Abdel-Wanis ME, Ameen M, Sayed AA, Mosallam KH, Ahmed AM, Tammam H.

383 (2021) Posterolateral Fusion Versus Posterior Lumbar Interbody Fusion: A Systematic Review

384 and Meta-Analysis of Randomized Controlled Trials. Global Spine J. 2021:21925682211016426.

385 [http://doi: 10.1177/21925682211016426](http://doi:10.1177/21925682211016426). Online ahead of print.

386 **Figure legends**

387 **Figure 1. Flowchart showing study enrollment**

388 **Figure 2. Preoperative and postoperative imaging findings of typical patients**

389 **a-f** Preoperative X-ray showed L4 vertebral body slipped backward II, lumbar instability in a

390 dynamic position, and no obvious isthmus was found in a double oblique position. **g-h**

391 Preoperative CT showed multiple lesions at the upper and lower edges of the vertebral body. **i-l**

392 Preoperative MRI showed uneven abnormal signal changes in the vertebral body and

393 intervertebral disc. **m-n** Two weeks after the operation, X-ray showed L4 spondylolisthesis

394 reduction. **o-p** One year after the operation, X-ray showed there was no apparent loss of

395 spondylolisthesis reduction, and the spine was stable. **q-r** One year after the operation, CT showed

396 interbody fusion had been achieved, and the damaged area was repaired well.

397 **Figure 3. Histopathological results of postoperative lesions**

398 **a** HE staining showed many different types of inflammatory cells in the lesions (x400). **b** Brucella

399 saw by Giemsa staining (x1000)

400 **Tables**

401 **Table 1. Clinical data of patients**

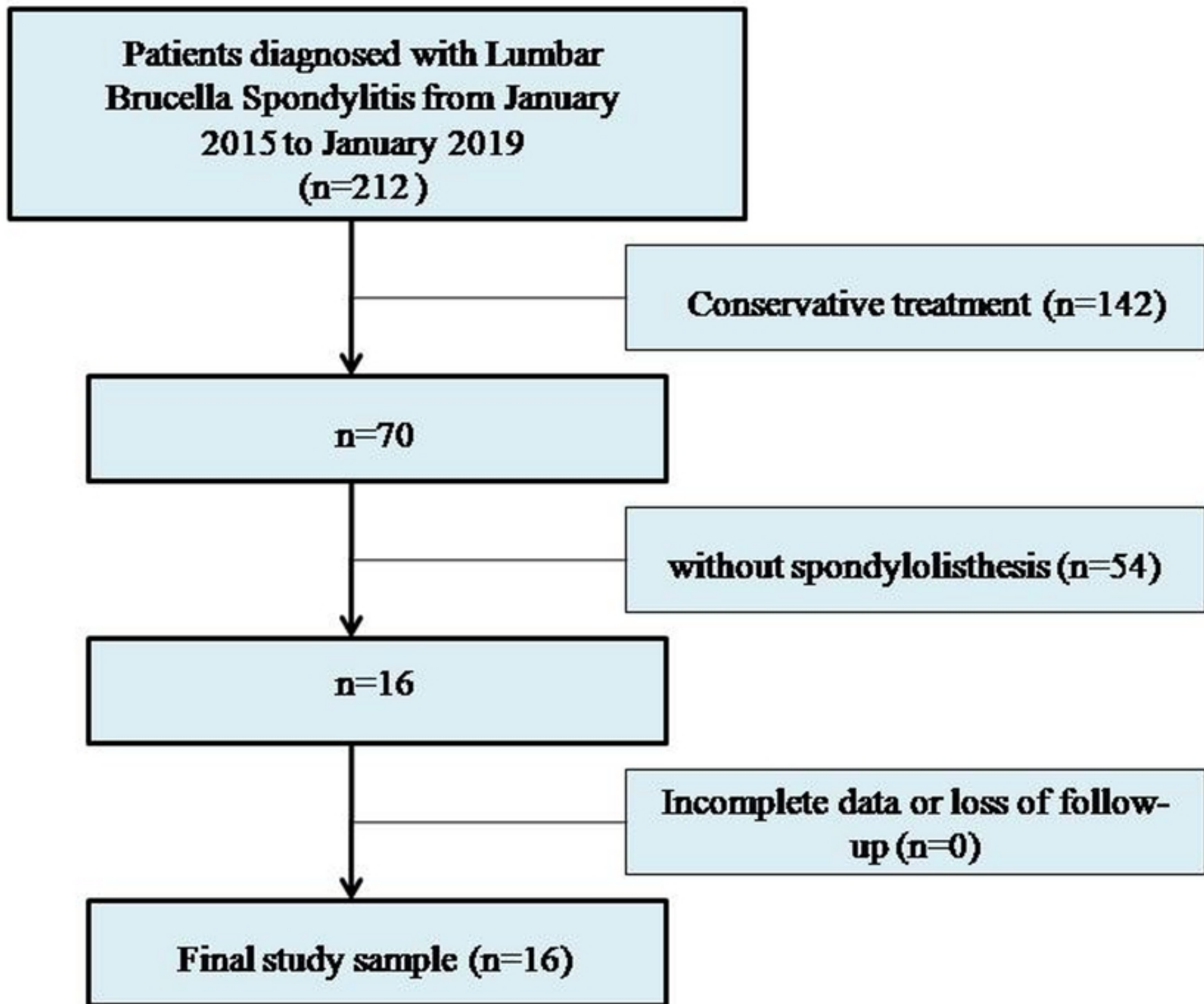
| | N (%) | | N (%) |
|---|-----------|-------------------------|-----------|
| Epidemic history | | Imaging findings | |
| Living in or having been to pastoral areas | 12(75%) | L1/2 | 3(18.8%) |
| Contact history | 14(87.5%) | L2/3 | 2(12.5%) |
| Clinical symptoms | | L3/4 | 1(6.3%) |
| Fever | 12(75%) | L4/5 | 4(25%) |
| Sweats | 12(75%) | L5/S1 | 6(37.5%) |
| Weakness or fatigue | 14(87.5%) | Anterior slippage | 9(56.3%) |
| Weight loss | 10(62.5%) | Posterior slippage | 7(43.8%) |
| Back pain | 16(100%) | Grade I | 11(68.8%) |
| Neurological symptoms of lower limbs | 10(62.5%) | Grade II | 5(31.3%) |
| Serological evidence and microbiological evidenc | | Grade III | 0 |
| Rose Bengal plate agglutination test | 16(100%) | Isthmus | 10(62.5%) |
| Histopathological examination | 16 | Other pathogens | 0 |

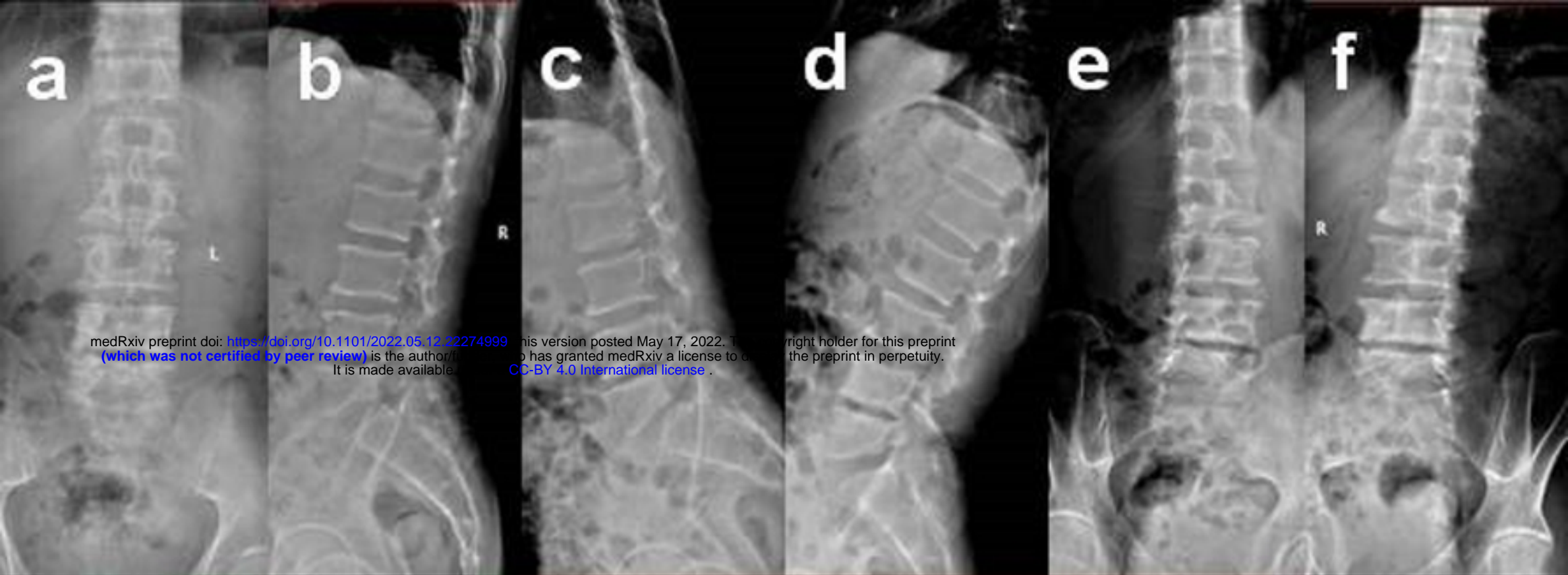402

403 **Table 2. Comparison of preoperative and postoperative VAS, JOA, ODI, ESR and CRP**

| | VAS | JOA | ODI (%) | ESR (mm/h) | CRP (mg/l) |
|------------------|--------------|----------|----------|-----------------|------------|
| Preoperative | 8.0(8.0,8.8) | 11.8±3.6 | 88.5±5.6 | 35.5(14.5,43.0) | 20.3±10.2 |
| 2-week follow-up | 2.0(1.3,2.0) | 18.6±2.3 | 35.7±3.1 | 12.9±5.3 | 7.6±3.1 |
| 1-year follow-up | 0.0(0.0,1.0) | 23.6±2.7 | 9.3±5.7 | 9.2±3.6 | 3.5±1.7 |
| Z/T | - | 102.651 | 612.140 | - | 37.095 |

| <i>P</i> | 0.000 | 0.000 | 0.000 | 0.000 | 0.000 |
|----------|--|-------|-------|-------|-------|
| 404 | VAS: preoperative vs. 2-week follow-up: $Z = -3.551, P = 0.000$; preoperative vs. 1-year follow-up: | | | | |
| 405 | $Z = -3.543, P = 0.000$; 2-week follow-up vs. 1-year follow-up: $Z = -3.508, P = 0.000$. | | | | |
| 406 | JOA: preoperative vs. 2-week follow-up: $T = -14.806, P = 0.000$; preoperative vs. 1-year | | | | |
| 407 | follow-up: $T = -11.802, P = 0.000$; 2-week follow-up vs. 1-year follow-up: $T = -6.899, P = 0.000$. | | | | |
| 408 | ODI: preoperative vs. 2-week follow-up: $T = 31.327, P = 0.000$; preoperative vs. 1-year follow-up: | | | | |
| 409 | $T = 36.063, P = 0.000$; 2-week follow-up vs. 1-year follow-up: $T = 20.702, P = 0.000$. | | | | |





medRxiv preprint doi: <https://doi.org/10.1101/2022.05.12.22274999>; this version posted May 17, 2022. The copyright holder for this preprint (which was not certified by peer review) is the author/funder, who has granted medRxiv a license to display the preprint in perpetuity. It is made available under a [CC-BY 4.0 International license](https://creativecommons.org/licenses/by/4.0/).

