

Brain Changes and Breast Cancer Antiestrogen Hormonal Therapy 1

Multimodal MRI examination of structural and functional brain changes in older women
with breast cancer in the first year of antiestrogen hormonal therapy

Brenna C. McDonald^{1*}, Kathleen M. Van Dyk^{2*}, Rachael L. Deardorff¹, Jessica N.
Bailey¹, Wanting Zhai³, Judith E. Carroll², James C. Root⁴, Tim A. Ahles⁴, Jeanne S.
Mandelblatt^{3^}, Andrew J. Saykin^{1^}

*Co-First Authors ^Co-Senior Authors

¹Department of Radiology and Imaging Sciences, Indiana University School of Medicine
and Indiana University Melvin and Bren Simon Comprehensive Cancer Center,
Indianapolis, IN, USA

²Department of Psychiatry and Biobehavioral Sciences, David Geffen School of
Medicine and UCLA Jonnson Comprehensive Cancer Center, University of California at
Los Angeles, Los Angeles, CA, USA

³Georgetown University and Georgetown Lombardi Comprehensive Cancer Center,
Washington, DC, USA

⁴Memorial Sloan Kettering Cancer Center, New York, NY, USA

Corresponding author:

Brenna McDonald, PsyD

mcdonalb@iupui.edu

ORCID: 0000-0001-6895-4490

Brain Changes and Breast Cancer Antiestrogen Hormonal Therapy 2

ClinicalTrials.gov Identifier: NCT03451383

Data from this study were presented in part at the meeting of the International Cognition and Cancer Task Force, Denver, CO, February 2020.

Running head: Brain Changes and Breast Cancer Antiestrogen Hormonal Therapy

Key words: Antiestrogen hormonal therapy, Breast cancer, Cognition, Multimodal MRI, Neuroimaging, Older women

Abstract

Purpose

Cancer patients are concerned about treatment-related cognitive problems. We examined effects of antiestrogen hormonal therapy on brain imaging metrics in older women with breast cancer.

Methods

Women aged 60+ treated with hormonal therapy only and matched non-cancer controls (n=29/group) completed MRI and objective and self-reported cognitive assessment at pre-treatment/enrollment and 12 months later. Gray matter was examined using voxel-based morphometry (VBM), FreeSurfer, and brain age calculations. Functional MRI (fMRI) assessed working memory-related activation. Analyses examined cross-sectional and longitudinal differences and tested associations between brain metrics, cognition, and days on hormonal therapy.

Results

The cancer group showed regional reductions over 12 months in frontal, temporal, and parietal gray matter on VBM, reduced FreeSurfer cortical thickness in prefrontal, parietal, and insular regions, and increased working memory-related fMRI activation in frontal, cingulate, and visual association cortex. Controls showed only reductions in fusiform gyrus on VBM and FreeSurfer temporal and parietal cortex thickness. Women with breast cancer showed higher estimated brain age and lower regional gray matter volume than controls at both timepoints. The cancer group showed a trend toward

Brain Changes and Breast Cancer Antiestrogen Hormonal Therapy 4

decreased performance in attention, processing speed, and executive function over time. There were no significant associations between brain imaging metrics and cognition or days on hormonal therapy.

Conclusion

Older women with breast cancer showed brain changes in the first year of hormonal therapy. Increased brain activation during working memory processing may be a sign of functional compensation for treatment-related structural changes. This hypothesis should be tested in larger samples over longer time periods.

Introduction

Breast cancer is the second most common cancer in US women, and over half of those diagnosed annually are ages 60 and older [1]. Seventy-five percent will be treated with 5-10 years of antiestrogen hormonal therapy (HT) [2-4], which is effective at reducing breast cancer recurrence through downregulating the action of estrogen in the body [3]. Estrogen is closely linked with cognitive function, especially in older women [5], and HTs cross the blood-brain barrier [6, 7], raising questions about the potential for cognitive side effects of this common treatment modality [6-8].

Despite years of clinical use, the extent to which HT affects cognition remains unclear due to limited research, inconsistent results, and differences in study design [9-21]. Recent results from the TAILORx trial comparing chemotherapy plus HT to HT alone showed self-reported cognitive concerns in both groups [22], and others have described worse self-reported cognition in women with breast cancer taking HT than non-cancer controls, despite little difference on cognitive testing [23]. We have also reported greater cognitive and other symptom burden in women with breast cancer on HT than non-cancer controls, and found that perceived cognitive difficulties are a risk factor for discontinuing HT [24, 25].

While extensively used to examine structural and functional brain changes after breast cancer chemotherapy [26-30], neuroimaging has not been widely applied to examine the impact of HT. Lower hippocampal volume and resting hippocampal-prefrontal

functional connectivity have been reported in women with breast cancer taking tamoxifen [31, 32], and Hurria and colleagues found metabolic changes on FDG-PET in post-menopausal women with breast cancer taking an aromatase inhibitor, notably in regions relevant to aging [33]. HT exposure intersects with known changes to the brain and cognitive function associated with aging and menopause that are being actively investigated using neuroimaging. Therefore, better understanding of HT effects on the brain is clinically relevant for older women with breast cancer.

This single-site study examined a subset of the larger Thinking and Living with Cancer (TLC) prospective cohort [34, 35] who underwent neuroimaging. We used structural and functional MRI metrics to compare older women with breast cancer from pre-HT baseline to 12-month follow-up with matched non-cancer controls. We tested whether older women with breast cancer on HT exhibited different patterns of change in brain structure and function in the first year of therapy relative to controls, and explored if changes were related to self-reported and objective cognitive outcomes. Given the small number of participants available from this single-site sample, these analyses are intended to be hypothesis-generating to guide future research.

Participants and Methods

The TLC Study is a national multicenter prospective cohort study (NCT03451383); overall study methods have been detailed previously [34, 35]. All data for this report were gathered between 2016-2020 at Indiana University (IU), the only TLC site

Brain Changes and Breast Cancer Antiestrogen Hormonal Therapy 7

conducting neuroimaging. Written informed consent was obtained from all participants according to the Declaration of Helsinki under a protocol approved by the IU Institutional Review Board.

Participants

Women with breast cancer are eligible for the TLC study if they have a new diagnosis of primary non-metastatic breast cancer. Those with a history of other cancers (except non-melanoma skin cancer) are excluded if active treatment was <5 years or included systemic therapy. All participants (cancer and non-cancer control groups) are women aged ≥ 60 years; exclusion criteria include neurological or major psychiatric disorders or sensory impairment precluding assessment. All TLC participants at IU are offered the opportunity to participate in MRI scanning, and screened for MRI safety/claustrophobia if interested. For this study of effects of HT, we included women with breast cancer treated with adjuvant HT but not chemotherapy who had MRI data at both pre-HT baseline and 12-month follow-up (n=29). Two additional women with breast cancer who took HT for <2 months and one who was prescribed raloxifene primarily for osteoporosis were excluded from analysis. We selected 29 controls with baseline and 12-month follow-up data who best matched the cancer group for age and education as a comparison group.

Data Collection

Assessments were completed at baseline (post-surgery, pre-radiation and/or HT) and 12-month follow-up, and included a survey capturing demographic, health history, and

symptom information, neuropsychological testing, and neuroimaging. Clinical information was abstracted from medical records of women with breast cancer.

Cognitive Measures

Objective cognitive assessment included domain-specific z-scores for attention, processing speed, and executive functioning (APE) and verbal learning and memory (LM). The APE domain consisted of the Digits Forward and Digits Backward subtests from the Neuropsychological Assessment Battery (NAB), Trail Making Tests A and B, the Controlled Oral Word Association Test, and the Digit Symbol subtest from the Wechsler Adult Intelligence Scale-III [36-39]. The LM domain consisted of the Logical Memory I and II subtests from the Wechsler Memory Scale-III and the Immediate Recall, Short Delayed Recall, and Long Delayed Recall scores from the NAB List Learning Test [38, 40]. Raw neuropsychological test scores were standardized to the baseline mean and standard deviation of the overall TLC control group, stratified by age and education, which were used to calculate the APE and LM domain scores.

Self-reported cognition was assessed using the Perceived Cognitive Impairments (PCI) score from the Functional Assessment of Cancer Therapy-Cognitive Function (FACT-Cog) [41].

Psychosocial and Clinical Measures

We used several psychosocial and clinical measures to characterize the study sample. Baseline verbal intellect was estimated using the Wide Range Achievement Test-4

Word Reading subtest [42]. Depressive and anxiety symptoms were assessed with the Center for Epidemiologic Studies-Depression Scale (CES-D) and the State-Trait Anxiety Inventory (STAI) State subscale [43, 44]. Past use of menopausal hormone replacement therapy, age at menopause, and days on HT were based on self-report and data from the medical record.

MRI scan acquisition

All scans were acquired on the same Siemens Prisma 3T scanner using a 64-channel head and neck coil. A T1-weighted three-dimensional magnetization prepared rapid gradient echo (MPRAGE) volume was used for voxel-based morphometry (VBM), FreeSurfer, and brain age calculations. A gradient-echo, echo-planar sequence was used for fMRI (see Online Resource 1 for sequence parameters).

Working Memory fMRI Task

A visual-verbal n-back task was used to elicit brain activation during working memory processing, as in our previous studies [45-60] and as recommended by the International Cognition and Cancer Task Force [61] (see Online Resource 1 for details).

Neuroimaging Preprocessing and Analysis

Voxel-Based Morphometry (VBM)

VBM was used to examine gray matter volume across the whole brain. T1-weighted images were processed using the standard longitudinal pipeline in Computational Anatomy Toolbox for SPM12 (CAT12.6). Statistical models were generated using a

Brain Changes and Breast Cancer Antiestrogen Hormonal Therapy 10

flexible factorial design to examine within- and between-group longitudinal changes, including group-by-time interactions, and a full factorial design to examine between-group cross-sectional differences (see Online Resource 1 for details). Overall significance was set at family-wise error (FWE) correction $p=0.05$. Clusters were considered significant at cluster-level $p_{\text{uncorrected}} < 0.05$. Participant mean values for clusters showing significantly reduced gray matter volume from baseline to follow-up were extracted using MATLAB for correlational analyses.

FreeSurfer

Cortical and volumetric segmentation was performed on T1-weighted images using the longitudinal FreeSurfer 6.0.0 pipeline [62]. A within-subject template image was created and used for skull stripping, Talairach transforms, and atlas registration prior to segmentation. For data reduction purposes, selected regional values were summed bilaterally to create prefrontal, temporal, parietal, basal ganglia, thalamus, limbic, and insular volumes and prefrontal, temporal, and parietal thicknesses (Online Resource 2). Participant mean values for regions showing significantly reduced gray matter thickness from baseline to follow-up were used for correlational analyses.

Brain Age

Predicted brain age values were generated with brainageR (version 1.0, <https://github.com/james-cole/brainageR/releases/tag/1.0>), which uses SPM12 and KernLab in R [63]. T1-weighted follow-up scans were registered to the baseline scan for each participant and then segmented. Predicted brain age was calculated using

Brain Changes and Breast Cancer Antiestrogen Hormonal Therapy 11

machine-learning Gaussian Process Regression (GPR) based on a training dataset of 2001 healthy individuals [64-66].

Task-Based fMRI

Preprocessing steps are detailed in Online Resource 1. Analyses focused on the most challenging working memory load condition (2-back>0-back). Statistical models were generated using a flexible factorial design to examine within- and between-group longitudinal changes, including group-by-time interactions, and a full factorial design to examine between-group cross-sectional differences. Overall cluster-level significance was set at $p=0.001$. Clusters were considered significant at cluster-level $p_{\text{uncorrected}} < 0.05$. Participant mean values for clusters showing significantly increased activation from baseline to follow-up were extracted using MATLAB for correlational analyses.

Other Statistical Analyses

T-tests and chi-square tests were used for between-group comparisons of demographic, cognitive, psychosocial, and clinical variables, self-reported and objective cognition, and FreeSurfer and brain age variables, as well as between-group differences in change over time. For FreeSurfer volume variables, analyses controlled for baseline total intracranial volume. Within-group longitudinal comparisons used paired t-tests. In the cancer group, Pearson's correlations examined relationships between change in neuroimaging variables, change in self-reported and objective cognitive outcomes, and days on HT. Analyses used SAS Version 9.4.b, and $p < 0.05$ was considered statistically significant.

Brain Changes and Breast Cancer Antiestrogen Hormonal Therapy 12

Given the minimal previous neuroimaging literature examining HT effects, we conducted three types of comparisons to best understand the data and generate hypotheses for future, larger studies. First, cross-sectional comparisons were conducted at each timepoint. It is important to examine baseline neuroimaging metrics in this older sample given pre-treatment neuroimaging differences found between younger women with breast cancer and controls [47, 67-70]. Cross-sectional differences at 12-month follow-up are also important for hypothesis generation, as our available sample size might limit power to detect differences in longitudinal change metrics. Second, within-group longitudinal change was examined to identify metrics showing significant alterations over 12 months. Third, we examined between-group differences in change over time (i.e., group-by-time interactions), to directly compare change in the cancer and control groups.

Results

Sample Characteristics

Groups were generally comparable at baseline (Table 1). The cancer group showed higher depressive symptoms ($p < 0.01$) and a trend toward higher anxiety symptoms at baseline ($p = 0.06$). Mean symptom levels were well below clinically meaningful thresholds [71, 72], however, and there were no significant between-group differences in change over time for depressive or anxiety symptoms ($p_s > 0.30$), so these variables were not included as covariates in analyses.

Brain Changes and Breast Cancer Antiestrogen Hormonal Therapy 13

Objective and Self-Reported Cognitive Functioning

Self-reported and objective cognitive function did not differ between groups at baseline (Table 2). At follow-up the breast cancer group showed a trend toward lower performance than controls in APE ($p=0.07$). Between-group comparison of change scores showed a trend level difference ($p=0.09$) for this scale, with controls showing significantly improved performance over time ($p=0.03$), consistent with practice effects, while women with breast cancer showed no change. There were no other significant findings for self-reported or objective cognition.

Whole-Brain Voxel-Based Morphometry

Women with breast cancer showed significantly lower gray matter volume than controls in a right frontal cluster (BA6) at both baseline and follow-up (Figure 1, Table 3). The cancer group showed significantly reduced gray matter volume over time in left temporal (BA38) and parietal (BA40) and bilateral frontal regions (BA10, BA44, and BA47) (Figure 2A, Table 3). Controls showed a single cluster of significant gray matter volume reduction in the right fusiform gyrus (BA37) (Figure 2B, Table 3). There were no regions at either timepoint in which gray matter volume was significantly greater in women with breast cancer than controls, and no regions of increased volume over time in either group. No clusters were significant in group-by-time interactions.

FreeSurfer Regional Analyses

Brain Changes and Breast Cancer Antiestrogen Hormonal Therapy 14

Women with breast cancer showed significantly lower volume than controls at both baseline and follow-up in prefrontal and temporal cortex (p s=0.02-0.008, Table 2).

There was a trend for lower basal ganglia volume in the cancer group at both timepoints (p s=0.05-0.06). Insular volume showed a trend for lower volume in the cancer group at baseline, with increased significance at follow-up (p s=0.06 and 0.045, respectively).

There were no significant within-group longitudinal changes in regional FreeSurfer volumes, nor between-group differences in change over time.

Women with breast cancer showed significant reduction over time in prefrontal, parietal, and insular cortex thickness (p s<0.05), as well as a trend toward lower insular cortex thickness relative to controls at follow-up (p =0.07). Controls showed reductions over time in temporal and parietal cortex thickness (p s=0.03-0.004). There were no significant between-group differences for cortical thickness at baseline or change over time.

Brain Age

Estimated brain age for controls was ~five years younger than chronological age on average, while estimates for women with breast cancer were comparable to chronological age; these significant group differences were observed at both baseline and follow-up (p =0.03, Table 2). There was no significant between-group difference in change in estimated brain age over time.

Working Memory fMRI

Brain Changes and Breast Cancer Antiestrogen Hormonal Therapy 15

There were no significant between-group differences in task-related activation at baseline, but at follow-up women with breast cancer showed significantly greater working memory-related activation than controls in right dorsolateral prefrontal (BA9) and dorsal posterior cingulate cortex (BA31) (Figure 3, Table 4). The cancer group showed significantly increased activation over time in right frontal (BA6, BA44, BA47) and visual association (BA19) and left frontal (BA6, BA9) and cingulate (BA23, BA32) cortex (Figure 4, Table 4). There were no regions in which women with breast cancer showed significantly decreased activation or in which controls showed significant change over time. No clusters were significant in group-by-time interactions.

Relationships of Brain Changes to Cognition and Time on Treatment

There were no significant correlations between change in VBM gray matter volume, FreeSurfer thickness, or working memory-related activation in women with breast cancer and change in APE, LM, FACT-Cog PCI, or 2-back accuracy or reaction time (all $p > 0.05$). There were also no significant correlations between these variables and days on HT (all $p > 0.05$).

Discussion

This is the first MRI study examining effects of the first 12 months of HT in older women with breast cancer. We used multiple structural and functional neuroimaging metrics and compared results to a demographically matched non-cancer control group. Women with breast cancer showed reductions in gray matter volume and cortical thickness over

Brain Changes and Breast Cancer Antiestrogen Hormonal Therapy 16

time that were not seen in controls. Brain age was higher in the cancer group than controls before therapy, an effect which persisted over time. While there were no significant associations between brain imaging metrics and cognition, women with breast cancer showed increased activation during working memory processing that was not seen in controls. Finally, in this first year of HT, there was no significant relationship between time on treatment and brain metrics. These results support the need for future examination of the role of HT in cancer-related cognitive decline over longer time periods.

Our findings in this small sample reveal a pattern of structural brain changes in the first year of HT. The few prior neuroimaging studies [31-33] of HT effects focused on single imaging modalities, single brain regions, or on women prescribed only tamoxifen or AIs; the one prior longitudinal study had only a six-month assessment interval. Given these limitations in comparability, it is noteworthy that the previous work also found regional gray matter reductions, as well as alterations in resting functional connectivity and cerebral metabolism related to HT. Our findings encourage the use of multiple, complementary imaging analytic methods and modalities in future work to increase sensitivity to detect differences in grey matter volume and thickness and brain activation.

Our finding that women with breast cancer had a higher estimated brain age and lower frontal and temporal gray matter volume than controls before systemic treatment is consistent with literature showing pre-treatment structural differences [67-70]. Such

Brain Changes and Breast Cancer Antiestrogen Hormonal Therapy 17

results are thought to reflect a potential contribution of other factors (e.g., other medical comorbidities, including cancer risk factors or disease processes, surgery or anesthesia exposure [73]) to brain function and cognition in individuals with cancer.

The observed neuroimaging changes were not directly associated with cognitive functioning or time on HT, raising several questions for future research. It may be that the first year of therapy is too limited an observation period (i.e., restricted range of length of time on HT). It is also possible that cumulative HT effects may take longer to manifest in detectable cognitive changes, or that the influence of HT is more complex than a function of additive exposure time. Notably, our results also suggest that functional compensatory mechanisms could be sustaining cognitive performance in the cancer group, despite the observed reductions in gray matter volume and thickness. We saw increased working memory-related brain activation in women with breast cancer over time, and greater activation in the cancer group than controls at follow-up. Given comparable task performance between groups, this may represent a compensatory response to maintain cognitive function, as has been hypothesized in other studies of women with breast cancer [45-47, 74, 75]. It will be important to examine larger, more heterogeneous samples and to follow women over a longer time period, given the potential for years of HT exposure. If increased brain activation is compensatory, this may suggest vulnerability for future cognitive changes when compensatory mechanisms and/or the benefits of higher baseline cognitive reserve are exhausted. HT exposure over the recommended 5-10 years has the potential to interact with other risks for cognitive decline (e.g., medical comorbidities, cognitive aging, dementia). Furthermore,

Brain Changes and Breast Cancer Antiestrogen Hormonal Therapy 18

while we only examined women who did not receive chemotherapy, HT and chemotherapy effects may be additive, especially as similar frontal and temporal regions appear vulnerable to effects of both types of treatment [26-30].

Much of the research studying cognitive effects of HT has focused on tamoxifen [8, 20, 21]. However, as in our study, post-menopausal women with breast cancer are most often prescribed aromatase inhibitors, which downregulate estrogen synthesis in the body and brain. Different classes of HT may have varying effects, but there were too few women on tamoxifen (only 28% of our sample) to compare regimen types. Future studies in broader age groups may be able to test hypotheses based on modes of action of different classes of HT. Overall, however, our findings suggest brain changes following HT exposure. These results are consistent with literature showing links between menopause, estrogen function, and changes in cognition and brain structure and function [76-80], as well as studies examining the potential for estrogen replacement therapy to protect the brain from cognitive decline and dementia [81, 82]. A prior fMRI study found greater working memory-related prefrontal activity in post-menopausal compared to pre- or peri-menopausal women [83], parallel to our finding that post-menopausal women with breast cancer on HT showed greater activation relative to controls. In a study of >500 post-menopausal women, younger brain age was associated with higher levels of circulating estrogen in APOE ϵ 4 noncarriers, but the opposite pattern was seen in APOE ϵ 4 carriers [84]. Since HTs cross the blood-brain barrier, their effects on brain estrogen levels are one biologically plausible explanation

Brain Changes and Breast Cancer Antiestrogen Hormonal Therapy 19

for brain changes and cognitive problems among women with breast cancer receiving HT.

This study used a comprehensive battery of MRI and cognitive metrics to generate clinically relevant hypotheses to fill gaps in knowledge about unanswered questions regarding effects of HT. Given the preliminary nature of our observations, there are several limitations that should be considered in evaluating the results and planning future studies. The sample size is small, which may have limited our ability to detect significant differences between groups or over time; however, our early data will be useful to inform power estimates for future studies. Clinical guidelines recommend that women diagnosed with hormone receptor positive breast cancers receive HT, so there were only four women with breast cancer in our neuroimaging study cohort who did not receive systemic treatment. Thus, we could not evaluate the effects of cancer itself over time separately from therapy. Participants were largely white; it is especially critical to study relationships between HT, cognition, and brain structure and function in minoritized individuals and samples from diverse backgrounds, who may have unique patterns of effects and contributing factors. Our sample was well-educated and likely representative of high cognitive reserve; it will be important to examine women with varying levels of cognitive reserve to discern potential differences in effects. The protocol also did not include testing of FSH/LH levels to explore effects of estrogen status. Finally, since this is an observational study, treatment type and adherence were subject to individual differences and introduced exposure variability. One opportunity to

Brain Changes and Breast Cancer Antiestrogen Hormonal Therapy 20

accelerate knowledge would be to add neuroimaging and cognitive assessments to randomized HT trials.

Overall, we found a clinically relevant pattern of structural and functional brain changes in post-menopausal women with breast cancer on HT that was not seen in non-cancer controls. HT is prescribed for the majority of women with breast cancer and is effective for preventing cancer recurrence. If confirmed, however, our results suggest there may be potential side effects from downregulating estrogen function in the brain among post-menopausal women. It will be important to replicate and extend our findings to longer-term outcomes in larger samples. Such studies will also be useful to determine which factors place women at greatest risk for brain changes on HT (e.g., APOE ϵ 4 genotype [85] or comorbidities), since any adverse brain effects can have a broad impact on quality of life and health care costs among the growing population of older breast cancer survivors.

Acknowledgements: The authors gratefully thank all the participants who graciously gave their time and effort to this work, and our research MRI technologists and neuroradiologist colleagues for their efforts to ensure the successful completion of the study. We also thank Michiel B. de Ruiter, PhD, for his assistance with brain age calculations and analysis. Finally, we wish to posthumously acknowledge the contributions of John D. West, MS to this research.

Brain Changes and Breast Cancer Antiestrogen Hormonal Therapy 21

References

1. Noone AM, Howlader N, Krapcho M, Miller D, Brest A, Yu M, Ruhl J, Tatalovich Z, Mariotto A, Lewis DR, Chen HS, Feuer EJ, Cronin KA, eds (based on November 2017 SEER data submission, posted to the SEER web site, April 2018) SEER Cancer Statistics Review, 1975-2015. National Cancer Institute, Bethesda, MD
2. American Cancer Society (2017) Breast Cancer Facts and Figures 2017-2018. American Cancer Society, Inc., Atlanta
3. Burstein HJ, Temin S, Anderson H, Buchholz TA, Davidson NE, Gelmon KE, Giordano SH, Hudis CA, Rowden D, Solky AJ, Stearns V, Winer EP, Griggs JJ (2014) Adjuvant endocrine therapy for women with hormone receptor-positive breast cancer: American Society of Clinical Oncology clinical practice guideline focused update. *J Clin Oncol* 32:2255-2269.
<https://doi.org/10.1200/jco.2013.54.2258>
4. Runowicz CD, Leach CR, Henry NL, Henry KS, Mackey HT, Cowens-Alvarado RL, Cannady RS, Pratt-Chapman ML, Edge SB, Jacobs LA, Hurria A, Marks LB, LaMonte SJ, Warner E, Lyman GH, Ganz PA (2016) American Cancer Society/American Society of Clinical Oncology breast cancer survivorship care guideline. *CA Cancer J Clin* 66:43-73. <https://doi.org/10.3322/caac.21319>
5. Hara Y, Waters EM, McEwen BS, Morrison JH (2015) Estrogen effects on cognitive and synaptic health over the lifecourse. *Physiol Rev* 95:785-807.
<https://doi.org/10.1152/physrev.00036.2014>

Brain Changes and Breast Cancer Antiestrogen Hormonal Therapy 22

6. Lien EA, Solheim E, Ueland PM (1991) Distribution of tamoxifen and its metabolites in rat and human tissues during steady-state treatment. *Cancer Res* 51:4837-4844.
7. Overk CR, Lu PY, Wang YT, Choi J, Shaw JW, Thatcher GR, Mufson EJ (2012) Effects of aromatase inhibition versus gonadectomy on hippocampal complex amyloid pathology in triple transgenic mice. *Neurobiol Dis* 45:479-487.
<https://doi.org/10.1016/j.nbd.2011.08.035>
8. Zwart W, Terra H, Linn SC, Schagen SB (2015) Cognitive effects of endocrine therapy for breast cancer: keep calm and carry on? *Nat Rev Clin Oncol* 12:597-606. <https://doi.org/10.1038/nrclinonc.2015.124>
9. Bender CM, Sereika SM, Brufsky AM, Ryan CM, Vogel VG, Rastogi P, Cohen SM, Casillo FE, Berga SL, Bender CM, Sereika SM, Brufsky AM, Ryan CM, Vogel VG, Rastogi P, Cohen SM, Casillo FE, Berga SL (2007) Memory impairments with adjuvant anastrozole versus tamoxifen in women with early-stage breast cancer. *Menopause* 14:995-998.
<https://doi.org/10.1097/gme.0b013e318148b28b>
10. Bender CM, Gentry AL, Brufsky AM, Casillo FE, Cohen SM, Dailey MM, Donovan HS, Dunbar-Jacob J, Jankowitz RC, Rosenzweig MQ, Sherwood PR, Sereika SM (2014) Influence of patient and treatment factors on adherence to adjuvant endocrine therapy in breast cancer. *Oncol Nurs Forum* 41:274-285.
<https://doi.org/10.1188/14.Onf.274-285>
11. Bender CM, Merriman JD, Gentry AL, Ahrendt GM, Berga SL, Brufsky AM, Casillo FE, Dailey MM, Erickson KI, Kratofil FM, McAuliffe PF, Rosenzweig MQ,

Brain Changes and Breast Cancer Antiestrogen Hormonal Therapy 23

- Ryan CM, Sereika SM (2015) Patterns of change in cognitive function with anastrozole therapy. *Cancer* 121:2627-2636. <https://doi.org/10.1002/cncr.29393>
12. Boele FW, Schilder CM, de Roode ML, Deijen JB, Schagen SB (2015) Cognitive functioning during long-term tamoxifen treatment in postmenopausal women with breast cancer. *Menopause* 22:17-25.
<https://doi.org/10.1097/gme.0000000000000271>
 13. Castellon SA, Ganz PA, Bower JE, Petersen L, Abraham L, Greendale GA (2004) Neurocognitive performance in breast cancer survivors exposed to adjuvant chemotherapy and tamoxifen. *J Clin Exp Neuropsychol* 26:955-969.
<https://doi.org/10.1080/13803390490510905>
 14. Collins B, Mackenzie J, Stewart A, Bielajew C, Verma S (2009) Cognitive effects of hormonal therapy in early stage breast cancer patients: a prospective study. *Psychooncology* 18:811-821. <https://doi.org/10.1002/pon.1453>
 15. Ganz PA, Petersen L, Castellon SA, Bower JE, Silverman DH, Cole SW, Irwin MR, Belin TR (2014) Cognitive function after the initiation of adjuvant endocrine therapy in early-stage breast cancer: an observational cohort study. *J Clin Oncol* 32:3559-3567. <https://doi.org/10.1200/jco.2014.56.1662>
 16. Jenkins V, Shilling V, Fallowfield L, Howell A, Hutton S (2004) Does hormone therapy for the treatment of breast cancer have a detrimental effect on memory and cognition? A pilot study. *Psychooncology* 13:61-66.
<https://doi.org/10.1002/pon.709>
 17. Lee PE, Tierney MC, Wu W, Pritchard KI, Rochon PA (2016) Endocrine treatment-associated cognitive impairment in breast cancer survivors: evidence

Brain Changes and Breast Cancer Antiestrogen Hormonal Therapy 24

from published studies. Breast Cancer Res Treat 158:407-420.

<https://dx.doi.org/10.1007/s10549-016-3906-9>

18. Phillips KA, Aldridge J, Ribí K, Sun Z, Thompson A, Harvey V, Thürlimann B, Cardoso F, Pagani O, Coates AS, Goldhirsch A, Price KN, Gelber RD, Bernhard J (2011) Cognitive function in postmenopausal breast cancer patients one year after completing adjuvant endocrine therapy with letrozole and/or tamoxifen in the BIG 1-98 trial. Breast Cancer Res Treat 126:221-226.
<https://doi.org/10.1007/s10549-010-1235-y>
19. Schilder CM, Seynaeve C, Beex LV, Boogerd W, Linn SC, Gundy CM, Huizenga HM, Nortier JW, van de Velde CJ, van Dam FS, Schagen SB (2010) Effects of tamoxifen and exemestane on cognitive functioning of postmenopausal patients with breast cancer: results from the neuropsychological side study of the tamoxifen and exemestane adjuvant multinational trial. J Clin Oncol 28:1294-1300. <https://doi.org/10.1200/JCO.2008.21.3553>
20. Underwood EA, Rochon PA, Moineddin R, Lee PE, Wu W, Pritchard KI, Tierney MC (2018) Cognitive sequelae of endocrine therapy in women treated for breast cancer: a meta-analysis. Breast Cancer Res Treat 168:299-310.
<https://doi.org/10.1007/s10549-017-4627-4>
21. Van Dyk K, Crespi CM, Bower JE, Castellon SA, Petersen L, Ganz PA (2019) The cognitive effects of endocrine therapy in survivors of breast cancer: a prospective longitudinal study up to 6 years after treatment. Cancer 125:681-689.
<https://doi.org/10.1002/cncr.31858>

Brain Changes and Breast Cancer Antiestrogen Hormonal Therapy 25

22. Wagner LI, Gray RJ, Sparano JA, Whelan TJ, Garcia SF, Yanez B, Tevaarwerk AJ, Carlos RC, Albain KS, Olson JA, Jr., Goetz MP, Pritchard KI, Hayes DF, Geyer CE, Dees EC, McCaskill-Stevens WJ, Minasian LM, Sledge GW, Jr., Cella D (2020) Patient-reported cognitive impairment among women with early breast cancer randomly assigned to endocrine therapy alone versus chemoendocrine therapy: results from TAILORx. *J Clin Oncol* 38:1875-1886.
<https://doi.org/10.1200/jco.19.01866>
23. Schilder CM, Seynaeve C, Linn SC, Boogerd W, Beex LV, Gundy CM, Nortier JW, van de Velde CJ, van Dam FS, Schagen SB (2012) Self-reported cognitive functioning in postmenopausal breast cancer patients before and during endocrine treatment: findings from the neuropsychological TEAM side-study. *Psychooncology* 21:479-487. <https://doi.org/10.1002/pon.1928>
24. Bluethmann SM, Alfano CM, Clapp JD, Luta G, Small BJ, Hurria A, Cohen HJ, Sugarman S, H BM, Isaacs C, Mandelblatt JS (2017) Cognitive function and discontinuation of adjuvant hormonal therapy in older breast cancer survivors: CALGB 369901 (Alliance). *Breast Cancer Res Treat* 165:677-686.
<https://doi.org/10.1007/s10549-017-4353-y>
25. Mandelblatt JS, Zhai W, Ahn J, Small BJ, Ahles TA, Carroll JE, Denduluri N, Dilawari A, Extermann M, Graham D, Hurria A, Isaacs C, Jacobsen PB, Jim HSL, Luta G, McDonald BC, Patel SK, Root JC, Saykin AJ, Tometich DB, Zhou X, Cohen HJ (2020) Symptom burden among older breast cancer survivors: The Thinking and Living with Cancer (TLC) study. *Cancer* 126:1183-1192.
<https://dx.doi.org/10.1002/cncr.32663>

Brain Changes and Breast Cancer Antiestrogen Hormonal Therapy 26

26. Andryszak P, Wilkosc M, Izdebski P, Zurawski B (2017) A systemic literature review of neuroimaging studies in women with breast cancer treated with adjuvant chemotherapy. *Contemp Oncol (Pozn)* 21:6-15.
<https://dx.doi.org/10.5114/wo.2017.66652>
27. Feng Y, Zhang XD, Zheng G, Zhang LJ (2019) Chemotherapy-induced brain changes in breast cancer survivors: evaluation with multimodality magnetic resonance imaging. *Brain Imaging Behav* 13:1799-1814.
<https://dx.doi.org/10.1007/s11682-019-00074-y>
28. Li M, Caeyenberghs K (2018) Longitudinal assessment of chemotherapy-induced changes in brain and cognitive functioning: A systematic review. *Neurosci Biobehav Rev* 92:304-317. <https://dx.doi.org/10.1016/j.neubiorev.2018.05.019>
29. McDonald BC (2021) Structural neuroimaging findings related to adult non-CNS cancer and treatment: review, integration, and implications for treatment of cognitive dysfunction. *Neurother* 18:792-810. <https://doi.org/10.1007/s13311-021-01096-5>
30. Sousa H, Almeida S, Bessa J, Pereira MG (2020) The developmental trajectory of cancer-related cognitive impairment in breast cancer patients: a systematic review of longitudinal neuroimaging studies. *Neuropsychol Rev* 30:287-309.
<https://dx.doi.org/10.1007/s11065-020-09441-9>
31. Eberling JL, Wu C, Tong-Turnbeaugh R, Jagust WJ (2004) Estrogen- and tamoxifen-associated effects on brain structure and function. *Neuroimage* 21:364-371. <https://doi.org/10.1016/j.neuroimage.2003.08.037>

Brain Changes and Breast Cancer Antiestrogen Hormonal Therapy 27

32. Chen X, He X, Tao L, Li J, Wu J, Zhu C, Yu F, Zhang L, Zhang J, Qiu B, Yu Y, Wang K (2017) The working memory and dorsolateral prefrontal-hippocampal functional connectivity changes in long-term survival breast cancer patients treated with tamoxifen. *Int J Neuropsychopharmacol* 20:374-382.
<https://dx.doi.org/10.1093/ijnp/pyx008>
33. Hurria A, Patel SK, Mortimer J, Luu T, Somlo G, Katheria V, Ramani R, Hansen K, Feng T, Chuang C, Geist CL, Silverman DH (2014) The effect of aromatase inhibition on the cognitive function of older patients with breast cancer. *Clin Breast Cancer* 14:132-140. <https://doi.org/10.1016/j.clbc.2013.10.010>
34. Mandelblatt JS, Stern RA, Luta G, McGuckin M, Clapp JD, Hurria A, Jacobsen PB, Faul LA, Isaacs C, Denduluri N, Gavett B, Traina TA, Johnson P, Silliman RA, Turner RS, Howard D, Van Meter JW, Saykin A, Ahles T (2014) Cognitive impairment in older patients with breast cancer before systemic therapy: is there an interaction between cancer and comorbidity? *J Clin Oncol* 32:1909-1918.
<https://dx.doi.org/10.1200/JCO.2013.54.2050>
35. Mandelblatt JS, Small BJ, Luta G, Hurria A, Jim H, McDonald BC, Graham D, Zhou X, Clapp J, Zhai W, Breen E, Carroll JE, Denduluri N, Dilawari A, Extermann M, Isaacs C, Jacobsen PB, Kobayashi LC, Holohan Nudelman K, Root J, Stern RA, Tometich D, Turner R, VanMeter JW, Saykin AJ, Ahles T (2018) Cancer-related cognitive outcomes among older breast cancer survivors in the Thinking and Living with Cancer study. *J Clin Oncol* 36:3211-3222.
<https://dx.doi.org/10.1200/JCO.18.00140>

Brain Changes and Breast Cancer Antiestrogen Hormonal Therapy 28

36. Benton AL (1994) Neuropsychological assessment. *Annu Rev Psychol* 45:1-23.
<https://doi.org/10.1146/annurev.ps.45.020194.000245>
37. Reitan RM, Wolfson D (1993) The Halstead-Reitan Neuropsychological Test Battery: Theory and Clinical Interpretation, Second Edition. Neuropsychology Press, Tucson, AZ
38. Stern RA, White T (2003) Neuropsychological Assessment Battery (NAB). Psychological Assessment Resources, Inc., Lutz, FL
39. Wechsler D (1997) Wechsler Adult Intelligence Scale-Third Edition (WAIS-III). The Psychological Corporation, San Antonio, TX
40. Wechsler D (1997) Wechsler Memory Scale-Third Edition (WMS-III). The Psychological Corporation, San Antonio, TX
41. Wagner L, Sweet J, Butt Z, Lai J-S, Cella D (2009) Measuring patient self-reported cognitive function: development of the functional assessment of cancer therapy–cognitive function instrument. *J Support Oncol* 7:W32-W39.
42. Wilkinson GS, Robertson GJ (2006) WRAT4 Wide Range Achievement Test Professional Manual. Psychological Assessment Resources, Inc., Lutz, FL
43. Radloff LS (1977) The CES-D Scale: A self-report depression scale for research in the general population. *Appl Psychol Meas* 1:385-401.
<https://doi.org/10.1177/014662167700100306>
44. Spielberger CD (1983) Manual for the State-Trait Anxiety Inventory (STAI: Form Y). Consulting Psychologists Press, Inc., Palo Alto, CA
45. Conroy SK, McDonald BC, Ahles TA, West JD, Saykin AJ (2013) Chemotherapy-induced amenorrhea: a prospective study of brain activation changes and

Brain Changes and Breast Cancer Antiestrogen Hormonal Therapy 29

neurocognitive correlates. *Brain Imaging Behav* 7:491-500.

<http://dx.doi.org/10.1007/s11682-013-9240-5>

46. Ferguson RJ, McDonald BC, Saykin AJ, Ahles TA (2007) Brain structure and function differences in monozygotic twins: possible effects of breast cancer chemotherapy. *J Clin Oncol* 25:3866-3870.
<https://doi.org/10.1200/JCO.2007.10.8639>
47. McDonald BC, Conroy SK, Ahles TA, West JD, Saykin AJ (2012) Alterations in brain activation during working memory processing associated with breast cancer and treatment: a prospective functional magnetic resonance imaging study. *J Clin Oncol* 30:2500-2508. <http://dx.doi.org/10.1200/JCO.2011.38.5674>
48. Conroy SK, McDonald BC, Smith DJ, Moser LR, West JD, Kamendulis LM, Klaunig JE, Champion VL, Unverzagt FW, Saykin AJ (2013) Alterations in brain structure and function in breast cancer survivors: effect of post-chemotherapy interval and relation to oxidative DNA damage. *Breast Cancer Res Treat* 137:493-502. <http://dx.doi.org/10.1007/s10549-012-2385-x>
49. Dumas JA, Saykin AJ, McDonald BC, McAllister TW, Hynes ML, Newhouse PA (2008) Nicotinic versus muscarinic blockade alters verbal working memory-related brain activity in older women. *Am J Geriatr Psychiatry* 16:272-282.
<http://dx.doi.org/10.1097/JGP.0b013e3181602a2b>
50. Dumas JA, Kutz AM, McDonald BC, Naylor MR, Pfaff AC, Saykin AJ, Newhouse PA (2013) Increased working memory-related brain activity in middle-aged women with cognitive complaints. *Neurobiol Aging* 34:1145-1147.
<http://dx.doi.org/10.1016/j.neurobiolaging.2012.08.013>

Brain Changes and Breast Cancer Antiestrogen Hormonal Therapy 30

51. Flashman LA, McDonald BC, Ford JC, Kenny RM, Andrews KD, Saykin AJ, McAllister TW (2021) Differential effects of pergolide and bromocriptine on working memory performance and brain activation after mild traumatic brain injury. *J Neurotrauma* 38:225-234. <https://doi.org/10.1089/neu.2020.7087>
52. McAllister TW, Saykin AJ, Flashman LA, Sparling MB, Johnson SC, Guerin SJ, Mamourian AC, Weaver JB, Yanofsky N (1999) Brain activation during working memory 1 month after mild traumatic brain injury: a functional MRI study. *Neurology* 53:1300-1308. <https://doi.org/10.1212/wnl.53.6.1300>
53. McAllister TW, Sparling MB, Flashman LA, Guerin SJ, Mamourian AC, Saykin AJ (2001) Differential working memory load effects after mild traumatic brain injury. *Neuroimage* 14:1004-1012. <https://doi.org/10.1006/nimg.2001.0899>
54. McAllister TW, Flashman LA, McDonald BC, Saykin AJ (2006) Mechanisms of working memory dysfunction after mild and moderate TBI: evidence from functional MRI and neurogenetics. *J Neurotrauma* 23:1450-1467. <https://doi.org/10.1089/neu.2006.23.1450>
55. McAllister TW, Flashman LA, McDonald BC, Ferrell RB, Tosteson TD, Yanofsky NN, Grove MR, Saykin AJ (2011) Dopaminergic challenge with bromocriptine one month after mild traumatic brain injury: altered working memory and BOLD response. *J Neuropsychiatry Clin Neurosci* 23:277-286. <http://dx.doi.org/10.1176/appi.neuropsych.23.3.277>
56. McAllister TW, McDonald BC, Flashman LA, Ferrell RB, Tosteson TD, Yanofsky NN, Grove MR, Saykin AJ (2011) Alpha-2 adrenergic challenge with guanfacine one month after mild traumatic brain injury: altered working memory and BOLD

Brain Changes and Breast Cancer Antiestrogen Hormonal Therapy 31

- response. *Int J Psychophysiol* 82:107-114.
<http://dx.doi.org/10.1016/j.ijpsycho.2011.06.022>
57. Saykin AJ, Wishart HA, Rabin LA, Flashman LA, McHugh TL, Mamourian AC, Santulli RB (2004) Cholinergic enhancement of frontal lobe activity in mild cognitive impairment. *Brain* 127:1574-1583. <https://doi.org/10.1093/brain/awh177>
58. Westfall DR, West JD, Bailey JN, Arnold TW, Kersey PA, Saykin AJ, McDonald BC (2015) Increased brain activation during working memory processing after pediatric mild traumatic brain injury (mTBI). *J Pediatr Rehabil Med* 8:297-308.
<https://doi.org/10.3233/PRM-150348>
59. Wishart HA, Saykin AJ, McDonald BC, Mamourian AC, Flashman LA, Schuschu KR, Ryan KA, Fadul CE, Kasper LH (2004) Brain activation patterns associated with working memory in relapsing-remitting MS. *Neurology* 62:234-238.
<https://doi.org/10.1212/01.wnl.0000103238.91536.5f>
60. Wishart HA, Saykin AJ, Rabin LA, Santulli RB, Flashman LA, Guerin SJ, Mamourian AC, Belloni DR, Rhodes CH, McAllister TW (2006) Increased brain activation during working memory in cognitively intact adults with the APOE epsilon4 allele. *Am J Psychiatry* 163:1603-1610.
<https://doi.org/10.1176/appi.ajp.163.9.1603>
61. Deprez S, Kesler SR, Saykin AJ, Silverman DHS, de Ruiter MB, McDonald BC (2018) International Cognition and Cancer Task Force recommendations for neuroimaging methods in the study of cognitive impairment in non-CNS cancer patients. *J Natl Cancer Inst* 110:223-231. <https://doi.org/10.1093/jnci/djx285>

Brain Changes and Breast Cancer Antiestrogen Hormonal Therapy 32

62. Reuter M, Schmansky NJ, Rosas HD, Fischl B (2012) Within-subject template estimation for unbiased longitudinal image analysis. *Neuroimage* 61:1402-1418. <https://doi.org/10.1016/j.neuroimage.2012.02.084>
63. Karatzoglou A, Smola A, Hornik K, Zeileis A (2004) kernlab - an S4 package for kernel methods in R. *J Stat Software* 11 <https://doi.org/10.18637/jss.v011.i09>
64. Cole JH, Leech R, Sharp DJ (2015) Prediction of brain age suggests accelerated atrophy after traumatic brain injury. *Ann Neurol* 77:571-581. <https://doi.org/10.1002/ana.24367>
65. Cole JH, Poudel RPK, Tsagkrasoulis D, Caan MWA, Steves C, Spector TD, Montana G (2017) Predicting brain age with deep learning from raw imaging data results in a reliable and heritable biomarker. *Neuroimage* 163:115-124. <https://doi.org/10.1016/j.neuroimage.2017.07.059>
66. Cole JH, Ritchie SJ, Bastin ME, Valdés Hernández MC, Muñoz Maniega S, Royle N, Corley J, Pattie A, Harris SE, Zhang Q, Wray NR, Redmond P, Marioni RE, Starr JM, Cox SR, Wardlaw JM, Sharp DJ, Deary IJ (2018) Brain age predicts mortality. *Mol Psychiatry* 23:1385-1392. <https://doi.org/10.1038/mp.2017.62>
67. Kesler SR, Adams M, Packer M, Rao V, Henneghan AM, Blayney DW, Palesh O (2017) Disrupted brain network functional dynamics and hyper-correlation of structural and functional connectome topology in patients with breast cancer prior to treatment. *Brain Behav* 7:e00643. <https://dx.doi.org/10.1002/brb3.643>
68. McDonald BC, Conroy SK, Smith DJ, West JD, Saykin AJ (2013) Frontal gray matter reduction after breast cancer chemotherapy and association with

Brain Changes and Breast Cancer Antiestrogen Hormonal Therapy 33

- executive symptoms: a replication and extension study. *Brain Behav Immun* 30 Suppl:S117-125. <http://dx.doi.org/10.1016/j.bbi.2012.05.007>
69. Menning S, de Ruiter MB, Veltman DJ, Koppelmans V, Kirschbaum C, Boogerd W, Reneman L, Schagen SB (2015) Multimodal MRI and cognitive function in patients with breast cancer prior to adjuvant treatment--the role of fatigue. *NeuroImage. Clinical* 7:547-554. <https://doi.org/10.1016/j.nicl.2015.02.005>
70. Scherling C, Collins B, MacKenzie J, Lepage C, Bielajew C, Smith A (2012) Structural brain differences in breast cancer patients compared to matched controls prior to chemotherapy. *International Journal of Biology* 4:3-25. <https://doi.org/10.5539/ijb.v4n2p3>
71. Lewinsohn PM, Seeley JR, Roberts RE, Allen NB (1997) Center for Epidemiological Studies-Depression Scale (CES-D) as a screening instrument for depression among community-residing older adults. *Psychol Aging* 12:277-287. <https://doi.org/10.1037//0882-7974.12.2.277>
72. Kvaal K, Ulstein I, Nordhus IH, Engedal K (2005) The Spielberger State-Trait Anxiety Inventory (STAI): the state scale in detecting mental disorders in geriatric patients. *Int J Geriatr Psychiatry* 20:629-634. <https://doi.org/10.1002/gps.1330>
73. Sato C, Sekiguchi A, Kawai M, Kotozaki Y, Nouchi R, Tada H, Takeuchi H, Ishida T, Taki Y, Kawashima R, Ohuchi N (2015) Postoperative structural brain changes and cognitive dysfunction in patients with breast cancer. *PLoS ONE* 10:e0140655. <https://doi.org/10.1371/journal.pone.0140655>
74. Cimprich B, Reuter-Lorenz P, Nelson J, Clark PM, Therrien B, Normolle D, Berman MG, Hayes DF, Noll DC, Peltier S, Welsh RC (2010) Prechemotherapy

Brain Changes and Breast Cancer Antiestrogen Hormonal Therapy 34

- alterations in brain function in women with breast cancer. *J Clin Exp Neuropsychol* 32:324-331. <https://doi.org/10.1080/13803390903032537>
75. Scherling C, Collins B, Mackenzie J, Bielajew C, Smith A (2011) Pre-chemotherapy differences in visuospatial working memory in breast cancer patients compared to controls: an fMRI study. *Front Hum Neurosci* 5:122. <https://doi.org/10.3389/fnhum.2011.00122>
76. Rahman A, Jackson H, Hristov H, Isaacson RS, Saif N, Shetty T, Etingin O, Henchcliffe C, Brinton RD, Mosconi L (2019) Sex and gender driven modifiers of Alzheimer's: the role for estrogenic control across age, race, medical, and lifestyle risks. *Front Aging Neurosci* 11:315. <https://doi.org/10.3389/fnagi.2019.00315>
77. Cui J, Shen Y, Li R (2013) Estrogen synthesis and signaling pathways during aging: from periphery to brain. *Trends in molecular medicine* 19:197-209. <https://doi.org/10.1016/j.molmed.2012.12.007>
78. Seitz J, Kubicki M, Jacobs EG, Cherkerzian S, Weiss BK, Papadimitriou G, Mouradian P, Buka S, Goldstein JM, Makris N (2019) Impact of sex and reproductive status on memory circuitry structure and function in early midlife using structural covariance analysis. *Hum Brain Mapp* 40:1221-1233. <https://doi.org/10.1002/hbm.24441>
79. Mosconi L, Rahman A, Diaz I, Wu X, Scheyer O, Hristov HW, Vallabhajosula S, Isaacson RS, de Leon MJ, Brinton RD (2018) Increased Alzheimer's risk during the menopause transition: A 3-year longitudinal brain imaging study. *PLoS ONE* 13:e0207885. <https://doi.org/10.1371/journal.pone.0207885>

Brain Changes and Breast Cancer Antiestrogen Hormonal Therapy 35

80. Zeydan B, Tosakulwong N, Schwarz CG, Senjem ML, Gunter JL, Reid RI, Gazzuola Rocca L, Lesnick TG, Smith CY, Bailey KR, Lowe VJ, Roberts RO, Jack CR, Jr., Petersen RC, Miller VM, Mielke MM, Rocca WA, Kantarci K (2019) Association of bilateral salpingo-oophorectomy before menopause onset with medial temporal lobe neurodegeneration. *JAMA Neurol* 76:95-100.
<https://doi.org/10.1001/jamaneurol.2018.3057>
81. Ferretti MT, Iulita MF, Cavedo E, Chiesa PA, Schumacher Dimech A, Santuccione Chadha A, Baracchi F, Girouard H, Misoch S, Giacobini E, Depypere H, Hampel H (2018) Sex differences in Alzheimer disease - the gateway to precision medicine. *Nat Rev Neurol* 14:457-469.
<https://doi.org/10.1038/s41582-018-0032-9>
82. Mauvais-Jarvis F, Bairey Merz N, Barnes PJ, Brinton RD, Carrero JJ, DeMeo DL, De Vries GJ, Epperson CN, Govindan R, Klein SL, Lonardo A, Maki PM, McCullough LD, Regitz-Zagrosek V, Regensteiner JG, Rubin JB, Sandberg K, Suzuki A (2020) Sex and gender: modifiers of health, disease, and medicine. *Lancet* 396:565-582. [https://doi.org/10.1016/s0140-6736\(20\)31561-0](https://doi.org/10.1016/s0140-6736(20)31561-0)
83. Jacobs EG, Weiss B, Makris N, Whitfield-Gabrieli S, Buka SL, Klibanski A, Goldstein JM (2016) Reorganization of functional networks in verbal working memory circuitry in early midlife: the impact of sex and menopausal status. *Cereb Cortex* 27:2857-2870. <https://doi.org/10.1093/cercor/bhw127>
84. de Lange A-MG, Barth C, Kaufmann T, Maximov II, van der Meer D, Agartz I, Westlye LT (2020) Women's brain aging: effects of sex-hormone exposure,

Brain Changes and Breast Cancer Antiestrogen Hormonal Therapy 36

pregnancies, and genetic risk for Alzheimer's disease. Hum Brain Mapp 41:5141-5150. <https://doi.org/10.1002/hbm.25180>

85. de Lange A-M, Barth C, Kaufmann T, Maximov II, van der Meer D, Agartz I, Westlye LT (2019) Cumulative estrogen exposure, APOE genotype, and women's brain aging - a population-based neuroimaging study.826123. 10.1101/826123 %J bioRxiv

Brain Changes and Breast Cancer Antiestrogen Hormonal Therapy 37

Statements & Declarations

Funding: This research and the authors' effort were supported by the National Institutes of Health, including National Cancer Institute grants R35 CA197289, P30 CA008748, P30 CA082709, R01 CA129769, R01 CA244673, R01 CA172119, and K08 CA241337, and National Institute on Aging grants P30 AG010133, P30 AG072976, R01 AG068193, and R56 AG068086.

Competing Interests: The authors have no relevant financial or non-financial interests to disclose.

Author Contributions: All authors contributed to the study conception and design.

Material preparation, data collection, and analysis were performed by Brenna McDonald, Rachael Deardorff, Jessica Bailey, and Wanting Zhai. The first draft of the manuscript was written by Brenna McDonald, Kathleen Van Dyk, and Jeanne Mandelblatt, and all authors commented on previous versions of the manuscript. All authors read and approved the final manuscript.

Data Availability: The datasets generated and/or analyzed for the current study are not publicly available due to the ongoing nature of the study, but are available from the corresponding author on reasonable request.

Brain Changes and Breast Cancer Antiestrogen Hormonal Therapy 38

Ethics Approval: This study was performed in line with the principles of the Declaration of Helsinki. Written informed consent was obtained from all participants under a protocol approved by the Indiana University Institutional Review Board (#1602851718, first approved July 27, 2016).

Brain Changes and Breast Cancer Antiestrogen Hormonal Therapy 39

Figure Captions

Fig. 1 Voxel-based morphometry (VBM): Lower gray matter volume in older women with breast cancer treated with hormonal therapy relative to non-cancer controls at A) pre-treatment baseline and B) 12-month follow-up (Overall FWE-corrected $p < 0.05$, cluster-level $p_{\text{uncorrected}} < 0.05$)

Fig. 2 Voxel-based morphometry (VBM): Reduced gray matter volume from baseline to 12-month follow-up in A) Older women with breast cancer treated with hormonal therapy and B) Non-cancer controls (Overall FWE-corrected $p < 0.05$, cluster-level $p_{\text{uncorrected}} < 0.05$)

Fig. 3 Greater working memory-related functional MRI activation (2-Back > 0-Back) in older women with breast cancer treated with hormonal therapy relative to non-cancer controls at 12-month follow-up (Overall $p < 0.001$, cluster-level $p_{\text{uncorrected}} < 0.05$)

Fig. 4 Increased working memory-related functional MRI activation (2-Back > 0-Back) from baseline to 12-month follow-up in older women with breast cancer treated with hormonal therapy (Overall $p < 0.001$, cluster-level $p_{\text{uncorrected}} < 0.05$)

Brain Changes and Breast Cancer Antiestrogen Hormonal Therapy 40

Table 1. Sample Characteristics

	Women with Breast Cancer Treated with Hormonal Therapy (n=29)	Non-Cancer Controls (n=29)	p
Age at baseline (years)	67.7 (4.8)	66.8 (3.9)	0.44
Education (years)	15.8 (2.0)	15.6 (1.8)	0.63
WRAT-4 Word Reading standard score at baseline	111.0 (17.0)	108.4 (13.8)	0.54
CES-D total score at baseline ^a (0-60; Higher=More depressive symptoms)	9.9 (8.0)	3.8 (5.7)	<0.01
STAI-State score at baseline ^b (20-80; Higher=More anxiety)	30.9 (9.3)	26.8 (6.7)	0.06
Race (% White, Non-Hispanic)	100.0	96.6	0.31
Age at menopause (years)	48.2 (6.0)	50.0 (5.4)	0.24
Ever taken hormone replacement therapy (%)	58.6	51.7	0.60
Interval between baseline and 12-month follow-up (days)	375.9 (24.3)	378.2 (26.5)	0.74
AJCC cancer stage (n, %)			
0 (DCIS)	8, 27.6		
I	17, 58.6		
II	4, 13.8		
Hormonal Therapy initially taken ^c			
Anastrozole	20		
Tamoxifen	8		
Letrozole	1		
Cumulative days taken Hormonal Therapy at follow-up ^d	306.7 (75.9) range 111-399		

Values are mean (SD) unless otherwise indicated

^aA score of ≥ 16 suggests clinically significant symptoms⁶⁷

^bA score of ≥ 55 suggests clinically significant symptoms⁶⁸

^c3 women changed from anastrozole to letrozole, 1 changed from anastrozole to exemestane, and 1 changed from anastrozole to tamoxifen, all due to physical side effects

^d6 women were off hormonal therapy for periods of time ranging from 23-122 days between baseline and 12-month follow-up, including 3 who discontinued treatment 23-36 days prior to 12-month follow-up

AJCC=American Joint Committee on Cancer; CES-D=Center for Epidemiologic Studies Depression Scale; DCIS=Ductal Carcinoma In Situ; STAI-State=State-Trait Anxiety Inventory State Scale; WRAT=Wide Range

Achievement Test

$p < 0.1$ **$p < 0.01$**

Brain Changes and Breast Cancer Antiestrogen Hormonal Therapy 41

Table 2. Self-Reported and Objective Cognition, FreeSurfer, and Brain Age Results

	Mean (SD)				p Values				
					Cross-Sectional Breast Cancer vs. Non-Cancer Controls		Within-Group Change (12-Month Follow-Up Minus Baseline)		Between-Group Difference in Change over Time
	Breast Cancer		Non-Cancer Controls		Baseline	12-Month Follow-Up	Breast Cancer	Non-Cancer Controls	Breast Cancer vs. Non-Cancer Controls
<i>Self-Reported and Objective Cognition</i>									
FACT-Cog PCI Score (0-72; Higher=Better Functioning)	58.03 (10.94)	56.92 (11.31)	59.62 (9.74)	60.87 (9.62)	0.56	0.16	0.43	0.16	0.16
Attention, Processing Speed, and Executive Functioning Domain z score	0.07 (0.53)	0.07 (0.50)	0.19 (0.59)	0.34 (0.61)	0.41	0.07	0.99	0.03	0.09
Learning and Memory Domain z score	0.15 (0.77)	0.20 (0.95)	0.13 (0.72)	0.27 (0.90)	0.95	0.78	0.65	0.35	0.63
2-Back Performance Accuracy	61.82 (27.92)	60.84 (24.92)	72.27 (19.09)	65.17 (29.32)	0.10	0.55	0.97	0.13	0.31
2-Back Task Reaction Time	0.93 (0.25)	0.94 (0.17)	0.92 (0.23)	0.90 (0.24)	0.84	0.45	0.42	0.63	0.36
<i>FreeSurfer (FS) and Brain Age</i>									
FS Prefrontal Cortex Volume	127704.34 (9655.10)	126399.52 (9094.32)	132664.28 (8933.55)	131714.90 (8859.55)	0.02	0.009	0.46	0.61	0.41
FS Temporal Cortex Volume	99452.34 (8143.60)	98554.34 (7816.24)	104277.21 (8812.70)	103433.45 (8973.40)	0.008	0.008	0.58	0.60	0.84
FS Parietal Cortex Volume	92385.79 (8520.61)	91606.90 (8491.53)	94738.45 (8354.18)	94183.90 (8313.07)	0.24	0.19	0.64	0.72	0.45
FS Basal Ganglia Volume	18923.73 (1891.33)	18826.83 (1822.76)	19902.33 (1837.02)	19784.19 (1870.97)	0.05	0.06	0.84	0.80	0.76
FS Thalamus Volume	12552.45 (1193.89)	12395.37 (1152.71)	12692.10 (1197.39)	12606.98 (1252.21)	0.74	0.54	0.55	0.71	0.19
FS Limbic Cortex Volume	11884.23 (1120.03)	11761.01 (1131.91)	11918.12 (979.69)	11828.49 (992.80)	0.96	0.86	0.65	0.73	0.40
FS Insula Cortex Volume	13237.31 (996.89)	13095.76 (1007.07)	13703.72 (1072.25)	13593.07 (1096.37)	0.06	0.045	0.50	0.63	0.65
FS Prefrontal Cortex Thickness	55.77 (1.53)	55.50 (1.57)	56.16 (1.18)	55.99 (1.13)	0.28	0.17	0.02	0.16	0.50
FS Temporal Cortex Thickness	52.47 (1.56)	52.32 (1.75)	52.72 (1.42)	52.51 (1.41)	0.54	0.64	0.24	0.03	0.75
FS Parietal Cortex Thickness	24.03 (0.79)	23.91 (0.84)	24.21 (0.63)	24.09 (0.62)	0.34	0.35	0.02	0.004	0.98
FS Insula Cortex Thickness	5.81 (0.21)	5.77 (0.23)	5.88 (0.19)	5.87 (0.19)	0.18	0.07	0.04	0.74	0.17
Estimated Brain Age (years)	65.61 (7.19)	66.71 (7.73)	60.87 (9.11)	61.91 (9.10)	0.03	0.03	0.004	0.004	0.90

FACT-Cog=Functional Assessment of Cancer Therapy-Cognitive Function Scale; FS=FreeSurfer; PCI=Perceived Cognitive Impairments $p < 0.1$ $p < 0.01$

medRxiv preprint doi: <https://doi.org/10.1101/2022.02.25.22271510>; this version posted February 28, 2022. The copyright holder for this preprint (which was not certified by peer review) is the author/funder, who has granted medRxiv a license to display the preprint in perpetuity. All rights reserved. No reuse allowed without permission.

Brain Changes and Breast Cancer Antiestrogen Hormonal Therapy 42

Table 3. Voxel-Based Morphometry (VBM) Results (Overall FWE-corrected $p < 0.05$, cluster-level $p_{\text{uncorrected}} < 0.05$)

MNI Coordinates	k	Cluster-Level $p_{\text{uncorrected}}$	Z	Region Description
Pre-Treatment Baseline: Non-Cancer Controls > Women with Breast Cancer Treated with Hormonal Therapy (Figure 1A)				
24 2 52	160	0.008	6.74	Right premotor/supplementary motor cortex (BA6)
12-Month Follow-Up: Non-Cancer Controls > Women with Breast Cancer Treated with Hormonal Therapy (Figure 1B)				
24 2 52	164	0.008	6.72	Right premotor/supplementary motor cortex (BA6)
Pre-Treatment Baseline > 12-Month Follow-Up: Women with Breast Cancer Treated with Hormonal Therapy (Figure 2A)				
-51 14 -10	138	0.001	5.80	Left temporal pole (BA38)
44 20 -12	141	0.001	5.29	Right pars orbitalis (BA47)
-52 12 30	47	0.033	5.24	Left inferior frontal gyrus (BA44)
0 51 15	55	0.023	5.02	Right anterior prefrontal cortex (BA10)
-45 -40 51	39	0.049	4.92	Left supramarginal gyrus (BA40)
Baseline > 12-Month Follow-Up: Non-Cancer Controls (Figure 2B)				
64 -45 -18	43	0.040	5.14	Right fusiform gyrus (BA37)

BA=Brodmann Area; FWE=Family-Wise Error; k=cluster extent size (number of voxels); MNI=Montreal Neurological Institute

Brain Changes and Breast Cancer Antiestrogen Hormonal Therapy 43

Table 4. Working Memory-Related Functional MRI (fMRI) Results (overall $p < 0.001$, cluster-level $p_{\text{uncorrected}} < 0.05$)

MNI Coordinates	k	Cluster-Level $p_{\text{uncorrected}}$	Z	Region Description
12-Month Follow-Up: Women with Breast Cancer Treated with Hormonal Therapy > Non-Cancer Controls (Figure 3)				
22 42 32	107	0.025	4.33	Right dorsolateral prefrontal cortex (BA9)
6 -42 48	106	0.025	4.20	Right dorsal posterior cingulate cortex (BA31)
44 30 18	80	0.048	3.55	Right dorsolateral prefrontal cortex (BA9)
12-Month Follow-Up > Pre-Treatment Baseline: Women with Breast Cancer Treated with Hormonal Therapy (Figure 4)				
-40 0 44	118	0.015	4.77	Left premotor/supplementary motor cortex (BA6)
52 14 10	453	<0.001	4.62	Right inferior frontal gyrus (BA44)
-8 30 26	164	0.005	4.61	Left dorsal anterior cingulate cortex (BA32)
38 4 26	113	0.016	4.35	Right premotor/supplementary motor cortex (BA6)
-2 -36 36	92	0.028	4.05	Left ventral posterior cingulate cortex (BA23)
40 42 -2	93	0.027	3.93	Right pars orbitalis (BA47)
34 -76 18	78	0.040	3.79	Right visual association cortex (BA19)
-36 32 26	87	0.032	3.67	Left dorsolateral prefrontal cortex (BA9)

BA=Brodmann Area; k=cluster extent size (number of voxels); MNI=Montreal Neurological Institute

Figure 1

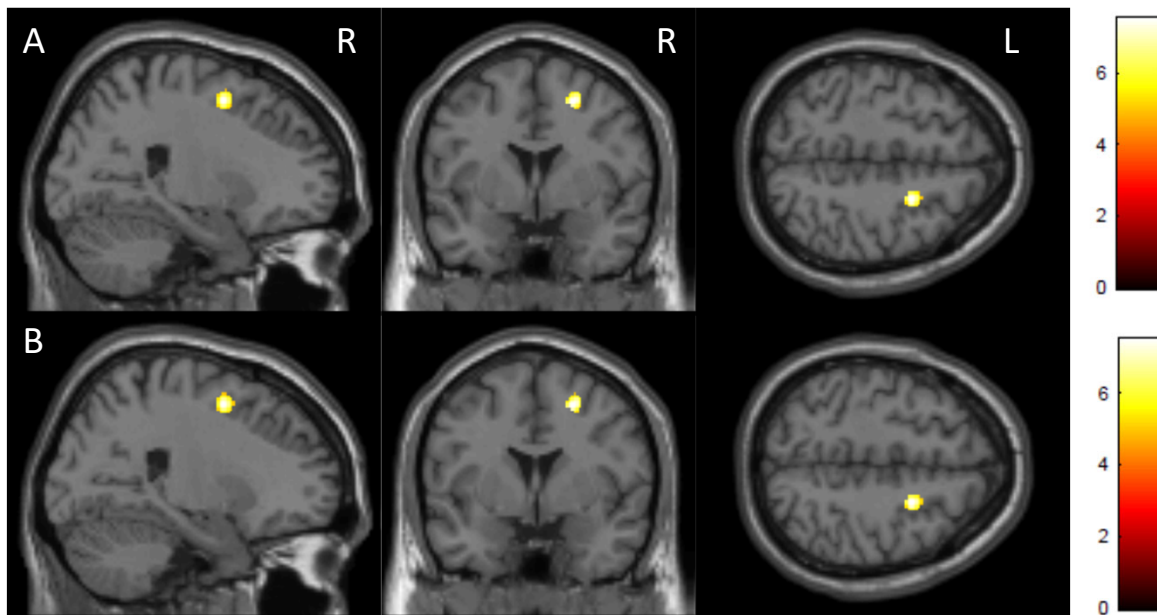


Figure 2

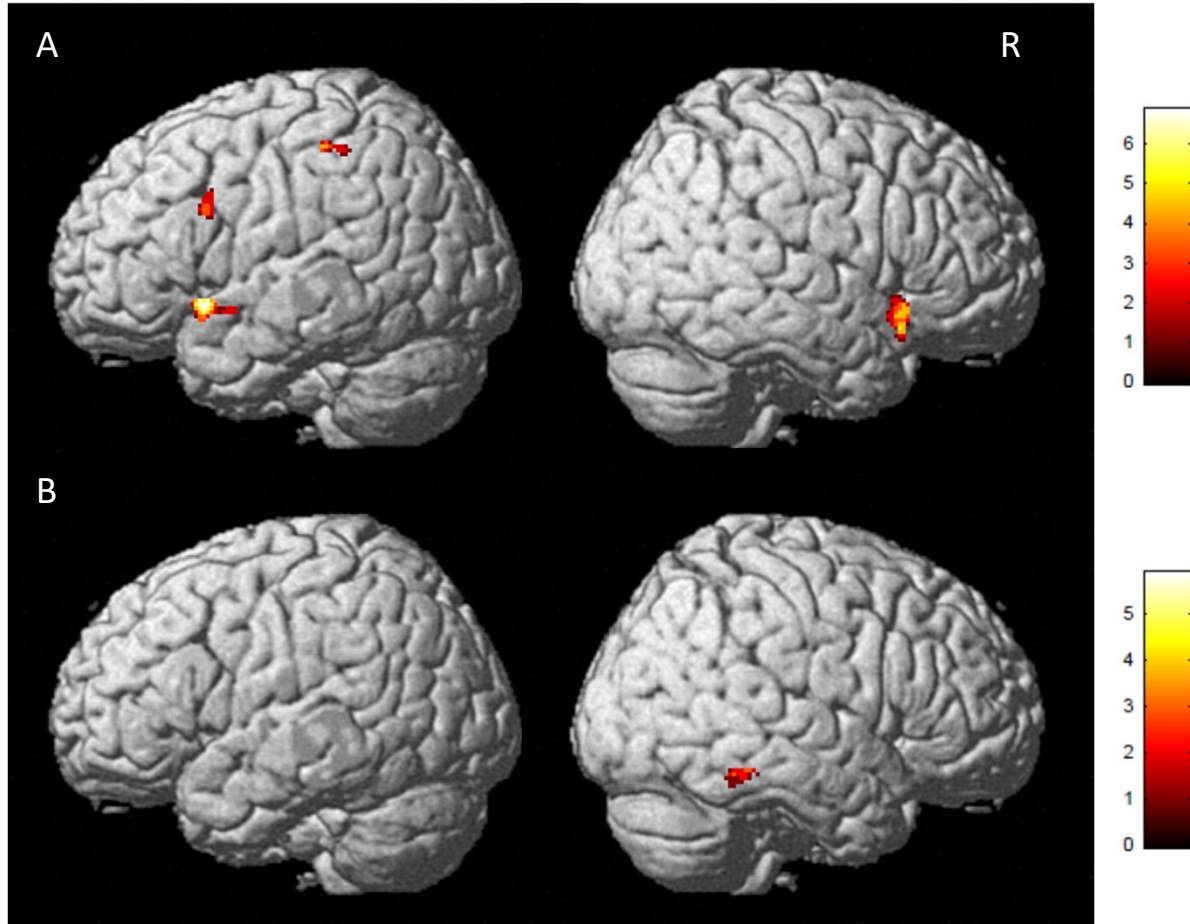


Figure 3

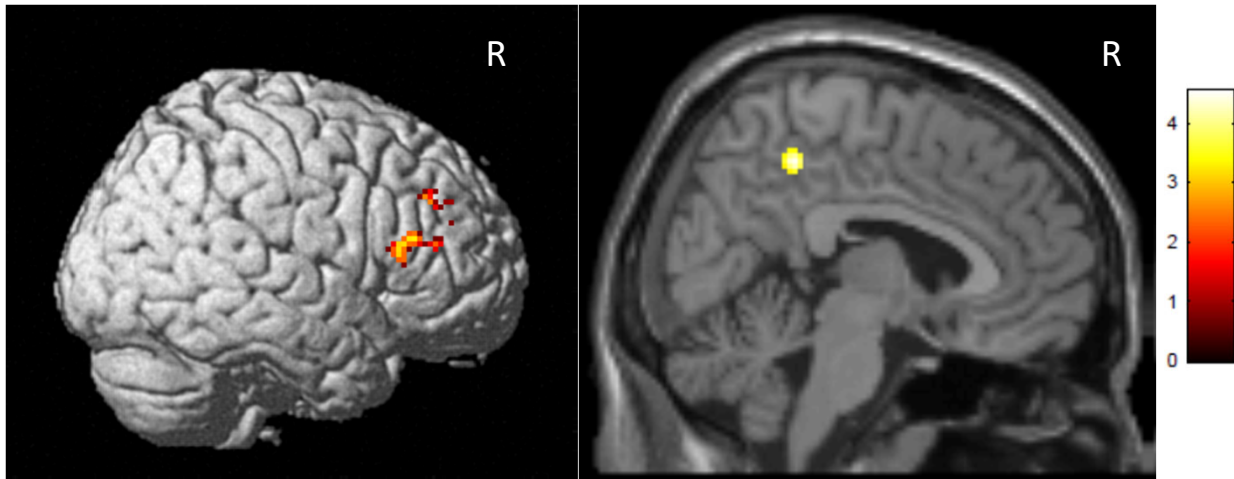
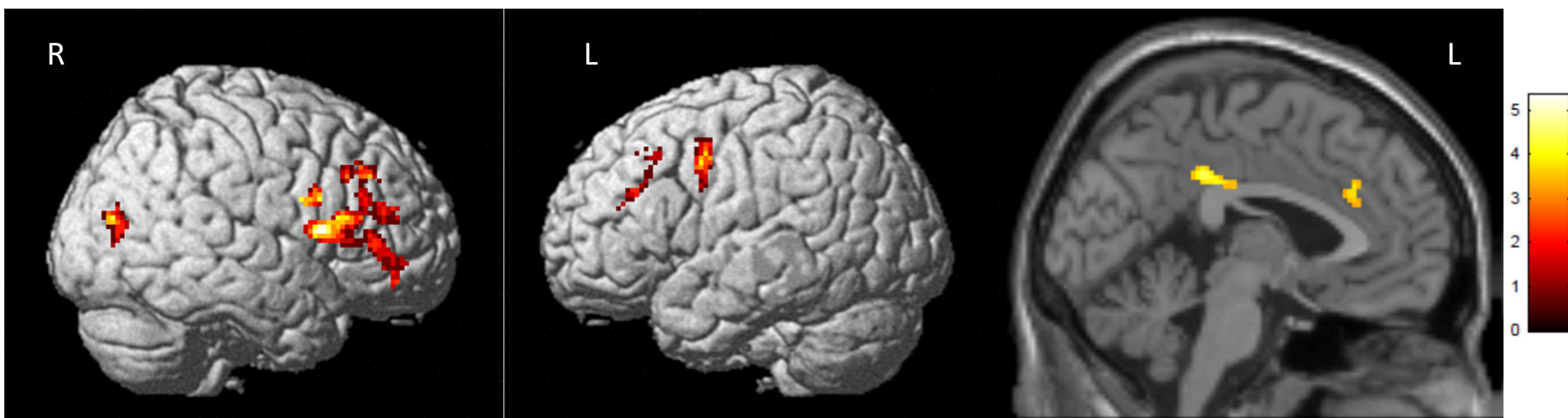


Figure 4



Online Resource 1 Supplementary Methodological Information

Scan Parameters

MPRAGE: repetition time (TR)=2300ms, echo time (TE)=2.95ms, flip angle (FA)=9°, field of view (FOV)=270x253mm, 256x240 matrix, 176 1.2mm-thick contiguous sagittal slices, voxel size 1.1x1.1x1.2mm, scan time 5:12

fMRI: TR=1200 ms, TE=29ms, FA=65°, FOV=220x220mm, 88x88 matrix, number of excitations (NEX)=1, multi-band=3, 54 interleaved 2.5mm-thick contiguous axial slices, voxel size 2.5x2.5x2.5mm, scan time 6:10

A 3D fluid-attenuated inversion recovery (FLAIR) sequence was also acquired, and reviewed along with the MPRAGE by a board-certified neuroradiologist to rule out incidental pathology. Image quality was assessed during scan acquisition and at multiple preprocessing steps (e.g., accuracy of skull stripping, alignment of individual images to templates).

Working Memory fMRI Task

During scanning, participants saw a string of consonant letters (except L, W, and Y) presented one every three seconds. Task conditions were 0-, 1-, and 2-back, in a blocked design. For each consonant, participants used a button press device to signify whether the current letter was a match (i.e., was the same as the designated target or the letter presented 1- or 2-back in the sequence) or a nonmatch. Each condition was presented in 27-second epochs preceded by three seconds of instruction (e.g., “the match is one back”). The three experimental conditions were each presented three

times in pseudorandom order for a total of nine task blocks. Participants rehearsed a practice version of the task before scanning to ensure that they understood the demands of the task. Stimuli were presented through an MRI-compatible projection system and programmed in Presentation, which recorded response accuracy and reaction times.

Voxel-Based Morphometry (VBM) Preprocessing

VBM was used to examine gray matter volume across the whole brain using the standard longitudinal pipeline in Computational Anatomy Toolbox for SPM12 (CAT12.6). T1-weighted follow-up scans were registered to the baseline scan for each participant. Scans were then registered to the Montreal Neurological Institute (MNI) T1-weighted template and segmented into gray matter, white matter, and cerebrospinal fluid compartments using the MNI T1-weighted template and corresponding tissue probability maps. Gray matter maps were then spatially normalized to MNI space, resampled to 1.5mm isotropic voxels, and smoothed using an isotropic Gaussian spatial filter (FWHM=8mm) to reduce residual inter-individual variability. The smoothed, normalized gray matter maps were subjected to statistical parametric mapping on a voxel-by-voxel basis using the general linear model as implemented in SPM12 using total intracranial volume (generated by CAT12.6) as a covariate. The SPM prior probability gray matter template was used to restrict the statistical comparisons to the gray matter compartment. Statistical models were generated using a flexible factorial design to examine within- and between-group longitudinal changes, including group-by-time interactions (factors: 1) subject, baseline and follow-up scans for each participant, 2)

group, two independent levels, breast cancer and control, 3) time, two non-independent levels, baseline and follow-up), and a full factorial design to examine between-group cross-sectional differences (factors: 1) group, two independent levels, breast cancer and control, 2) time, two non-independent levels, baseline and follow-up).

Task-Based fMRI Preprocessing

For each participant's echo-planar fMRI series the susceptibility-induced field was estimated and corrected using reverse phase-encoded imaging pairs with FSL 6.0.0 Topup [1]. Slice timing correction was performed with a slice order file using slicetimer in FSL. Corrected fMRI data were then processed with Multivariate Exploratory Linear Optimized Decomposition into Independent Components (MELODIC version 3.15) using the following parameters: high pass filter cutoff=100s, MCFLIRT motion correction, and spatial smoothing FWHM=6mm. Auto classification and removal of ICA components were completed with FMRIB's ICA-based Xnoiseifier (FIX) version 1.06 [2, 3] using an in-house generated independent training set of 23 protocol-specific, age-matched healthy controls. Filtered data were then coregistered and normalized to MNI 2x2x2mm³ standard space and statistical parametric mapping on a voxel-by-voxel basis was conducted by using a general linear model approach using motion parameters as regressors in SPM12. Contrast images comparing task conditions were created for each participant for second-level multi-subject/between-group analyses. The SPM prior probability gray matter template was used to restrict the statistical comparisons to the gray matter compartment. Statistical models were generated using a flexible factorial design to examine within- and between-group longitudinal changes, including group-by-

time interactions (factors: 1) subject, baseline and follow-up scans for each participant, 2) group, two independent levels, breast cancer and control, 3) time, two non-independent levels, baseline and follow-up), and a full factorial design to examine between-group cross-sectional differences (factors: 1) group, two independent levels, breast cancer and control, 2) time, two non-independent levels, baseline and follow-up).

1. Andersson JL, Skare S, Ashburner J (2003) How to correct susceptibility distortions in spin-echo echo-planar images: application to diffusion tensor imaging. *Neuroimage* 20:870-888. [https://doi.org/10.1016/s1053-8119\(03\)00336-7](https://doi.org/10.1016/s1053-8119(03)00336-7)
2. Griffanti L, Salimi-Khorshidi G, Beckmann CF, Auerbach EJ, Douaud G, Sexton CE, Zsoldos E, Ebmeier KP, Filippini N, Mackay CE, Moeller S, Xu J, Yacoub E, Baselli G, Ugurbil K, Miller KL, Smith SM (2014) ICA-based artefact removal and accelerated fMRI acquisition for improved resting state network imaging. *Neuroimage* 95:232-247. <https://doi.org/10.1016/j.neuroimage.2014.03.034>
3. Salimi-Khorshidi G, Douaud G, Beckmann CF, Glasser MF, Griffanti L, Smith SM (2014) Automatic denoising of functional MRI data: combining independent component analysis and hierarchical fusion of classifiers. *Neuroimage* 90:449-468. <https://doi.org/10.1016/j.neuroimage.2013.11.046>

Online Resource 2 FreeSurfer Region Groupings by FreeSurfer Variable Name

Prefrontal	Temporal	Parietal	Basal Ganglia	Thalamus	Limbic	Insula
Volume	Volume	Volume	Volume	Volume	Volume	Volume
RtCaudmidfrontVol	RtBanksstsVol	RtInfparVol	LtCaudate	LtThalamus	LtAccumb	RtInsulaVol
RtlatorbitofrontVol	RtEntorhinalVol	RtPrecuneusVol	LtPutamen	RtThalamus	RtAccumb	LtInsulaVol
RtMedorbitofrontalVol	RtFusiformVol	RtSupparietalVol	LtPallidum		LtHipp	RtInsulaThick
RtParsopercularisVol	RtInfTempVol	RtIstcing	RtCaudate		LtAmyg	LtInsulaThick
RtParsorbitalisVol	RtMidtempVol	RtSupramargVol	RtPutamen		RtHippo	
RtParstriangularisVol	RtParahippoVol	LtInfparVol	RtPallidum		RtAmyg	
RtRostmidfrontVol	RtSuptempVol	LtPrecuneusVol				
RtSupfrontVol	RtTemppoleVol	LtSupparietalVol				
RtFrontalpoleVol	RtTranstempVol	LtIstcing				
RtCaudantcingVol	LtBanksstsVol	LtSupramargVol				
RtRostantcingVol	LtEntorhinalVol					
LtCaudmidfrontVol	LtFusiformVol					
LtlatorbitofrontVol	LtInfTempVol					
LtMedorbitofrontalVol	LtMidtempVol					
LtParsopercularisVol	LtParahippoVol					
LtParsorbitalisVol	LtSuptempVol					
LtParstriangularisVol	LtTemppoleVol					
LtRostmidfrontVol	LtTranstempVol					
LtSupfrontVol						
LtFrontalpoleVol						
LtCaudantcingVol						
LtRostantcingVol						
Thickness	Thickness	Thickness				
RtCaudmidfrontThick	RtBanksstsThick	RtInfparThick				
RtlatorbitofrontThick	RtEntorhinalThick	RtPrecuneusThick				
RtMedorbitofrontalThick	RtFusiformThick	RtSupparietalThick				

RtParsopercularisThick	RtInfTempThick	RtSupramargThick
RtParsorbitalisThick	RtMidtempThick	RtIstcingThick
RtParstriangularisThick	RtParahippoThick	LtInfparThick
RtRostmidfrontThick	RtSuptempThick	LtPrecuneusThick
RtSupfrontThick	RtTemppoleThick	LtSupparietalThick
RtFrontalpoleThick	RtTranstempThick	LtSupramargThick
RtCaudantcingThick	LtBanksstsThick	LtIstcingThick
RtRostantcingThick	LtEntorhinalThick	
LtCaudmidfrontThick	LtFusiformThick	
LtlatorbitofrontThick	LtInfTempThick	
LtMedorbitofrontalThick	LtMidtempThick	
LtParsopercularisThick	LtParahippoThick	
LtParsorbitalisThick	LtSuptempThick	
LtParstriangularisThick	LtTemppoleThick	
LtRostmidfrontThick	LtTranstempThick	
LtSupfrontThick		
LtFrontalpoleThick		
LtCaudantcingThick		
LtRostantcingThick		