

Chest computed tomography (CT) scan findings in patients with COVID-19: a systematic review and meta-analysis

Mohammad Karimian (MD)¹, Milad Azami (MD)^{2*}

1. Assistant Professor, Department of General Surgery, Faculty of Medicine, Ilam University of Medical Sciences, Ilam, Iran

2. Faculty of Medicine, Ilam University of Medical Sciences, Ilam, Iran

***Correspondence: Faculty of Medicine, Ilam, Iran. E-Mail: milad98azami@gmail.com, Tel:**

+989120291600

ORCID: <https://orcid.org/0000-0002-4509-5520>

Chest computed tomography (CT) scan findings in patients with COVID-19: a systematic review and meta-analysis

Abstract

Objectives: Numerous cases of pneumonia of caused by coronavirus disease 2019 (COVID-19) were reported in Wuhan, China. Chest computed tomography (CT) scan is highly important in the diagnosis and follow-up of lung disease treatment. The present meta-analysis was performed to evaluate chest CT findings in COVID-19 patients.

Materials and Methods: All research steps were taken according to the MOOSE protocol and the final report was based on PRISMA guidelines. Each stage of the study was conducted by two independent authors. We searched the Web of Science, Ovid, Science Direct, Scopus, EMBASE, PubMed/Medline, Cochrane Library, EBSCO, CINAHL and Google scholar databases. The search was conducted on March 20, 2020. Grey literature was searched at medrxiv website. All analyses were performed using Comprehensive Meta-Analysis. The adapted Newcastle Ottawa Scale was used to evaluate the risk of bias. We registered this review at PROSPERO (registration number: CRD42019127858).

Results: Finally, 40 eligible studies with 4,183 patients with COVID-19 were used for meta-analysis. The rate of positive chest CT scan in patients with COVID-19 was 94.5% (95%CI: 91.7-96.3). Bilateral lung involvement, pure ground-glass opacity (GGO), mixed (GGO pulse consolidation or reticular), consolidation, reticular, and presence of nodule findings in chest CT scan of COVID-19 pneumonia patients were respectively estimated to be 79.1% (95% CI: 70.8-85.5), 64.9% (95%CI: 54.1-74.4), 49.2% (95%CI: 35.7-62.8), 30.3% (95%CI: 19.6-43.6), 17.0% (95%CI: 3.9-50.9) and 16.6% (95%CI: 13.6-20.2). The distribution of lung lesions in patients with COVID-19 pneumonia was peripheral (70.0% [95%CI: 57.8-79.9]), central (3.9% [95%CI: 1.4-10.6]), and peripheral and central (31.1% [95%CI: 19.5-45.8]). The most common pulmonary lobes involved were right lower lobe (86.5% [95%CI: 57.7-96.8]) and left lower lobe (81.0% [95%CI: 50.5-94.7]).

Conclusion: Our study showed that chest CT scan has little weakness in diagnosis of COVID-19 combined to personal history, clinical symptoms, and initial laboratory findings, and may therefore serve as a standard method for diagnosis of COVID-19 based on its features and transformation rule, before initial RT-PCR screening.

Key word: Computed tomography, COVID-19, meta-analysis

1. Introduction

In December 2019, numerous cases of pneumonia of unknown cause were reported in Wuhan, Hubei Province, China. On January 7, 2020, the novel coronavirus, severe acute respiratory syndrome coronavirus-2 (SARS-CoV-2) was identified as a causative organism by Chinese experts by performing real-time polymerase chain reaction (real-time PCR) on patients' respiratory tract specimens. It was subsequently named 2019-nCoV by World Health Organization (WHO) (1). There is also evidence that it can be transmitted through respiratory droplets and contact with infected patients as well as fecal–oral transmission (2, 3). Etiologically speaking, virulence of a pathogen may increase sharply during host shifts (4, 5), and in contrast, the virulence may decrease through prolonged host-parasite interactions (6).

Coronavirus Disease 2019 (COVID-19) is primarily transmitted through respiratory droplets and close contact, and the incubation period is usually between 1 and 14 days. The common symptoms include fever, dry cough, fatigue, and the gradual onset of shortness of breath. People who carry the virus are the source of infection even during the incubation period. Early detection of the disease or the virus carrier is the key to prevent further spread. However, confirmation of the infection requires Nucleic Acid Detection Kit. The virus can be identified in swabs, secretions, and sputum from the respiratory tract, blood, or feces (7).

Computed tomography (CT) scan is highly important in the diagnosis and follow-up of lung disease treatment. In a review of different studies, one may find that the imaging features of COVID-19 pneumonia are varied; from their natural appearance to diffuse changes in the lungs. In addition, different radiological patterns are observed at different times over the course of the disease. Since the onset of symptoms and acute respiratory distress syndrome (ARDS) was short-

lived in first cases with COVID-19 pneumonia, early detection of the disease is essential for the management of these patients (8).

Numerous studies have been performed on the findings of CT scans in COVID-19 patients and the results are inconsistent (3, 8-46). In a systematic review and meta-analysis, a structured review of all documentation and their composition can provide a more comprehensive picture of all dimensions of the subject. One of the main goals of meta-analysis, which is a combination of different studies, is to reduce the differences between parameters by increasing the number of studies involved in the analysis process. Another noteworthy goal of meta-analysis is to find the inconsistencies between the results and their causes (47-49). The present meta-analysis was performed to evaluate CT findings in COVID-19 patients at the time of admission.

2. Method

2.1.Study protocol

All research steps were taken according to the Meta-analyses Of Observational Studies in Epidemiology (MOOSE) protocol (49) and the final report was based on the Preferred Reporting Items for Systematic Reviews and Meta-Analyses (PRISMA) guideline (Supplementary file [SF]1)(64). Each stage of the study was conducted by two independent authors. Disagreements were resolved by discussion or a third author was involved. We registered this review at PROSPERO (registration number: CRD42020178078) (SF2). Available at: https://www.crd.york.ac.uk/prospero/display_record.php?RecordID=178078.

2.2.Literature search

We searched the Web of Science (ISI), Ovid, Science Direct, Scopus, EMBASE, PubMed/Medline, Cochrane Library (Cochrane Database of Systematic Reviews - CDSR), EBSCO, CINAHL and Google scholar databases using the following keywords: “2019 nCoV”, “Novel coronavirus”, “COVID-19”, “Novel coronavirus 2019”, “Wuhan pneumonia”, “Wuhan coronavirus”, “acute respiratory infection”, “COVID-19”, and “SARS-CoV-2”, “CT scan”, “Computed tomography”, “Radiology”, “Radiography”, “Clinical Characteristics”, “clinical features”, and “COVID-19”. An example of a combined search within PubMed is as follows: (“2019 nCoV”, OR “Novel coronavirus”, OR “COVID-19”, OR “Novel coronavirus 2019”, OR “Wuhan pneumonia”, OR “Wuhan coronavirus”, OR “acute respiratory infection”, OR “COVID-19”, OR “SARS-CoV-2”) AND (“CT scan” OR “Computed tomography” OR “Radiology” OR “Radiography” OR “Clinical characteristics” OR “clinical features” OR “COVID-19”).

The search was conducted on March 20, 2020. Additional studies were identified by reviewing the reference lists of relevant articles. No language restrictions were applied. Since the present study was based on a regular review of previous studies, approval of the organizational review board and patient satisfaction was not necessary. The research received no specific funding. Grey literature was found at medrxiv (<https://www.medrxiv.org/>) and manual search of related articles was also conducted.

2.3. Inclusion and exclusion criteria

Inclusion criteria were all cross-sectional epidemiological studies aimed at examining chest CT scan findings in COVID-19 patients from January 1, 2020 until March 20, 2020 without language restrictions. Exclusion criteria were as follows: 1) non-random sampling, 2) duplicate studies, 3) studies on non-adult population (more than 10% of sample size being children), 5) being irrelevant, 6) sample size smaller than 10 participants, 7) diagnostic intervention for

COVID-19 other than laboratory confirmation, 8) CT scans findings have not been verified by at least one radiology expert 9) poor quality in qualitative evaluation, and 10) case reports, review articles, and letters to the editor without quantitative data.

2.4.Study selection and data extraction

Two authors independently presented the results of the initial search with the title and abstract. At this stage, duplicate and unrelated studies were excluded. Duplicate studies were identified manually or using EndNote X9. Both authors then reviewed the full text of appropriate articles for the inclusion and exclusion criteria. Finally, the authors independently extracted the data from the articles. Any discrepancies between the data extractors were resolved by consensus or by a third author. It should be noted that when an article reported duplicate information from the same patients, both reports were combined to obtain the most complete data, but was considered as one case.

Data summary form includes the following items: First author's name and year of publication, country and province, article references, study design, mean age and standard deviation, average duration from onset of symptoms until admission, time of performing CT scan, COVID-19 detection method, patient description, sample (respiratory secretions, blood, etc.), sample location (nasal, pharyngeal, etc.), number of patients (total, male and female), number of patients referred to the intensive care unit (ICU), quality of articles, positive chest CT scan in COVID-19 patients, number of positive chest CT scan findings in COVID-19 patients available in the studies.

2.5.Qualitative evaluation

Based on the type of studies, the adapted Newcastle–Ottawa Scale (NOS) was used to evaluate the risk of bias (65). Three categories were defined: studies with scores less than 6 were low quality studies, studies with scores 6 or 7 were medium quality, and studies with scores 8 or 9 were high quality studies.

2.6. Statistical analysis

I^2 index (with values ranging from 0 to 100%) was used to evaluate the heterogeneity between studies; values above 75% indicate high heterogeneity, 50-74% indicate significant heterogeneity, 25-49% indicate moderate heterogeneity, and values below 25% indicate low heterogeneity (66, 67). In addition, $P < 0.1$ was also defined for heterogeneity. Meta-analysis was performed with at least three studies. In case of low heterogeneity, the fixed effects model and otherwise, the random effects model was used to combine the studies. Results were reported as pooled prevalence and 95% CI. To find the cause of heterogeneity, we could not perform subgroup analysis or meta-regression due to limitations. Sensitivity analysis for meta-analyses with at least five studies was performed by omitting one study at a time to evaluate the consistency of the results. Funnel plots and the Begger's and Egger's test were used to evaluate publication bias. All analyses were performed using Comprehensive Meta-Analysis ver.2. P-values less than 0.05 were considered statistically significant.

3. Results

3.1. Description of included studies

We identified 2264 potential articles from databases. After removing duplicates, there were 766 articles left. After evaluating the titles and abstracts, 85 articles were removed for at least one of

the following reasons: non-random sampling (N=10), studies on non-adult population (N=3), being irrelevant (N=650), diagnostic intervention for COVID-19 other than laboratory confirmation (N=3), CT scans findings have not been verified by at least one radiology expert (N=2), poor quality in qualitative evaluation (N=0), and case reports, review articles, and letters to the editor without quantitative data (N=58). Finally, 40 eligible studies with 4183 patients with COVID-19 were used for meta-analysis. This process is illustrated in the SF3. The mean age of the study participants was 50.52 years (95% CI: 50.87-52.17).

3.2.Positive chest CT findings for COVID-19

The rate of positive chest CT scan in patients with COVID-19 was 94.5% (95% CI: 91.7-96.3). The lowest and highest estimates were for studies by Azami (61.5%) and many other studies (100%), respectively (Figure 1).

3.3.Bilateral lung involvement

Bilateral lung involvement in chest CT scan of patients with COVID-19 pneumonia was estimated to be 79.1% (95% CI: 70.8-85.5) (Figure 2).

3.4.Predominant chest CT scan patterns

Pure ground-glass opacity (GGO), mixed (GGO plus consolidation or reticular), consolidation, reticular, and presence of nodule findings in chest CT scan of COVID-19 pneumonia patients were respectively estimated to be 64.9% (95% CI: 54.1-74.4), 49.2% (95% CI: 35.7-62.8), 30.3% (95% CI: 19.6-43.6), 17.0% (95% CI: 3.9-50.9) and 16.6% (95% CI: 13.6-20.2) (Figure 3).

3.5.Other chest CT scan features

Other chest CT scan features are shown in Figure 4 and thickened interlobular septa was 63.6% (95% CI: 52.1-73.8), vascular enlargement was 61.4% (95% CI: 40.4-79.0), air bronchogram

sign was 53.5% (95% CI: 40.3-66.2), bronchial wall thickening was 19.8% (95% CI: 12.6-29.6), bronchiolectasis was 19.9% (95% CI: 6.5-47.2), fibrous stripes was 17.2% (95% CI: 5.2-44.2), crazy paving pattern was 21.7% (95% CI: 13.8-32.5), thickening of the adjacent pleura was 30.0% (95% CI: 16.1-48.8), pleural effusion was 6.9% (95% CI: 4.7-10.1) and lymphadenopathy was 4.7% (95% CI: 3.0-7.5) (Figure 4).

3.6.Lesions distribution

The distribution of lung lesions in patients with COVID-19 pneumonia was as follows: peripheral (70.0% [95% CI: 57.8-79.9]), central (3.9% [95% CI: 1.4-10.6]), and peripheral and central (31.1% [95% CI: 19.5-45.8]) (SF4).

3.7.Lobes involvement

Pulmonary lobes involvement in patients with COVID-19 pneumonia was as follows (Figure 5): right upper lobe (58.4% [95% CI: 33.6-79.5]), right middle lobe (49.7% [95% CI: 23.0-76.6]), right lower lobe (86.5% [95% CI: 57.7-96.8]), left upper lobe (64.5% [95% CI: 37.3-84.7]), and left lower lobe (81.0% [95% CI: 50.5-94.7]).

3.8.Number of involved lobes

In patients with COVID-19 pneumonia, the number of involved lobes was as follows (SF5): One lobe (58.4% [95% CI: 33.6-79.5]), two lobes (31.1% [95% CI: 19.5-45.8]), three lobes (10.5% [95% CI: 8.0-13.8]), four lobes (20.1% [95% CI: 15.4-25.9]), and five lobes (43.2% [95% CI: 34.2-52.6]).

3.9.Sensitivity analysis

Sensitivity analysis was performed for all meta-analyses and it showed that the overall result remains robust after the omission of one study at a time (SF6-10).

3.10. Publication bias

Publication bias was evaluated for studies that showed positive chest CT scan of COVID-19 patients (Begg's test= 0.774 and Egger's test< 0.001) and for studies that showed bilateral lung involvement in chest CT scan of COVID-19 patients pneumonia (Begg's test= 0.194 and Egger's test< 0.001) (SF11).

4. Discussion

The present study is the first systematic review and meta-analysis that extensively examines chest CT scan findings in COVID-19 patients. COVID-19 is the outbreak of a new disease with serious consequences for public health. Chest CT scan is an important part of disease detection for patients suspected of having COVID-19 infection and may help early detection of lung malformations for the purpose of screening highly suspected patients, especially those with negative initial RT-PCR screening (50). In fact, given the limited number of RT-PCR kits in many centers and the likelihood of false negative RT-PCR results, the National Health Commission of China has encouraged clinical findings and chest CT scan (51). Our review showed some imaging findings that are often seen in patients with COVID-19. The present study showed that 94.5% of COVID-19 patients had positive chest CT scan findings, while bilateral lung involvement in chest CT scan of COVID-19 pneumonia patients was 79.1%. It is important to observe the high incidence of bilateral organizing pneumonia in these patients. This suggests that corticosteroids may be an option to suppress this immune response in lung parenchyma of COVID-19 pneumonia.

Viruses are a common cause of respiratory tract infection. Imaging findings of viral pneumonia are varied, and may overlap with other infectious and inflammatory lung diseases. Viruses in the same viral family have a similar pathogenesis, so chest CT scan may help identify distinct

patterns and features in immunocompromised patients (52). Meta-analysis of initial data suggests that chest CT scan findings for 2019-nCoV have many features similar to other viruses such as the Middle East Respiratory Syndrome (MERS-CoV) and Severe Acute Respiratory Syndrome (SARS-CoV) (53).

In the present study, most pulmonary lesions include bilateral lung involvement with multiple lung lobes (predominantly right lower lobe and left lower lobe), with dominant distribution in the peripheral portion of the lungs. Studies have shown that influenza pneumonia tends to affect the lower lobes (52, 54). Wang et al. also showed that H7N9 pneumonia has a predominant distribution in the right lower lobe (54). Both H1N1 and SARS pneumonia are more peripherally distributed (55, 56), whereas no lobe infection is found in H5N1 influenza (57). However, lung involvement with peripheral predominance has also been observed in SARS and MERS. Similarly, previous coronavirus pneumonias have a similar pattern. The dominant peripheral distribution for COVID-19 was shown in our study. Such a distribution is obvious at first glance. This feature of chest CT scan is caused by alveolar injury and pulmonary interstitial edema. We also observed some chest CT scan features of COVID-19 that differ from chest CT scan features of SARS and MERS. Unifocal involvement is more common than multifocal involvement in patients with SARS and patients with MERS (58, 59). However, contrary to what is seen in chest CT scan of patients with COVID-19, multi-lobe involvement was more common than single-lobe involvement in the present meta-analysis. Thus, more than two lobes are likely to be involved in this disease. To the best of our knowledge, these findings have not been reported in the literature related to SARS and MERS.

Our results showed that the most common findings of imaging were pure GGO, GGO with mixed consolidation or reticular pattern, interlobular septal thickening, and consolidation.

Reticular and nodular pattern were relatively small, which may be explained in the first stage of the disease. In H7N9 pneumonia, most cases showed consolidation (58). Each of the chest CT scan patterns in our patients is nonspecific and may overlap with other microorganism infections such as H7N9 pneumonia, H1N1 virus infection, SARS, MERS, and avian influenza A (H5N1) (56-59).

GGO, consolidation, and interlobular septal thickening are the most common chest CT scan findings of H1N1 influenza pneumonia, too (55). Based on the present meta-analysis, pure GGO is a common finding of about 65%, and 49% GGO with interlobular septal thickening/consolidation in COVID-19 pneumonia patients. Thus, these features of chest CT scan can be seen in most patients. This finding, along with the dominant distribution in the peripheral part of the lungs, is not common in other viral pneumonia (8, 18, 27, 29, 56, 57).

In addition, we found that all features of chest CT scan that exist in the initial chest CT scan of patients with COVID-19, like GGO and consolidation, and other chest CT scan features such as vascular enlargement, interlobular septal thickening, and air bronchogram sign are also present in the chest CT scan of SARS and MERS. The low incidence of pleural effusion and lymphadenopathy noted in our data was also a feature of chest CT scan in previous studies about SARS (53). This may be due to the inherent anatomical features of the lower lobe bronchus. The right lower lobe bronchus is tighter than other bronchi of the lung, and the angle between the right lower lobe and the long axis of the trachea is smaller, so it is more viral at early stages. Most likely, it attacks the bronchial branches of the lower lobe and causes infection.

Interestingly enough, we found that most patients have vascular enlargement lesions (61.4%) that may be caused by an acute inflammatory response. However, vascular changes are not similar to changes in malignant lesions such as lung adenocarcinoma that cause vascular dilatation or

irregularity and vascular convergence, which may be due to chronic progression and tumor infiltration (17, 60).

Angiotensin II converting enzyme is a key molecule involved in the development and progression of acute lung failure. COVID-19 induces direct lung injury by involving angiotensin converting enzyme, which contributes to the progression of alveolar injury (61). This may explain the pathological mechanism of GGO and consolidation as well as rapid changes in chest CT scan findings. Our results support the observed process, according to which, bilateral GGOs or mixed GGOs in chest CT scan should prompt the radiologist to recommend COVID-19 as a possible diagnosis (62, 63).

In summary, this work is a meta-analysis on preliminary studies of chest CT scan findings about COVID-19, aimed at introducing the common imaging manifestations of the disease. Radiologists play an important role in the rapid identification and early detection of new cases, which can be useful not only for the patient but also for public health surveillance systems. It is important to recognize the fact that the appearance of CT findings about COVID-19 has some similarities to other viral diseases, especially those in the same viral family (SARS and MERS). Future studies are recommended to determine how CT scans of COVID-19 patients change after treatment.

5. Limitations

Limitations of this study include: 1. All studies were performed in China, and the severity of chest CT scan manifestations might be affected by ethnic factors; 2. Most patients were the hospitalized patients and patients with milder symptoms or those who were not hospitalized, which may cause bias in the results. 3. In most preliminary studies, chest CT scan findings were not separately reviewed according to patients admitted to the intensive care unit or the isolated

ward, 4. Follow-up for chest CT scan during treatment until discharge was not included in our study, 5. Our results are based on CT findings during admission, but patients might have experienced symptoms before admission (because chest CT scan findings are influenced by the clinical course of the disease) and during this time, the patient might have received antiviral or antibacterial drugs, or steroid therapy, and this might have affected chest CT scan findings, 6. Since all studies were performed in 2020 in China with the same diagnostic method, we could not discover the cause of heterogeneity.

In conclusion, our study showed that chest CT scan has little weakness in diagnosis of COVID-19 combined to personal history, clinical symptoms, and initial laboratory findings, and may therefore serve as a standard method for diagnosis of COVID-19 based on its features and transformation rule. Rapid detection may lead to early control of the transmission. By diagnosing viral pneumonia on CT scan, infected or suspected patients can be isolated and treated in a timely manner to optimize patient management, especially for hospitals or communities without Rt-PCR test kits. However, chest CT scan is still limited in terms of identifying specific viruses. It is important that radiologists recognize if chest CT scan findings for COVID-19 overlap with chest CT scan findings for diseases caused by different virus families, such as adenovirus. They should also recognize the differences and similarities with other viruses in the same family, such as SARS-CoV and MERS-CoV or other families such as influenza. According to the present meta-analysis, lesion distribution in patients with COVID-19 is likely to have peripheral distribution, bilateral involvement, lower lobe dominance, and multi-lobe distribution.

Authors' contributions

MA and MK acquired the data. MA and MK analyzed and interpreted the data. MA drafted the manuscript; MA and MK critically revised the manuscript for important intellectual content. MK supervised the study. All authors have read and approved the manuscript in its current state.

Declaration of interests

We declare no competing interests

Abbreviation

SARS-CoV-2= severe acute respiratory syndrome coronavirus-2

real-time PCR real-time polymerase chain reaction

WHO= World Health Organization

COVID-19= Coronavirus Disease 2019

CT= computed tomography

MOOSE= Meta-analyses Of Observational Studies in Epidemiology

PRISMA the Preferred Reporting Items for Systematic Reviews and Meta-Analyses

PROSPERO = The International Prospective Register of Systematic Reviews

ICU= intensive care unit

GGO= ground-glass opacity

MERS-CoV= Middle East Respiratory Syndrome

SARS-CoV= Severe Acute Respiratory Syndrome

References:

1. WHO. Coronavirus disease (COVID-19) outbreak 2020 [Available from: <https://www.who.int/westernpacific/emergencies/covid-19>.
2. Li Q, Guan X, Wu P, Wang X, Zhou L, Tong Y, et al. Early transmission dynamics in Wuhan, China, of novel coronavirus-infected pneumonia. New England Journal of Medicine. 2020.

3. Chen N, Zhou M, Dong X, Qu J, Gong F, Han Y, et al. Epidemiological and clinical characteristics of 99 cases of 2019 novel coronavirus pneumonia in Wuhan, China: a descriptive study. *The Lancet*. 2020;395(10223):507-13.
4. Jones KE, Patel NG, Levy MA, Storeygard A, Balk D, Gittleman JL, et al. Global trends in emerging infectious diseases. *Nature*. 2008;451(7181):990-3.
5. Woolhouse ME, Haydon DT, Antia R. Emerging pathogens: the epidemiology and evolution of species jumps. *Trends in ecology & evolution*. 2005;20(5):238-44.
6. Alizon S, Hurford A, Mideo N, Van Baalen M. Virulence evolution and the trade-off hypothesis: history, current state of affairs and the future. *Journal of evolutionary biology*. 2009;22(2):245-59.
7. Pan Y, Guan H. Imaging changes in patients with 2019-nCov. Springer; 2020.
8. Huang C, Wang Y, Li X, Ren L, Zhao J, Hu Y, et al. Clinical features of patients infected with 2019 novel coronavirus in Wuhan, China. *The Lancet*. 2020;395(10223):497-506.
9. Chen G, Wu D, Guo W, Cao Y, Huang D, Wang H, et al. Clinical and immunologic features in severe and moderate forms of Coronavirus Disease 2019. *medRxiv*. 2020.
10. Yang W, Cao Q, Qin L, Wang X, Cheng Z, Pan A, et al. Clinical characteristics and imaging manifestations of the 2019 novel coronavirus disease (COVID-19): A multi-center study in Wenzhou city, Zhejiang, China. *Journal of Infection*. 2020.
11. Xu Y-H, Dong J-H, An W-M, Lv X-Y, Yin X-P, Zhang J-Z, et al. Clinical and computed tomographic imaging features of Novel Coronavirus Pneumonia caused by SARS-CoV-2. *Journal of Infection*. 2020.
12. Shi H, Han X, Jiang N, Cao Y, Alwalid O, Gu J, et al. Radiological findings from 81 patients with COVID-19 pneumonia in Wuhan, China: a descriptive study. *The Lancet Infectious Diseases*. 2020.
13. Wang D, Hu B, Hu C, Zhu F, Liu X, Zhang J, et al. Clinical characteristics of 138 hospitalized patients with 2019 novel coronavirus-infected pneumonia in Wuhan, China. *Jama*. 2020.

14. Pan Y, Guan H, Zhou S, Wang Y, Li Q, Zhu T, et al. Initial CT findings and temporal changes in patients with the novel coronavirus pneumonia (2019-nCoV): a study of 63 patients in Wuhan, China. *European Radiology*. 2020:1-4.
15. Xu X-W, Wu X-X, Jiang X-G, Xu K-J, Ying L-J, Ma C-L, et al. Clinical findings in a group of patients infected with the 2019 novel coronavirus (SARS-Cov-2) outside of Wuhan, China: retrospective case series. *Bmj*. 2020;368.
16. Li Y, Xia L. Coronavirus Disease 2019 (COVID-19): Role of chest CT in diagnosis and management. *American Journal of Roentgenology*. 2020:1-7.
17. Zhou S, Wang Y, Zhu T, Xia L. CT Features of Coronavirus Disease 2019 (COVID-19) Pneumonia in 62 Patients in Wuhan, China. *American Journal of Roentgenology*. 2020:1-8.
18. Zhao W, Zhong Z, Xie X, Yu Q, Liu J. Relation Between Chest CT Findings and Clinical Conditions of Coronavirus Disease (COVID-19) Pneumonia: A Multicenter Study. *American Journal of Roentgenology*. 2020:1-6.
19. Guan W-j, Ni Z-y, Hu Y, Liang W-h, Ou C-q, He J-x, et al. Clinical characteristics of 2019 novel coronavirus infection in China. *MedRxiv*. 2020.
20. Ai J-W, Zhang H-C, Xu T, Wu J, Zhu M, Yu Y-Q, et al. Optimizing diagnostic strategy for novel coronavirus pneumonia, a multi-center study in Eastern China. *medRxiv*. 2020.
21. Feng Z, Yu Q, Yao S, Luo L, Duan J, Yan Z, et al. Early Prediction of Disease Progression in 2019 Novel Coronavirus Pneumonia Patients Outside Wuhan with CT and Clinical Characteristics. *medRxiv*. 2020.
22. Yuan M, Yin W, Tao Z, Tan W, Hu Y. Association of radiologic findings with mortality of patients infected with 2019 novel coronavirus in Wuhan, China. *medRxiv*. 2020.

23. Qian G-Q, Yang N-B, Ding F, Ma AHY, Wang Z-Y, Shen Y-F, et al. Epidemiologic and Clinical Characteristics of 91 Hospitalized Patients with COVID-19 in Zhejiang, China: A retrospective, multi-centre case series. medRxiv. 2020.
24. Cao W. Clinical features and laboratory inspection of novel coronavirus pneumonia (COVID-19) in Xiangyang, Hubei. medRxiv. 2020.
25. Liang Y, Liang J, Zhou Q, Li X, Lin F, Deng Z, et al. Prevalence and clinical features of 2019 novel coronavirus disease (COVID-19) in the Fever Clinic of a teaching hospital in Beijing: a single-center, retrospective study. medRxiv. 2020.
26. Huang Y, Zhou H, Yang R, Xu Y, Feng X, Gong P. Clinical characteristics of 36 non-survivors with COVID-19 in Wuhan, China. medRxiv. 2020.
27. Wu J, Wu X, Zeng W, Guo D, Fang Z, Chen L, et al. Chest CT Findings in Patients with Corona Virus Disease 2019 and its Relationship with Clinical Features. Investigative Radiology. 2020.
28. Kui L, Fang Y-Y, Deng Y, Liu W, Wang M-F, Ma J-P, et al. Clinical characteristics of novel coronavirus cases in tertiary hospitals in Hubei Province. Chinese Medical Journal. 2020.
29. Chung M, Bernheim A, Mei X, Zhang N, Huang M, Zeng X, et al. CT imaging features of 2019 novel coronavirus (2019-nCoV). Radiology. 2020:200230.
30. Song F, Shi N, Shan F, Zhang Z, Shen J, Lu H, et al. Emerging 2019 novel coronavirus (2019-nCoV) pneumonia. Radiology. 2020:200274.
31. Bernheim A, Mei X, Huang M, Yang Y, Fayad ZA, Zhang N, et al. Chest CT Findings in Coronavirus Disease-19 (COVID-19): Relationship to Duration of Infection. Radiology. 2020:200463.
32. Xu Z, Wu W, Jin Y, Pan A. Key Points of Clinical and CT Imaging Features of 2019 Novel Coronavirus (2019-nCoV) Imported Pneumonia Based on 21 Cases Analysis. Available at SSRN 3543610. 2020.

33. Li K, Wu J, Wu F, Guo D, Chen L, Fang Z, et al. The clinical and chest CT features associated with severe and critical COVID-19 pneumonia. *Investigative radiology*. 2020.
34. Jj Z. Clinical characteristics of 140 patients infected with SARS-CoV-2 in Wuhan, China [Published Online February 19, 2020]. *Allergy DOI*.10.
35. Liu W, Wang F, Li G, Wei Y, Li X, He L, et al. Analysis of 2019-nCoV Infection and Clinical Manifestations of Outpatients: An Epidemiological Study from the Fever Clinic in Wuhan, China. 2020.
36. Hu Z, Song C, Xu C, Jin G, Chen Y, Xu X, et al. Clinical characteristics of 24 asymptomatic infections with COVID-19 screened among close contacts in Nanjing, China. *Science China Life Sciences*. 2020:1-6.
37. Fu H, Li H, Tang X, Li X, Shen J, Zhou Y, et al. Analysis on the Clinical Characteristics of 36 Cases of Novel Coronavirus Pneumonia in Kunming. *medRxiv*. 2020.
38. Li J, Li S, Cai Y, Liu Q, Li X, Zeng Z, et al. Epidemiological and Clinical Characteristics of 17 Hospitalized Patients with 2019 Novel Coronavirus Infections Outside Wuhan, China. *medRxiv*. 2020.
39. Cai Q, Huang D, Ou P, Yu H, Zhu Z, Xia Z, et al. COVID-19 in a Designated Infectious Diseases Hospital Outside Hubei Province, China. *medRxiv*. 2020.
40. Jian-ya G. Clinical characteristics of 51 patients discharged from hospital with COVID-19 in Chongqing, China. *medRxiv*. 2020.
41. Cui P, Chen Z, Wang T, Dai J, Zhang J, Ding T, et al. Clinical features and sexual transmission potential of SARS-CoV-2 infected female patients: a descriptive study in Wuhan, China. *medRxiv*. 2020.
42. Cao M, Zhang D, Wang Y, Lu Y, Zhu X, Li Y, et al. Clinical Features of Patients Infected with the 2019 Novel Coronavirus (COVID-19) in Shanghai, China. *medRxiv*. 2020.
43. Xu Y, Li Y-r, Zeng Q, Lu Z-b, Li Y-z, Wu W, et al. Clinical characteristics of SARS-CoV-2 pneumonia compared to controls in Chinese Han population. *medRxiv*. 2020.

44. Chen J, Fan H, Zhang L, Huang B, Zhu M, Zhou Y, et al. Retrospective Analysis of Clinical Features in 101 Death Cases with COVID-19. medRxiv. 2020.
45. Liu J, Ouyang L, Guo P, sheng Wu H, Fu P, liang Chen Y, et al. Epidemiological, Clinical Characteristics and Outcome of Medical Staff Infected with COVID-19 in Wuhan, China: A Retrospective Case Series Analysis. medRxiv. 2020.
46. Lei Y. Clinical features of imported cases of coronavirus disease 2019 in Tibetan patients in the Plateau area. medRxiv. 2020.
47. Sayehmiri K, Tavan H, Sayehmire F, Mohamadi I. Prevalence of Epilepsy in iran using meta-analysis and systematic review. J Adv Med Biomed Res. 2015;23(97):112-21.
48. Sayehmiri K, Tavan H. Systematic review and meta-analysis methods prevalence of peptic ulcer in IRAN. Journal of Govareesh. 2015;20(4):250-8.
49. Stroup DF, Berlin JA, Morton SC, Olkin I, Williamson GD, Rennie D, et al. Meta-analysis of observational studies in epidemiology: a proposal for reporting. Jama. 2000;283(15):2008-12.
50. Xie X, Zhong Z, Zhao W, Zheng C, Wang F, Liu J. Chest CT for typical 2019-nCoV pneumonia: relationship to negative RT-PCR testing. Radiology. 2020:200343.
51. X Y. China's Hubei reports jump in new cases of COVID-19 after diagnosis criteria revision. National Health Commission of the People's Republic of China website [Available from: www.en.nhc.gov.cn/2020-02/13/c_76515.htm. Published February 13, 2020. Accessed February 17, 2020.
52. Koo HJ, Lim S, Choe J, Choi S-H, Sung H, Do K-H. Radiographic and CT features of viral pneumonia. Radiographics. 2018;38(3):719-39.
53. Ooi GC, Khong PL, Müller NL, Yiu WC, Zhou LJ, Ho JC, et al. Severe acute respiratory syndrome: temporal lung changes at thin-section CT in 30 patients. Radiology. 2004;230(3):836-44.

54. Wang Q, Zhang Z, Shi Y, Jiang Y. Emerging H7N9 influenza A (novel reassortant avian-origin) pneumonia: radiologic findings. *Radiology*. 2013;268(3):882-9.
55. Yuan Y, Tao XF, Shi YX, Liu SY, Chen JQ. Initial HRCT findings of novel influenza A (H1N1) infection. *Influenza and other respiratory viruses*. 2012;6(6):e114-e9.
56. Wong K-t, Antonio GE, Hui DS, Ho C, Chan P-n, Ng W-h, et al. Severe acute respiratory syndrome: thin-section computed tomography features, temporal changes, and clinoradiologic correlation during the convalescent period. *Journal of computer assisted tomography*. 2004;28(6):790-5.
57. Qureshi NR, Hien TT, Farrar J, Gleeson FV. The radiologic manifestations of H5N1 avian influenza. *Journal of thoracic imaging*. 2006;21(4):259-64.
58. Paul NS, Roberts H, Butany J, Chung T, Gold W, Mehta S, et al. Radiologic pattern of disease in patients with severe acute respiratory syndrome: the Toronto experience. *Radiographics*. 2004;24(2):553-63.
59. Das KM, Lee EY, Langer RD, Larsson SG. Middle east respiratory syndrome coronavirus: what does a radiologist need to know? *American Journal of Roentgenology*. 2016;206(6):1193-201.
60. Xu X, Chen P, Wang J, Feng J, Zhou H, Li X, et al. Evolution of the novel coronavirus from the ongoing Wuhan outbreak and modeling of its spike protein for risk of human transmission. *Science China Life Sciences*. 2020;63(3):457-60.
61. Zhou P, Yang X-L, Wang X-G, Hu B, Zhang L, Zhang W, et al. A pneumonia outbreak associated with a new coronavirus of probable bat origin. *Nature*. 2020;579(7798):270-3.
62. Müller NL, Ooi GC, Khong PL, Nicolaou S. Severe acute respiratory syndrome: radiographic and CT findings. *American Journal of Roentgenology*. 2003;181(1):3-8.
63. Müller NL, Ooi GC, Khong PL, Zhou LJ, Tsang KW, Nicolaou S. High-resolution CT findings of severe acute respiratory syndrome at presentation and after admission. *American Journal of Roentgenology*. 2004;182(1):39-44.

64. Moher D, Shamseer L, Clarke M, Ghera D, Liberati A, Petticrew M, et al. Preferred reporting items for systematic review and meta-analysis protocols (PRISMA-P) 2015 statement. *Systematic reviews*. 2015;4(1):1.
65. Peterson J, Welch V, Losos M, Tugwell P. The Newcastle-Ottawa scale (NOS) for assessing the quality of nonrandomised studies in meta-analyses. Ottawa: Ottawa Hospital Research Institute. 2011.
66. Higgins JP, Green S. *Cochrane handbook for systematic reviews of interventions*: John Wiley & Sons; 2011.
67. Higgins JP, Thompson SG, Deeks JJ, Altman DG. Measuring inconsistency in meta-analyses. *Bmj*. 2003;327(7414):557-60.

Figures legends:

Figure 1: Meta-analysis of positive chest CT scan in patients with COVID-19.

Figure 2: Meta-analysis of bilateral lung involvement in chest CT scan of patients with COVID-19 pneumonia.

Figure 3: Meta-analysis of pure ground-glass opacity (GGO) (A), mixed (GGO pulse consolidation or reticular) (B), consolidation (C), reticular (D), and presence of nodule (E) findings in chest CT scan of COVID-19 pneumonia.

Figure 4: Meta-analysis of thickened interlobular septa (A), vascular enlargement was (B), air bronchogram sign (C), bronchial wall thickening was (D), bronchiolectasis (E), fibrous stripes (F), crazy paving pattern (G), thickening of the adjacent pleura (H), pleural effusion (I) and lymphadenopathy (J) findings in chest CT scan of COVID-19 pneumonia.

Figure 5: Meta-analysis of right upper lobe (A), right middle lobe (B), right lower lobe (C), left upper lobe (D), and left lower lobe (E) involvement in chest CT scan of COVID-19 pneumonia.

Supplementary files:

Supplementary file 1: PRISMA checklist

Supplementary file 2: PROSPERO registration

Supplementary file 3: PRISMA flowchart

Supplementary file 4: Meta-analysis of the distribution of lung lesions in patients with COVID-19 pneumonia was as follows: peripheral (A), central (B), and peripheral and central (C).

Supplementary file 5: Meta-analysis of one lobe involvement (A), two lobes involvement (B), three lobes involvement (C), four lobes involvement (D), and five lobes involvement (E).

Supplementary file 6: Sensitivity analysis of positive chest CT scan in patients with COVID-19.

Supplementary file 7: Sensitivity analysis of bilateral lung involvement in chest CT scan of patients with COVID-19 pneumonia.

Supplementary file 8: Sensitivity analysis of pure ground-glass opacity (GGO) (A), mixed (GGO plus consolidation or reticular) (B), consolidation (C), reticular (D), and presence of nodule (E) findings in chest CT scan of COVID-19 pneumonia.

Supplementary file 9: Sensitivity analysis of thickened interlobular septa (A), vascular enlargement was (B), air bronchogram sign (C), bronchial wall thickening was (D), bronchiolectasis (E), fibrous stripes (F), crazy paving pattern (G), thickening of the adjacent pleura (H), pleural effusion (I) and lymphadenopathy (J) findings in chest CT scan of COVID-19 pneumonia.

Supplementary file 10: Sensitivity analysis of right upper lobe (A), right middle lobe (B), right lower lobe (C), left upper lobe (D), and left lower lobe (E) involvement in chest CT scan of COVID-19 pneumonia.

Supplementary file 11: Publication bias for positive chest CT scan of COVID-19 patients (A) and for studies that showed bilateral lung involvement in chest CT scan of COVID-19 patients pneumonia (B)

Table 1: Characteristics of articles entered into meta-analysis

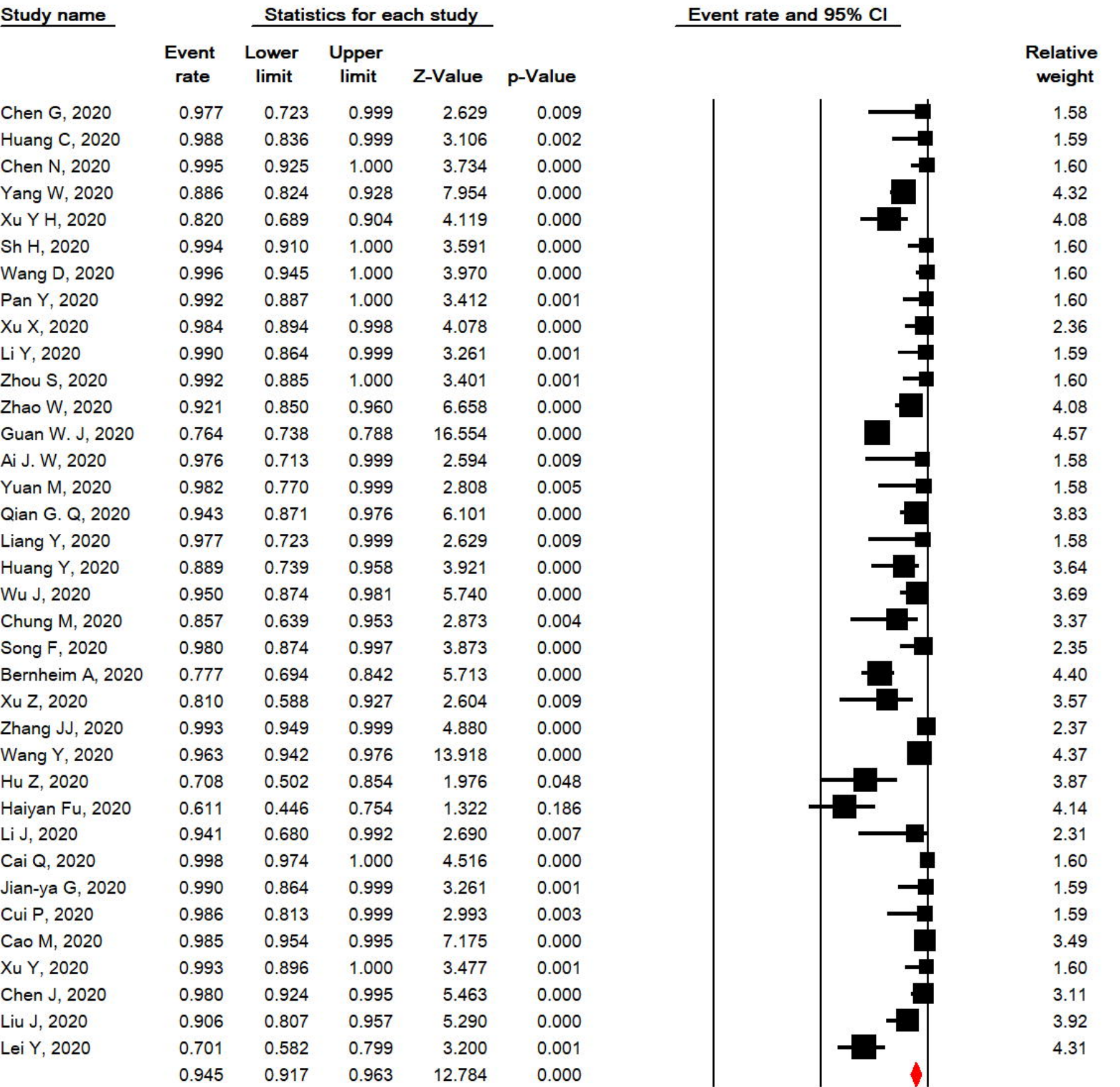
Ref.	First author, Published Year	Source	Time assessment	Country / Province	Population	Age (year)		The onset of symptoms to admission (day)		ICU / isolate admission	Sample	COVID-19 Confirmation	Sample size			Quality
						Mean	SD	Median	Range				All	Male /Female	CT(+)	
(9)	Chen G, 2020	medRxiv	On admission	China, Wuhan	Patients with 2019-nCoV pneumonia (severe and moderate)	56.3	14.30				Respiratory specimens	Next-generation sequencing or real-time RT-PCR	21	17/4	21	7
(8)	Huang C, 2020	Lancet	On admission	China, Wuhan	Patients with 2019-nCoV pneumonia	49.0	41-58	7.0	4-8	13/8	Respiratory specimens or plasma	RT-PCR confirmed	41	30/11	41	9
(3)	Chen N, 2020	Lancet	On admission	China, Wuhan	Patients with 2019-nCoV pneumonia	55.5	13.1				Throat-swab specimens	RT-PCR confirmed	99	67/32	99	9
(10)	Yang W, 2020	Journal of Infection	On admission	China, Zhejiang	Patients with 2019-nCoV pneumonia	45.11	13.35	6.8	5	0/149	Nasal and pharyngeal swab specimens	RT-PCR confirmed	149	81/68	132	7
(11)	Xu Y H, 2020	Journal of Infection	Not mentioned	China, Beijing	Patients with 2019-nCoV pneumonia	43.9	16.8				Not mentioned	Nucleic acid testing	50	29/21	41	6
(12)	Sh H, 2020	The Lancet Infectious Diseases	On admission	China, Wuhan	Patients with confirmed COVID-19 pneumonia	49.5	11.0				Throats wab	Next-generation sequencing or RT-PCR	81	42/39	81	8
(13)	Wang D, 2020	JAMA	On admission	China, Wuhan	Patients with confirmed COVID-19 pneumonia			7.0	4-8	36/102	Throats wab specimens	RT-PCR confirmed	138	75/63	138	9
(14)	Pan Y, 2020	European Radiology	On admission	China, Wuhan	Patients with confirmed COVID-19 pneumonia	44.9	15.2				Nasopharyngeal	RT-PCR confirmed	63	33/30	63	8
(15)	Xu X, 2020	BMJ: British Medical Journal	On admission	China, Zhejiang	Patients with confirmed COVID-19 pneumonia	41.0	32-52	2.0	1-4		Sputum and throat swab specimens	RT-PCR confirmed	62	36/27	61	8
(16)	Li Y, 2020	American Journal of	On	China,	Patients with	58.0	17				Oropharyngeal	nucleic acid testing	51	28/23	51	9

		Roentgenology	admission	Wuhan	COVID-19						swab					
(17)	Zhou S, 2020	American Journal of Roentgenology	On admission	China, Wuhan	Patients with confirmed COVID-19 pneumonia	52.8	12.2				Respiratory specimens	RT-PCR confirmed	62	39/23	62	9
(18)	Zhao W, 2020	American Journal of Roentgenology	Not mentioned	China, Hunan	Patients with confirmed COVID-19 pneumonia	44.44	12.3				Not mentioned	RT-PCR confirmed	101	56/45	93	8
(19)	Guan W. J, 2020	MedRxiv	On admission	China, 31 provinces	patients with laboratory-confirmed 2019-nCoV ARD					55/1044	Nasal and pharyngeal swab specimens	RT-PCR confirmed	1099	640/459	840	7
(20)	Ai J. W, 2020	medRxiv	On admission	China, Eastern cities	Patients with confirmed COVID-19 pneumonia						Nasopharyngeal swab specimens	RT-PCR confirmed	20	10/10	20	8
(21)	Feng Z, 2020	medRxiv	On admission	China, outside Wuhan	Patients with confirmed COVID-19 pneumonia	44.0					Nasal and pharyngeal swab specimens	RT-PCR confirmed	141	72/69		7
(22)	Yuan M, 2020	medRxiv	On admission	China, Wuhan	Patients with confirmed COVID-19 pneumonia			8.0	5-11		Throat-swab specimens	RT-PCR confirmed	27	12/15	27	8
(23)	Qian G. Q, 2020	medRxiv	On admission	China, Zhejiang	Patients with COVID-19						Throat-swab specimens	RT-PCR confirmed	88	37/54	83	8
(24)	Cao W, 2020	medRxiv	On admission	China, Hubei	Patients with COVID-19						Nasal and pharyngeal swab specimens	RT-PCR confirmed	128	60/68		8
(25)	Liang Y, 2020	medRxiv	Not mentioned	China, Beijing	Patients with confirmed COVID-19 pneumonia						Throat-swab specimens	RT-PCR confirmed	21	11/10	21	8
(26)	Huang Y, 2020	medRxiv	On admission	China, Wuhan	Non-survivors patients with COVID-19	69.22	9.64				Not mentioned	RT-PCR confirmed	36	11/25	32	7
(27)	Wu J, 2020	Invest Radiol	On admission	China, Chongqin	Patients with COVID-19	44.0	11.00	7.0	4		Throat swabs or lower respiratory	RT-PCR confirmed	80	42/38	76	7

				g							tract					
(28)	Kui L, 2020	Chinese Medical Journal	Not mentioned	China, Hubei	Patients with COVID-19	55.0	16.00				Sputum and nasopharyngeal swabs	Nucleic acid positive and RT-PCR confirmed	137	61/76		7
(29)	Chung M, 2020	Radiology	On admission	China, three provinces	Patients with COVID-19	51.0	14.00				Bronchoalveolar lavage, endotracheal aspirate, nasopharyngeal swab, or oropharynx	RT-PCR confirmed	21	13/8	18	7
(30)	Song F, 2020	Radiology	Not mentioned	China, Wuhan	Patients with COVID-19	49.0	16	4.0	1-14		Not mentioned	RT-PCR confirmed	51	25/26	50	8
(31)	Bernheim A, 2020	Radiology	On admission	China, four provinces	Patients with COVID-19	45.0	15.60		1-15		Bronchoalveolar lavage, endotracheal aspirate, nasopharyngeal swab, or oropharynx	RT-PCR confirmed	121	61/60	94	8
(32)	Xu Z, 2020	Lancet	On admission	China, Guangdong	Patients with confirmed COVID-19 pneumonia	43.1	17.10				Not mentioned	Not mentioned	21	10/11	17	9
(33)	Li K, 2020	Investigative Radiology	On admission	China, Chongqing	Patients with confirmed COVID-19 pneumonia	45.5	12.3				Throat swabs or lower respiratory tract /respiratory or blood samples	RT-PCR confirmed	83	44/39		8
(34)	Zhang JJ, 2020	Epidemiology and Genetics	On admission	China, Wuhan	Patients with COVID-19			8.0	6-11		Pharyngeal swab specimens	RT-PCR confirmed	135	68/67	134	8
(35)	Wang Y, 2020	Lancet	Not mentioned	China, Wuhan	Patients with COVID-19						Not mentioned	Nucleic acid	511		492	8
(36)	Hu Z, 2020	Science China Life Sciences	On admission	Nanjing, China	Asymptomatic carriers were laboratory-confirmed positive for the COVID-19 virus					1/23	Pharyngeal swab specimens	RT-PCR confirmed	24	8/16	17	9
(37)	Haiyan Fu, 2020	medRxiv	On admission	Kunming, China	Patients with COVID-19					2/34	Respiratory specimens	RT-PCR confirmed	36	16/20	22	8

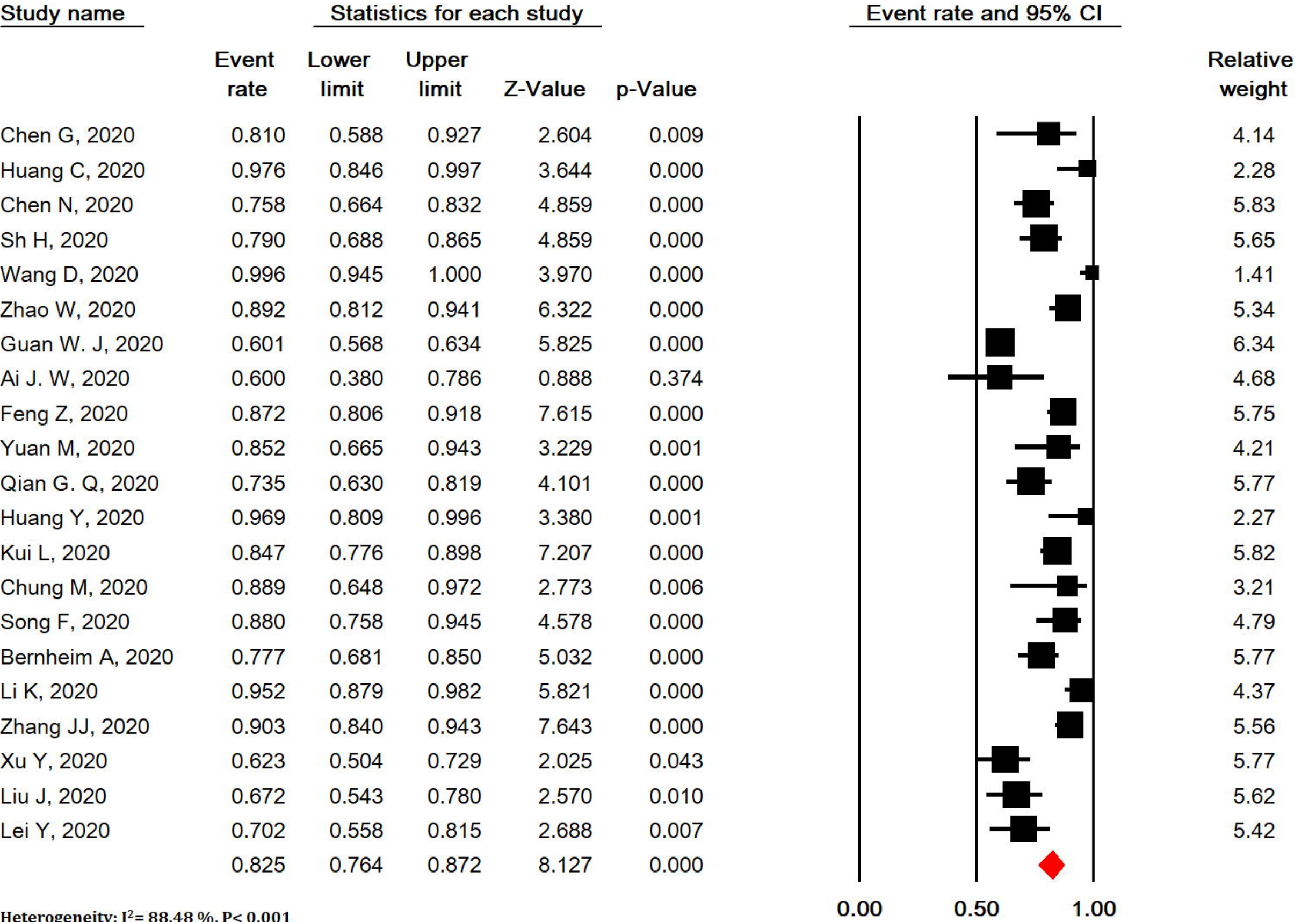
(38)	Li J, 2020	medRxiv	On admission		Patients with confirmed COVID-19 pneumonia			5.0	2.-7	58/240	throat swab	RT-PCR confirmed	17	9/8	16	7
(39)	Cai Q, 2020	medRxiv	On admission	China, Hubei Province	Patients with confirmed COVID-19 pneumonia	47.0	33-61			32/266	Nasal swab	RT-PCR confirmed	298	149/149	298	8
(40)	Jian-ya G, 2020	medRxiv	On admission	China, Chongqing	Patients with COVID-19			6.0	3-8	7/44	Not mentioned	RT-PCR confirmed	51	32/19	51	7
(41)	Cui P, 2020	medRxiv	On admission	China, Wuhan	Patients with COVID-19	61.5	11.2				Throat swab	RT-PCR confirmed	35	0/35	35	8
(42)	Cao M, 2020	medRxiv	On admission	China, Shanghai	Patients with COVID-19	50.1	16.3	5.0		19/179	Throat-swab specimens	RT-PCR confirmed	198	101/97	195	6
(43)	Xu Y, 2020	medRxiv	On admission	China, Chinese Han	Patients with confirmed COVID-19 pneumonia					25/44	Pharyngeal swab specimens	RT-PCR confirmed	69	35/34	69	7
(44)	Chen J, 2020	medRxiv	On admission	China, Wuhan	Death Cases with COVID-19	65.46	9.74	11.0	8-13.5	47/54	Not mentioned	RT-PCR confirmed	101	64/37	99	7
(45)	Liu J, 2020	medRxiv	On admission	China, Wuhan	Medical Staff Infected with COVID-19			8.5	4.3-15.0		Throat-swab specimens	RT-PCR confirmed	64	28/36	58	8
(46)	Lei Y, 2020	medRxiv	On admission	China, Chengdu	Tibetan patients with COVID-19	39.3	18.3			7/60	nasal and pharyngeal swabs or blood	RT-PCR confirmed	67	39/28	47	8

SD: standard deviation, NR: not reported



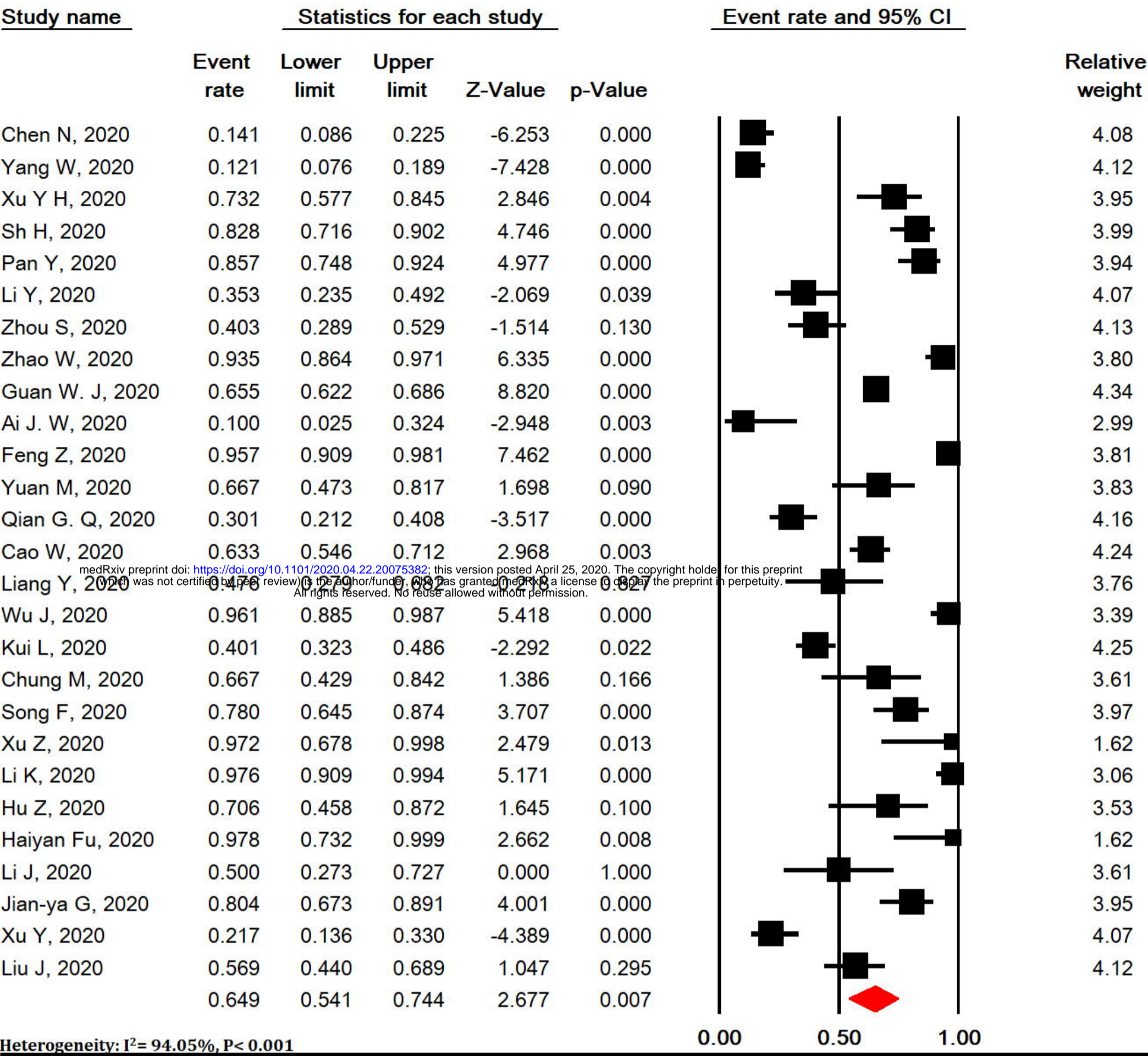
Heterogeneity: I²= 98.6%, P< 0.001

Meta Analysis



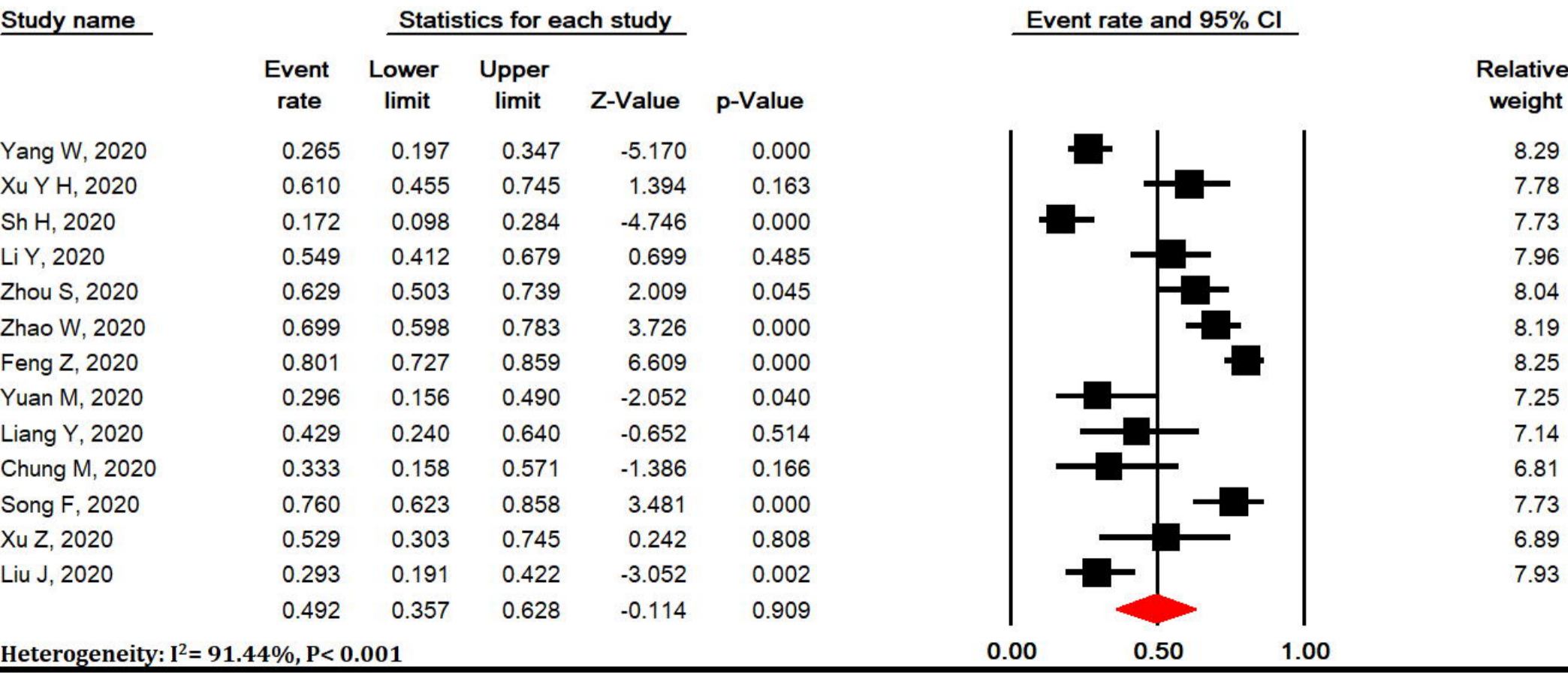
Meta Analysis

A

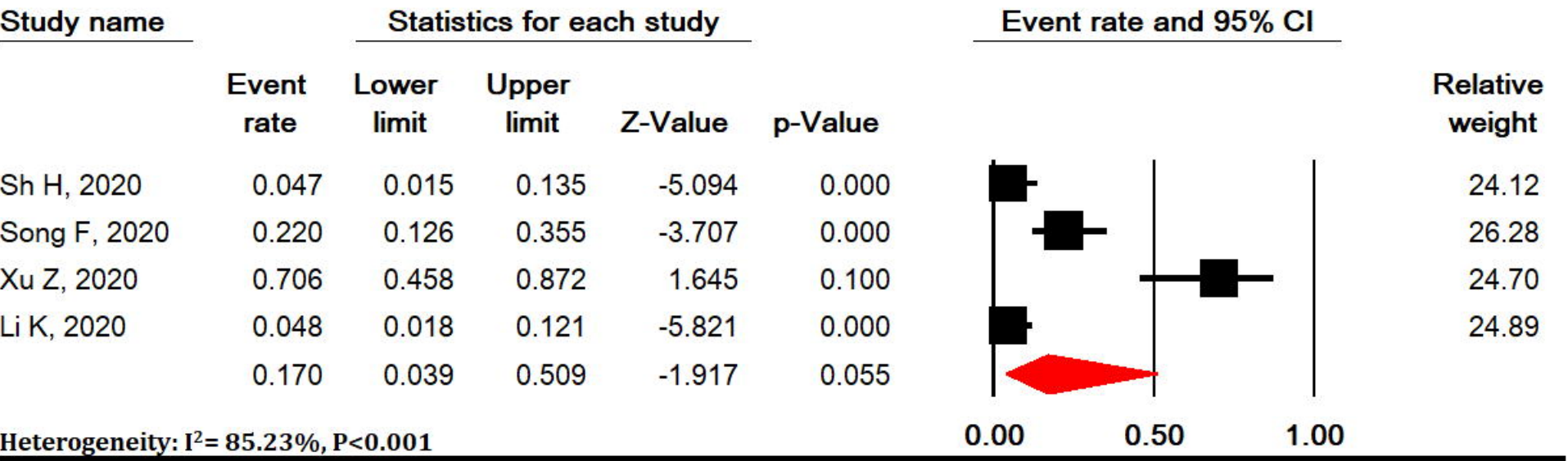


Meta Analysis

B

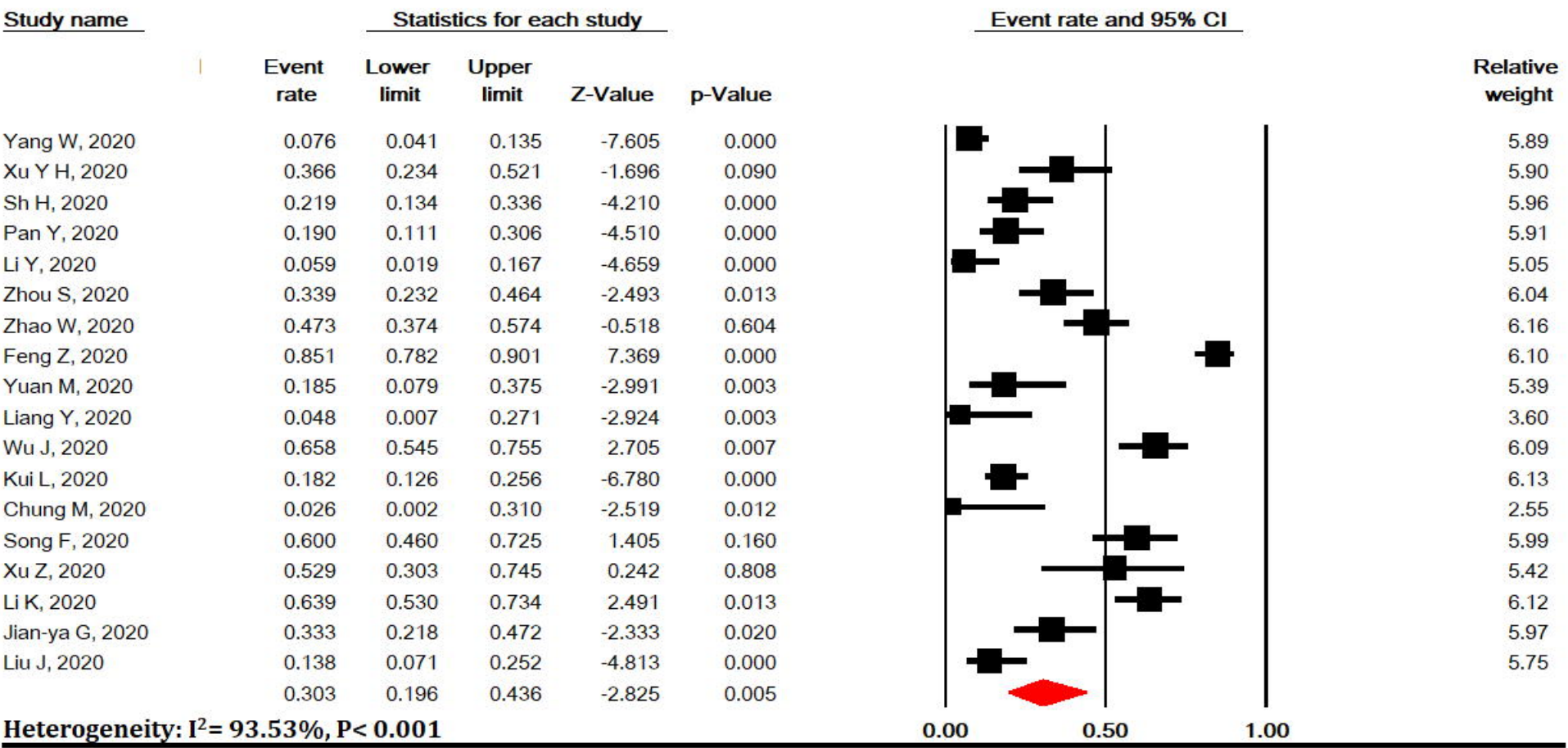


Meta Analysis

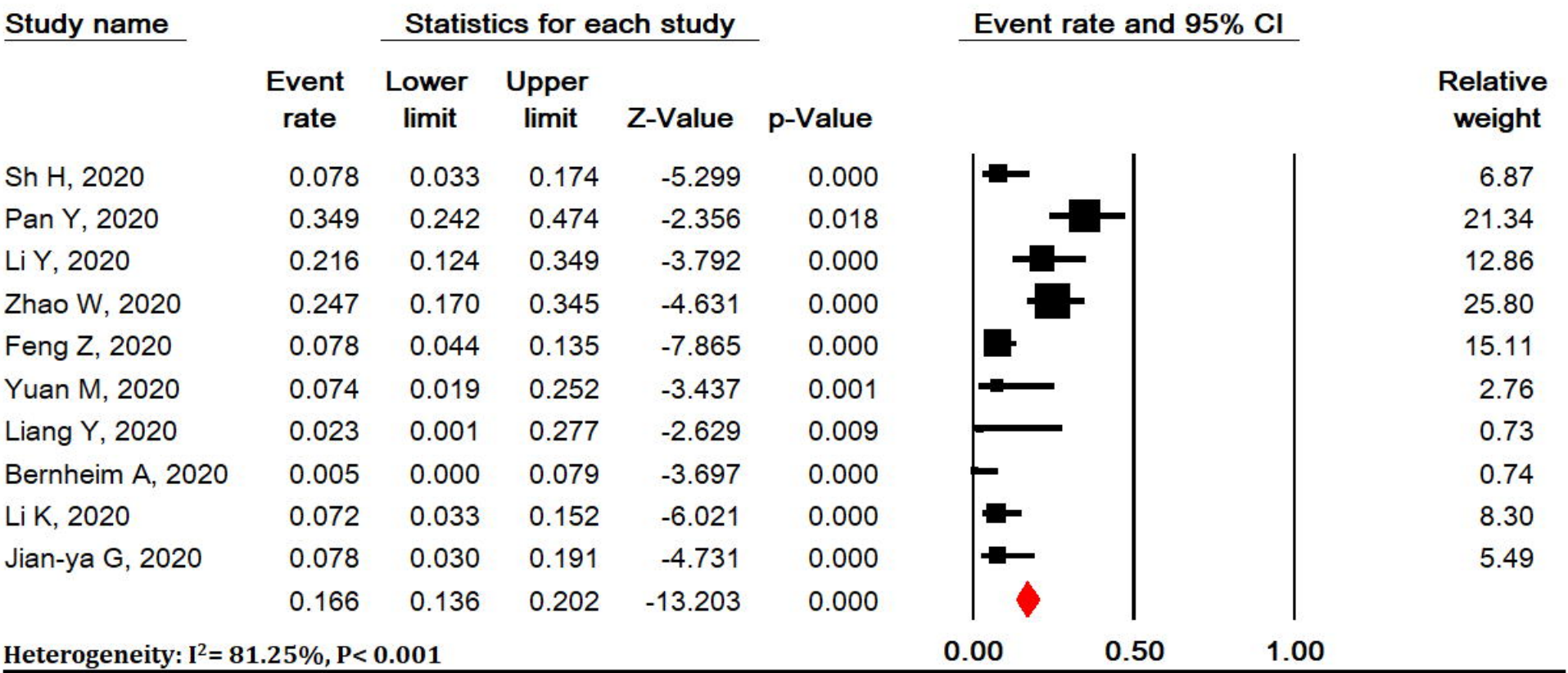


Meta Analysis

medRxiv preprint doi: <https://doi.org/10.1101/2020.04.22.20075382>; this version posted April 25, 2020. The copyright holder for this preprint (which was not certified by peer review) is the author/funder, who has granted medRxiv a license to display the preprint in perpetuity. All rights reserved. No reuse allowed without permission.

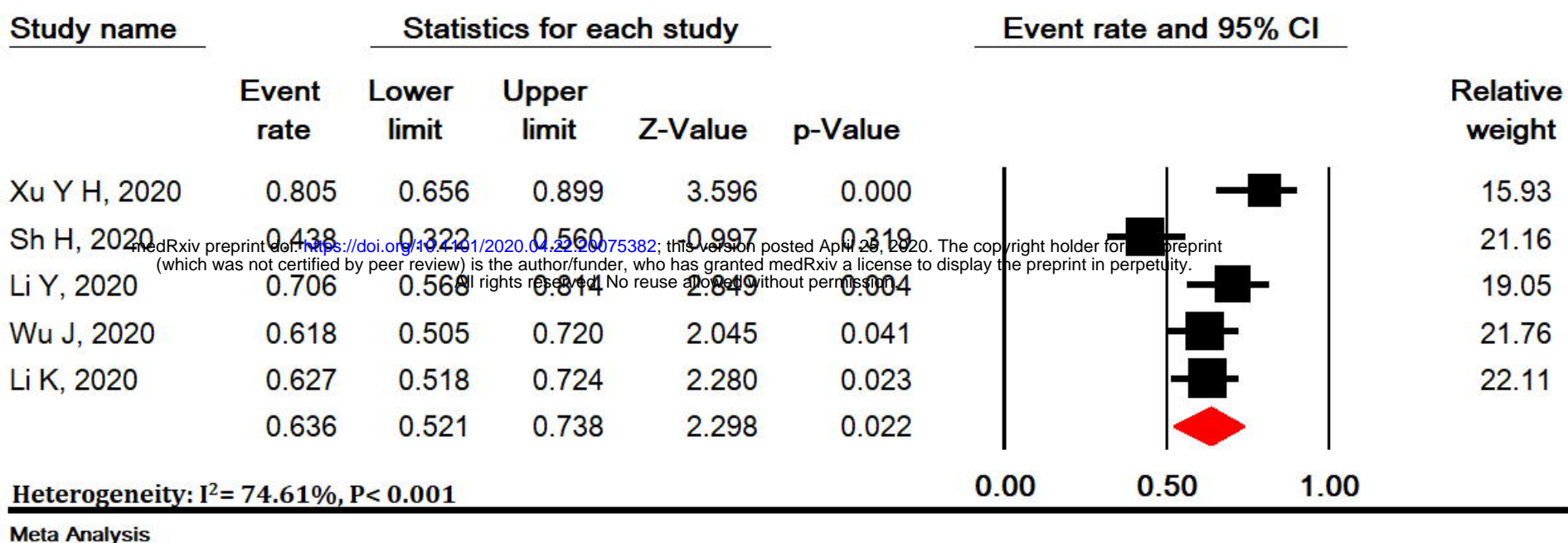


Meta Analysis

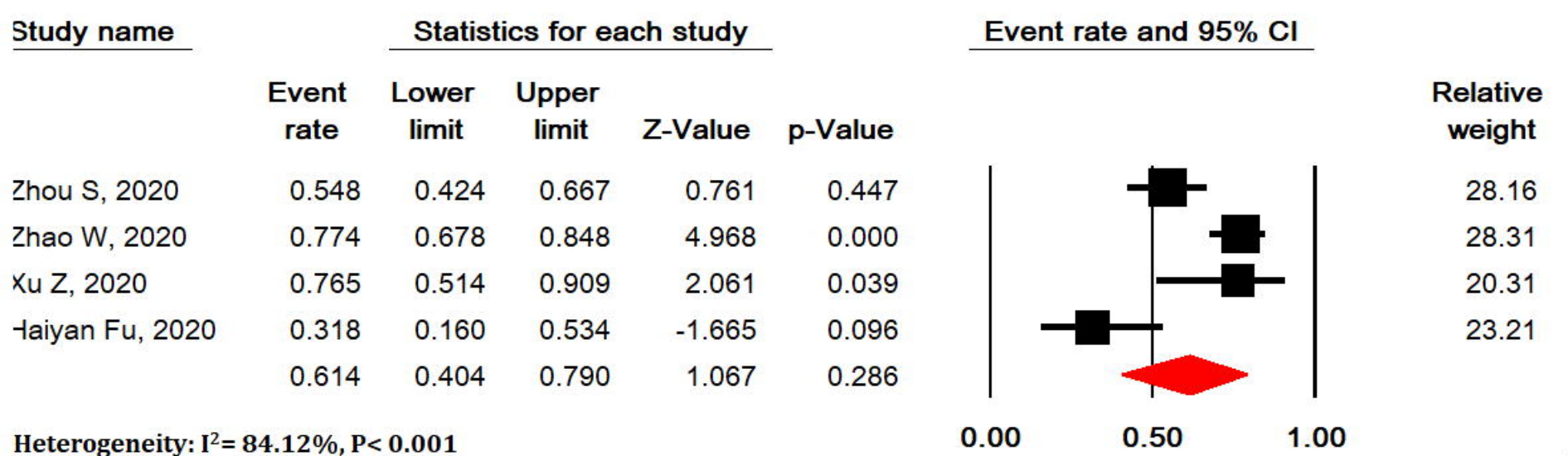


Meta Analysis

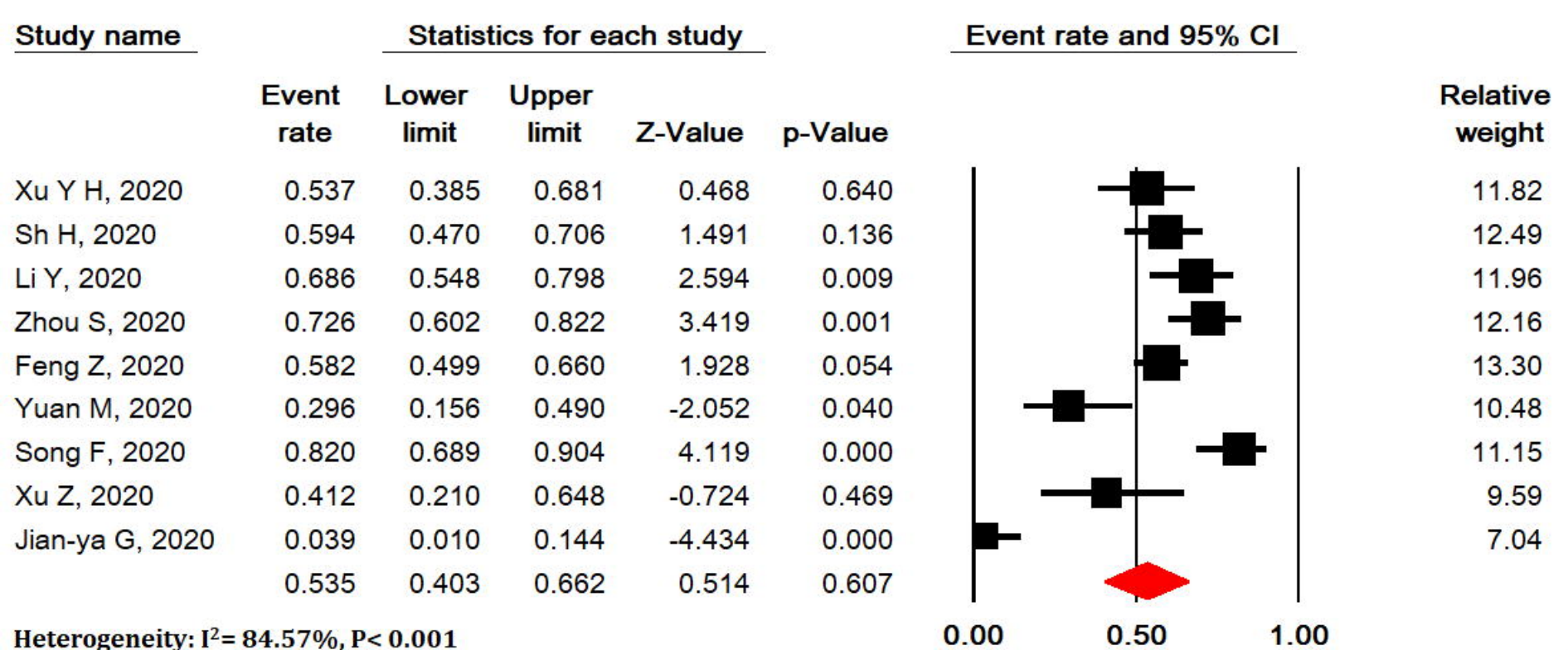
A



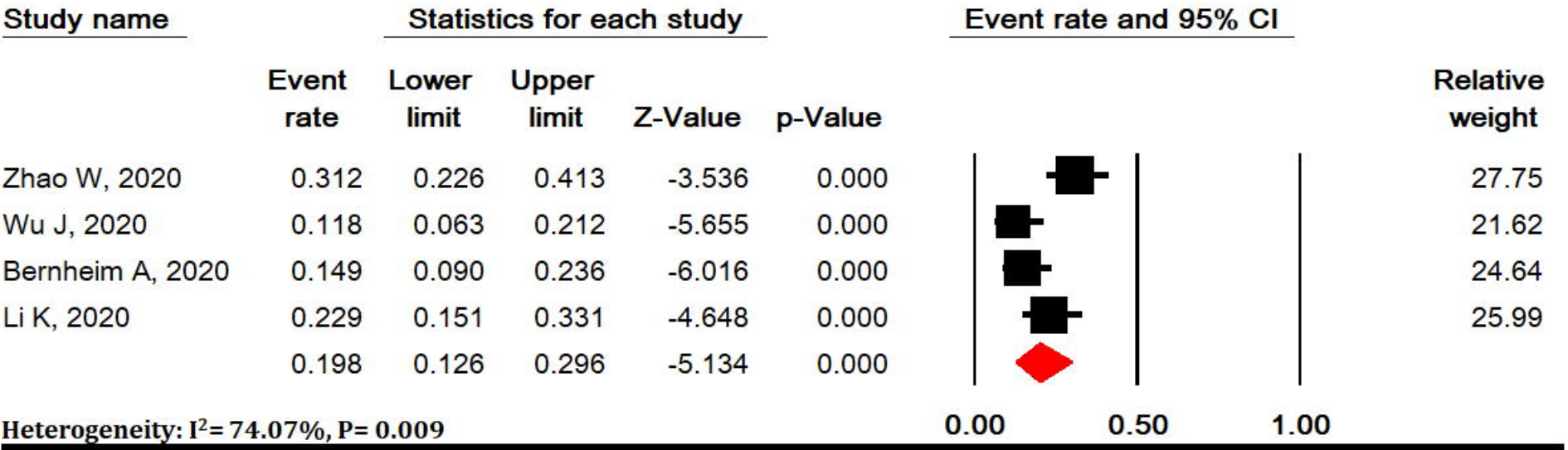
B



C

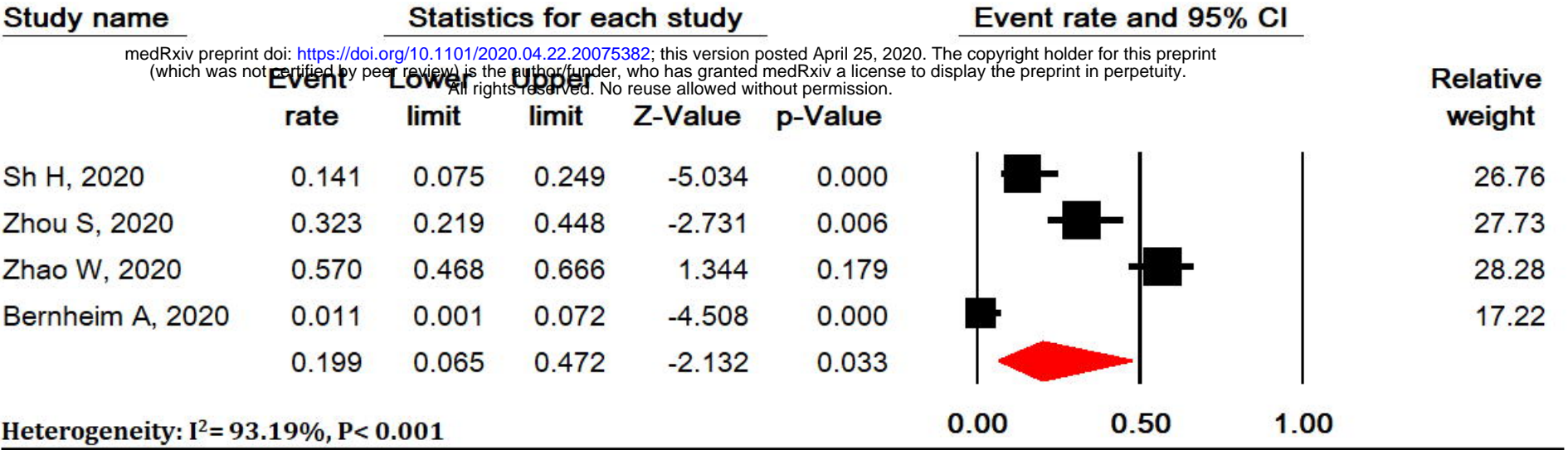


D



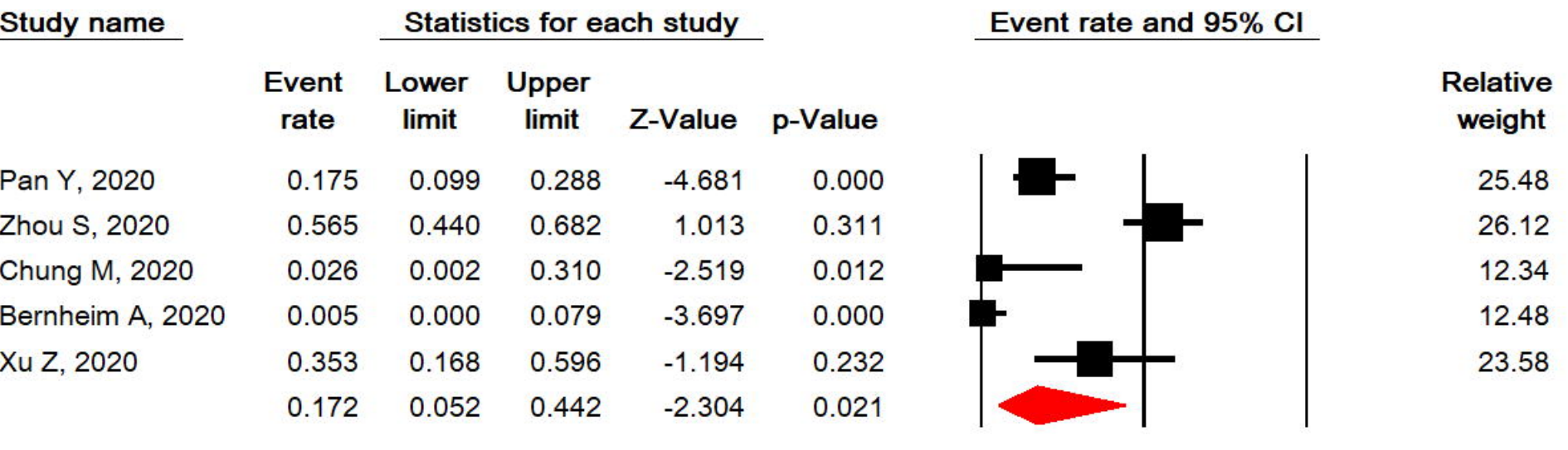
Meta Analysis

E



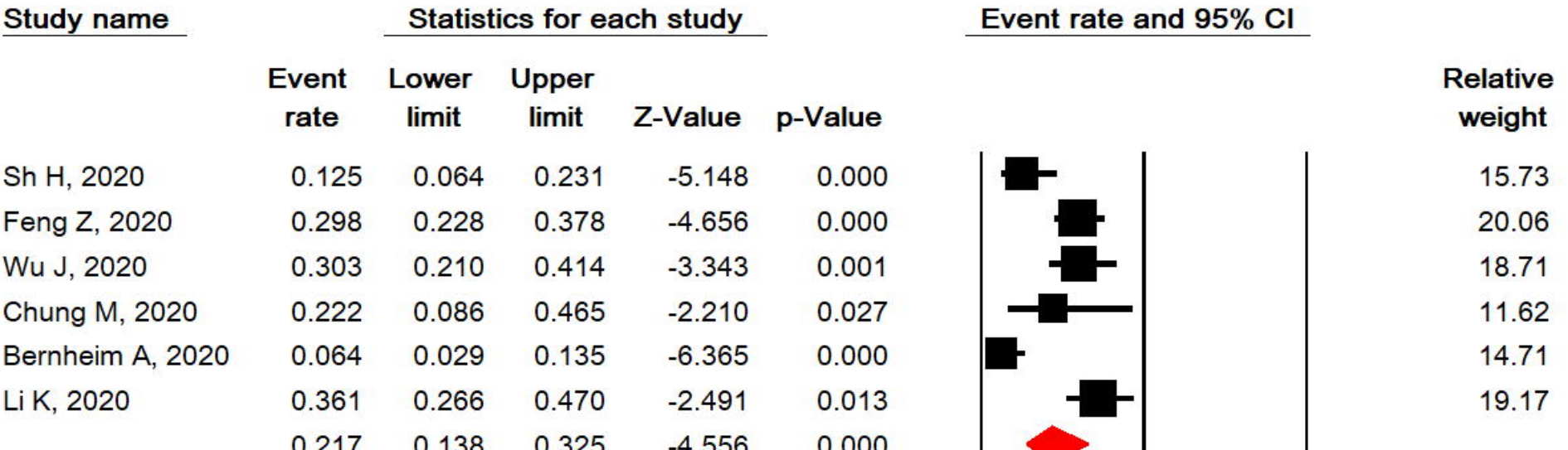
Meta Analysis

F

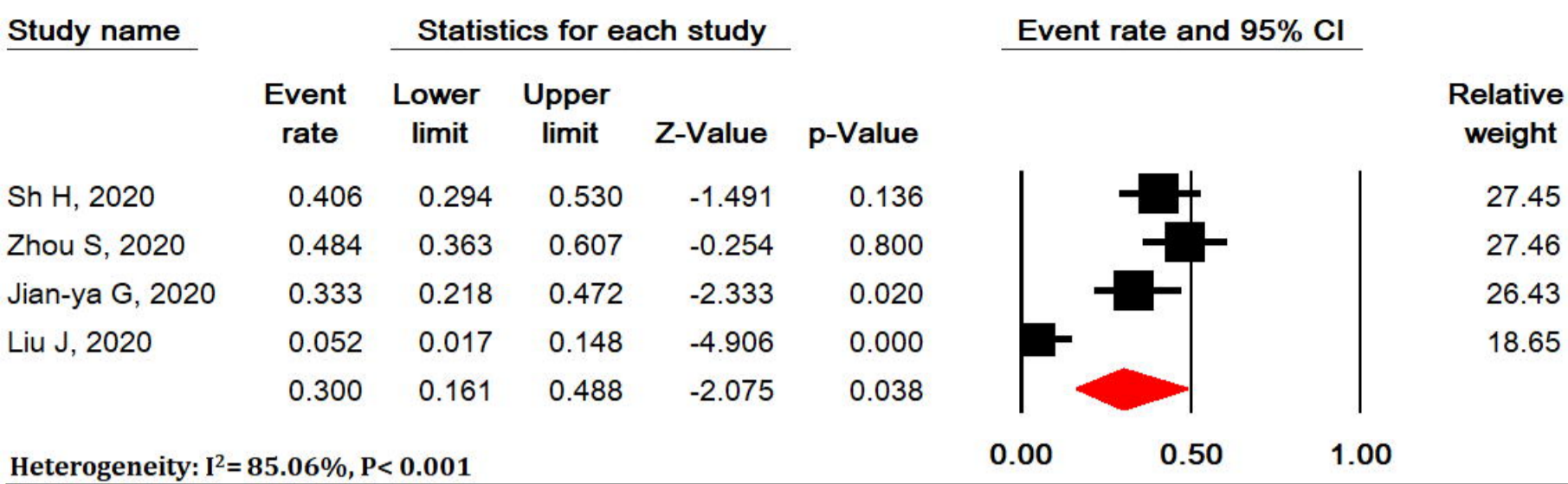


Meta Analysis

G

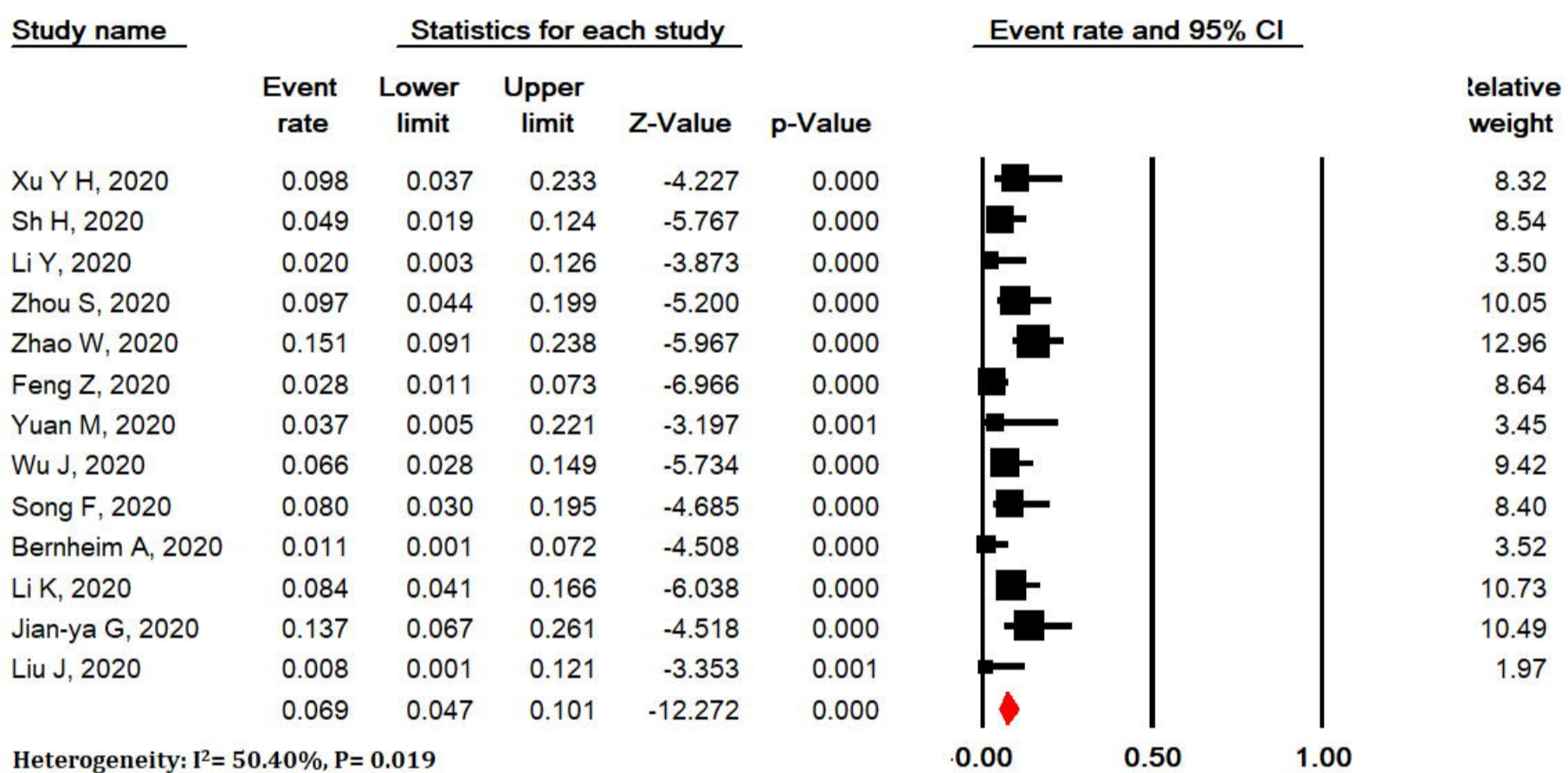


Meta Analysis

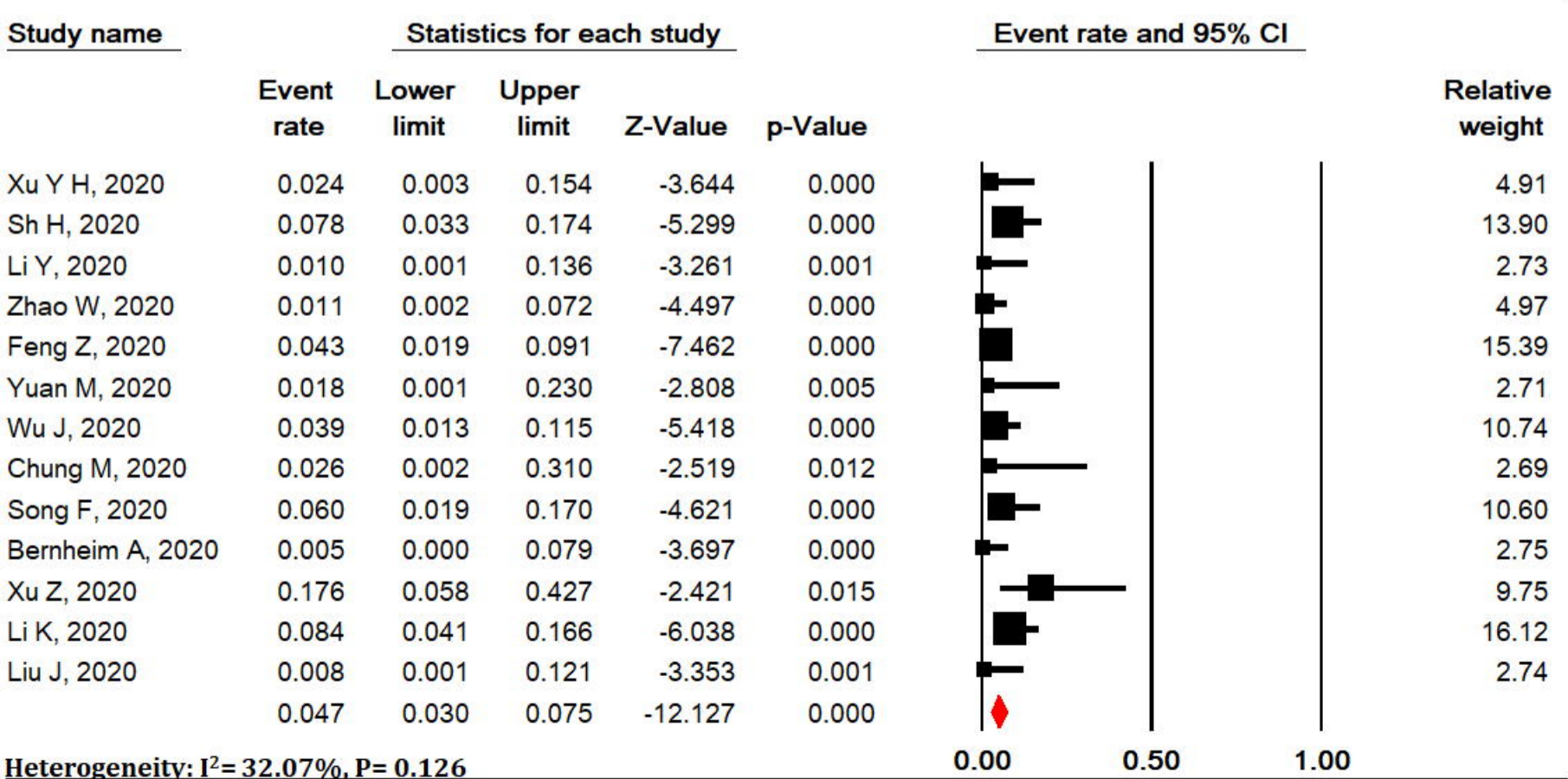


Meta Analysis

medRxiv preprint doi: <https://doi.org/10.1101/2020.04.22.20075382>; this version posted April 25, 2020. The copyright holder for this preprint (which was not certified by peer review) is the author/funder, who has granted medRxiv a license to display the preprint in perpetuity. All rights reserved. No reuse allowed without permission.

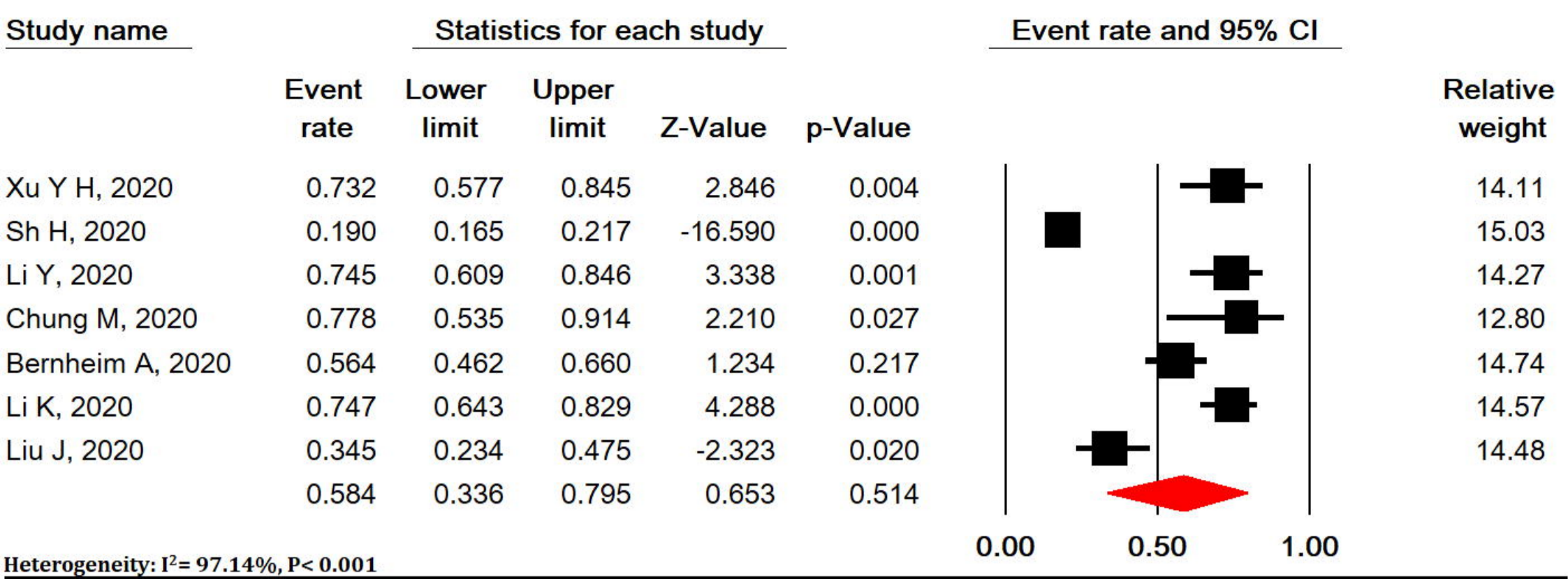


Meta Analysis



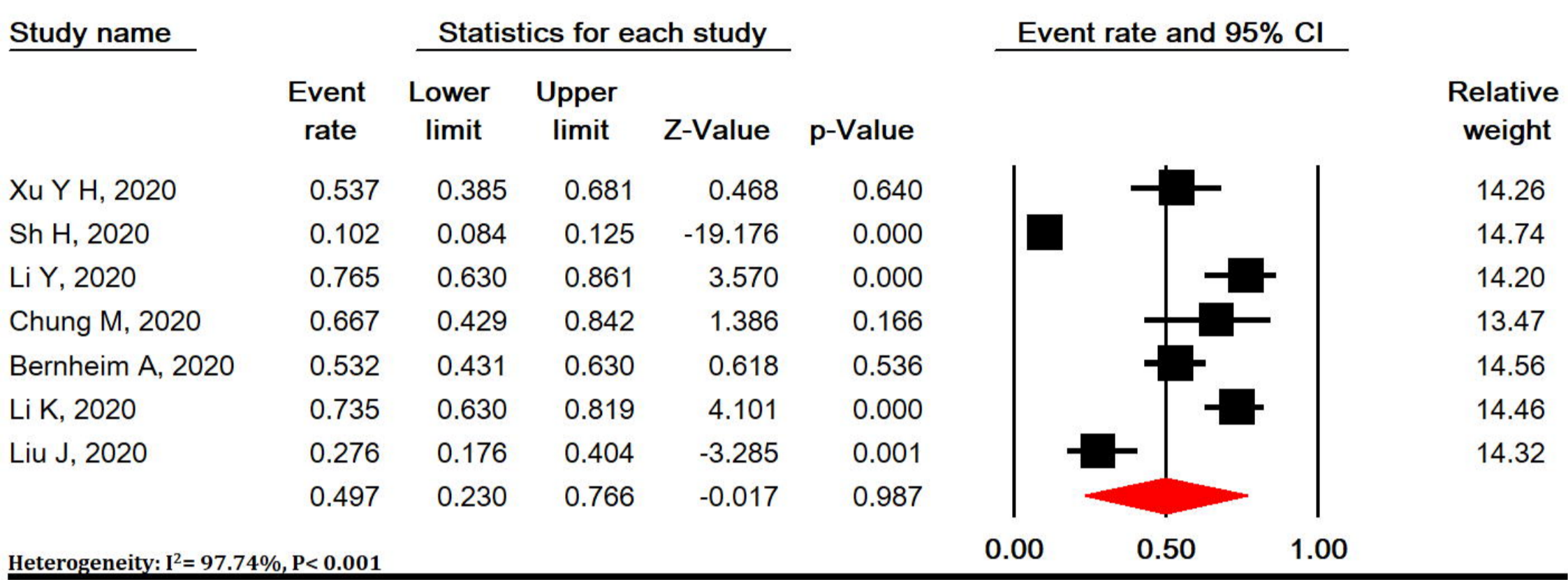
Meta Analysis

A



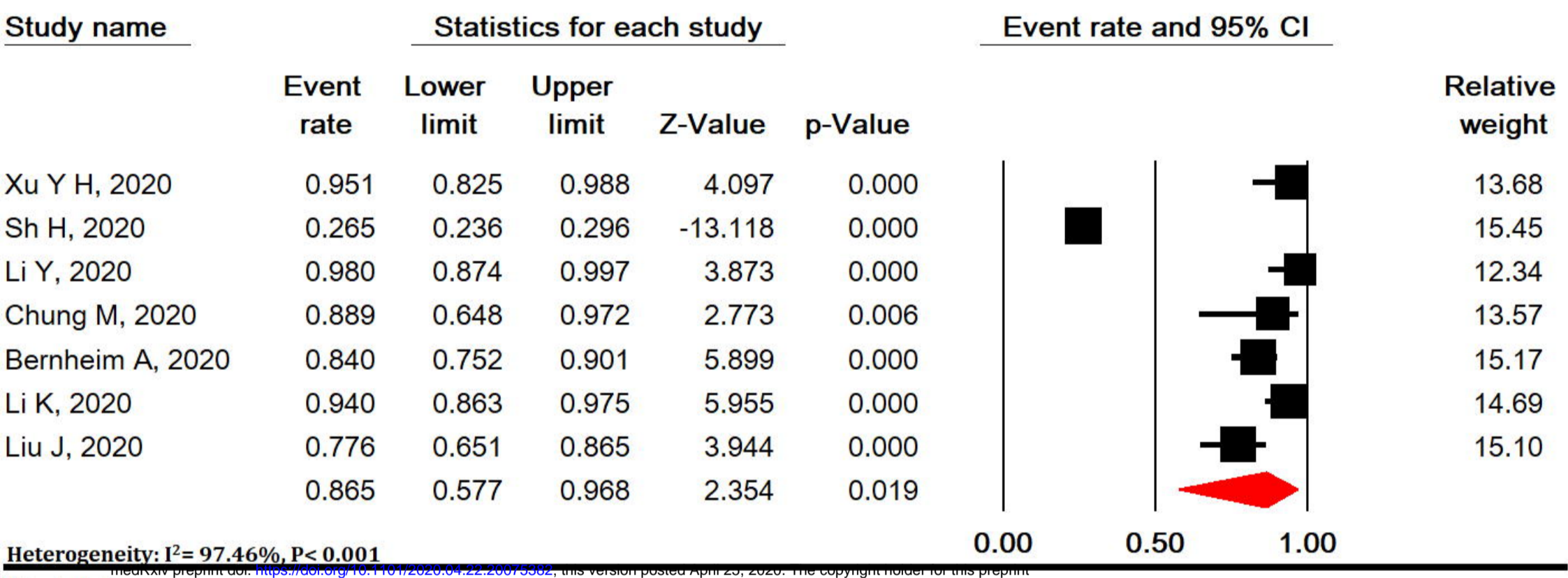
Meta Analysis

B



Meta Analysis

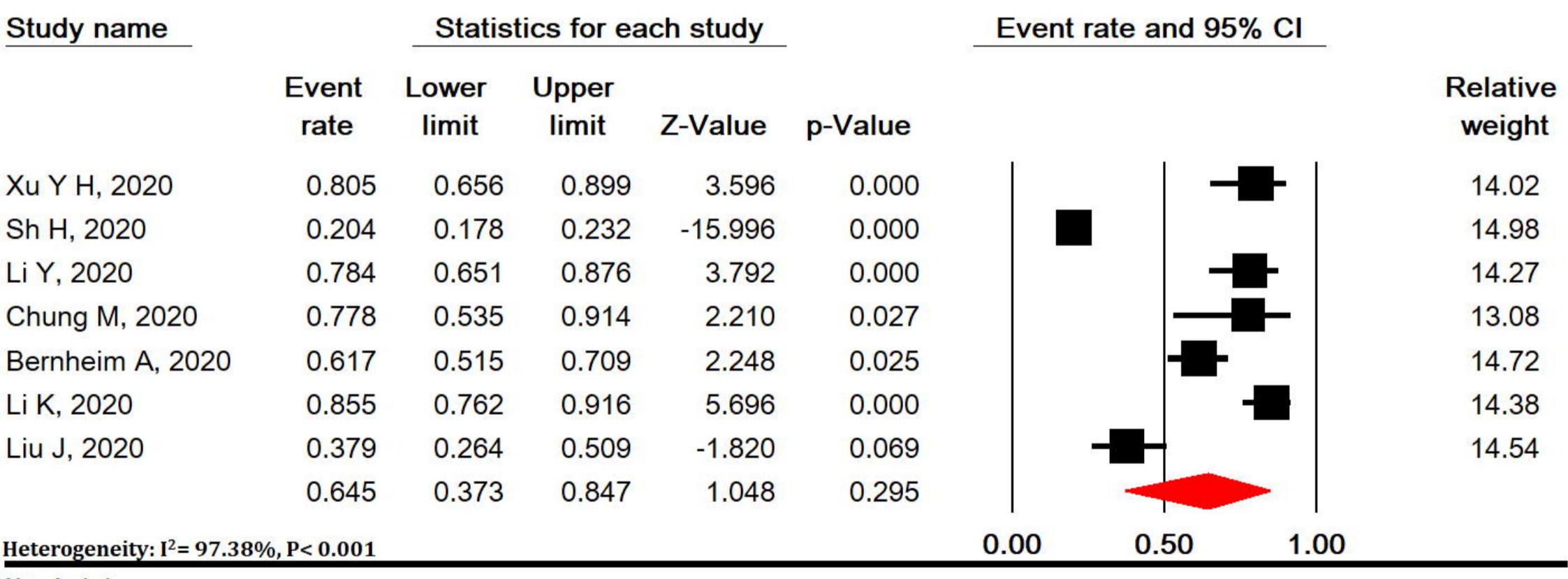
C



medRxiv preprint doi: <https://doi.org/10.1101/2020.04.22.20075302>; this version posted April 20, 2020. The copyright holder for this preprint (which was not certified by peer review) is the author/funder, who has granted medRxiv a license to display the preprint in perpetuity. All rights reserved. No reuse allowed without permission.

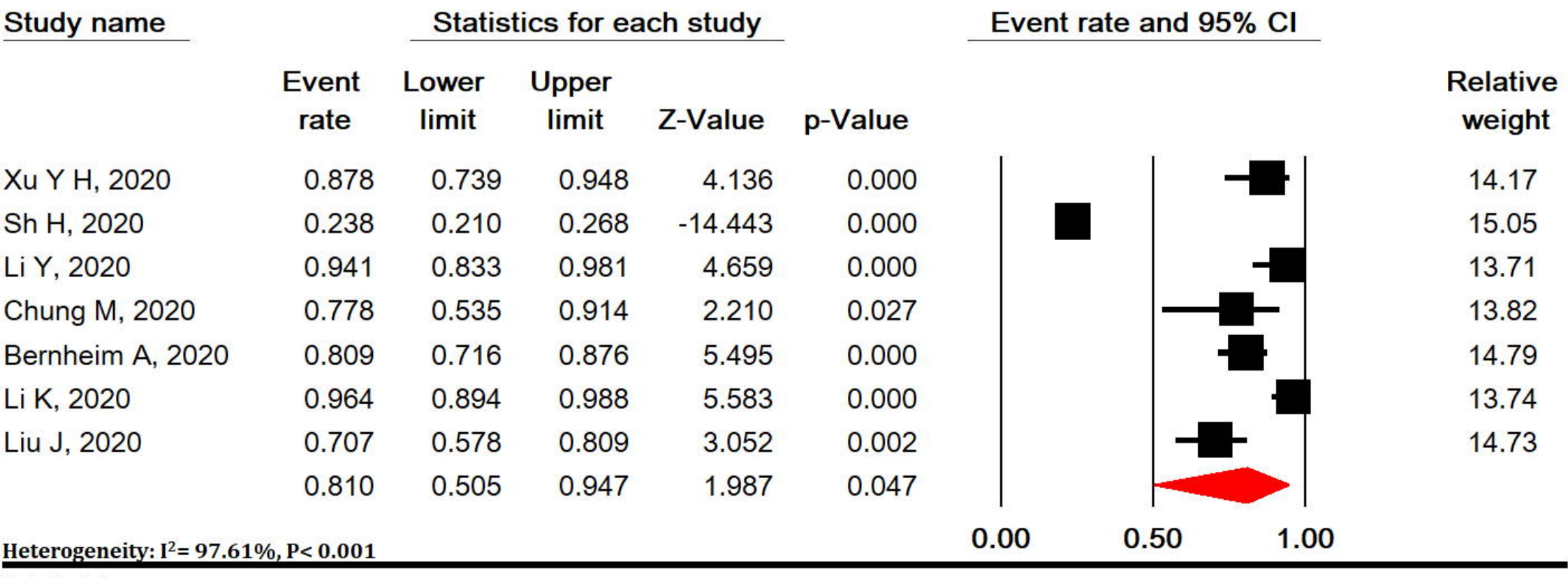
Meta Analysis

D



Meta Analysis

E



Meta Analysis